Use of CT and PET in Radiation Therapy

Refresher Course

Sasa Mutic
Mallinckrodt Institute of Radiology
Siteman Cancer Center
Washington University School of Medicine
St. Louis, Missouri 63110

Outline

- Multimodality-imaging in RT
- Current status of CT-simulation
- PET imaging for RT
  - MO-B23A-1 PET Systems: Design, Performance, and Evaluation
  - TH-B23A-1 PET Scanner Quality Assurance and Acceptance Testing
  - TU-B23A-1 Data Correction and Image Reconstruction Methods for PET
  - WE-B23A-1 PET/CT and Image Fusion Issues
- CT/PET image registration process
- Influence of PET imaging on RT
- Examples of PET based treatment planning
- Conclusions

Multimodality-imaging in RT

- Patient medical images are an essential tool in conformal radiation therapy
- Computed tomography (CT) is the primary modality for image based treatment planning
- Other imaging modalities can provide unique information which may improve overall patient management
  - Magnetic resonance imaging and spectroscopy,
  - Single photon and positron emission computed tomography (SPECT and PET),
  - Ultrasound (US)
  - Molecular imaging
- The goal is to biologically characterize and accurately delineate an individual tumor and to predict the response to the planned course of therapy at the earliest possible time

The potential of multimodality-imaging in RT

- Detection – Possibly better and earlier detection
- Staging - Improved staging and patient selection
  - Functional imaging can influence the course of patient therapy, including intermodality and intramodality changes
  - Improved staging can define a more appropriate course of therapy

The potential of multimodality-imaging in RT

- Target definition
  improved target identification may significantly alter current treatment volumes in some cancer sites
- Dose distribution
  treatment plans could also be modified to deliver escalated doses to certain portions of target volumes

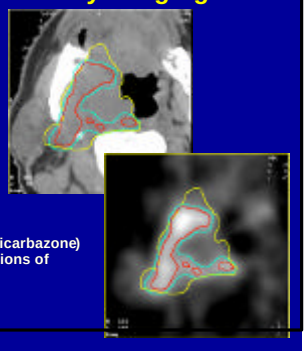

Cu(II)-diacetyl -bis (N^4-methylthiosemicarbazone) (^{60}Cu-ATSM) PET - used to detect regions of tumor hypoxia

The potential of multimodality-imaging in RT

- Treatment planning- continued
  - Tumor biology and therapy selection –
    - » Radiation or chemotherapy sensitivity
    - » Multi-modality therapy integration
    - » Indicator for more aggressive therapy in certain patients
  - New treatment techniques
    - » Revised target volumes and dose distributions will call for modification of current treatment techniques
- Evaluation - Therapy response and follow-up
  - Tumor control
  - Normal tissue function

CT simulator

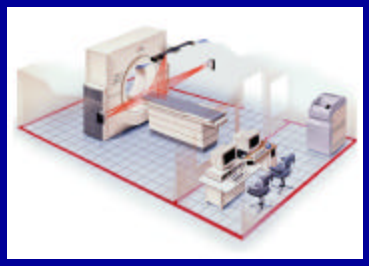

- CT scanner with external lasers
- Flat table top
- Virtual simulation software
- Simulation film output devices

CT scanner – x-ray tube

Courtesy Philips Medical Systems, Inc.

- Large number of images per study
  - DRR quality
  - Target delineation
- Rapid study acquisition time
  - Spatial and temporal integrity
  - Motion artifacts
- Large heat anode storage ability (MHU): 5-7 MHU tubes
- Fast anode cooling rate (MHU/min)

CT scanner – Single and multi-slice scanning

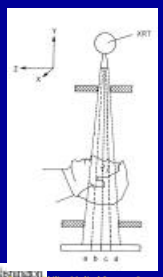

Philips Medical Systems, Inc.

- Wider collimator widths
- Post patient collimation
- Multiple area detectors
  - 1992 - Elscint CT Twin - first CT scanner capable of simultaneously acquiring more than one transaxial slice
  - 1998 – Four major manufacturers introduce scanners capable of scanning 4 slices simultaneously
  - 16 slice scanners available, larger slice count scanners under development

CT scanner – Single and multi-slice scanning

- Multi-slice:
  - Faster scan times (at least 8 times faster)
    - » multi: 0.5 sec/rotation and 4 slices/rotation
    - » single: 1 sec/rotation and 1 slice/rotation
  - Lower tube heat loading
    - » Longer volume covered per rotation
  - Reduced slice thickness
  - Improved temporal resolution - faster scan times
  - Improved spatial resolution – thinner slices
  - Decreased image noise – more mA available

Courtesy Philips Medical Systems, Inc.

DRR/DCR Image Quality

- Everything else being equal, thinner slices produce better images
- Balance between large amounts of data and image quality

Courtesy Varian Medical Systems, Palo Alto, CA

CT scanner – Single and multi-slice scanning

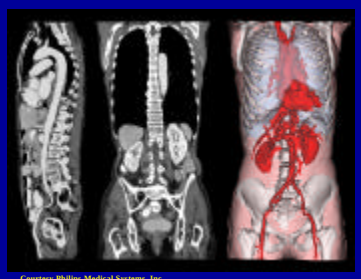

Courtesy Philips Medical Systems, Inc.

Measurement of Lung Motion (free breathing)

- Use multislice CT scanner
  - 12-slices, 0.5s per scan, 1.5mm per slice
- Ciné mode (15 acquisitions)
  - Couch does not move between slices
- Spirometry indexes CT scans for later analysis
- Take CT scans and redistribute according to lung volume
- Produced 4-D CT scan

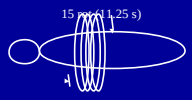

D. A. Low, *et al.*

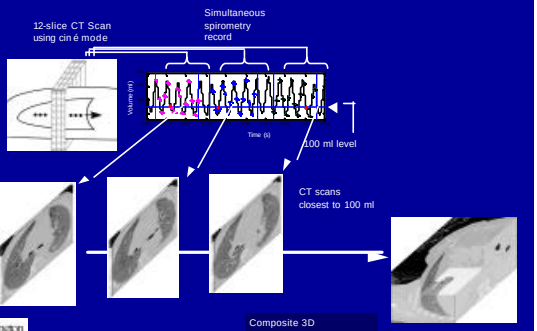

D. A. Low, *et al.*

Composite 3D CT scan reconstructed at 100 ml free breathing tidal volume

Results

Show 3D distribution as sagittal slices

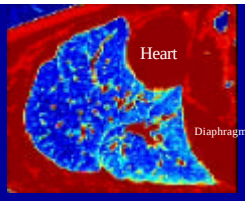

D. A. Low, *et al.*

Tissue/Tumor = red
Air/Lung = Blue

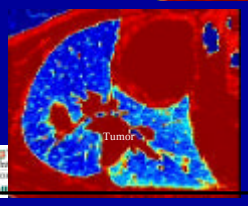

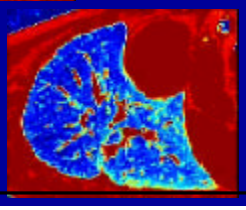

CT scanner – Bore size

85 cm Bore Opening

70 cm Bore Opening

CT scanner – Bore size

Bilateral Breast

CT scanner – Bore size

Upper Thigh Sarcoma

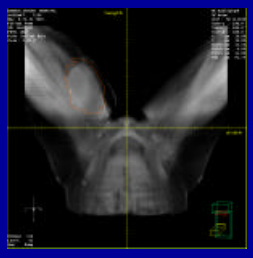

CT scanner

- Large bore
  - Improved setup flexibility
  - Improved immobilization flexibility
  - Increased scanned field of view (60 cm)
  - Image quality comparable to 70 cm diagnostic scanners
- Multi-slice
  - Thinner slices, longer volumes, more images for same tube heat
  - Lung scanning
  - It is not clear how many slices are needed to fully take advantage of this technology

Virtual simulation software

- Available from many vendors
- Fast/sophisticated systems
- Almost all packages offer image registration/fusion capabilities
- Almost all systems allow import of multimodality images

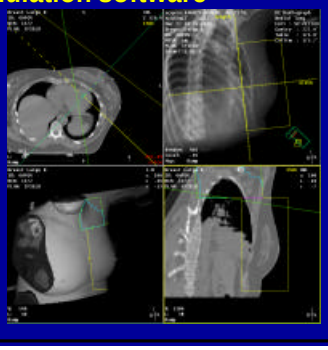

Localization on CT Console

- SIMULATION functions directly on the CT console
- Segmentation and localization
  - Create structures
  - Define target volume
  - Mark isocenter
- Export DICOM RT
  - RT Structure Set
  - RT plan
- Not intended to replace virtual simulation software

Courtesy Philips Medical Systems, Inc.

Quality assurance for CT simulators and the CT simulation process: Report of the AAPM Radiation Therapy Committee Task Group No. 66

- Sasa Mutic, Jatinder R. Palta, Elizabeth K. Butker, Indra J. Das, M. Saiful Huq, Leh-Nien Dick Loo, Bill J. Salter, Cynthia H. McCollough (Advisor), and Jacob Van Dyk (Advisor)
- Approved by the Radiation Therapy Committee - March 2003
- Approved by the Science Council - April 2003
- Accepted for publication in Medical Physics Journal – July 2003
- Expected publication date – Fall 2003

AAPM TG66

- QA recommendations and guidelines for diagnostic radiology and radiation therapy for CT-Simulators
- Equipment description
- Tests for
  - CT scanners
  - Virtual simulation software
  - Image registration
  - Overall CT-Simulation process
- Test frequencies, methods, equipment, and tolerances

PET Imaging for RT

- Provides information about physiology rather than anatomy
  - Tumor metabolism
  - Differentiation between tumor recurrence and radiation necrosis
  - Regional lung function

Para-aortic L.N.

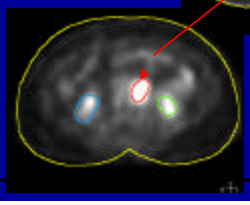

- Poor resolution
  - Difficult to delineate target and organ boundaries
  - Difficult to appreciate external contours

PET Imaging for RT

- DIAGNOSTIC SCANS
  - Detection
  - Staging
  - Treatment modality selection
  - Outcome prognosis
  - Therapy evaluation and follow up
  - Scan geometry is less important
  - Fusion or image registration with other imaging modalities less critical
- TREATMENT PLANNING SCANS
  - Target definition
  - Guidance for dose distribution and dose escalation
  - Patient positioning, immobilization, and scan geometry are extremely important
  - Fusion and image registration capabilities are mandatory

PET imaging for RT

- ^{18}F-fluorodeoxyglucose (^{18}F-FDG) is the primary imaging agent used for RT imaging
  - Lung
  - Breast
  - Colorectal
  - Melanoma
  - Head and neck
  - Pancreas
  - Brain
  - Thyroid
  - Sarcoma
  - GYN
  - Lymphoma
- Other imaging agents are extensively used and new are continually being developed
  - Slow growing tumors
  - Hypoxic regions

PET imaging for RT

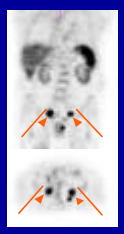

C-11 acetate

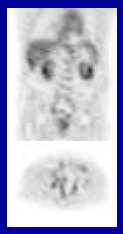

F-18 FDG

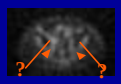

Prostascint

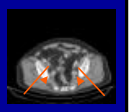

CT

Oyama *et al.* J Nuc Med 44, 549-555, 2003

Treatment planning process

These can be separate units or a combined CT/PET machine

- Setup reproducibility the primary concern
- Poor setup reproducibility may require deformable image registration

RT Treatment Planning with PET

- Target definition
  - Improved target definition?
- Dose distribution
  - Altered dose distributions based on PET indications
  - Dose escalation
- Modified treatment techniques based on PET guidance

Fusion/Image Registration

- Lack of anatomical definition makes a registration with CT image a necessity
- Due to this lack of anatomical definition CT and PET study registration is somewhat challenging
- Combined PET/CT scanners can simplify the process

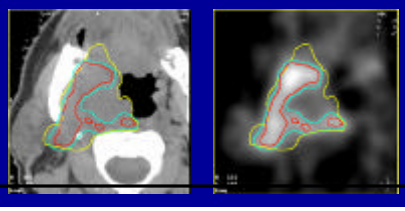

Multimodality Image Registration

- Registration Techniques:
  - Surface-based Registration
    - » Internal
    - » External
  - Image-based Registration
  - Point-based Registration
  - Automatic and semiautomatic computer assisted methods

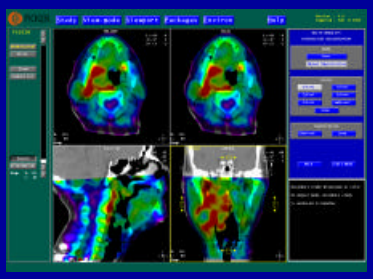

Fiducial Markers

- 0.5 cm diameter, 3.5 cm long, 0.25 ml, plastic, disposable microcentrifuge tubes
- VWRbrand Disposable Microcentrifuge Tubes, VWR Scientific Products, West Chester, PA
- CT, MR, and PET compatible
  - CT - Aluminum
  - MR - 4 mM $CuNO_3$
  - PET - ^{18}F-deoxyglucose

Fiducial Markers

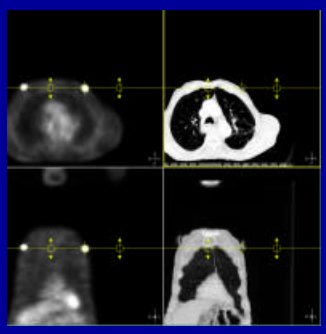

Image Registration Phantom

Contour Correlation

CT

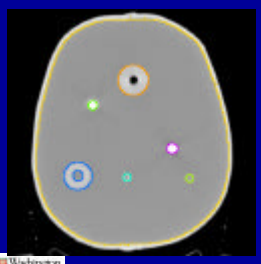

PET

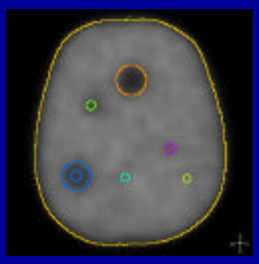

Mutic et al. IJROBP 51, 255-260. (2001).

Patient positioning and immobilization

Flat Tabletop

Registration Device

Patient positioning and immobilization
Registration Device

- Relatively small size of the PET scanner gantry opening limits the size of body mould to approximately 20 inch width

Laser positioning system



- For extracranial, patient position reproducibility is greatly improved if the PET scanner is equipped with external laser positioning system similar to a CT-simulator

PET/CT scanner combined unit

- Multislice CT scanner mated to a PET scanner
- Possibly three scans acquired during procedure
  - Attenuation correction CT
  - PET
  - Treatment planning CT, with contrast if necessary

PET/CT scanner combined unit
Patient Motion

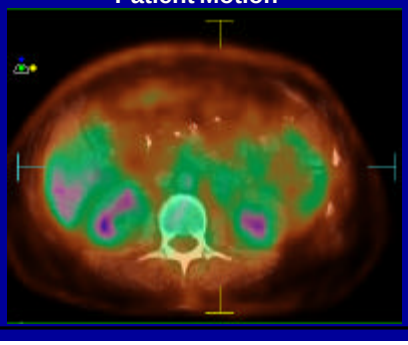

Staging with PET for RT

- Locoregional disease progression or symptomatic distant metastasis soon after therapy are indicators that the true extent of the disease was not appreciated
- Conventional staging commonly underestimates the true extent of NSCLC, for example
- Tumor stage is often the strongest prognostic factor and the most important parameter that guides treatment decision making
- PET imaging has been shown to be superior to conventional imaging in staging of several tumors (NSCLC, GYN, colorectal, etc.)
- It has a potential to improve treatment planning and provide valuable prognostic information
- Accurate staging will help render treatment appropriate for that stage
- Differentiate between tumor and other abnormalities (e.g. atelectasis)

Detection and Staging with PET
NSCLC EXAMPLE

- Mac Manus MP, et al. *Cancer, 92:886-895, 2001*
  - Prospective, n=153, unresectable NSCLC
  - "before PET" and "after PET" staging
  - subsequent management and survival recorded
  - "after PET" stage strongly assoc w/ survival (p=.0041) 2 yr
  - detected unsuspected metastases in 20% - upstaged
  - downstaged 5 pts. - went on to potential curative Sx
  - 22/102 (RT) pts. significant increase in target volume
  - 16/102 (RT) pts. significant reduction in target volume

Detection and Staging with PET
NSCLC EXAMPLE

- Mah K, et al. *IJROBP, '02*
  - Prospective, n=30, unresectable NSCLC
  - Multiple observers used for target volume delineation
  - detected unsuspected metastases in 7 of 30 (22%) patients - upstaged
  - 30-76% pts. increase in target volume
  - 24-70% pts. reduction in target volume

Staging and Patient Management with PET
OVERALL IMPACT

- Dizendorf *et al*. J Nuc Med 44:24-29, 2003

Diagnosis	Patients (n)	Patients with therapy changes	
		n	%
Head and Neck Tumor	55	18	33
GYN Tumor	28	9	32
Breast Cancer	28	7	25
Lung Cancer	26	8	31
Malignant lymphoma	24	5	21
Gastrointestinal tract tumor	18	4	22
Unknown primary tumor	4	3	75
Malignant Melanoma	2	1	50
Other tumors	17	0	0
Total	202	55	27

Changes in management of radiation therapy relating to volumes, dose, or intent

Staging with PET for RT
IMPACT AND ITS VALIDATION

- Hicks and Mac Manus, J Nuc Med 44:30-32, 2003
  - » False positive PET findings may deny patients potentially curative treatment
  - » Histopathological validation of PET findings for RT patients
  - » Impact on the outcomes
  - » Impact on the quality of life

RT Treatment Planning with PET
TARGET DEFINITION

- Depending on image window and level setting, target volume can easily change by 50%

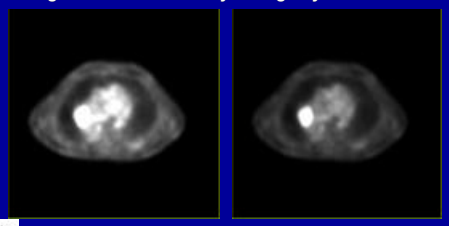

RT Treatment Planning with PET
TARGET DEFINITION

- Setting the PET image parameters so the tumor volume corresponds to CT image
- Erdi *et al. Cancer 1997*
  - Segmentation by CT-guided adaptive thresholding method
  - Phantom data used for determination of fixed threshold value for sphere volumes larger than 4 mL (from 36% to 44%)
  - CT used for estimation of lesion size and PET for estimation of signal to background ratio
  - 10 patients with 17 metastatic lung lesions
  - PET volumes compared with CT volumes
  - PET provides accurate volume estimations for lesions larger than 4 mL with a single threshold

RT Treatment Planning with PET
TARGET DEFINITON

- Respiratory Gating - Nehmeh *et al.* Med Phys 29:366-371, 2002
  - Respiratory motion during PET imaging degrades image quality and affects quantitative PET information
  - Motion reduces ability to detect small lesions
  - Reduction in measured standard uptake values (SUV)
  - Target volumes overestimated
  - PET images acquired in synchronization with the respiratory motion
  - Acquired images resulted in reduction of target volumes and increase of SUV

RT Treatment Planning with PET
TARGET DEFINITON

- Caldwell *et al.* IJROBP 55:1381-1393, 2003
  - Internal target volume (ITV) definition based on motion during PET imaging
  - Effect on definition of planning target volumes (PTVs)
  - Phantom study
  - Comparison of CT-based PTVs, PET –based PTVs, and ideal (calculated) PTVs
  - Fast CT-imaging of a moving target results in distorted target volumes
  - PET can provide a more accurate definition of time averaged postion of target volumes

Altered/Escalated Dose Distributions
^{60}Cu-ATSM (Hypoxia) - Guided IMRT

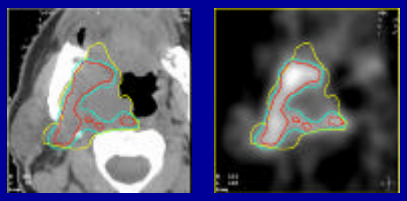

Chao *et al.* IJROBP 49:1171-1182, (2001).

Altered/Escalated Dose Distributions
^{60}Cu-ATSM (Hypoxia) - Guided IMRT

- 80 Gy in 35 fractions to the hypoxic tumor sub-volume as judged by Cu-ATSM PET (red)
- GTV (blue) simultaneously receives 70 Gy in 35 fractions
- Clinical target volume (yellow) receives 60 Gy
- More than half of the parotid glands (green) are spared to less than 30 Gy.

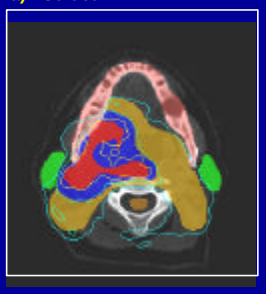

Chao *et al.* IJROBP 49:1171-1182, (2001).

Altered/Escalated Dose Distributions
PET Guided GYN Brachytherapy Implants

- Mutic *et al.* IJROBP 52: 1104-1110, (2002).
- PET images may allow more accurate delineation of three-dimensional treatment planning (3DTP) target volumes of brachytherapy gynecologic (GYN) implants
- This study evaluated the feasibility of using PET images as the sole source of target and normal structure geometries for intracavitary brachytherapy GYN implant treatment planning using a commercial treatment planning system

Mutic *et al.* IJROBP 52: 1104-1110, (2002).

Altered/Escalated Dose Distributions
PET Guided GYN Brachytherapy Implants

- Tandem and colpostat applicator inserted in the OR
  - Applicator design and mode of delivery (HDR or LDR) not important
- Foley catheter placed in the urinary bladder
- Patient taken to the PET scannerwhere 555 MBq (15 mCi) ^{18}F-FDG (^{18}F-fluorodeoxyglucose) is intravenously administered
- Three small tubes containing ^{18}F-FDG inserted into the applicator
- Whole pelvis scan obtained and images transferred to the treatment planning system (FOCUS, CMS, St. Louis, MO)
- 3D treatment plan created with target and normal structure DVHs

Anatomy
PET Guided GYN Brachytherapy Implants

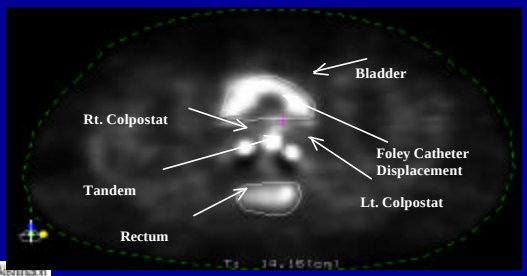

Treatment planning

PET Guided GYN Brachytherapy Implants

- Applicators, critical structures and tumor contoured
- Software places sources at predefined positions with respect to applicator tips
- Source strengths and treatments times optimized
- Alternatively, deliver conventional dose distributions

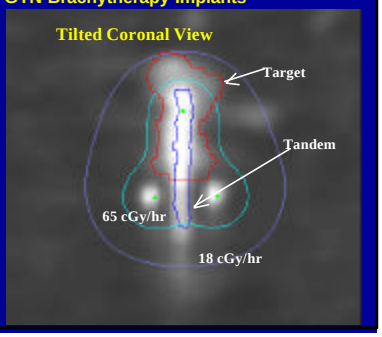

Conventional Dose Distributions

PET Guided GYN Brachytherapy Implants

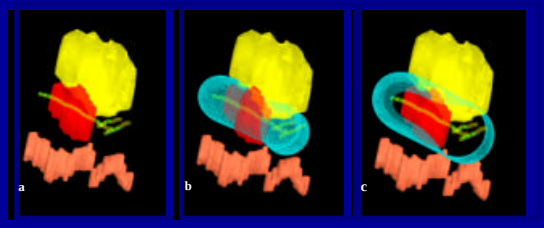

Optimized Dose Distributions
PET Guided GYN Brachytherapy Implants

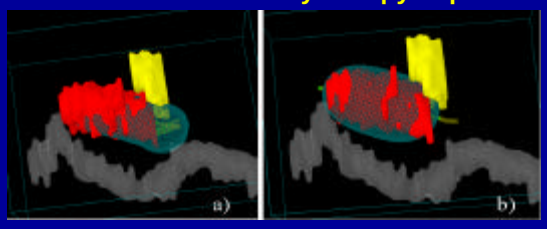

- Same Integrated Reference Air Kerma (IRAK) Strength used for both plans
- Dwell positions rearranged to conform dose distribution

Altered/Escalated Dose Distributions

FDG-PET Guided IMRT for Treatment of Cervical Cancer Patients with Positive Para-aortic Lymph Nodes

FDG-PET CT

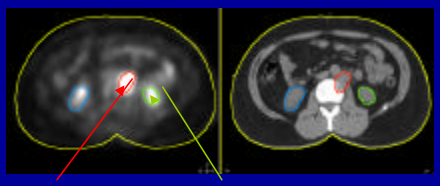

Para-aortic L.N. Kidney

Mutic *et al*. IJROBP 55:28-35, (2003).

FDG-PET Guided IMRT for Treatment of Cervical Cancer Patients

- Pelvic area (1) treated with conventional techniques
- Para-aortic area (2) treated with IMRT
- PET used for identifying positive para-aortic lymph nodes (PALN)
- CT used as the primary imaging modality
- Conventional doses delivered to pelvic area
- Dose escalated to the para-aortic region
  - 59.4 Gy to positive PALN
  - 50.4 Gy to PALN bed
  - Conventional PALN bed dose 45 Gy

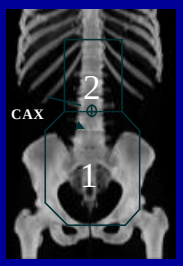

Altered/Escalated Dose Distributions

IMRT Dose to PALN

50.4 Gy to PALN bed

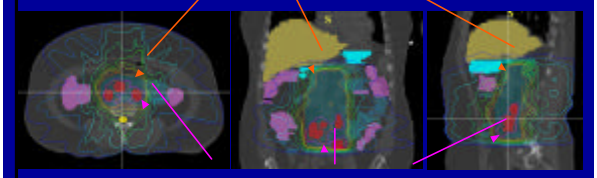

59.4 Gy to positive PALN

Critical structure doses (Kidneys, colon, small intestine, liver, stomach, and cord) are kept at acceptable levels.

Conclusions

- CT-simulation has proven to be a valuable tool in the treatment planning process
- It will likely remain the primary imaging modality to which other studies will be registered
- The role of PET in radiation therapy and its impact needs further evaluation
- For several treatment sites it has already been shown that PET studies have a strong potential to improve staging, outcome prognosis, therapy selection, treatment planning, and follow-up
- The recently introduced combined PET/CT scanner will simplify the treatment planning process