IMRT for H&N Cancer

K.S. Clifford Chao, M.D.

Associate Professor
Director of Molecular Image-guided Therapy

Department of Radiation Oncology
University of Texas, M.D. Anderson Cancer Center
Houston, Texas

Outline

- Treatment and QA Techniques
- Target Determination and Delineation
- Clinical Results
- Ongoing Study

Outline

- Treatment and QA Techniques
- Target Determination and Delineation
- Clinical Results
- Ongoing Study

Fabrication of Non-invasive Immobilization Thermoplastic Mask for IMRT

CT Simulation for H&N IMRT

Step-n-Shoot IMRT by Segmental MLC

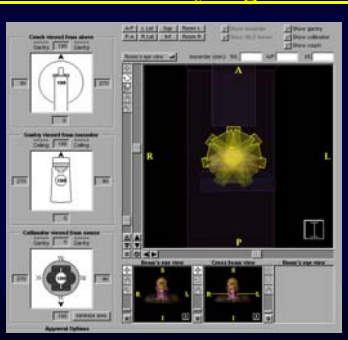

QA for Step-n-Shoot IMRT by Segmental MLC

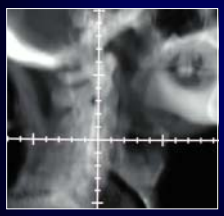

Outline

- Treatment and QA Techniques
- Target Determination and Delineation
- Clinical Results
- Ongoing Study

Target Determination

What to Shoot?

Clinical Target Volume Determination for Head and Neck IMRT

Tumor Site	Clinical Presentation	CTV1 (70Gy/35fx)	CTV2 (63Gy/35fx)	CTV3 (56Gy/35fx)
Oral Cavity				
Buccal RMT	T1-2NO T3-4N+* N2c	GTVp GTVp+n GTVp+n	IN (I-III) IN+CN(I-V)	IN (I-III) CN (I-III)
Oral Tongue	T1-2NO T3-4N+* N2c	GTVp GTVp+n GTVp+n	IN (I-IV) IN+CN(I-V)	IN +/- CN (I-IV) CN (I-IV)
FOM	T1-2NO T3-4N+* N2c	GTVp GTVp+n GTVp+n	IN (I-III) IN+CN(I-V)	IN (I-III) CN (I-III)
Nasopharynx	T1-2NO T3-4N+* N2c	GTVp GTVp+n GTVp+n	IN (I-V, RPLN) IN+CN (I-V, RPLN)	IN+CN (I-V, RPLN) CN (I-V, RPLN)

Chao et al., IJROBP 53:1174, 2002

Clinical Target Volume Determination for Head and Neck IMRT

Tumor Site	Clinical Presentation	CTV1 (70Gy/35fx)	CTV2 (63Gy/35fx)	CTV3 (56Gy/35fx)
Oropharynx				
BOT	T1-2NO T3-4N+* N2c	GTVp GTVp+n GTVp+n	IN (I-V, RPLN) IN+CN (II-IV, RPLN)	IN+CN (II-IV, RPLN) CN (I-V, RPLN)
Tonsil	T1-2NO T3-4N+* N2c	GTVp GTVp+n GTVp+n	IN (I-V, RPLN) IN+CN (II-IV, RPLN)	IN+/-CN (II-IV, RPLN) CN (I-V, RPLN)
Hypopharynx	T1-2NO T3-4N+* N2c	GTVp GTVp+n GTVp+n	IN (II-IV, RPLN) IN+CN (I-V, RPLN)	IN+CN (II-IV, RPLN) CN (II-IV, RPLN)
Larynx	T1-2NO T3-4N+* N2c	GTVp GTVp+n GTVp+n	IN (II-V) IN+CN (I-V)	IN+CN (II-V) CN (II-V)

Chao et al., IJROBP 53:1174, 2002

Target Delineation

Nodal Target for Head and Neck IMRT

For N0 neck, which one will you pick?

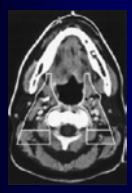

Wijers, 1999

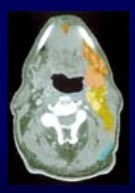

Gregoire, 2000

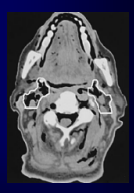

Nowak, 1999

Target Delineation of Clinically N+/N- Necks in Patients Receiving Definitive IMRT

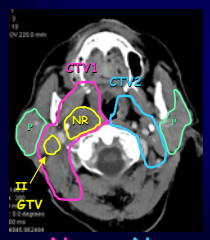

N+ N-

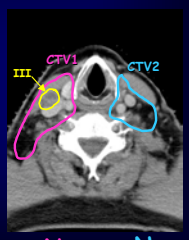

N+ N-

Chao et al., IJROBP 53:1174, 2002

Incidence of Extracapsular Extension of Metastatic Neck Node by Size

Nodal size	<1cm	1-3cm	>3cm
Annyas 1979	23%	53%	74%
Johnson 1981	-	65%	75%
Carter 1987	17%	83%	95%
Hirabayashi 1991	43%	-	81%

Target Delineation of Clinically N+/N- Necks in Patients Receiving Definitive IMRT

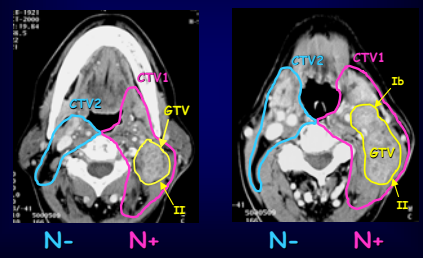

Chao et al., IJROBP 53:1174, 2002

Target Delineation of Pathologically ECE+/ECE- Necks in Patients Receiving Post-operative IMRT

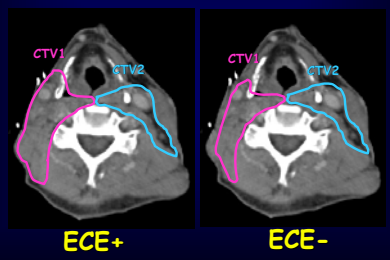

Chao et al., IJROBP 53:1174, 2002

Examples

T2N2bM0 SCC of Tonsillar Fossa

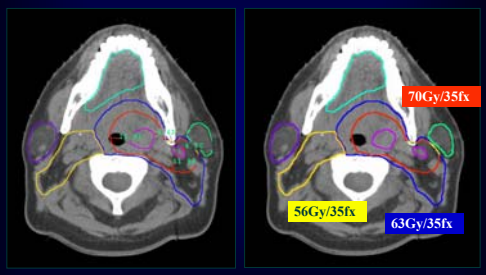

IMRT Target Dose Specification

Target Volume	H&N IMRT			
	Butler	RTOG H-0022	Lee	Chao
Concurrent Chemotherapy	NO All Sites	NO Early Oropharynx	Yes NPC	Yes All Sites
CTV1 70Gy/35fx	60 / 2.4Gy 25fx	66 / 2.2Gy 30fx	70 / 2.12Gy 33fx	70 / 2Gy 35fx
CTV2 60Gy/30fx	-	60 / 2Gy	59.4/1.8Gy	63 / 1.8Gy
CTV3 50Gy/25fx	50 / 2Gy	54 / 1.8Gy	-	56 / 1.6Gy

T2N1M0 SCC of Base of the Tongue

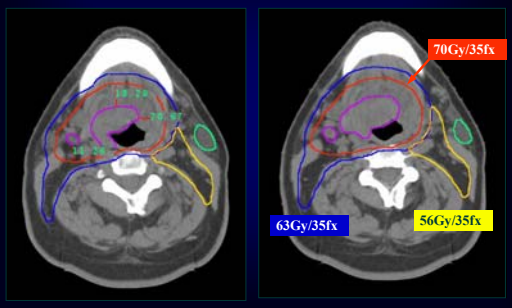

Target Delineation of BOT Carcinoma

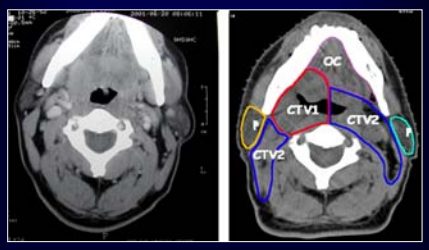

Post-operative IMRT

Sensitivity and Specificity of CT and MRI in Detecting Clinically Negative but Pathologically Positive Neck Nodes

Author	Modality	Pt. No.	Sensitivity	Specificity
Stern 1990	CT	53	40%	92%
Friedman 1990	CT MRI	68 16	68% 80%	90% 82%
Moreau 1990	CT	32	50%	86%
Van den Brekel 1993	CT MRI	49 55	78% 88%	86% 83%
Righi 1997	CT	32	50%	86%

MR Fusion for NPC Target Delineation

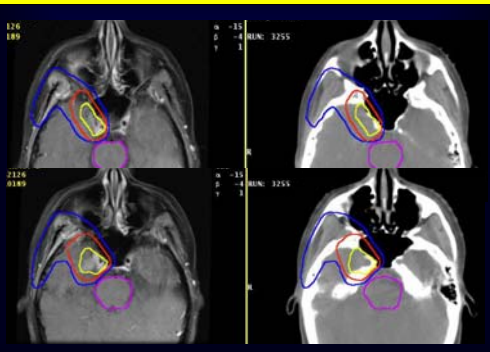

MR Fusion for NPC Target Delineation

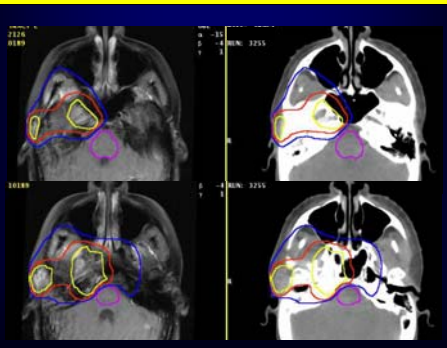

MR Fusion for NPC Target Delineation

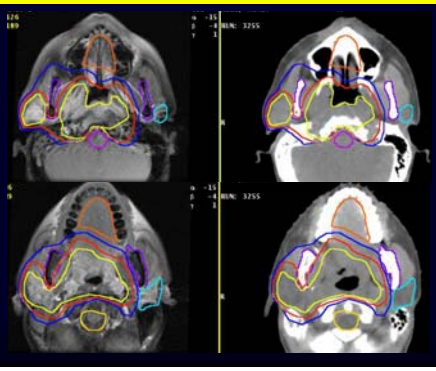

Target Delineation of Critical Structures

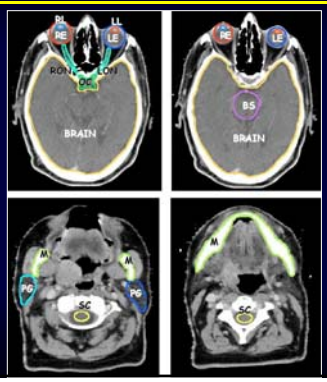

IMRT is "quid pro quo"

"something for something"

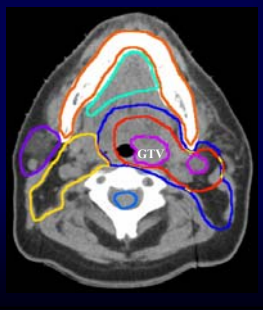

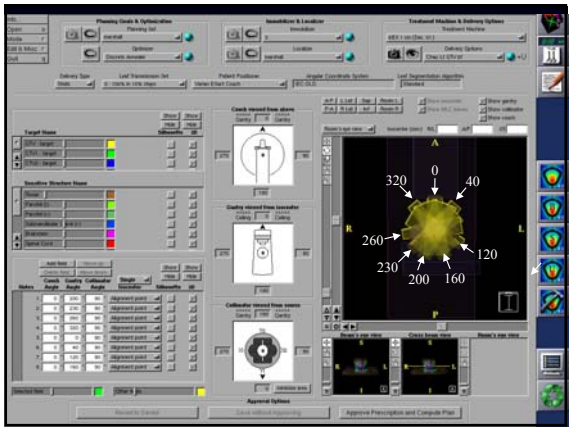

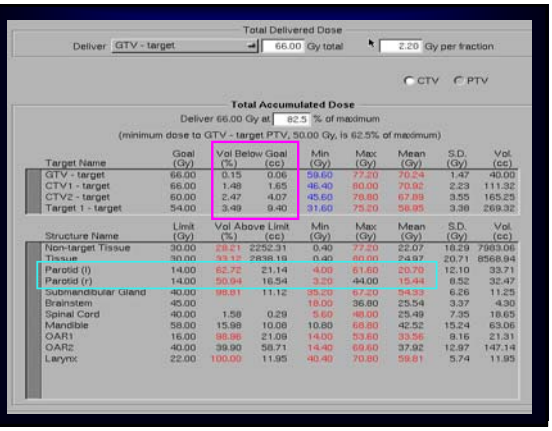

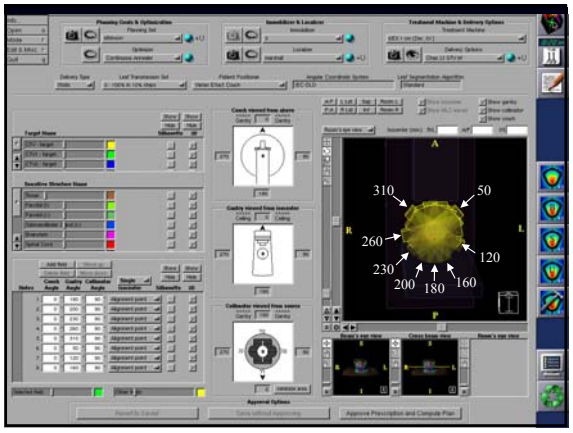

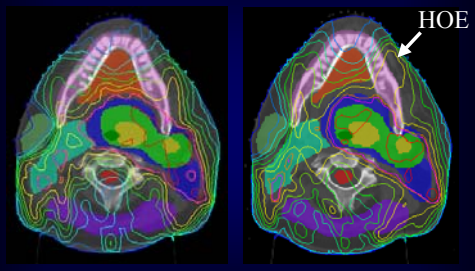

After Before

More Efficient??

- Class Solution
- Sharing Experience

www.imrttarget.org

Outline

- Treatment and QA Techniques
- Target Determination and Delineation
- Clinical Results
- Ongoing Study

Therapeutic Outcome of Oropharyngeal Carcinoma

Washington University Experience (1970-1999)

	Patient No.	Median F/U	2yr LC	2yr DFS
Def. CRT	153	3.5 yr (1.6-17.7)	68.3%	58.4%
Def. IMRT	12	2 yr (1-3)	87.5%	79.5%
Post-op CRT	142	3.9 yr (1.3-19.8)	75.7%	73.5%
Post-op IMRT	14	2.2 yr (1-3.2)	100%	92.5%

Chao et al. Radiotherapy & Oncology. 2001

Therapeutic Outcome of Oropharyngeal Carcinoma

Washington University Experience (1970-1999)

	Def. CRT (n=153)	Def. IMRT (n=12)	Post-op CRT (n=142)	Post-op IMRT (n=14)
Acute Grade 3-4 mucositis	25%	42% (P=0.134)	20%	21% (NS)
Late Grade 2-3 xerostomia (12m post-RT)	84%	30% (P<0.001)	77%	17% (P<0.001)

Chao et al. Radiotherapy & Oncology, 2001

Therapeutic Outcomes of Published Head and Neck IMRT Series

Author	IMRT Planning	N	Subsite	LC (%)	LRC (%)	OS (%)
Butler	Inverse planning	20	Multiple	N/A	85*	N/A
Dawson	Forward planning	58	Multiple	N/A	79 (2-y) 75 (5-y)	N/A
Lee	Inverse and forward	67	NPC	97 (4-y)	98 (4-y)	88 (4-y)
Chao	Inverse planning	126	Multiple	92 (3-y)	83 (3-y)	85% (3-y)

Patterns of Failure

Materials and Methods

Chao et al. IJROBP 2003

- From 2/97 to 12/00
- 126 head and neck patients (96 male, 30 female)
- Median age 56 (range 13-84 years)
- 52 definitive, 74 postop
- 35 definitive IMRT patients received chemotherapy
- Median follow-up 29 months (range 19-62)

Materials and Methods

- Primary site
  - Oropharynx 63
  - Oral cavity 15
  - NPX 12
  - Para. &nasal cav. 9
  - Unknown primary 9
  - Larynx 7
  - HPX 8
  - Other sites 3
- Def IMRT
  - 72.64±4.83 Gy to CTV1
  - 64.34±5.15 Gy to CTV2
- Postop IMRT
  - 68.53±4.71 Gy toCTV1
  - 60.95±5.33 Gy to CTV2

- T stages
  - T1 19
  - T2 33
  - T3 27
  - T4 38
- N stages
  - N0 30
  - N1 26
  - N2 61
  - N3 9
- AJCC staging
  - Stage I 5
  - Stage II 8
  - Stage III 26
  - Stage IV 78

Head and Neck IMRT-Results

	Overall	Def. IMRT	Postop IMRT	P value
2-year LRCR	86	80	90	p=0.36
2 year ult. LRCR	90	85	94	p=0.42
2-year OS	87	85	88	p=0.58

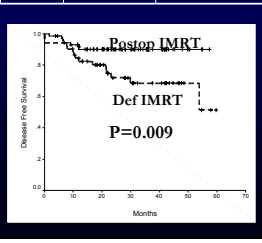

Geographic Detail of LR Failures

No.	Tumor Site	T	N	AJCC	Aim	Site of Failure	Location	Time to rec. (months)
1	L. Tonsil	4	2A	IV	Def	L. Tonsil	CTV1	11
2	R. PS	4	1	IV	Def	R. Level II LN	CTV1	17
3	BOT	4	2C	IV	Def	Bilateral neck	CTV1	10
4	L. Tonsil	4	3	IV	Def	R. Level II LN	CTV1	Pers.
5	R. Tonsil	3	2B	IV	Def	R. Tonsil	CTV1	10
6	L. Tonsil	2	2A	IV	Def	L. Tonsil	CTV1	Pers.
7	L. RMT	3	0	III	Def	L.RMT	CTV1	Pers.
8	NPX	3	3	IV	Def	Lower neck	Lower neck	12
9	L. Tongue	4	1	IV	Def	L. Tongue, neck	CTV1	12
10	Tonsil	2	2A	IV	Def	Lower neck	Lower neck	10
11	R. Tongue	2	2	IV	Postop	R. Level III LN	Lower neck	9
12	L. PS	3	0	IV	Postop	L. Level II LN	CTV2	6
13	L. BOT	3	2C	IV	Postop	R. Level IB LN	CTV2	2
14	L. larynx	3	2B	IV	Postop	L. Level II LN	CTV2	12
15	L. RMT	4	2B	IV	Postop	Thyroid, Level IA LN	CTV1 Lower neck	6
16	UP	X	2C	-	Postop	R. Neck	Post. Neck	7
17	L. Tongue	2	0	II	Postop	L. level III/IV LN	Lower neck	8

Chao et al. IJROBP 2003

Pre-RT MRI

Example 1: FC

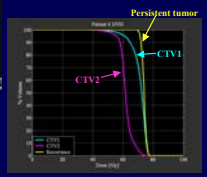

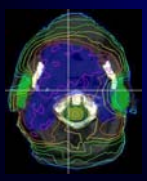

Chao et al. IJROBP 2003

Post-RT MRI

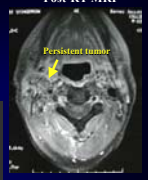

What Have We Learned?

- We observed no parotid or dermal failure.
- Satisfactory local-regional control in CTV2.
- Local failure predominantly within high dose regions
- Need to discern radioresistant subpopulation within CTV1

Outline

- Treatment and QA Techniques
- Target Determination and Delineation
- Clinical Results
- **Ongoing Study**

Biological Modifiers

Increase Volume
Decrease Volume

Dose Escalation
Dose Reduction

Refine Target Volume
Bigger or Smaller?

Marginal Failure or In-field Failure?

Marginal Failure

↓

Better Target Delineation

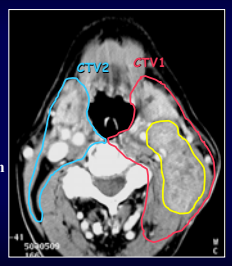

N- N+

In-field Failure

↓

Biological Causes

CT-FDG PET Imaging Co-registration for IMRT Target Delineation

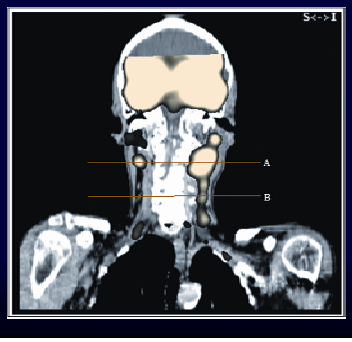

CT-FDG PET Imaging Co-registration for IMRT Target Delineation

A

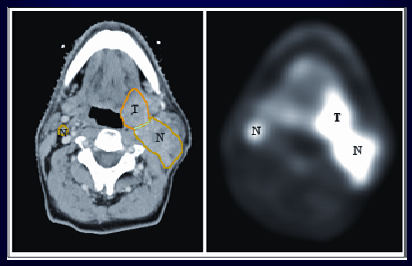

Marginal Failure or In-field Failure?

Marginal Failure

↓

Better Target Delineation

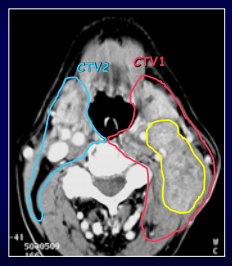

N- N+

In-field Failure

↓

Biological Causes

Imaging Targets of Tumor Geno- and Pheno-type

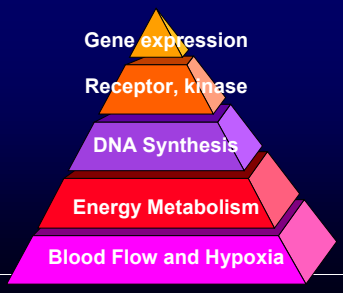

Tumor Hypoxia Contributes to Local Failure?

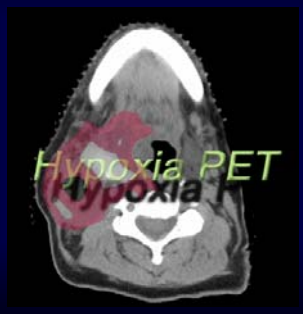

Delineation of Hypoxic GTV by ^{60}Cu-ATSM

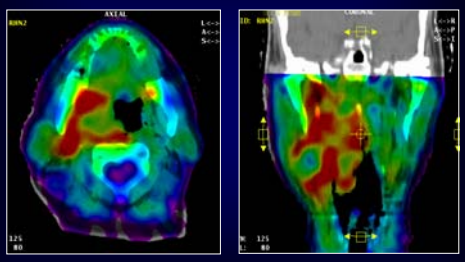

Chao, IJROBP 2001; 49(4): 1171-1182

A Target Coverage Scoring Function for IMRT Planning

-Based on the Probability of Gross Disease, Microscopic Tumor Extension and Lymph Node Metastasis

K.S. Clifford Chao, M.D.[1]
Angel I. Blanco, M.D. [2]
James F. Dempsey, Ph.D.[3]

[1]M.D. Anderson Cancer Center
[2]Washington University Medical School
[3]University of Florida

Problem (Example 1)

Lack of Spatial Information in DVH-based IMRT Optimization Algorithms

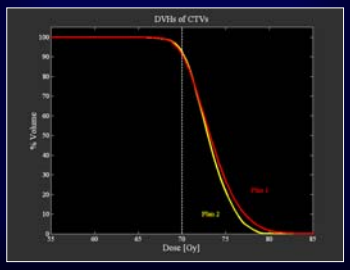

Plan 1

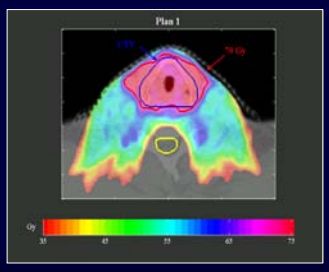

Plan 2

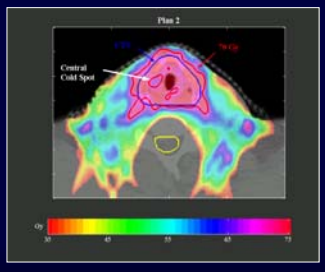

A Score Function to Discriminate Probability of Microscopic Extension from Gross Tumor & Lymph Node Metastasis for Voxels within CTV

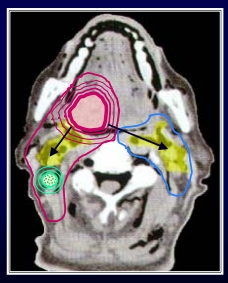

Probability of Tumor Extension vs. Distance

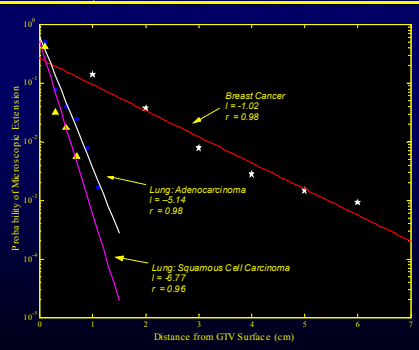

Probability of Nodal Metastasis vs. Distance in H&N Cancers

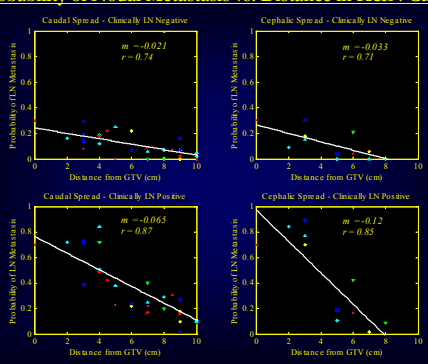

Score Function of Gross Disease, Microscopic Extension, and Nodal Metastasis

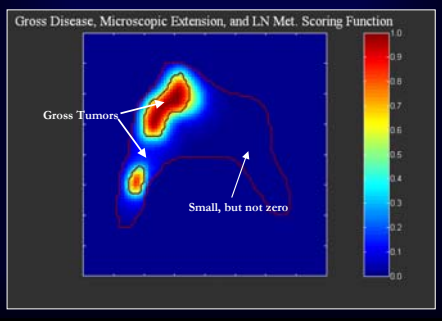

Problem (Example 2)

Lack of Spatial Information in DVH-based Optimization Algorithms

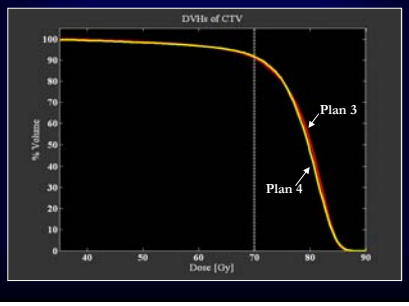

Plan 3

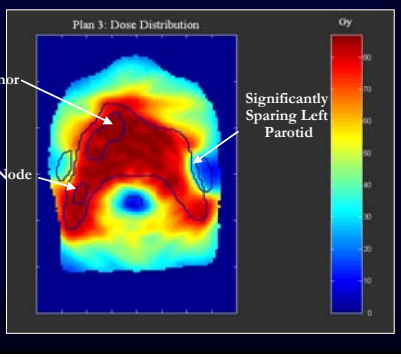

Plan 4

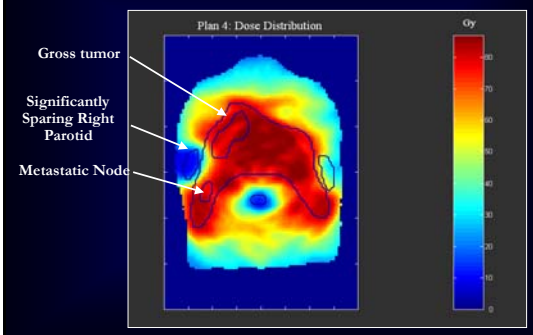

Solution #1

2-D Histograms for Dose-Volume-Tumor Extension/Metastasis Probability by Scoring Function

Plan 3

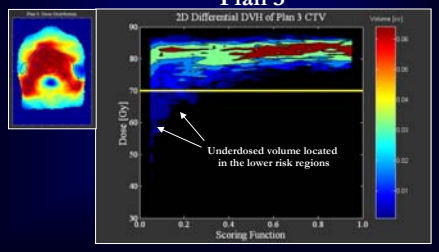

Solution #1

2-D Histograms for Dose-Volume-Tumor Extension/Metastasis Probability by Scoring Function

Plan 4

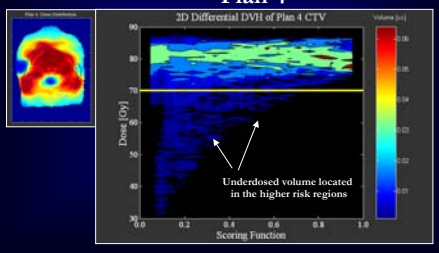

Solution #2

Relative Residual Tumor Burden: Voxel ($RRTB_{ijk}$) & Integral (IRRTB)

$$RRTB_{ijk} = \frac{SF^{ijk}{}_{Model}}{SF^{ijk}{}_{D_{Rx}}} = \rho_{ijk} \frac{e^{-\alpha D_{ijk} - \beta \frac{D_{ijk}^2}{nf}}}{e^{-\alpha D_{Rx} - \beta \frac{D_{Rx}^2}{nf}}} \qquad IRRTB = \frac{\sum_{ijk} SF^{ijk}{}_{Model}}{\sum_{ijk} SF^{ijk}{}_{D_{Rx}}}$$

Where $RRTB_{ijk}$ is the Relative Residual Tumor Burden of the i-j-k-th voxel, SF_{Model} is the surviving fraction of the model, $SF_{D_{Rx}}$ is the prescribed surviving fraction, α and β are radiosensitivity parameters ($\alpha = 0.29$ Gy^{-1} and $\beta = 0.029$ Gy^{-2}), D_{ijk} is the total plan dose of the i-j-k-th voxel, D_{Rx} is the total prescription dose, r_{ijk} is the scoring function value for the i-j-k-th voxel, and nf is the number of fractions.

Summary

- Treatment and QA Techniques
- Target Determination and Delineation
- Clinical Results
- Ongoing Study