USE OF ULTRASOUND IMAGING IN BREAST CANCER DIAGNOSIS & BIOPSY

Aaron Fenster
Kathleen JM Surry, Donal B Downey

Imaging Research Labs, Robarts Research Institute
Dept. of Medical Biophysics, University of Western Ontario
Dept. of Radiology, LHSC University Campus

Diagnosing Breast Cancer

- screening mammography, or palpable mass
- about 1 million biopsies/year in N America
  - 60 to 80% will be benign
- open surgical biopsy
- trend towards percutaneous image-guided breast biopsy

Breast Cancer diagnosis: US role

- Supplement mammography
- Independent examination
- Guiding biopsy
- Treatment planning for radiation therapy

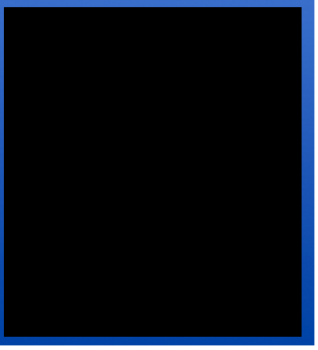

Role of US in diagnosis

- Women with dense breasts
- Women with fibrocystic disease
- When mammography alone cannot classify lesion
- Young women with masses
- Pregnant women with masses
- Women with implants
- Women who refuse mammography

Use of US in screening

Advantages

- Obtain tomographic images from almost any orientation
- Excellent for imaging cysts
- Determine if lesion is cyst or solid mass

Disadvantages

- Lacks sufficient spatial resolution
- Can't detect microcalcifications reliably (~30%)

Limitations of US in screening

- Difficulties in imaging deep lesion
- Operator & equipment factors - variability
- Image contrast between some lesions & surrounding breast tissue
- Microcalcification detection
- Cannot document how much tissue imaged

Breast lesion classification

- Image processing - analysis of image features
- Tissue characterization - analysis is US signals

Benign	Malignant
Ovoid/lobulated	Irregular shape
Linear margins	Poorly defined margin
Homogenous texture	Central shadowing
Parallel to skin	Distorted architecture
Distal enhancement	Calcifications
Dilated duct/mobile	Skin thickening

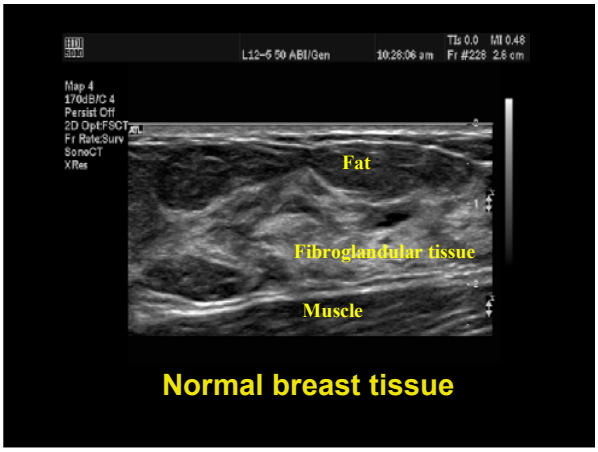

Normal breast tissue

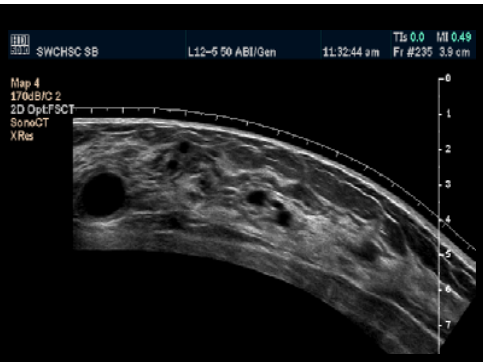

Multiple breast cysts
(panoramic SonoCT)

Malignant breast mass

Invasive Breast Carcinoma

Moon et al. Radiographics 2002

DCIS with micro-invasion

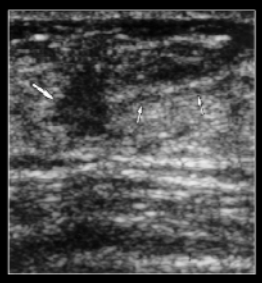

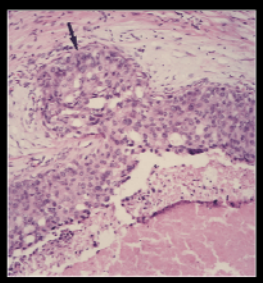

Moon et al. Radiographics 2002

Papillary DCIS with micro-invasion

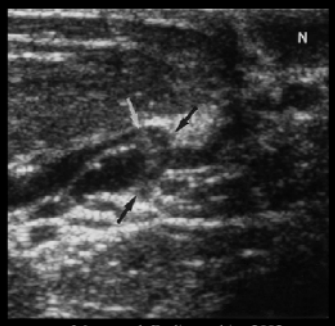

Moon et al Radiographics 2002

Solid DCIS

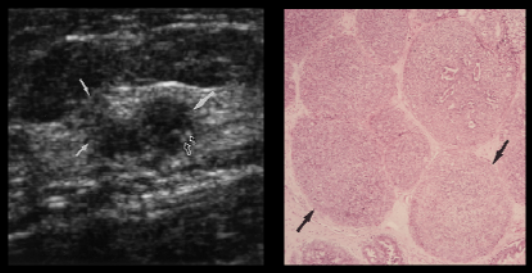

Moon et al. Radiographics 2002

Breast sonography adjunct to mammography

Stavros et al. Radiology 196:123-134, 1995

- Sensitivity: 98.4%
- Specificity: 67.8%
- Accuracy: 72.9%
- Positive predictive value: 38%
- Negative predicted value: 99.5%

Dense breasts

- Mammography alone - Sensitivity: ~50%
- Mammography/US - Sensitivity: increased by 42%

robarts IMAGING

3D ULTRASOUND

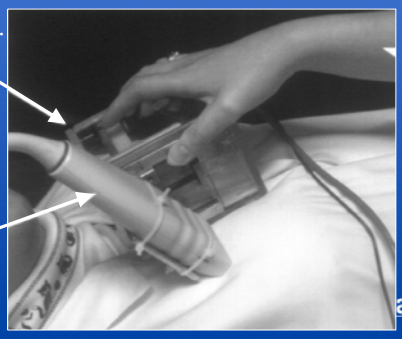

arts IMAGING

3-D ULTRASOUND

Breast Cysts

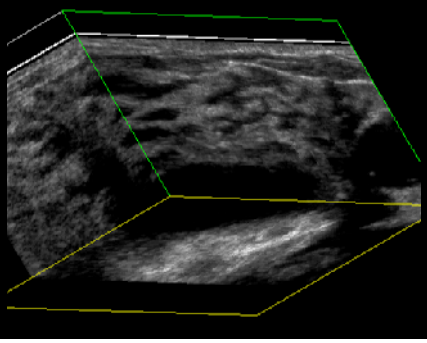

3D BREAST DUCT ECTASIA

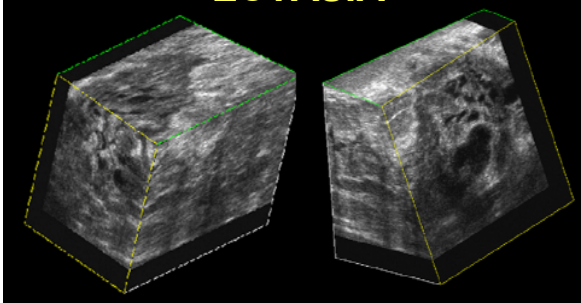

Doppler imaging - blood flow

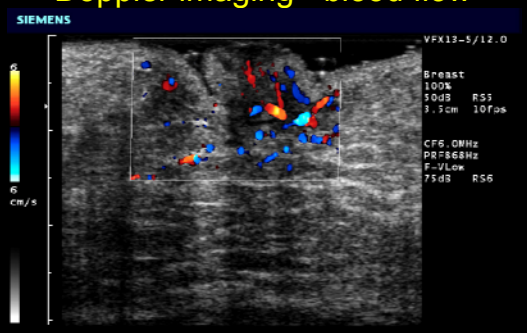

Small superficial vessels of the nipple

DUCTAL BREAST CARCINOMA

3D Colour Doppler

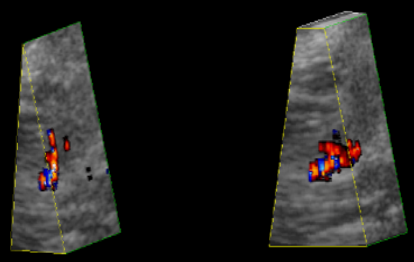

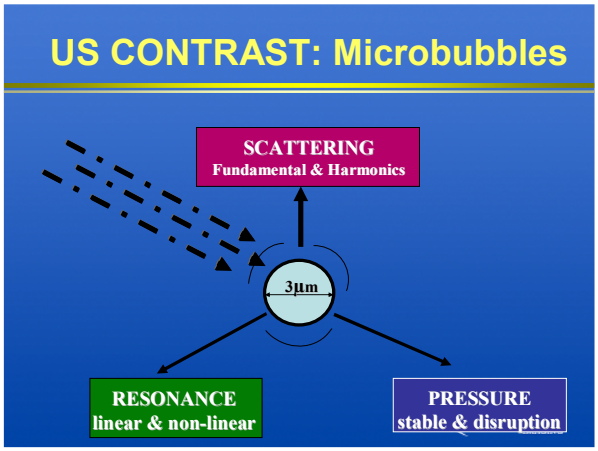
US CONTRAST: Microbubbles
SCATTERING
Fundamental & Harmonics
3µm
RESONANCE
linear & non-linear
PRESSURE
stable & disruption

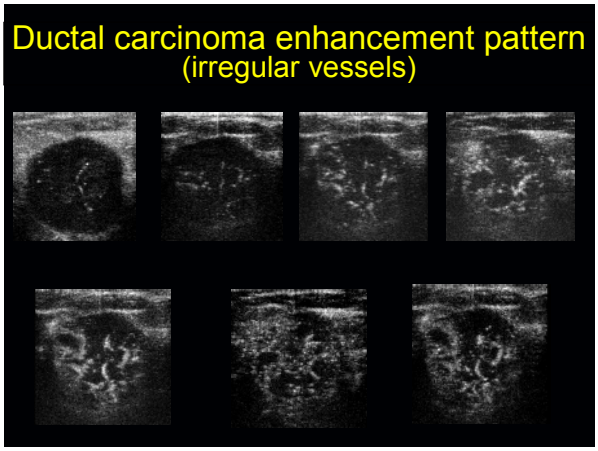
Ductal carcinoma enhancement pattern
(irregular vessels)

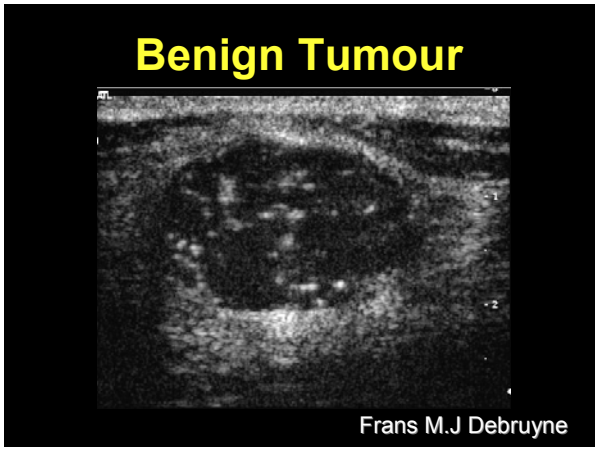
Benign Tumour
Frans M.J Debruyne

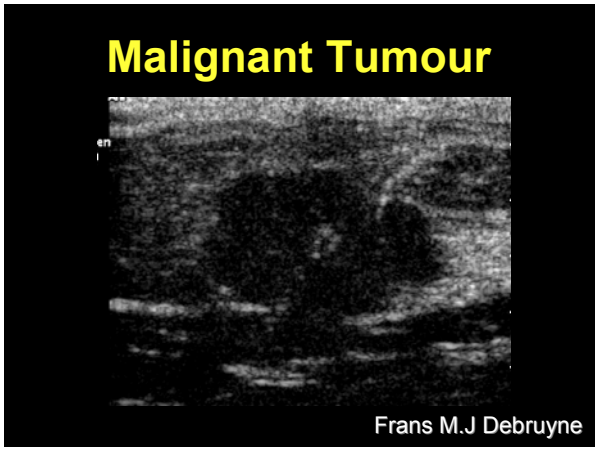
Malignant Tumour
Frans M.J Debruyne

Diagnosis by Biopsy

- Surgical biopsy
  - gold standard
  - all of suspicious mass is often removed
  - invasive procedure
  - very expensive
  - core needle breast biopsy is becoming accepted as an equal alternative

Needle Breast Biopsy

- Fine Needle Aspiration Cytology (FNAC)
  - 20 to 23 gauge needle
  - use a syringe to extract small samples
  - cytopathology
- Large Core Needle Biopsy (CNB)
  - 14 to 11 gauge needle
  - biopsy gun (also vacuum-assisted)
  - histopathology
  - false negative rate of 2%

Image Guided Breast Biopsy

- Stereotactic mammography guided
  - prone or upright
  - obvious continuation from screening
  - 3D information, but not real-time
- MRI-guided
  - contrast enhanced MRI is very sensitive
  - emerging application; expensive
- Free-hand US-guided
  - gaining popularity
  - 2D information, in real-time
  - requires expertise

Stereotactic Mammography

- X-ray mammography
- Stereotactic pairs, obtained 30° apart
- Geometry gives 3D information
- Procedural images:
  - identify target
  - confirm needle trajectory
  - confirm edema in target area

Free-Hand US-Guided Biopsy

- Real-time 2D image guidance
- Requires expert radiologist
- Breast is constrained with hand-held transducer
- Needle trajectory is not constrained
  - misinterpretation possible
  - danger to patient and clinician

robarts IMAGING

US Images pre Breast Biopsy

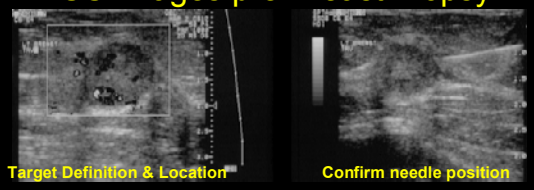

Post Biopsy images

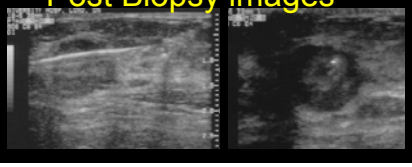

3D Ultrasound Imaging

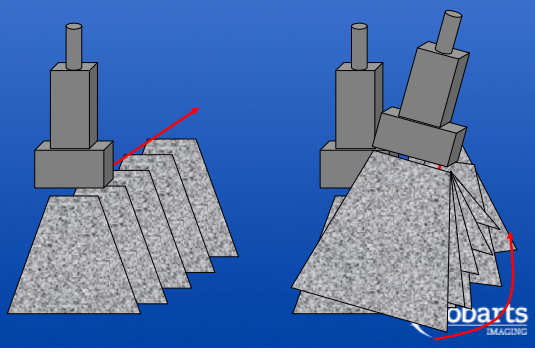

robarts IMAGING

Research Objectives:

3D US Guided Breast Biopsy (USB)

- Attributes combined from:
  - stereotactic mammography
    - breast fixation
    - controlled needle trajectory
  - 2D ultrasound
    - real-time imaging for guidance
  - 3D ultrasound
    - near real-time 3D imaging for targeting, guidance and verification

robarts IMAGING

3D USB System



Transducer

Sweep Direction

Needle Guide
&
Guide Movers

Insertion Direction

robarts IMAGING

3D US-Guided Biopsy Protocol

- Identify target in 3D US image
- Transducer moved over target
- Needle guide moved to be in-line with target
- Needle is inserted under real-time 2D US
- Biopsy is performed
- 3D scan acquired to confirm hit
- Needle removed
- Another target point identified

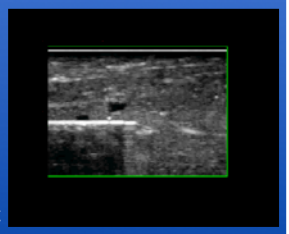

robarts IMAGING

Evaluation

1. Needle placement in tissue mimic
   - establish positioning accuracy
2. Biopsy of 'lesions' in tissue mimic
   - relate target size to biopsy success rates
3. Biopsy of 'lesions' in animal tissue
   - compare with performance of expert free-hand US guidance

robarts IMAGING

1. Needle Placement Accuracy

- Beads in agar
- Needle tip at target
- 3D US record
- Tip to target distance
- 3D analysis of accuracy

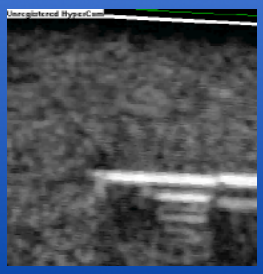

➔ 0.85 mm targeting accuracy, with 95% confidence

WL Smith et al, JUMB, 27(8):1025-1034, 2001.

robarts IMAGING

2. Biopsy Accuracy

- White PVA-C 'tissue'
- Green PVA-C 'lesions'
  - 1.6 to 16 mm diameter
- Scored as hit or miss
- Biopsy of 'lesions' in tissue mimic
  - relate target size to biopsy success rates

KJM Surry et al, Med Im Analysis, 6(3):301-312, 2002.

robarts IMAGING

2. Biopsy Accuracy

- Post-fire 3D US showed positioning accuracy

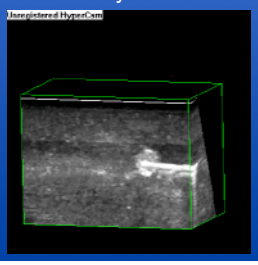

Biopsy Specimens

robarts IMAGING

2. Biopsy Accuracy

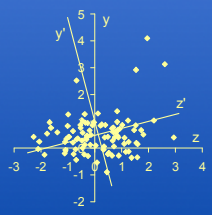

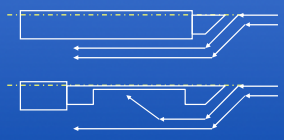

➔0.53 mm bias in placement

➔sampling notch direction bias

robarts IMAGING

2. Biopsy Accuracy

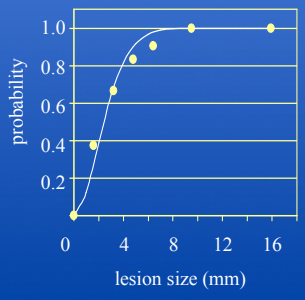

Lesion Size (mm)	Confidence 95%	Confidence 99%
0.5	180	309
1.0	45	78
2.0	12	20
3.0	5	9
5.0	2	4
10.0	1	1

robarts IMAGING

3. Comparison to Clinical Standard

Designed to show equivalence between the new method and a clinical standard

- 55 biopsies by each of:
  - 3 radiologists, free-hand
  - 1 team of scientists, 3D US apparatus

KJM Surry et al, Med Im Analysis, 6(3):301-312, 2002.
WL Smith et al, Acad Radiol 9:541-550, 2002.

3. Comparison to Clinical Standard

- 12 PVA-C lesions per chicken fillet
- 3.2 mm diameter

3. Comparison to Clinical Standard

2D technique

3D technique

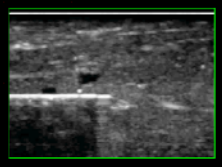

3. Results

- Radiologists
  - 94.5% success
- 3D US system
  - 96% success

➔Equivalence has been proven, within 5%, with 95% confidence

robarts IMAGING

Summary of Results

1. Needle placement at a target
   - fundamental to placement accuracy
2. Biopsy of a target
   - add needle firing and sample collection
3. Comparison with a standard
   - relate performance to current practice

We can sample a 3.2 mm lesion at a 96% success rate.

robarts IMAGING

Dual Modality Imaging

- for targets which are:
  - unequivocal in both modalities; or
  - clear in mammography, and obscure but visible in ultrasound

robarts IMAGING

Advantages of Dual Modality

- Information fusion for diagnosis confirmation
  - most relevant at the screening stage
- Pre-procedural target identification
  - x-ray mammography
- Real time 2D imaging and near real time 3D imaging for targeting and guidance
  - ultrasound

robarts IMAGING

Visibility and Detection

- screening mammography (XM)
- often followed with ultrasound (US)

Modality	Sensitivity		
	all	fatty	dense
XM	78%	98%	64%
US	75%	<66%	75%
both together	97%	n/a	97%

n(all) = 11,130; n(cancers) = 145
compiled from Kolb et al, Radiology, 225:165-175, 2002.

robarts IMAGING

Dual Modality Biopsy Protocol

1. Acquire SM image pair of target region

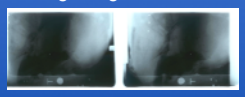

2. Identify target in both views

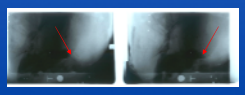

3. Calculate 3D position of target



4. Transform target to 3D US image space



Dual Modality Biopsy Protocol

5. 3D US image of target region

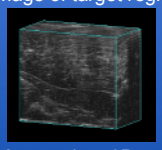

6. Place SM target into 3D US image

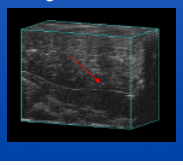

7. Align transducer and needle guide with target
8. Insert needle & acquire biopsy sample
9. Acquire 3D US image & confirm biopsy in 3D US
10. Remove needle

Dual Modality Biopsy: 2D SM / 3D US

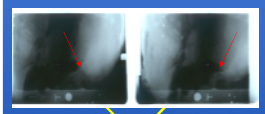

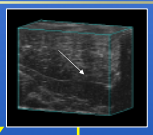

geometry

3DSM to 3DUS transform

vertical offset in 3DUS

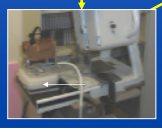

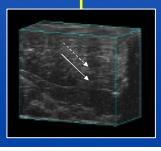

The Challenge

- stereotactic mammography guided biopsy inserts the needle vertically
- the needle has a 19 mm sampling notch
- our system: horizontal insertion

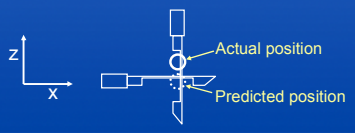

Registration of US and 3D SM

- dual modality phantom
- pin tips were used for fiducials and targets
  - 15 points were used to define the registration
  - 15 points were used to evaluate the registration
- linear least squares (translation + rotation)
  - vtkLandmarkTransform



robarts IMAGING

Pin Phantom Registered



robarts IMAGING

Registration: Results

- Fiducial Registration Error, FRE = 0.86 mm
- Target Registration Error, TRE = 0.98 mm

	x	y	z
FRE	0.31	0.25	0.76
TRE	0.35	0.35	0.84

TRE_z may be limited by the geometry

robarts IMAGING

Beads in Agar Phantom

3D Ultrasound →



Stereo-mammography

↓

Agar and Bead Phantom



- TRE = 0.94 mm
  - TRE_x = 0.24 mm
  - TRE_y = 0.30 mm
  - TRE_z = 0.86 mm

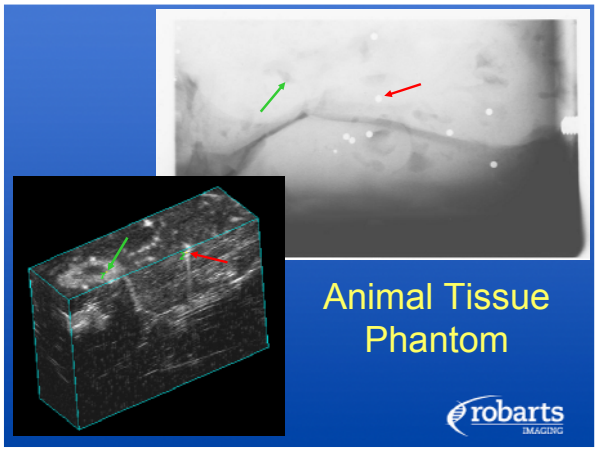

Animal Tissue Phantom

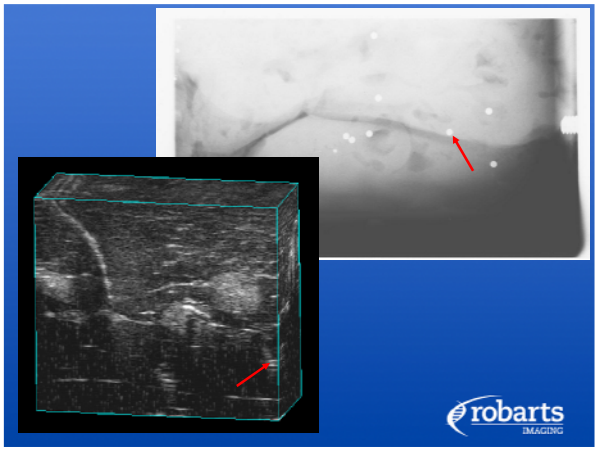

3D USB Evaluation: Conclusions

- Methods were developed for evaluating and assessing the accuracy of a biopsy apparatus
- 3.2 mm lesions were sampled with a 96% success rate
- We have demonstrated that the 3D US guided biopsy procedure is equivalent to current clinical practice

Conclusions

- Attributes of Combined 3D US and Stereotactic Mammography System:
  - breast compression for stability and safety
  - dual modality imaging for target localisation
  - real-time US for needle guidance
  - 3D US for targeting and guidance
  - 3D US image record for biopsy verification

robarts IMAGING

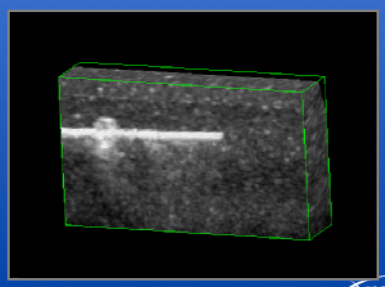

robarts IMAGING

Measurement Errors

A 2 mm measurement error on the films, leads to large errors in the z-direction

	x	y
either SM image	10 mm error in z	20 mm error in z
both SM images	20 mm error in z	35 mm error in z

robarts IMAGING

The Back Plate and Top Plate



Acknowledgements

- Dr. Aaron Fenster
- Dr. Donal Downey
- Dr. Ian Cunningham
- Greg Mills
- Dr. Wendy Smith
- Lori Gardy
- Kirk Bevan
- Sheila MacDonald
- Laura Campbell
- Dr. Mary Hassard
- Hristo Nikolov
- Dr. Chris Ellis
- CIHR Doctoral Fellowship

2. Biopsy Accuracy

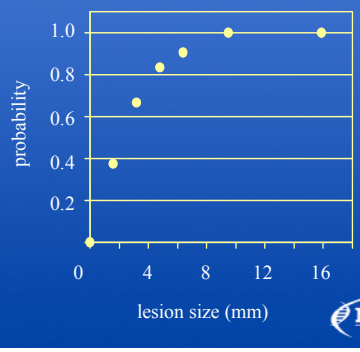

Ductal Carcinoma in situ

- Non-palpable, early stage cancer
- Under-diagnosis rate is 11 to 36%
- Hypothesis:
  - Dual modality will clarify biopsy target areas
  - Real-time imaging will ensure accurate guidance
- Proposal:
  - μ-calcs in SM can identify where to look in 3D US
  - architectural distortions and duct geometry in 3D US

Defining the Geometry

- What's known:
  - phantom geometry
  - distances between points on the phantom in the right and left images
- What's not known:
  - position of the source
    - height
    - horizontal position
    - angle from vertical
  - position of the film
    - height
    - horizontal position
    - rotation in the cassette
  - position of the phantom
    - orientation

robarts IMAGING

From 2D SM to 3D US

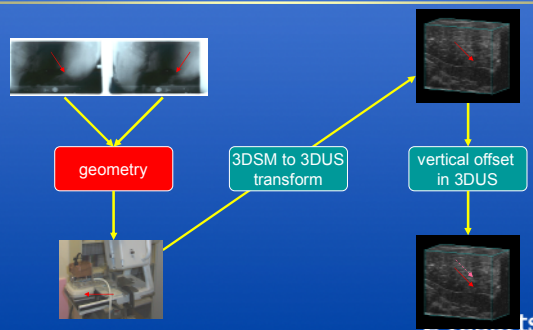

Defining the Geometry



Bead Grid Phantom

Defining the Geometry

- requires four points to define the geometry
  - reference point plus three others
- used 10 points to evaluate the relationship
  - accuracy of localising a point in 3D SM space
  - fiducial localisation error (FLE)
  - target localisation error (TLE)

robarts IMAGING

SM System Geometry

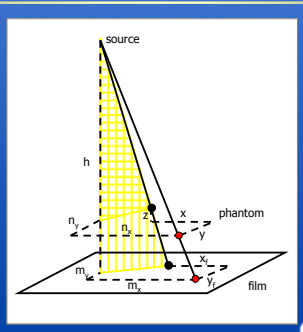

Defining the Geometry: Errors

- Target Localisation Error

$$TLE = \sqrt{\frac{1}{n}\sum_{n}(x_i - x_{di})^2 + (y_i - y_{di})^2 + (z_i - z_{di})^2}$$

- TLE = 1.36 mm
  - TLE_x = 0.48 mm
  - TLE_y = 0.36 mm
  - TLE_z = 1.23 mm

From 2D SM to 3D US

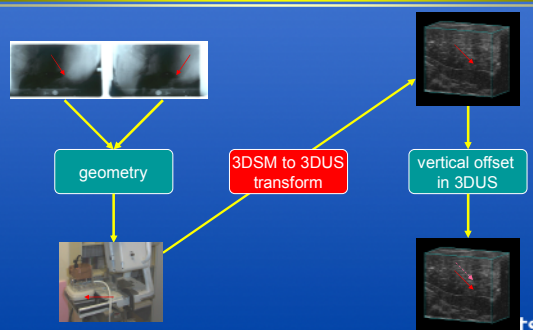

From 2D SM to 3D US

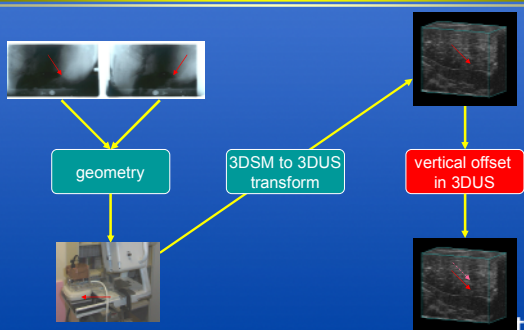

Future Work

- Test the SM-US guided biopsy procedure
  - needle targeting with SM guidance only
  - biopsy task when identification is an issue (cysts, solid and calcified masses, calcifications)
- Integrate the 3D US guidance system with digital stereotactic mammography
  - immediate identification of a target seen in SM by placing a marker in the 3D US image

robarts IMAGING

Towards Clinical Application

- Re-design for comfort
- Integration with digital SM imaging
- Real-time needle tracking (3D)
- Oblique insertion (away from chest)
- Automatic target identification and segmentation
- Biopsy planning

robarts IMAGING

3D US with SM Imaging

robarts IMAGING