Localization II: Volume Imaging Techniques and Accuracy for Brachytherapy Dosimetry

Jason Rownd, M.S.

Medical College of Wisconsin

Outline

- Imaging basics
- Simulation and Imaging
- Reconstruction and Planning
- Dosimetry and Evaluations



Volume Imaging-Pixels

- 2 dimensional image
- 2D grid of image elements
- smallest building block is pixel
- example
  - 50 cm field of view
  - 512x512 pixels
  - 0.98 mm x 0.98 mm
  - ~1 mm^2 / pixel



Volume Imaging-Voxels

- 3 dimensional image
- 3D grid of image elements
- smallest building block is voxel
- 1 mm x 1 mm x ???
- slice thickness
  - volume ‘slice’ information
- slice separation
  - center to center separation



Volume Imaging-Information

- slice thickness
  - partial volume
  - imaged object extends across multiple slices and fractions of slice
- slice separation
  - ideally separation = thickness
  - unintended gaps
  - lost information
- necessary information versus useful size
  - completely (or adequately) describe your original object with the volume scan information
  - remember that information is a storage issue

Volume Imaging-Machine limitations

- Planning assumes that equipment is correctly functioning
- Machine QA and limits
  - Commissioning and acceptance testing
    - task groups and published reports
  - geometric accuracy
  - anatomical accuracy
  - consistency
    - routine QA



Volume Imaging-Patient limitations

- patient
  - size
    - machine limits
    - image quality
  - applicator artifacts
  - other artifacts

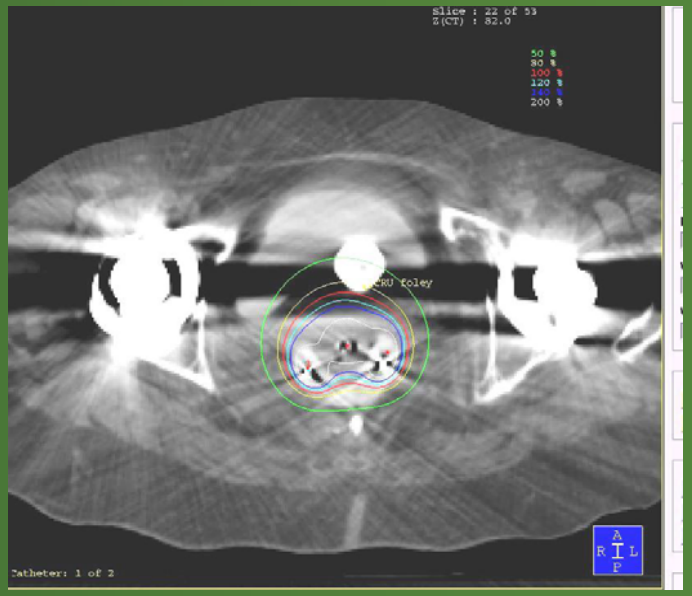

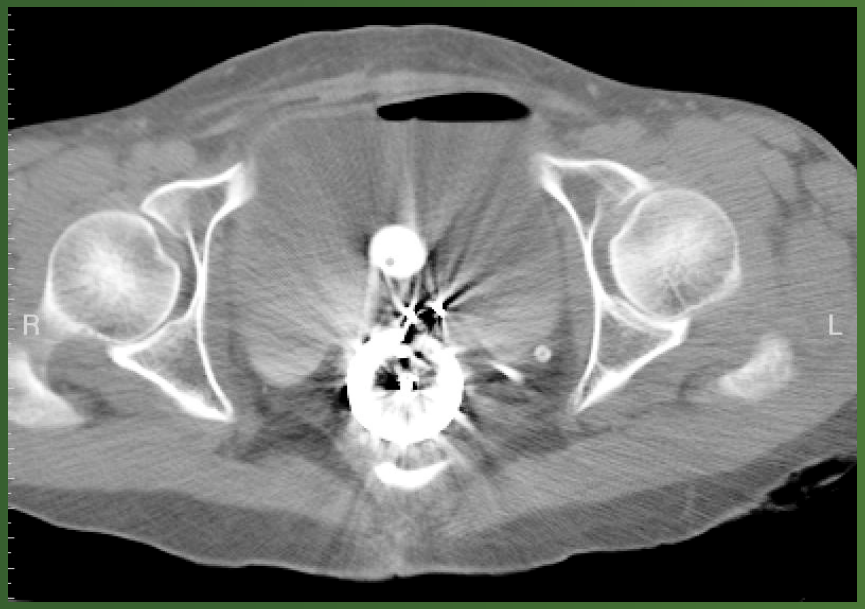

Volume Based Simulation and Planning

- Needed information
  - completely (or adequately) describe your original object with the volume scan information
- Applicator position
- Normal tissue locations
- Dwell positions
  - how well can you identify the actual treatment positions
- Treatment lengths

Radiographs and Volume Information

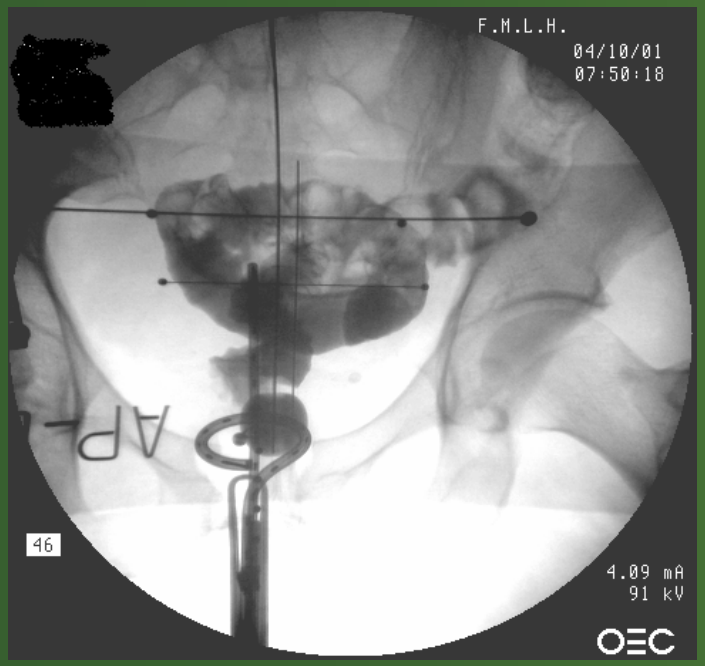

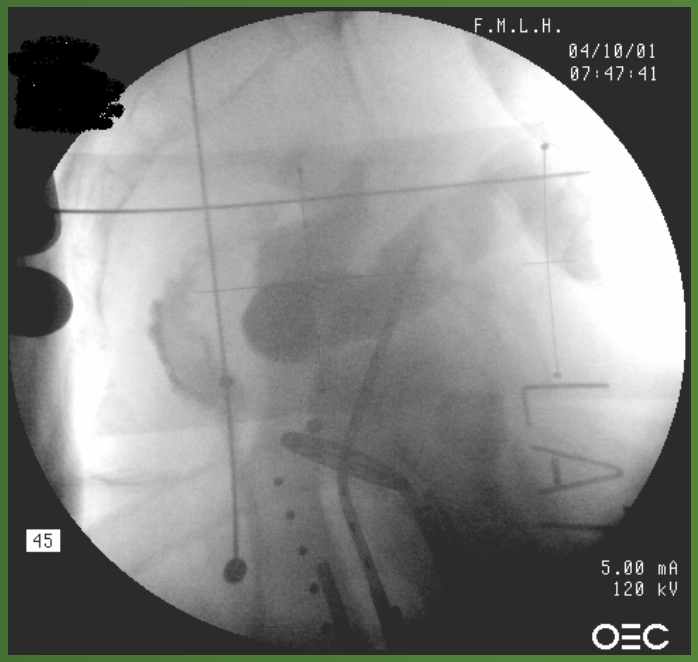

- AP/Lateral radiographs
- contrast determined normal tissues
- estimates

Volume Scans

- Axial slices
- contrast enhanced tissues
- less guess work
  - Foley bulb versus actual bladder doses
  - rectal-sigmoid doses

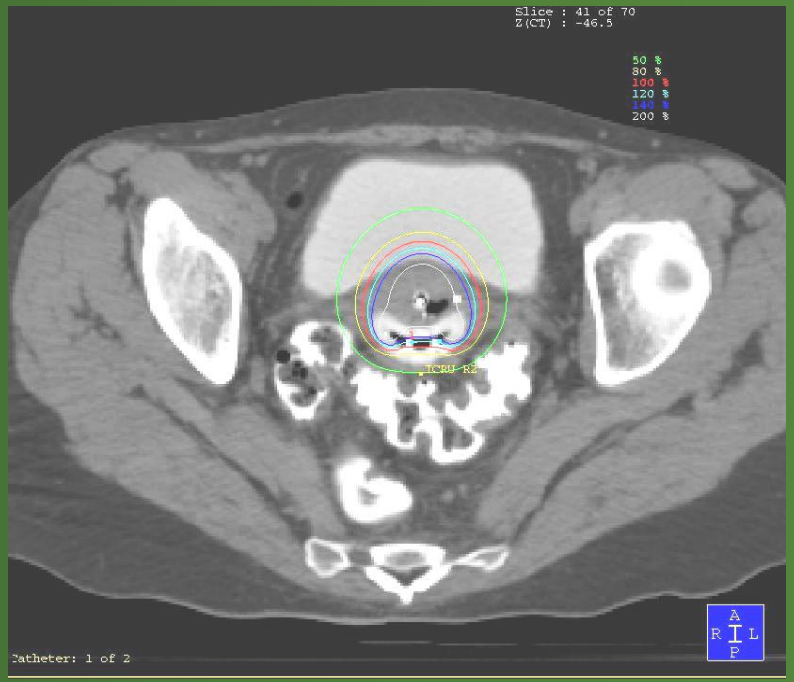

CT Images

- good geometry throughout
- sufficient information for many procedures
- common, CT-Simulators

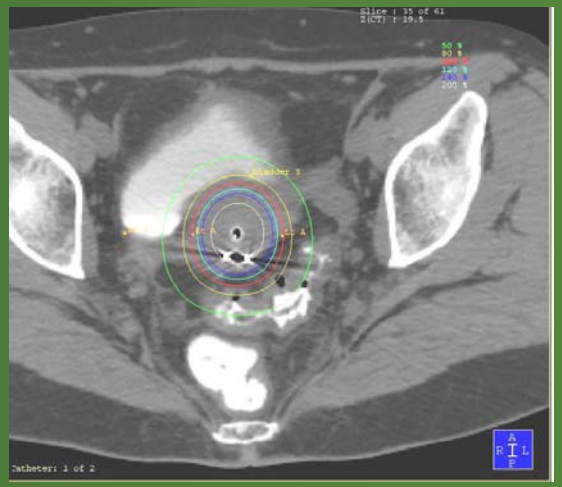

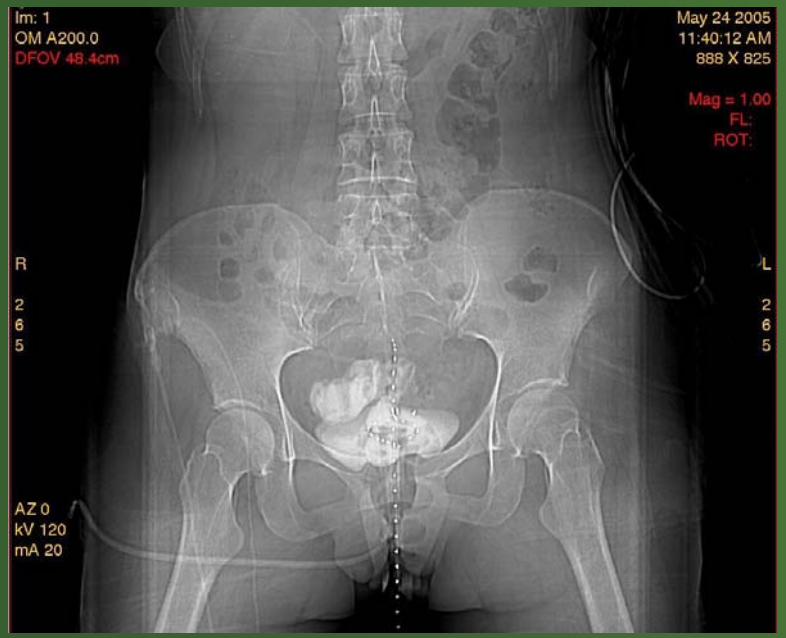

MR Images

- MRI
  - better tissue differentiation
  - more time consuming scans
  - diverse scanning ‘planes’
  - planning or image fusion with CT scans

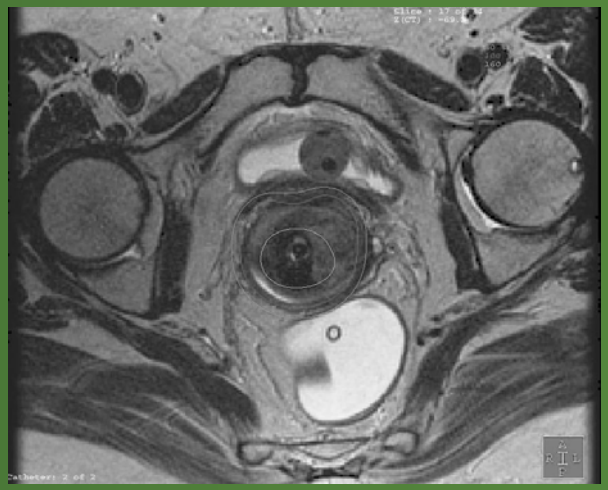

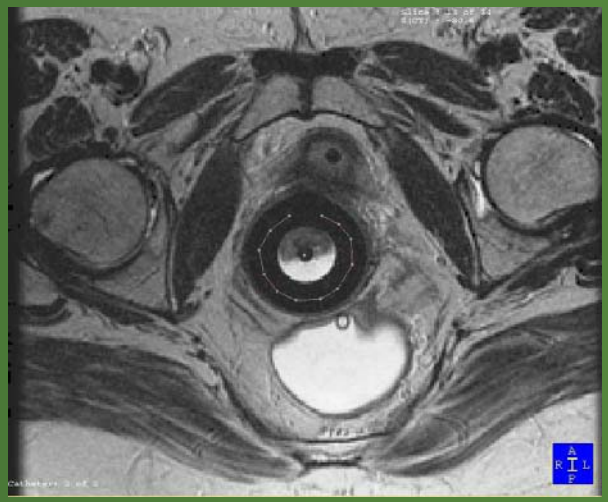

Compatible Applicators?

- Stainless steel applicators
  - Tandem and Ring
  - Vaginal cylinders
  - Needles
- Some artifacts are more difficult to handle
- It is possible to CT plan with metal applicators

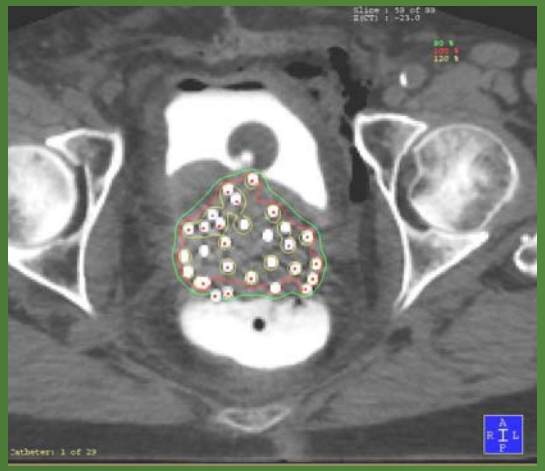

Compatible Applicators?

- Plastic or carbon fiber applicators
  - Tandem and Ring
  - Vaginal cylinders
  - Needles
- Some issues are more difficult to handle
  - x-ray markers easy
  - MRI compatible markers????



Simulation and Planning: GYN

- Initial CT scans
- AP Scout
- Lateral Scout

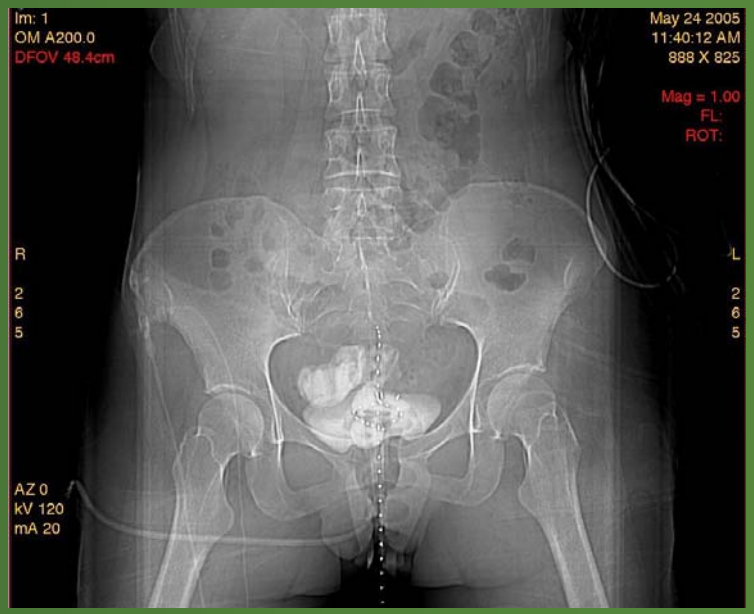

Simulation and Planning: GYN

- Axial slice review
- verify seed markers
- verify tandem insertion
- verify contrast and estimate anatomy concerns

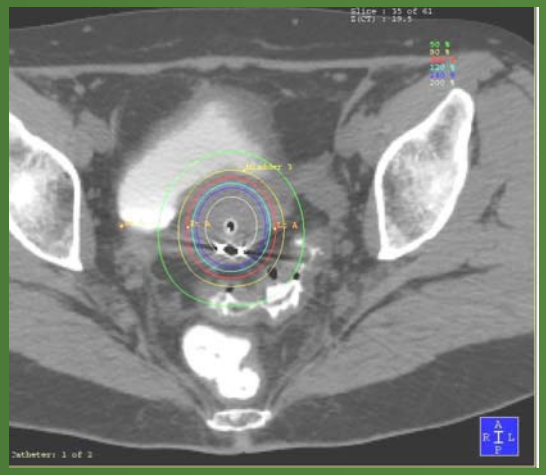

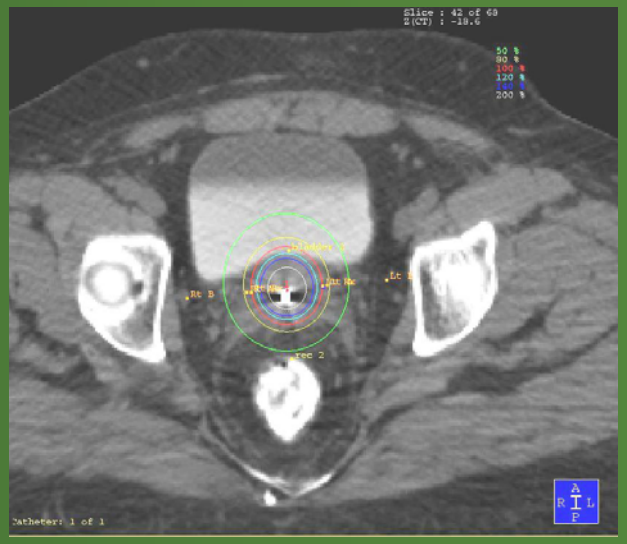

Simulation and Planning: GYN

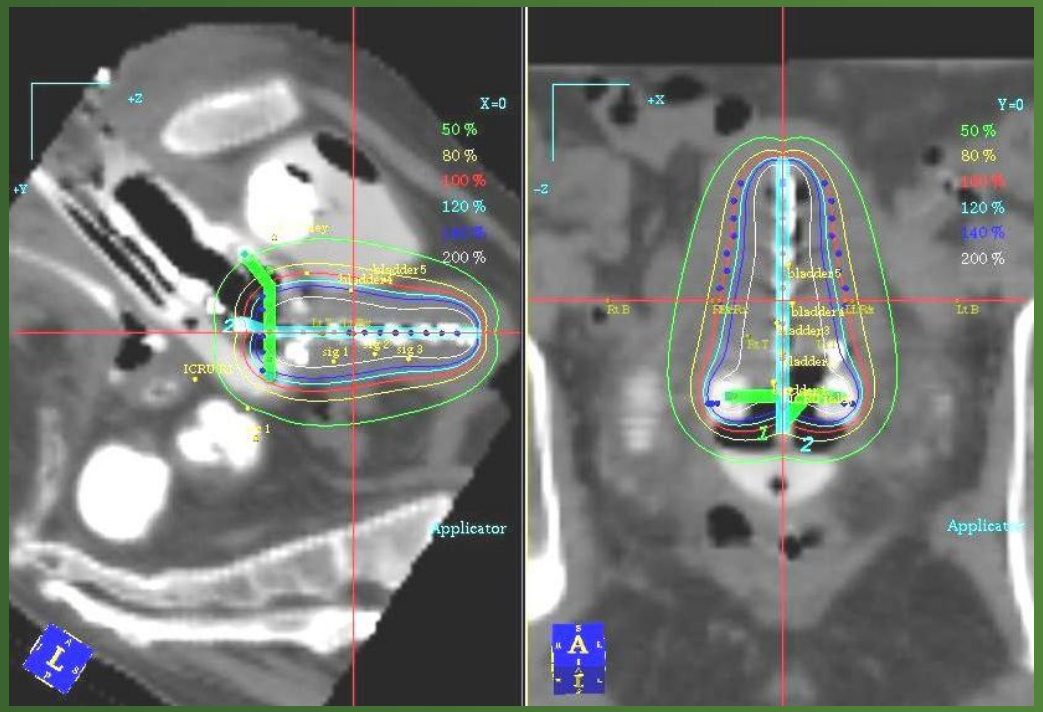

- Reconstructed views
- Source positions identified

Applicator Reconstruction

- Know what to expect
  - tandem and ring
  - ring is circular
- Unexpected reconstructed shape
  - unusual ring reconstruction
- Incorrect Dosimetry
- Incorrect Placement
  - i.e. correct geometry but inaccurate location

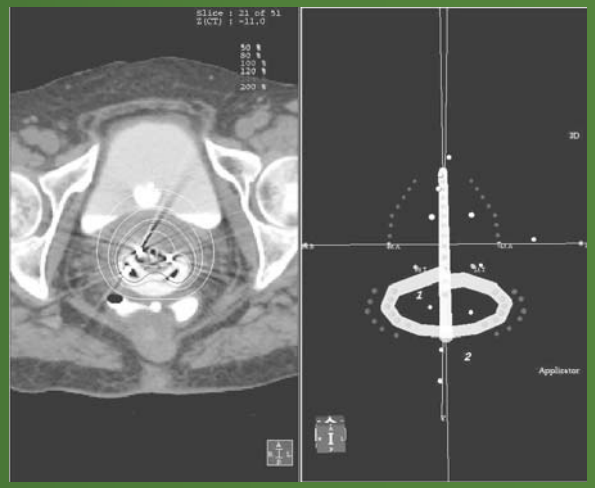

Dosimetry: GYN

- Typical tandem and ring plan

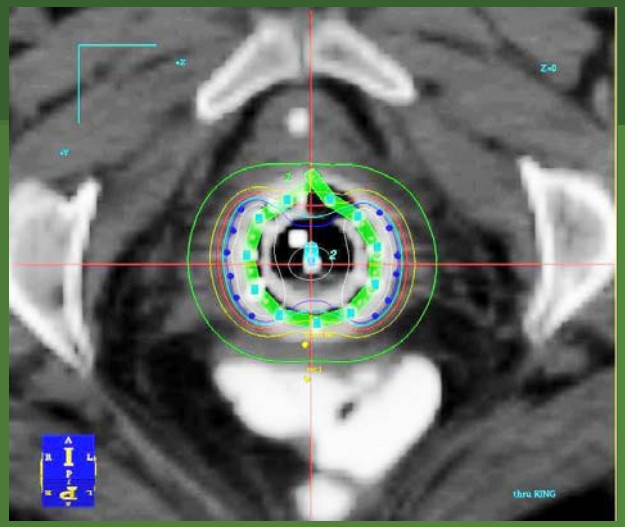

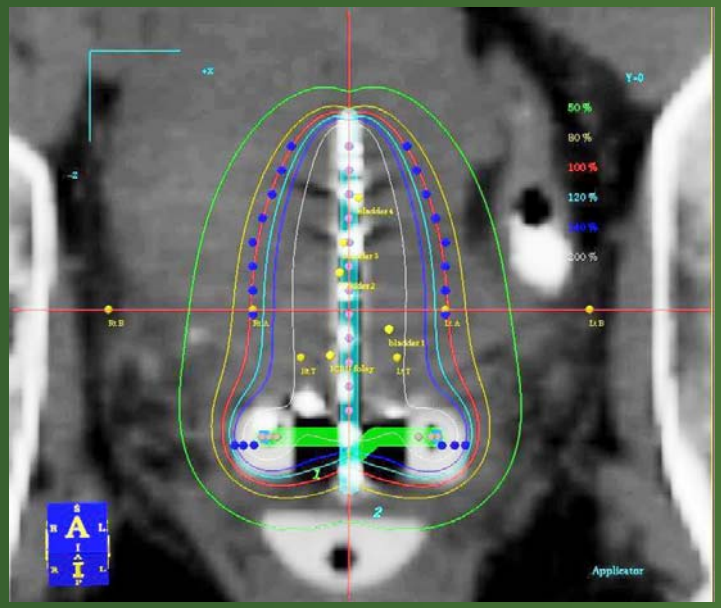

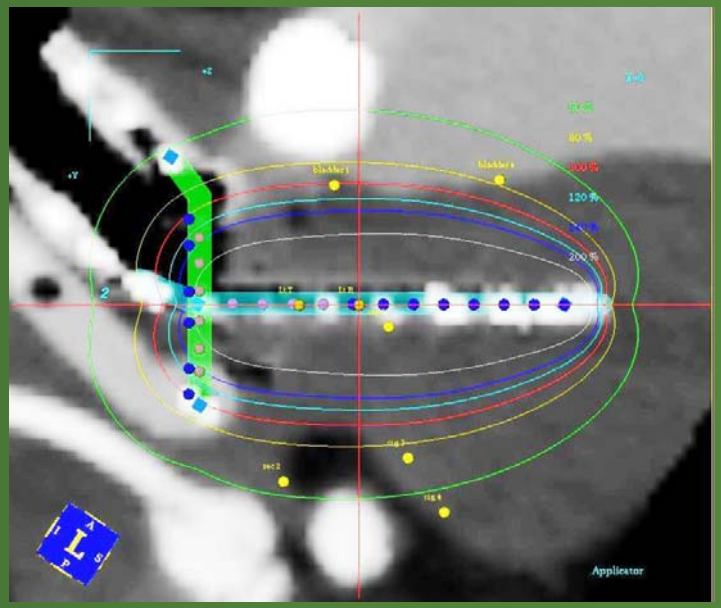

Dosimetry: GYN

- Vaginal cylinder plan
  - not often planned using CT images
  - increased use of CT-Sims

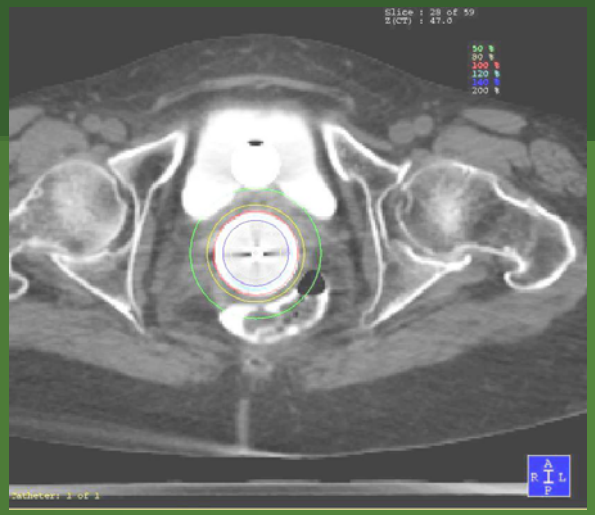

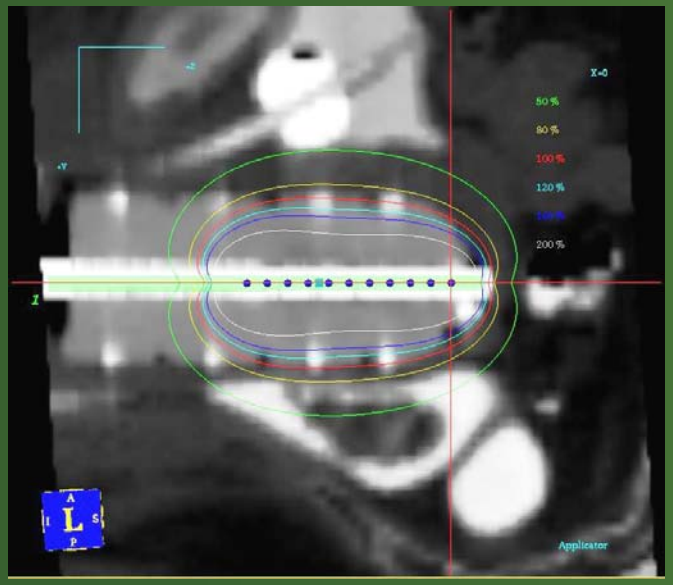

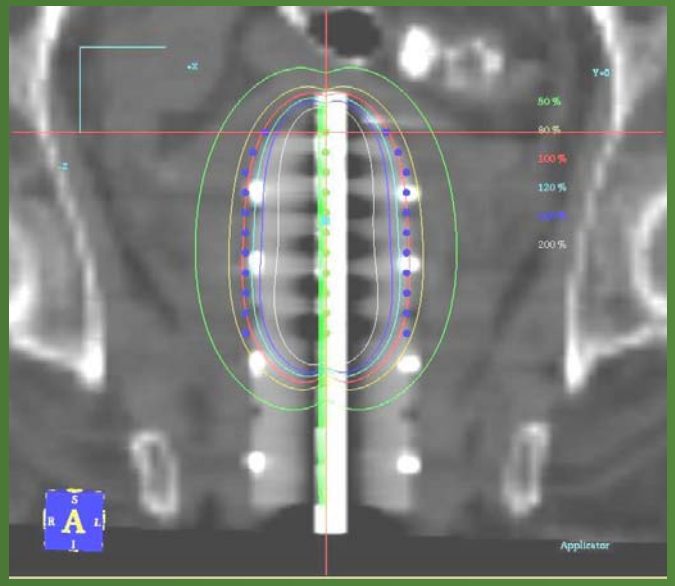

Dosimetry: GYN

- Typical tandem and cylinder plan
  - similar concerns for Point A prescriptions
  - simplified vaginal surface dosimetry but…
    - different treatment lengths
    - variable doses to different lengths
    - uniform axial dose
      - no tissue sparing

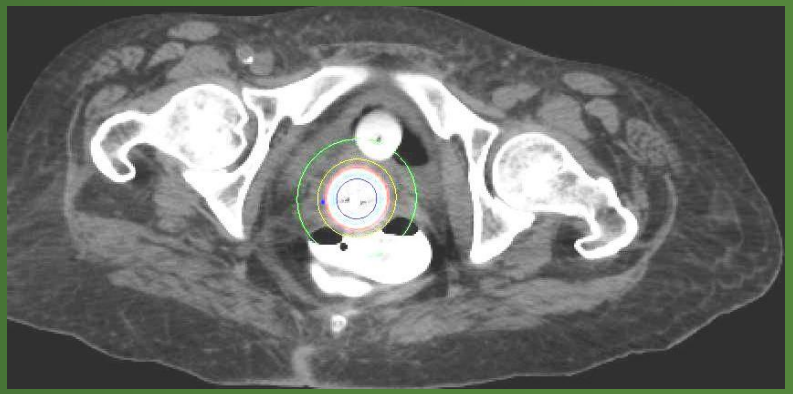

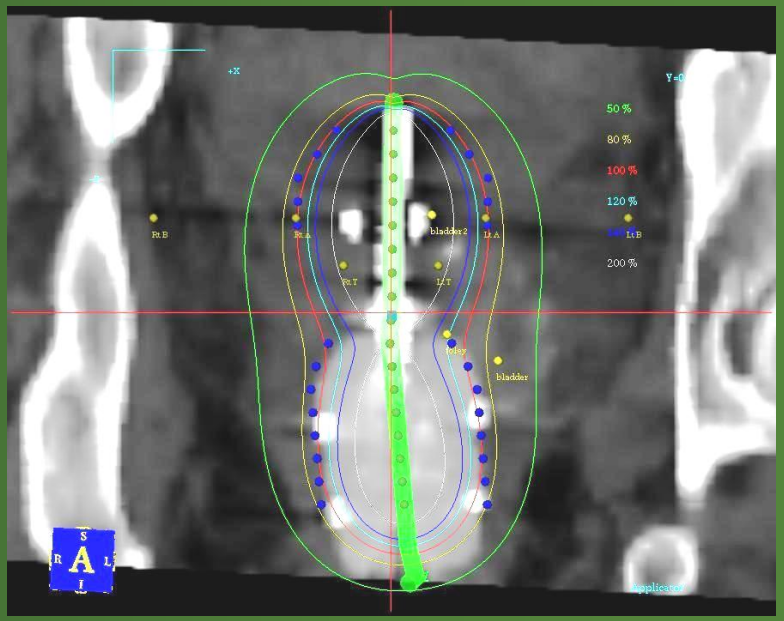

Simulation and Planning: Breast

- Radiographs and planning
- CT images and planning

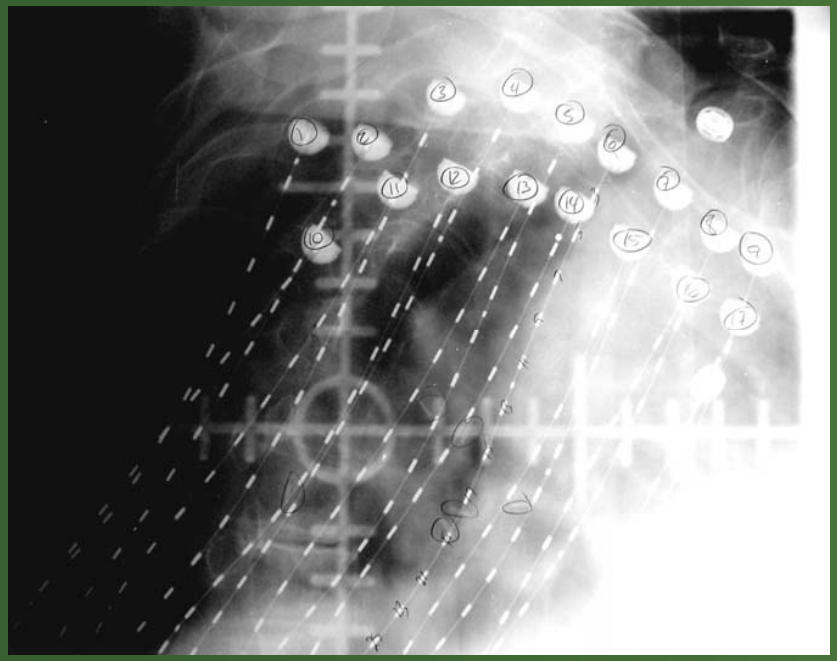

Simulation and Planning: Breast

- Catheter orientation in breast
  - medial to lateral placement is easier for the physician
  - head to toe is easier for reconstruction
  - compromise

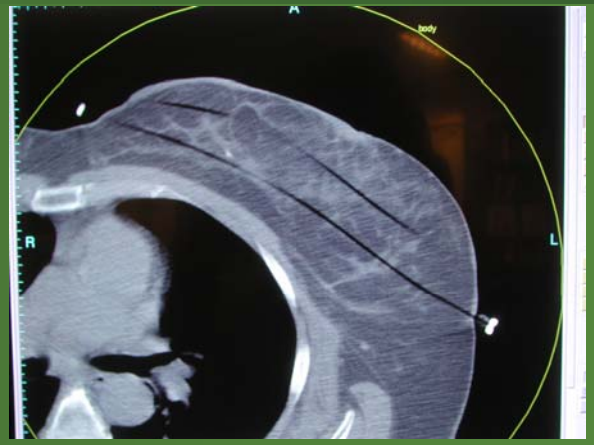

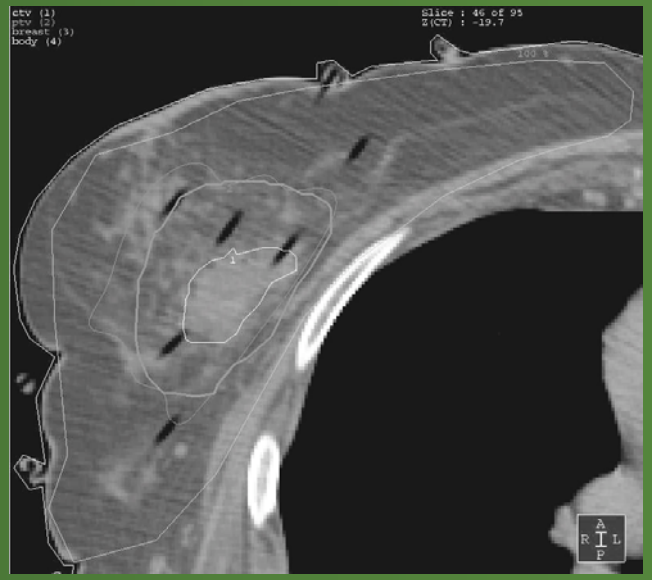

Dosimetry: Breast

- DVH of PTV
- Axial view showing dose uniformity (or lack)
- 3D view showing dose to the skin
- Make the best of your catheter placement

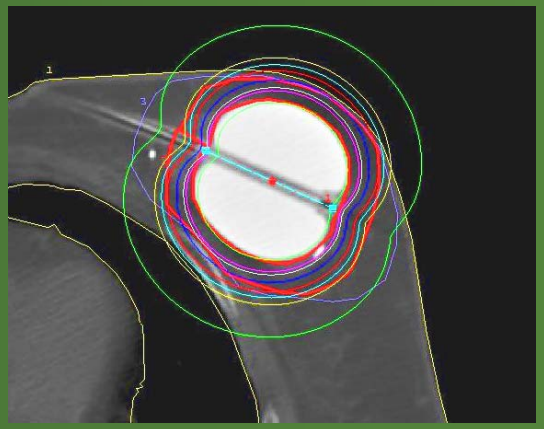

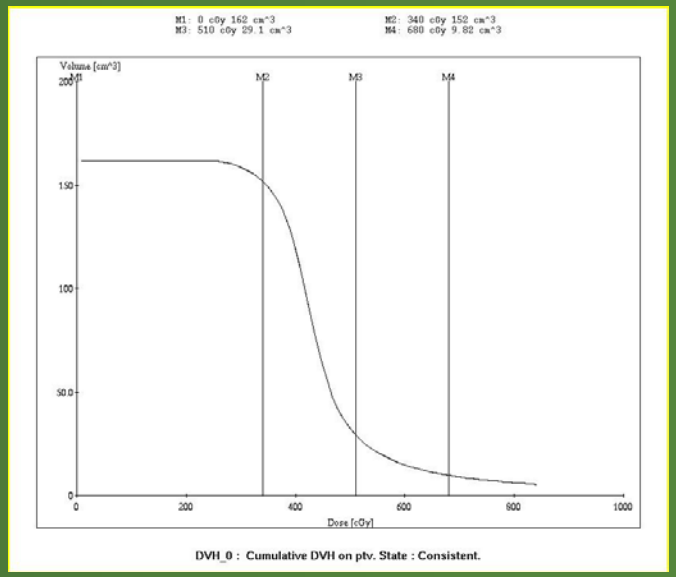

Simulation and Planning: Needles

- Know your applicator
  - steel needles
  - semi-rigid plastic needles
  - treatment lengths and active dwell positions
  - autoradiographs

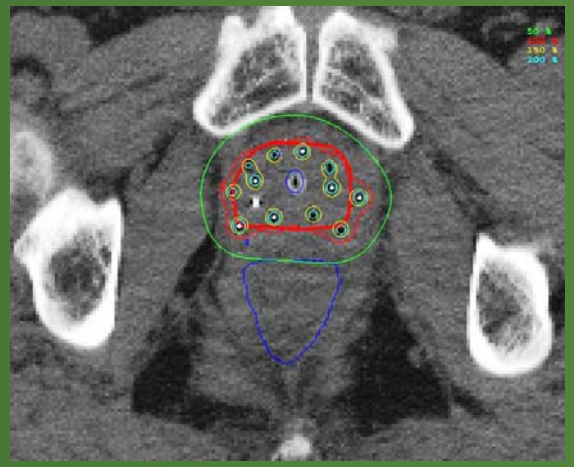

Simulation and Planning: Needles

- Correctly identify the treatment dwell positions with respect to the needles
  - steel or plastic needles
  - imaged tip versus actual first dwell position
  - CT axial views

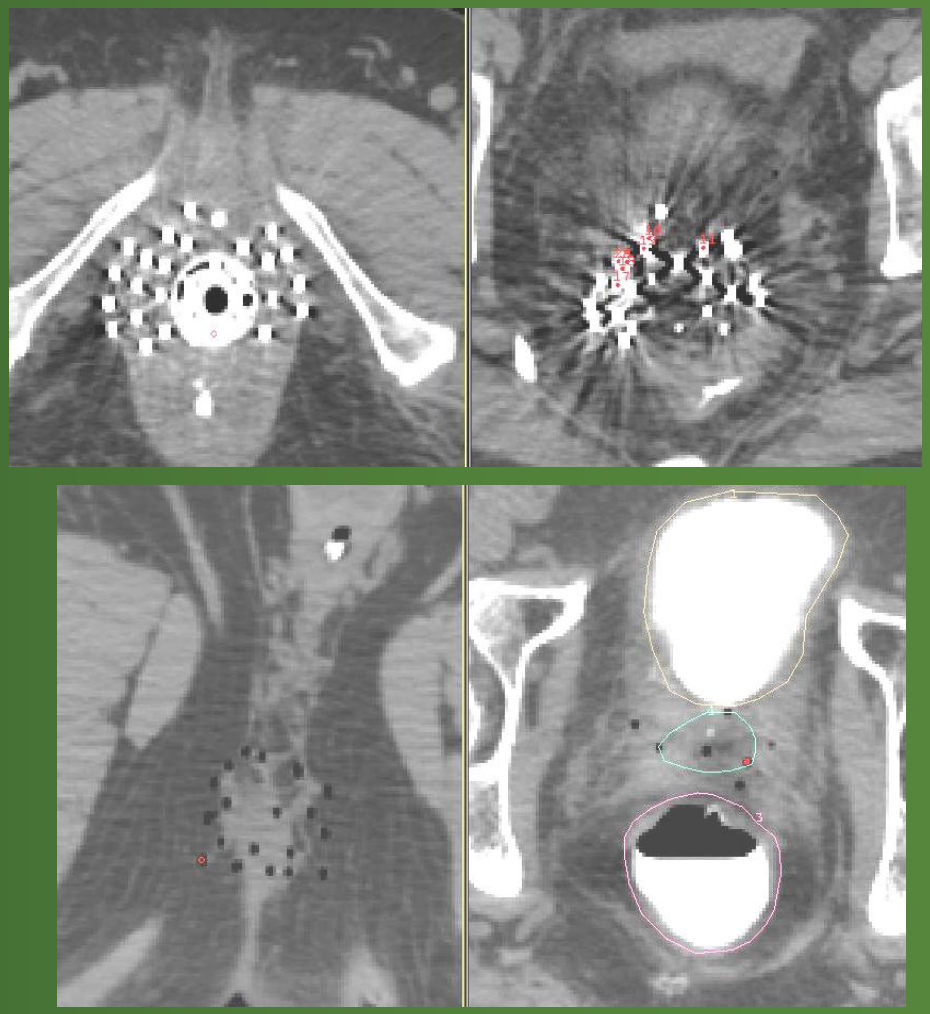

Dosimetry: Needles

- Not real time planning
- Make the best of the needle placement
- Adjust isodose lines as necessary
- DVH of target
  - good tool if you trust the contoured volumes

Conclusions

- Know your imaging system and its limitations
- Know your applicators and their expected reconstructed shapes
- Understand where the dwell positions are within the applicators as visualized on the volume scans
- Differentiate your traditional tissue point placement from the imaged tissues and their dosimetry