Small Animal Magnetic Resonance Imaging: Current Trends, Challenges and Perspectives for Pathological Imaging

C. Chad Quarles

Vanderbilt University Institute of Imaging Science

Outline

- Why image animals?
- MRI review
- Clinical versus animal imaging (*A Day in the Life of a Lab Rat)*
- Current trends
- On the horizon

Why Image Animals?

- Serial evaluation of preclinical disease models
  - Morphological (size, location)
  - Functional (blood flow, metabolism)
  - Cellular/Molecular
- Drug Screening
- Validation (characterization) of novel imaging methods
  - Biophysical basis of contrast mechanisms

Why Use MRI?

Technique	Resolution	Depth	Time	Cost	Uses (animals)
MRI	10-100 μm	No limit	Min-Hrs	$$$	High contrast, physiology, cell tracking
CT	50 μm	No limit	Min	$$	Lung/Bone tumor Imaging
PET/SPECT	1 - 2 mm	No limit	Min	$$-$$$	Metabolism of molecules/probes
Ultrasound	50 μm	mm	Min	$$	Vascular, Gross Morphology
Optical	1 - 2 mm	cm	Sec-Min	$$	Molecular, gene expression

Source: R.Weissleder, Nature Reviews Cancer, Vol 2, Jan 2002

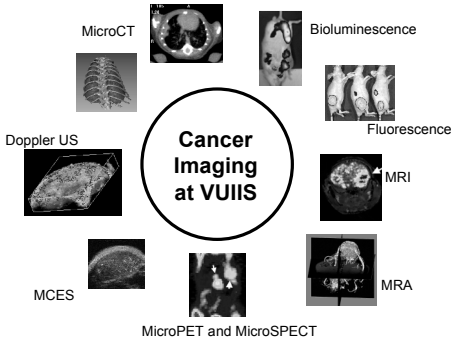

Imaging Across Scales

1) tumor size
2) tumor morphology
3) vascularity

anatomical/physiological

4) cell proliferation
5) cell density
6) apoptosis

cellular

7) cell surface receptors
8) extracellular milieu

molecular

MRI Review

Basis of NMR

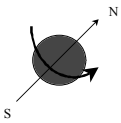

Hydrogen nuclei are small magnets

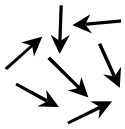

Normally they point in all different directions

MRI Review

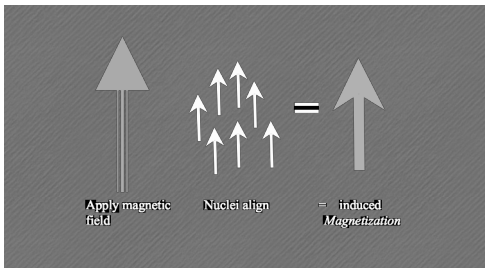

MRI

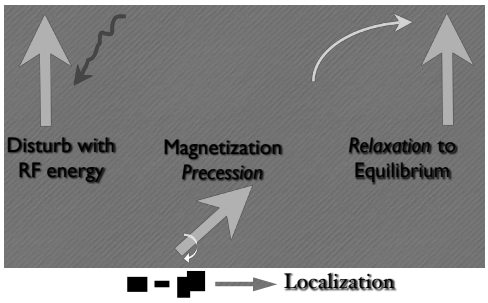

Transverse and Longitudinal Magnetization

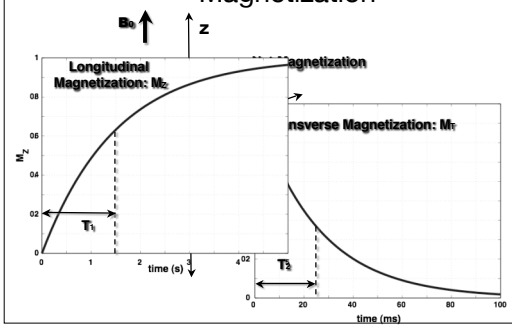

Relaxation Contrast

Different tissues have different T_1 and T_2 values

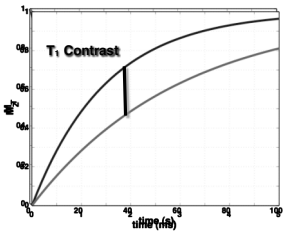

Different weighting, different contrast

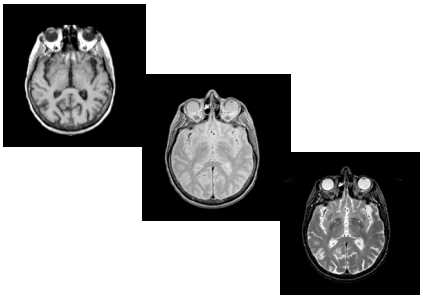

Other Ways to Generate Contrast

- Alter T_1 and T_2 with paramagnetic contrast agents
  - Non-Targeted (permeability, blood flow)
  - Targeted (cellular and molecular imaging)
- Diffusion weighting
- Flow contrast
- Susceptibility weighting
- ...

Clinical vs. Animal MRI SNR

- Resolution (↑Resolution ↓SNR)
  - Human ~ 100 kg: 10 mm^3 (1 x 1 x 10 mm)
  - Rat ~ 300 g: .03 mm^3 (310 x 310 x 310 μm)
  - Mouse ~ 25g: .0025 mm^3 (165 x 165 x 165 μm)
- Imaging time
  - To maintain SNR: $t \alpha 1 / x^6$
- Magnetic field strength (↑T ↑SNR)
  - Clinical (1.5T - 3T)
  - Animal (1.5T - 11.7T)
- RF coil (↓Size, better coupling, ↑SNR)

Reviews: GA Johnson, JMRI 16 (2002)

Clinical vs. Animal MRI (2)

Practical Aspects *(or my soap box)*

- Commercially available animal MRI systems come with very basic software packages
- Typically poor QC and QA
- Necessitates a dedicated MRI physicist/programmer/engineer for pulse programming, software debugging and hardware development. *(need a job?)*

  VUIIS: 2 MRI physicists and 1 engineer for 4 dedicated animal MRI systems
- Hardware -- clinic to lab

Data Issues

- Processing/Storing three-dimensional volumetric datasets (multi-modal and multi-parametric) is challenging.
  - 1 animal / 1 session ~ 1 - 5 GB
- Quantitative metrics, image fusion
- Screening, High throughput studies?
- Automation

Animal Handling

Day 0: Animals Delivered
Days 1-7: Animal acclimation
Day 8: Tumor Inoculation
Day 13: Catheters implanted
Days 14-35: Imaging Studies
Days 14-35: Treatment Application

Imaging Issues (2)

- Tune/Matching
- Shimming
- Respiratory / Cardiac Gating
  - Human RR ~ 20 breaths / minute
  - *Mouse RR ~ 160 breaths / minute*
  - Human HR ~ 72 beats / minute
  - *Mouse HR ~ 632 beats / minute*

Outline

- Why image animals?
- MRI review
- Clinical versus animal imaging (*A Day in the Life of a Lab Rat)*
- Current trends
- On the horizon

Current Trends

1) tumor size
2) tumor morphology
3) vascularity

anatomical/physiological
DCE-MRI,
BOLD-MRI, ASL,

4) cell proliferation
5) cell density
6) apoptosis

cellular
Diffusion,
Spectroscopy

7) cell surface receptors
8) extracellular milieu

molecular

Anatomical Localization/Size

- Rat glioma model
- Anti-angiogenic therapy
- T_1-Weighted Images after Gd-DTPA injection

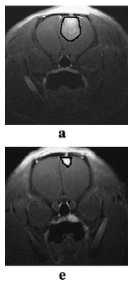

Untreated

Treated

C. Quarles, Magn Res Med 2007

Vascular Properties: DCE / DSC MRI

Interaction

Direct (T_1)

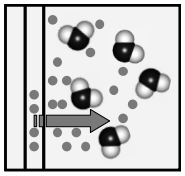

- Increase MRI Signal
- Dynamic Contrast Enhanced (DCE) MRI

Field (T_2,T_2^*)

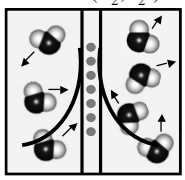

- Decrease MRI Signal
- Dynamic Susceptibility Contrast (DSC) MRI

DCE-MRI: Physiological Parameters

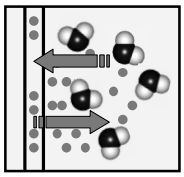

Physiological parameters that influence the temporal distribution of this contrast agent

blood volume: BV (units: ml · g^{-1})

extravascular extracellular (EES) volume fraction: v_e

vascular permeability: P·S (units: ml · g^{-1} · min^{-1})

blood flow: F (units: ml · g^{-1} · min^{-1})

Quantitative Analysis

Using a Compartmental Model

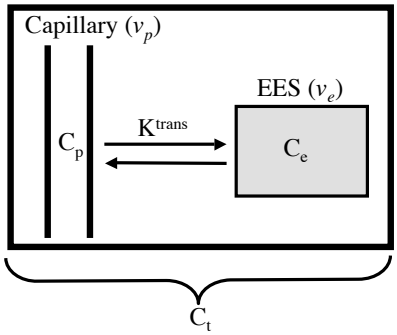

Knowns:
C_p, C_t

Unknowns:
K^{trans}, v_e

Note:
K^{trans} related to F and PS

DCE MRI Examples (1)

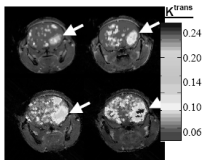

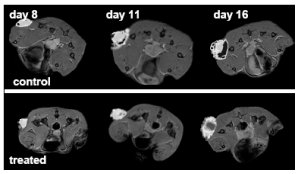

T.E. Yankeelov, VUIIS

DCE MRI Example (2)

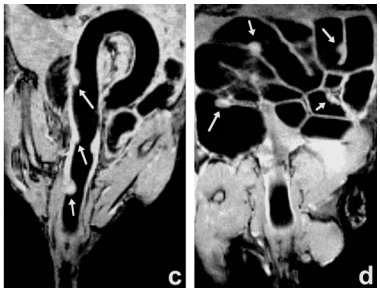

C. Quarles, Magn Res Med 2008 (in press)

DSC-MRI: Physiological Parameters

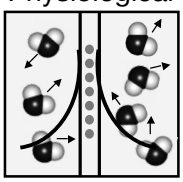

Physiological parameters that influence the temporal distribution of this contrast agent

blood volume: BV (units: ml · g^{-1})

blood flow: F (units: ml · g^{-1} · min^{-1})

transit times (sec)

DSC MRI: Preclinical Studies

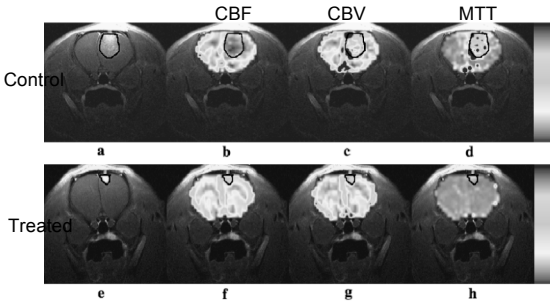

C. Quarles, Magn Res Med 2007

BOLD MRI

- Blood oxygen level-dependent MRI
- MRI signal intensity reflects oxygenation status of hemoglobin
  - dHb - Fe^{2+} is in a paramagnetic high spin state
- Alters R_2^* ($1/T_2^*$) transverse relaxation rates of water in blood and in the tissue surrounding the blood vessels
- Potentially useful for predicting response to oxygen enhancing therapeutics (e.g. changes in hypoxic fraction or responsiveness to radiation treatment)

BOLD MRI

- Compared BOLD and radiation response in GH3 and RIF-1 tumor models while animals breathed air or carbogen

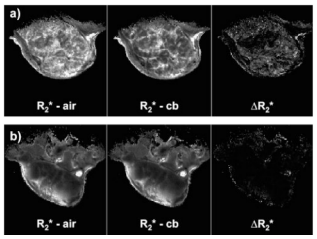

GH3

RIF-1

L.M. Rodrigues, JMRI 2004

Validation of CR-BOLD Contrast

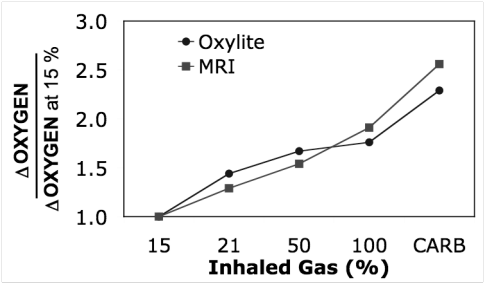

Arterial Spin Labeling

Used to quantify tissue perfusion

1. Acquire a "control image"
2. Tag Inflowing blood using selective RF pulse
3. Acquire the "tag image"

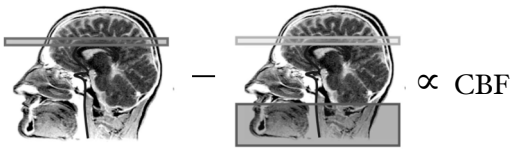

Image source: http://www.umich.edu/~fmri/asl.html

Rodent ASL Issues

- Human studies typically employ a single coil for labeling and imaging
- Difficult in rats/mice because labeling and imaging plane are in close proximity
  - RF irradiation for labeling can saturate the magnetization of macromolecules within the imaging plane (*magnetization transfer*)
  - Results in loss of water signal intensity

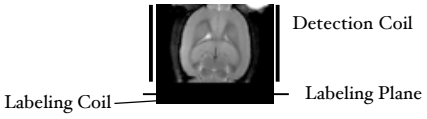

Biological Study

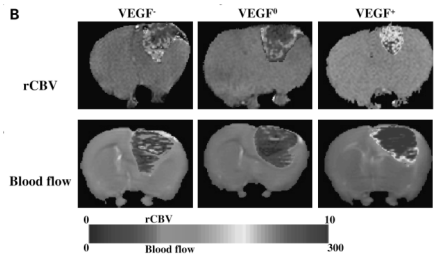

B. Moffat, Clinical Cancer Research, 2006

Current Trends

1) tumor size
2) tumor morphology
3) vascularity

anatomical/physiological
DCE-MRI,
BOLD-MRI, ASL,

4) cell proliferation
5) cell density
6) apoptosis

cellular
Diffusion,
Spectroscopy

7) cell surface receptors
8) extracellular milieu

molecular

Diffusion

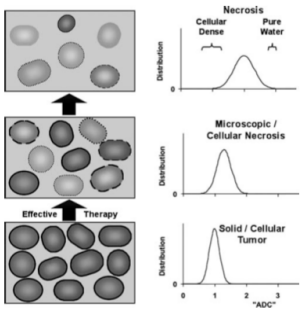

B. Ross, Mol Can Ther, 2003

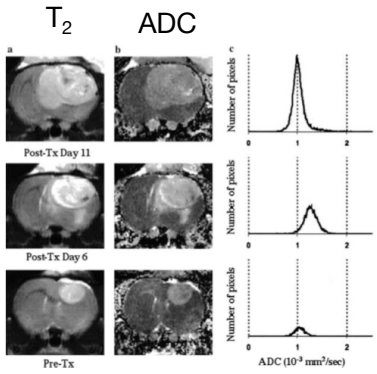

B. Ross, Mol Can Ther, 2003

Spectroscopy

- Non-invasive assessment of tissue specific metabolites
- Lactate - evidence of increased glycolysis
- Choline - shown to be useful for malignant diagnosis, treatment planning and monitoring treatment response

Spectroscopy

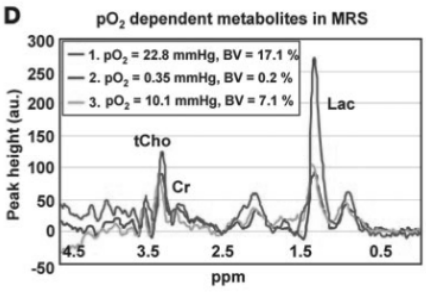

Matsumoto, J Clin Invest, 2008

Spectroscopy

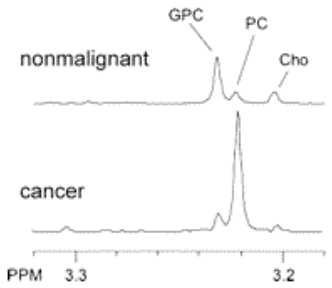

Hot Topics

- Sodium Imaging
- pH Imaging
- Cell Tracking
- Molecular Imaging

^{23}Na MR Imaging

- Cell division and the acidic extracellular microenvironment of tumors cells are associated with an increase in intracellular ^{23}Na concentration.

VD Schepkin, NMR in Medicine, 2006

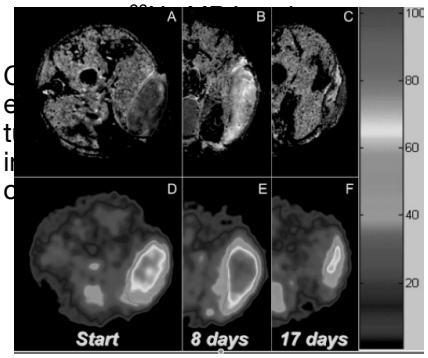

VD Schepkin, NMR in Medicine, 2006

pH Imaging

- Development of pH sensitive MRI contrast agents is a highly active area of research.
- Two strategies
  - Act as a T1 agent (Gd-based)
  - Directly image the agent using spectroscopy

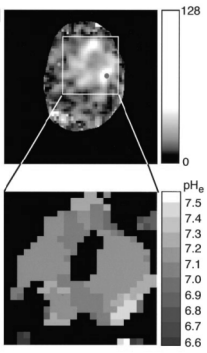

Imaging

pH sensitive MRI
is a highly active area

nt (Gd-based)
ne agent using

ML Garcia-Martin, Cancer Research, 2001

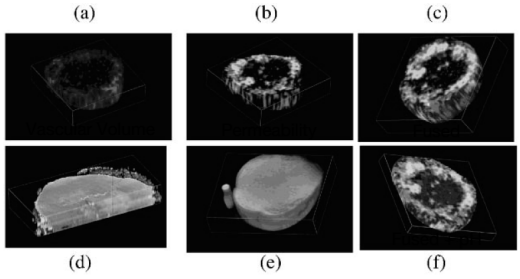

Z. Bhujwalla, NMR in Biomedicine, 2002

Cell Tracking (1)

- Bone marrow derived neural precursor cells incorporate into growing tumor vessels.
- Can be labeled with MRI-visible iron oxide nanoparticles and injected systemically
- Study - Image 10 days after injection of labeled cells

S. Anderson, Blood 2005

- Bone
cells
vess
- Can
oxide
syste
- Stud
label

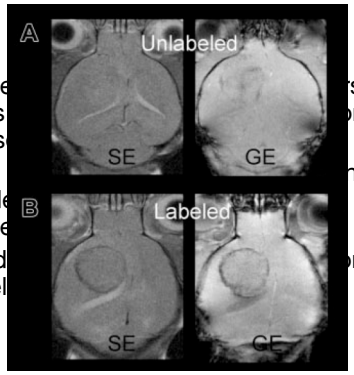

S. Anderson, Blood 2005

Cell Tracking (2)

- Neural precursor cells also colocalize within Multiple Sclerosis lesions.
- Can be labeled with MRI-visible iron oxide nanoparticles and injected systemically
- Study - Image 24 hours after injection of labeled cells

L. Poloti, Stem Cells 2007

Cell Tracking (2)

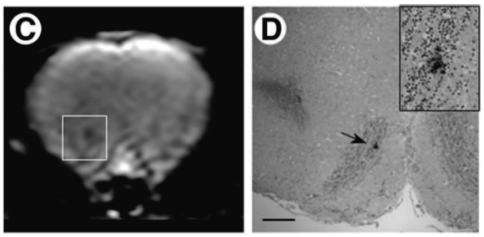

L. Poloti, Stem Cells 2007

$\alpha_v\beta_3$ Integrin Imaging

- Angiogenesis depends on adhesive interactions of endothelial cells
- $\alpha_v\beta_3$ is an important adhesion receptor integrin and has been imaged by many modalities
- Study: Compared non-targeted and targeted Gd-loaded liposomes

DA Sipkins, Nature Medicine, 1998

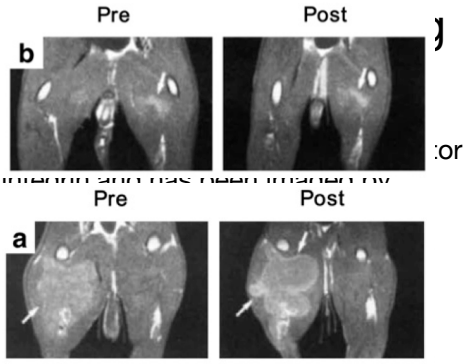

DA Sipkins, Nature Medicine, 1998

Her-2/neu Imaging

- The HER-2/neu receptor is an important target for tumor prognosis and therapy.
- It is overexpressed in approximately 25% of human breast cancers
- HER-2/neu expression correlates with poor prognosis for breast and other forms of human cancer.

D. Artemov, Cancer Research 2003

Her-2/neu Imaging

- The HER-2/neu receptor is an important target for tumor prognosis and therapy.

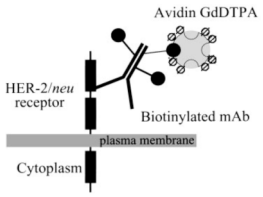

D. Artemov, Cancer Research 2003

Her-2/neu Imaging

- The HER-2/neu receptor is an important target for tumor prognosis and therapy.

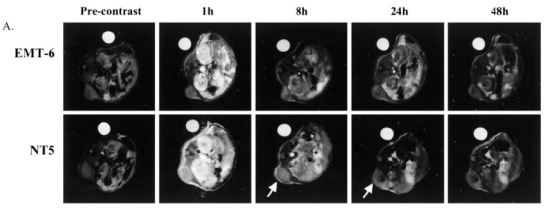

D. Artemov, Cancer Research 2003

Her-2/neu Imaging

- The HER-2/neu receptor is an important target for tumor prognosis and therapy.

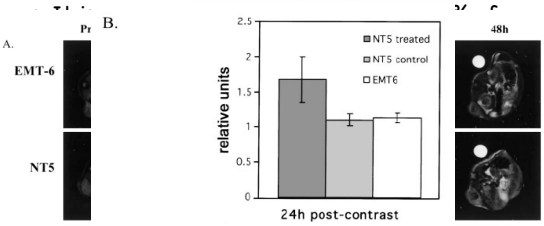

D. Artemov, Cancer Research 2003

Conclusions

- Animal MRI Advantages: High contrast, sensitive to many physiological and biochemical tissue characteristics
- Animal MRI Disadvantages: Costly, time consuming, requires substantial infrastructure
- Derived metrics useful for disease characterization, treatment planning and monitoring
- Serves as a screening process for clinically relevant tools

Acknowledgements

- Tom Yankeelov
- Mark Does***
- Chris Wargo
- Daniel Colvi
- Noor Tantaway

*** Hates that I exported his fancy and neat Keynote slides into Powerpoint