The Role of MRI-Guided High-Intensity Focused Ultrasound (MRgFUS) in Cancer Therapy

Lili Chen, PhD

Department of Radiation Oncology

Fox Chase Cancer Center

Outline

- Background of MR Guided High-Intensity Focused Ultrasound (MRgFUS)
- Currently available MRgFUS systems
- The potential of MRgFUS for cancer research and clinical applications

Diagnostic Ultrasound Vs Therapeutic Ultrasound

Frequency

Diagnostic: 3-10 MHz (> 20MHz for skin scan)

HIFU: 1-2 MHz

Power output

Diagnostic: < 5mW/cm^2

HIFU: > 100 W/cm^2

Background of MRgFUS

- High Intensity Focused Ultrasound (HIFU) first investigated in 1942

  (Lynn JG et al, biology. J Gen Physiol 1942;26:179-93)

  Many studies performed by groups of Dr ter Haar & of Dr Hynynen over the 3 decades

- Ultrasonic lesions seen on MR first reported in 1993

  (Cline HE et al MRM 1993;30:98-106)

Schematic Diagram

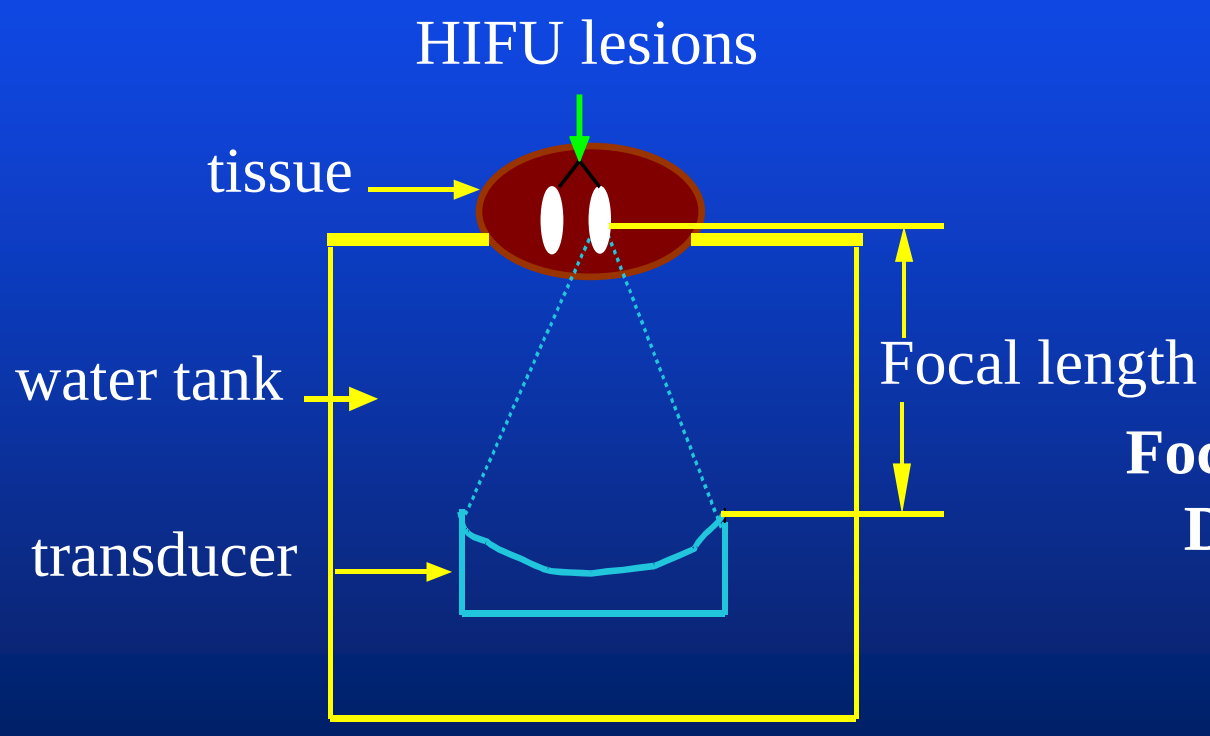

Focal region: 3x15 mm
Defined on a beam

profile (FWHM)

The water must be degassed

Mechanisms of Tissue Damage

- Primary mechanism of damage is thermal, i.e. “cooking” of the tissues

  (measured temperature >56 ºC at focal zone)

- Another mechanism is cavitation

Advantages of the MRgFUS

- Completely non-invasive therapy
- Re-treatment possible
- Alternative therapy after RT and surgery

HIFU Lesions

Histology Findings in Liver *(2 h after FUS)*

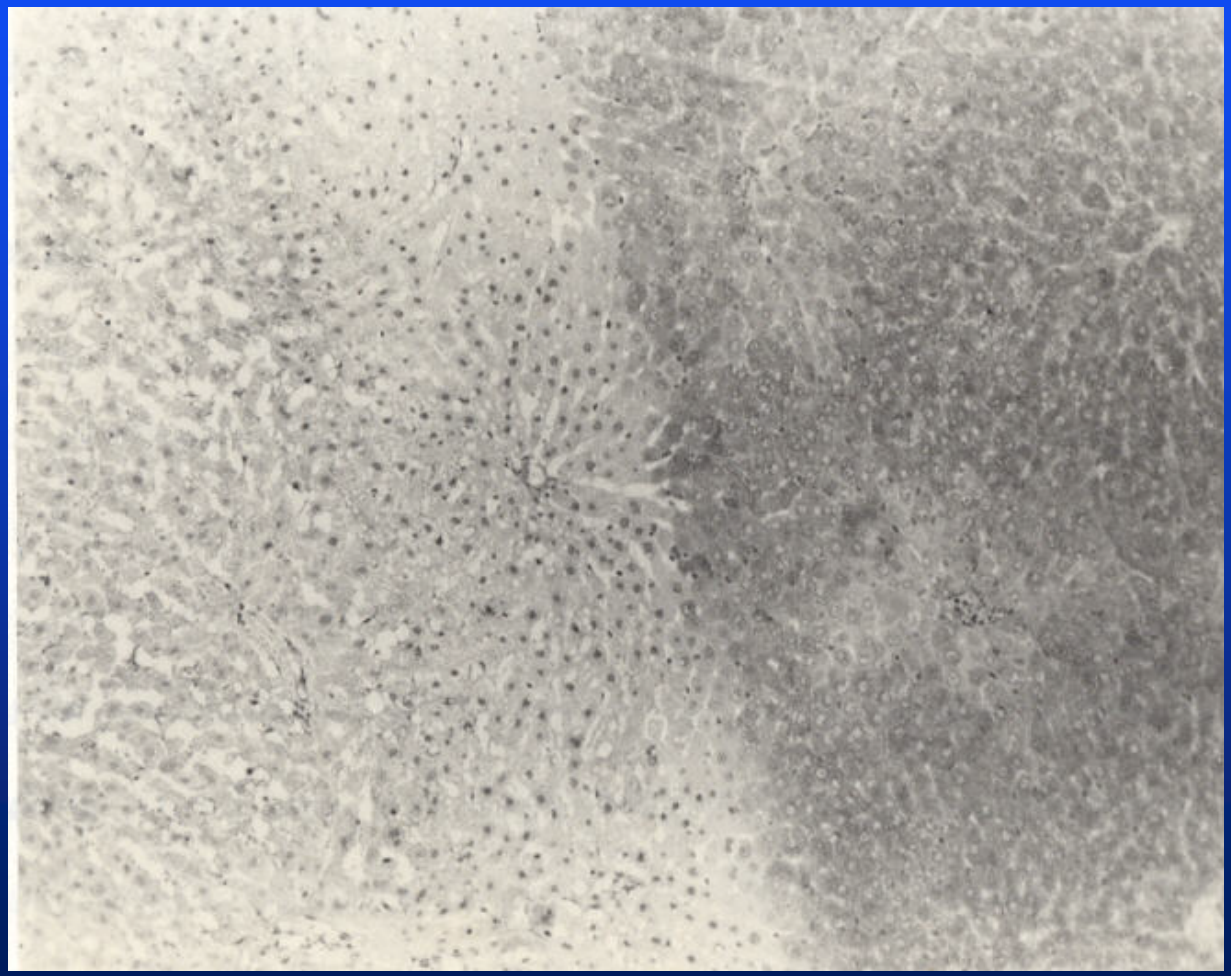

treated **untreated**

Factors affecting lesion formation

- Intensity
- Sonication duration
- Lesion separation
- Blood flow

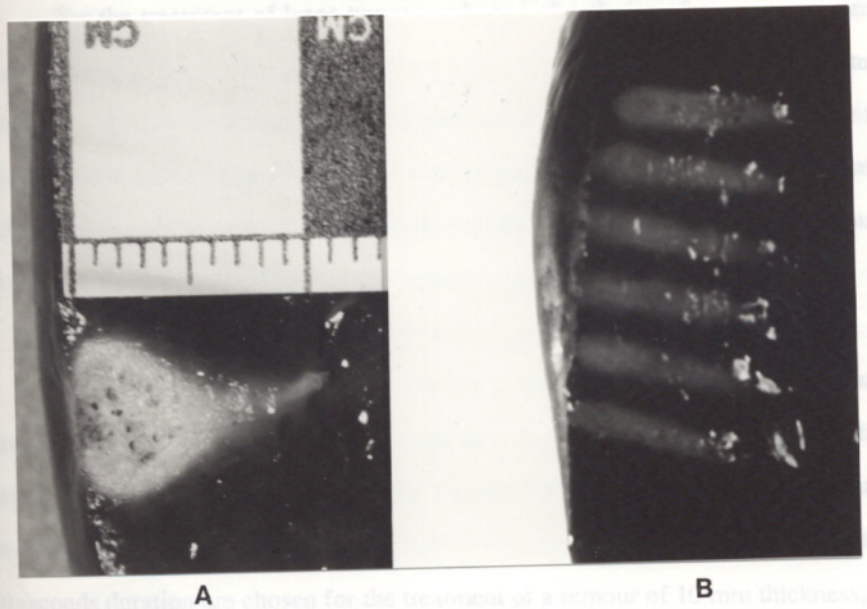

Fig. 5.10 Examples of ultrasonically induced lesions in excised porcine liver. Lesions made with higher intensities are "carrot-shaped" (a) while lesions made at lower intensities are "cigar-shaped" (b).

Effect of Lesion Separation

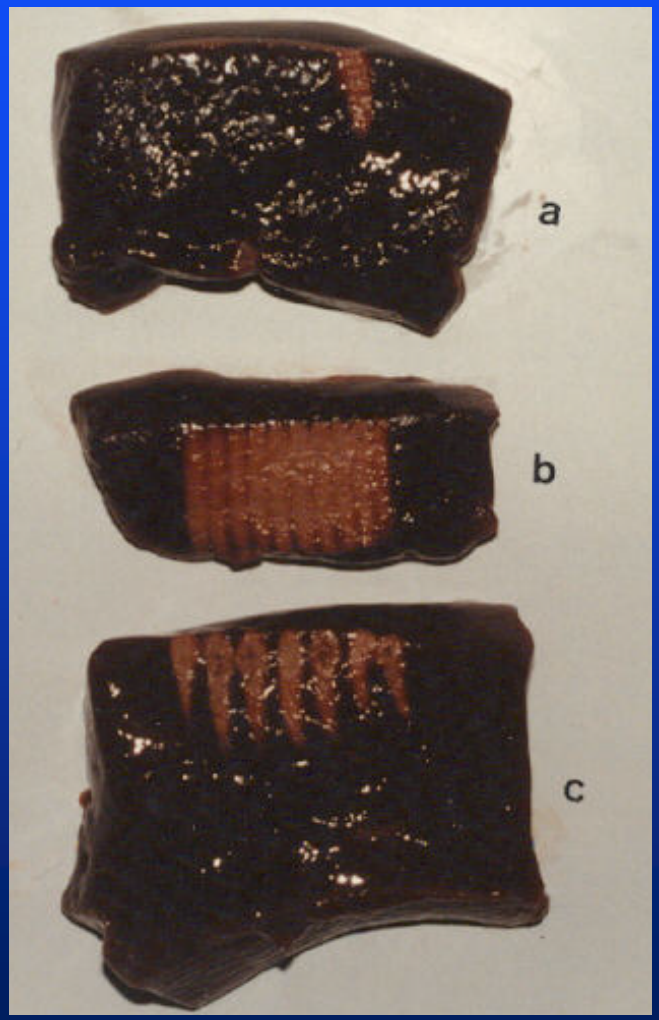

Lesions produced in the liver with 261 W/cm^2, 3 mm focal depth, and 5 S exposure duration

a) 1 mm exposure separation
b) 2 mm separation
c) 3 mm exposure separation.

Chen et al 1997 UMB

Effect of Blood Flow

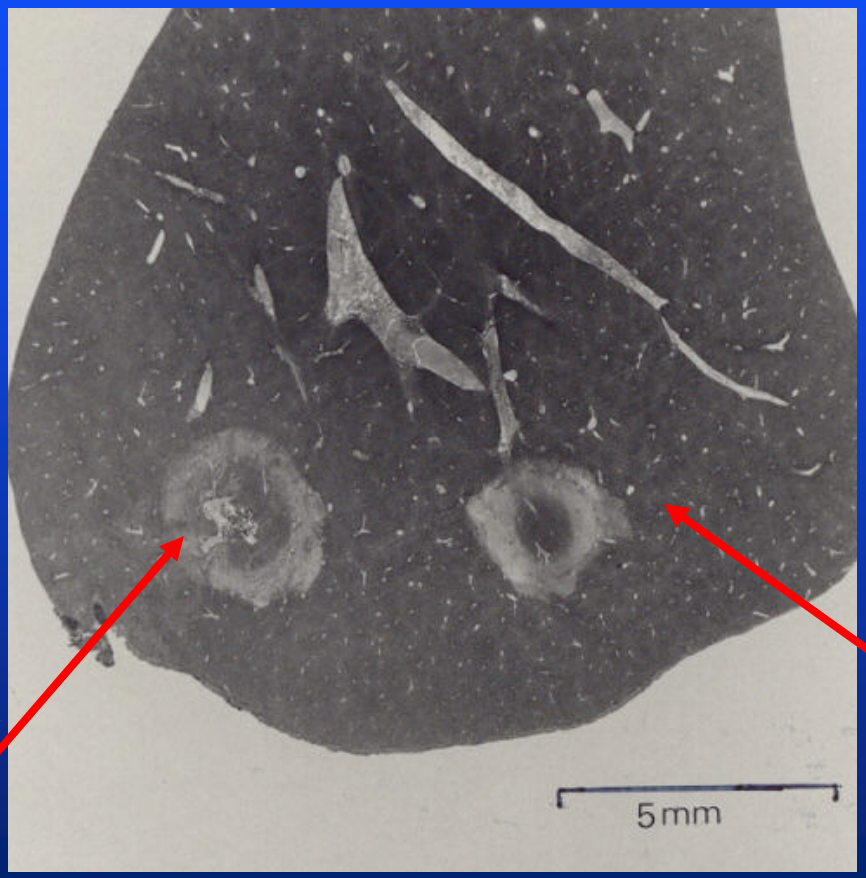

with reduced blood flow

with normal blood flow

Chen et al 1993 UMB

HIFU Surgery under MR Guidance

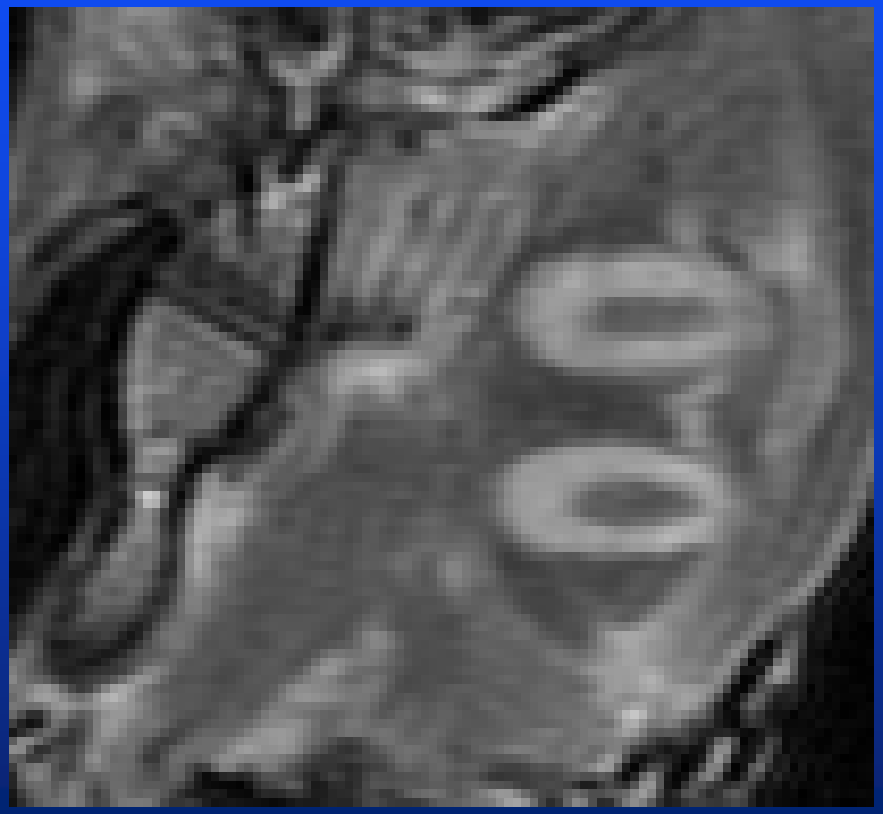

Lesions made in a rabbit brain (in vivo)

Chen et al 1999 JMRI

How to image HIFU lesions using MR?

- T2 shows cell death zone but not for real time monitoring due to time delay

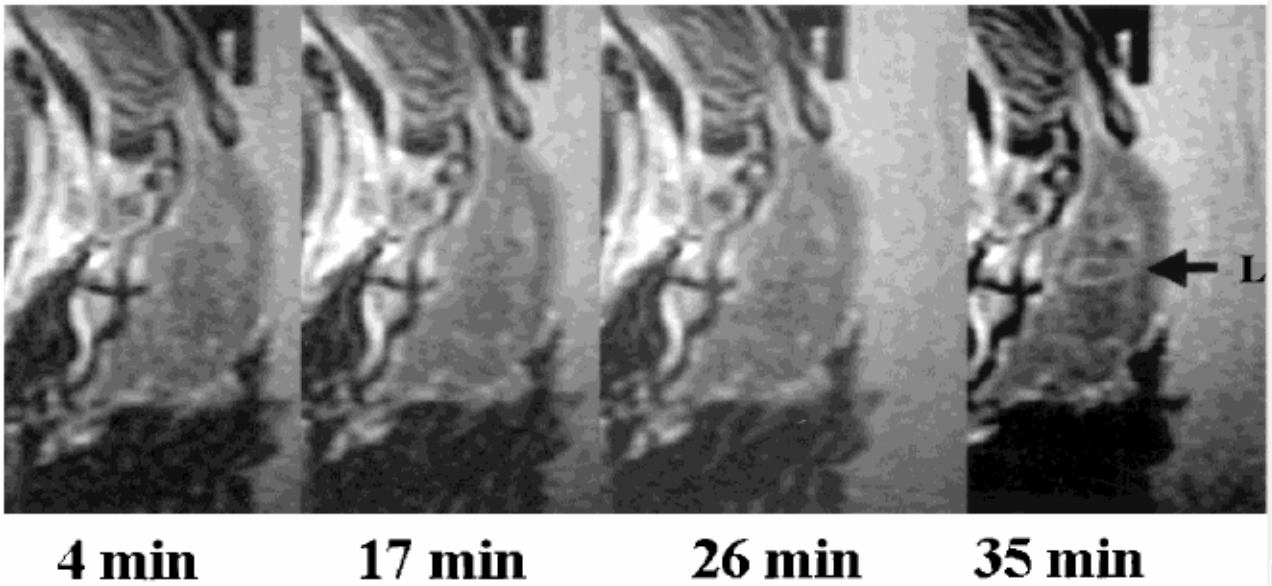

Figure 7. An example in one animal of time delay for bright ring to appear on T2-weighted MR images. The lesio between 26 and 35 minutes after FUS exposure.

Chen et al JMRI 10: 146-153 1999

How to image FUS lesions using MR?

- Real-time MR thermometry can provide an indication of tissue damage if temperature thresholds/ thermal Dose are known



Graham, Chen and Leitch et al 1999 MRM

Temperature Measurement on MRI using Proton Resonant Frequency Shift Method

$$\Delta T = \frac{\Phi - \Phi_o}{\gamma \alpha B TE}$$

Φ_o = the initial phase before heating

γ = the gyromagnetic ratio

α = the coefficient of temperature change

0.01 ppm/ °C for aqueous tissues

B = the magnetic field strength

TE = the echo time

Temperature Maps



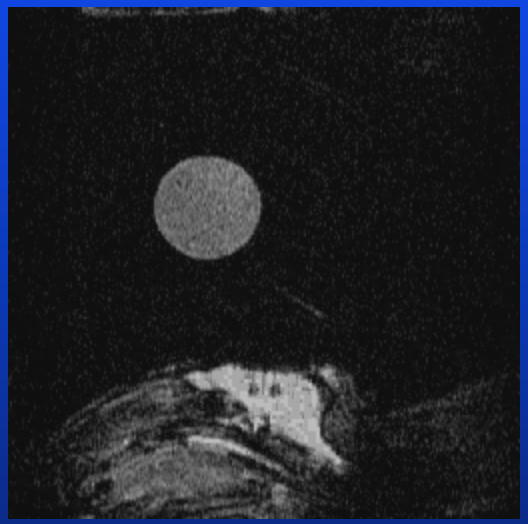

- *In vivo* laser ablation
- Color overlay where temp > 47°C

Courtesy of Dr. K Butts

Thermal Dose Calculation
(t_{43} = equivalent time at 43°)

$$t_{43} = \int C^{43-T(t)} dt,$$

C= 0.5 for >43 *°C*
C= 0.25 for < 43 *°C*

non-linear behavior for tissue damage:
at 43 *°C*: 240 min; at 54 *°C*: 3s; at 57 *°C*: 1s;

Sapareto SA and Dewey WC. Int.J.Radiat.Oncol Biol Phys 1984:10:787-800

FUS Equipments

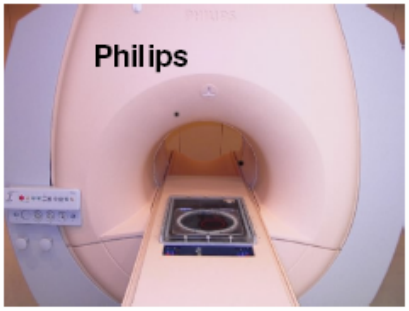



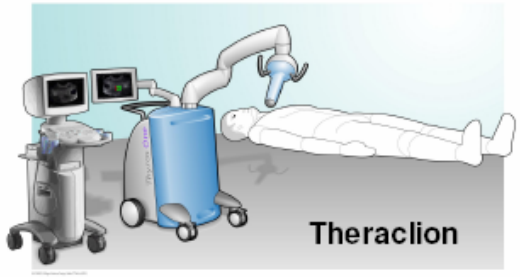

Courtesy of Dr. J-F Aubry

Haifu Model JC Focused Ultrasound Tumour Therapeutic System

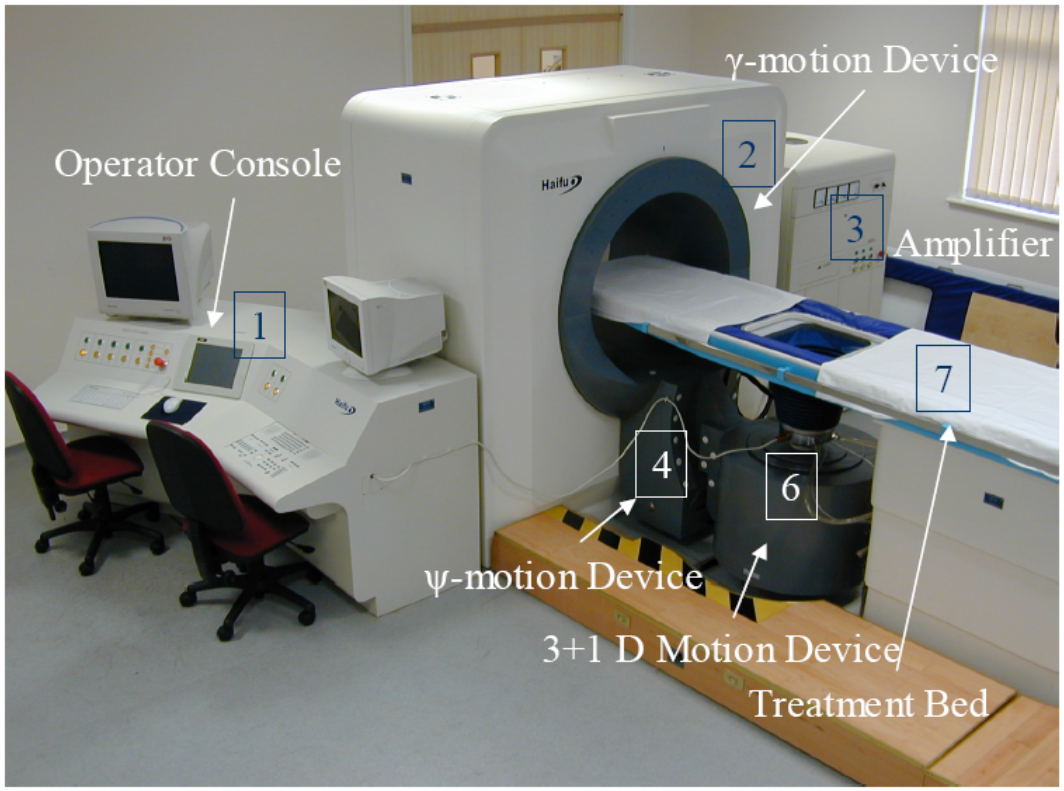

Courtesy of J. Kennedy, F. Wu

Oxford, UK & Chongqing, China

> 20,000 patients treated in China

ExAblate® 2000 Device (InSightec)

approved by FDA for treatment of uterine fibroids

ExAblate Main Components

Operator Console (operator room)

Equipment Cabinet (equipment room)

Patient Table (scanner room)

Patient Table: Patient Cradle



The phased array transducer is housed in a sealed bath and connected to a motion system.

What is MRgFUS?

3D anatomic information for exact tumor targeting

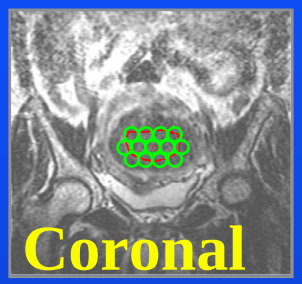

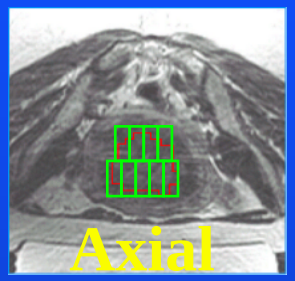

Beam path visualization for safe treatment

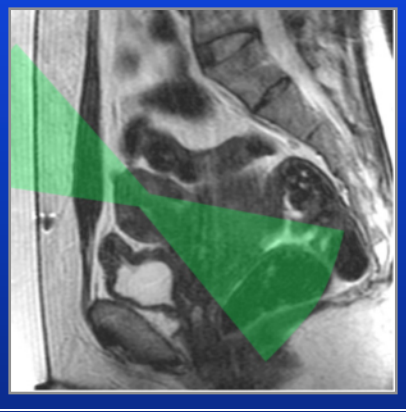

Real time MR thermometry to achieve planned outcome

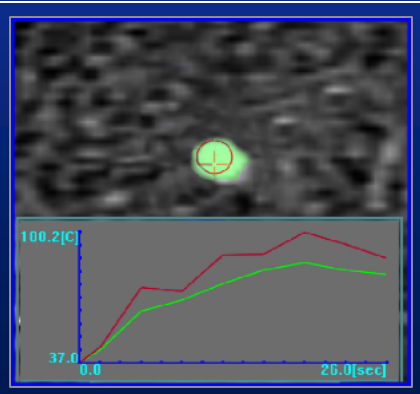

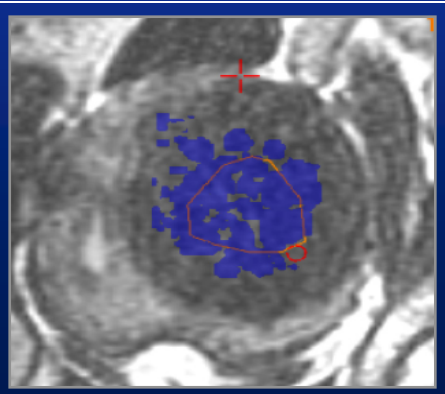

=



close loop therapy

Correlation of MR Thermometry and Tissue Damage

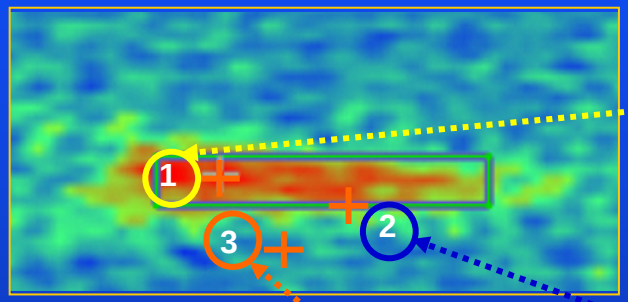

Temperature map of a sonication

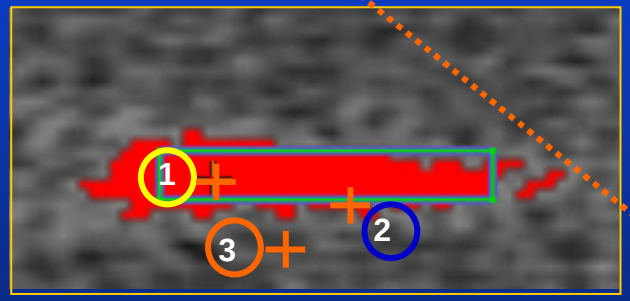

Thermal dose threshold
(above 240 minutes at 43° C)



Pathology of same sonication

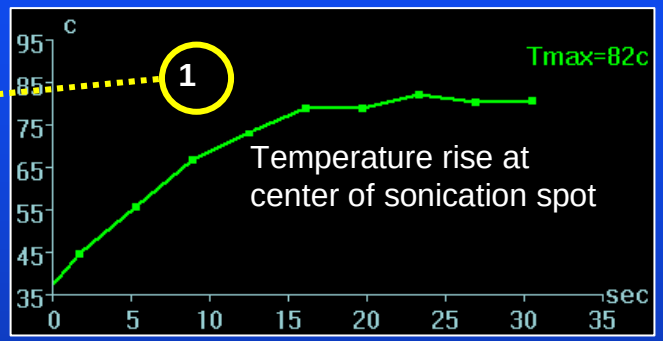

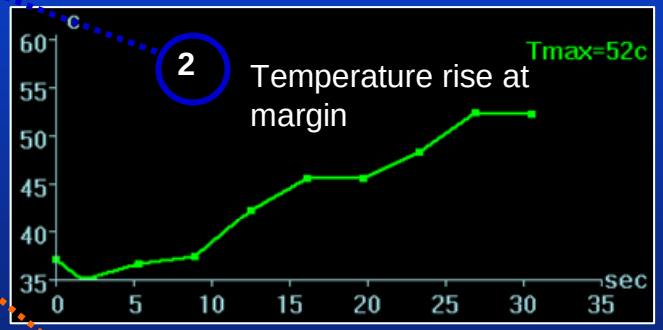

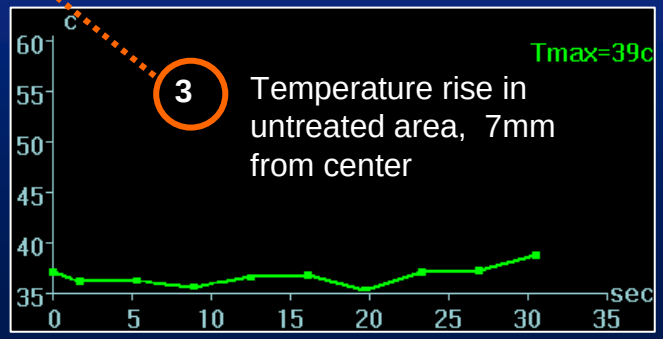

Potential Applications for Cancer Treatment

- Brain tumor
- Breast cancer
- Bone metastases (palliative pain relieve)
- GI (liver, pancreas)
- Prostate cancer, Kidney
- GYN

Breast cancer - excisionless study

- **Objectives:**
  Evaluate long term local recurrence of up to 1.5 cm MRgFUS treated breast carcinoma and evaluate safety of the procedure
- **Design:**
  Only patients with MR identified single focal lesion (up to 1.5 cm) of T1/T2, N0, M0 disease will be treated
- **Location:**
  Breastopia Namba Hospital, Miyazaki, Japan

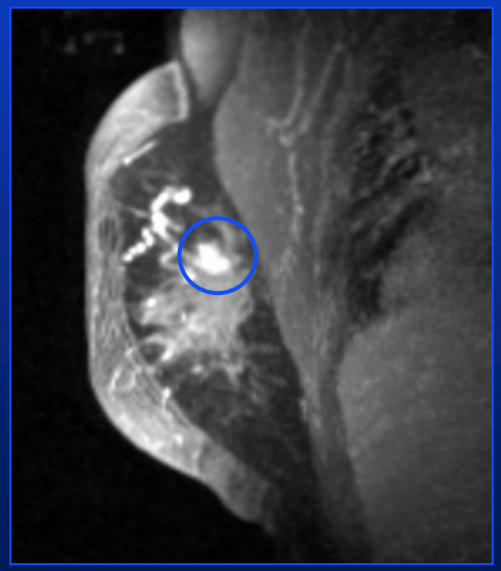

Pre treatment T1w+CE MIP image

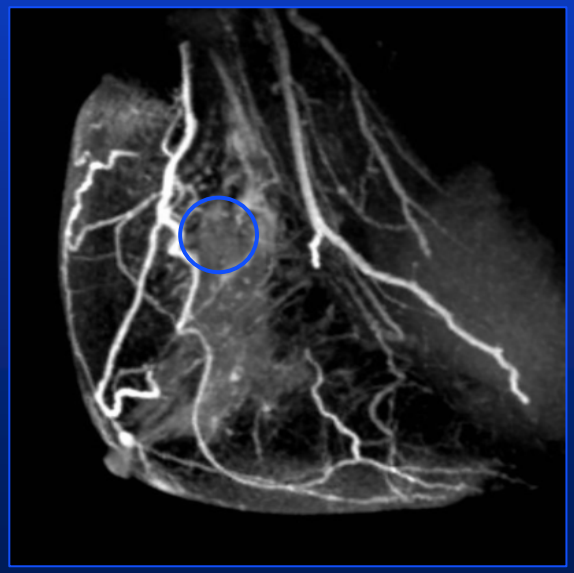

2 weeks post treatment T1w CE MIP image

Breast Cancer: before and after MRgFUS treatment

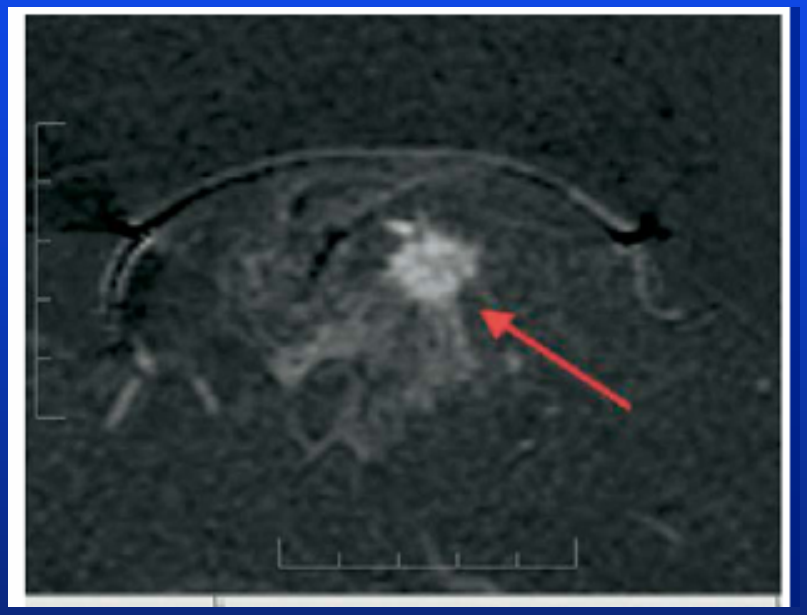

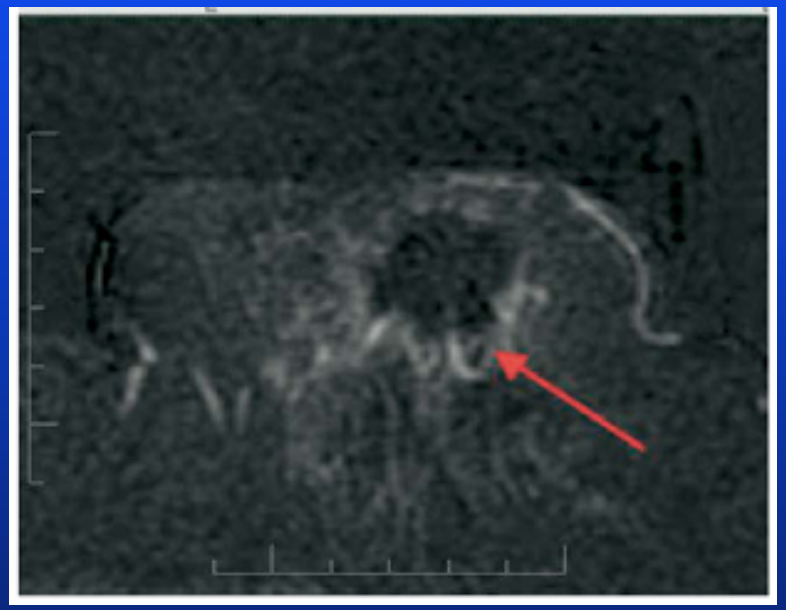

Furusawa et al J Am Coll Surg 203: 54-63; 2006

Brain Tumor Study

Objective:

- Safely treat brain tumors through intact skull

Results:

- 3 patients treated (recurrent glioblastoma or metastatic cancer)
- No skull heating
- Reported to FDA; FDA approved continuation based on safety

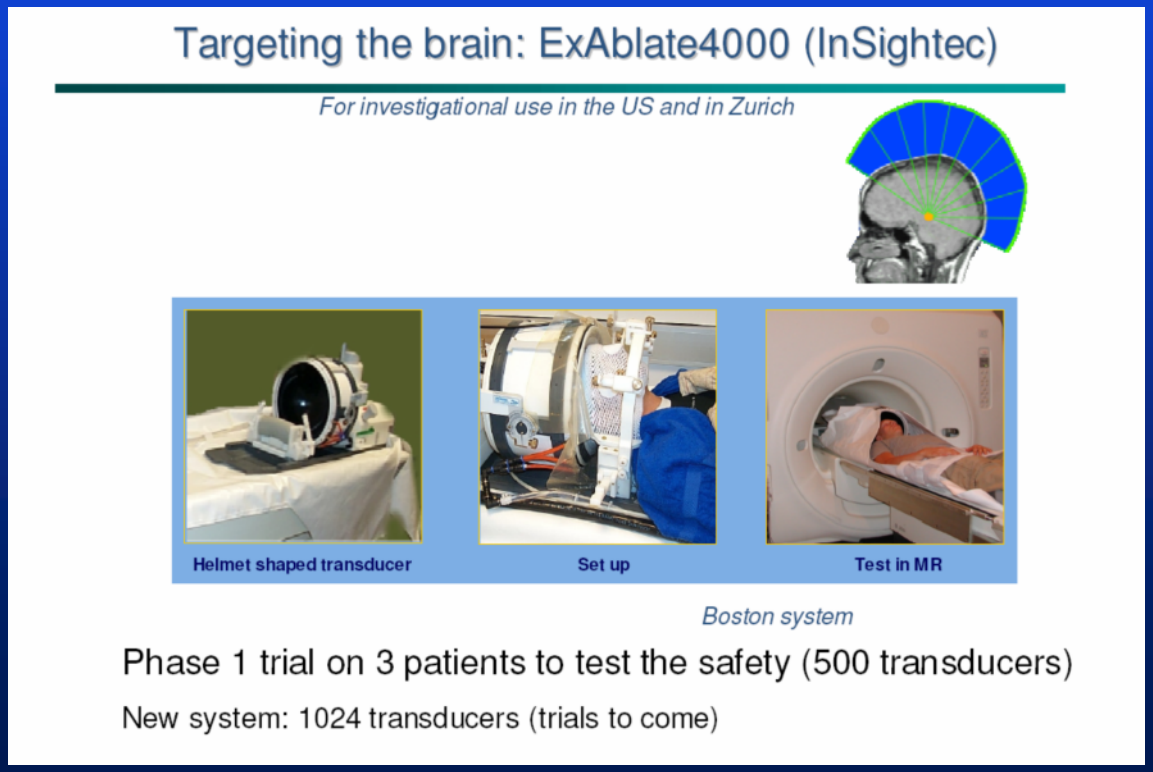

Brain Tumor Study

Results (continued):

2 patients are still alive (27 and 30 months later), 3rd patient survived 10 months after treatment (Paper submitted for publication)

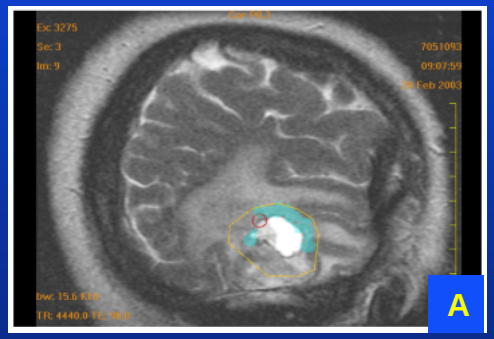

Accumulated thermal dose at end of treatment

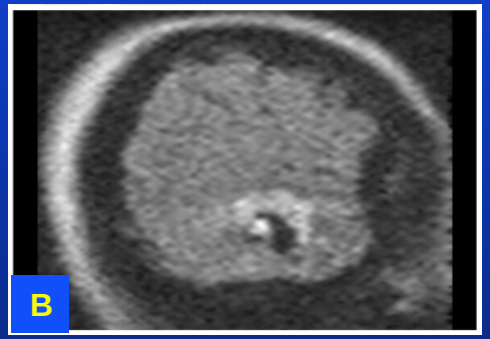

Diffusion weighted image immediately post-treatment

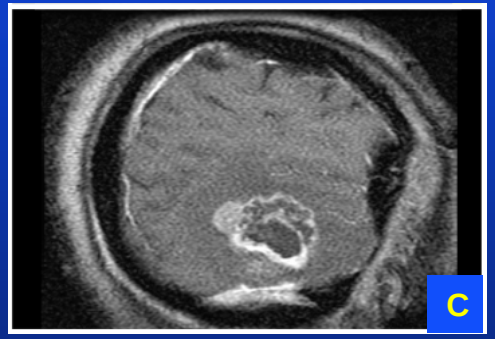

T1w contrast enhanced image immediately post-treatment

Courtesy of Sheba Medical Center, Tel Aviv, Israel

Liver Tumor Study

Objective:

- Demonstrate capability of treating liver tumors safely with respiratory gating

Results:

- Treatment synchronized with respiration enables consistent target position during sonications for entire procedure
- High quality MR thermal imaging

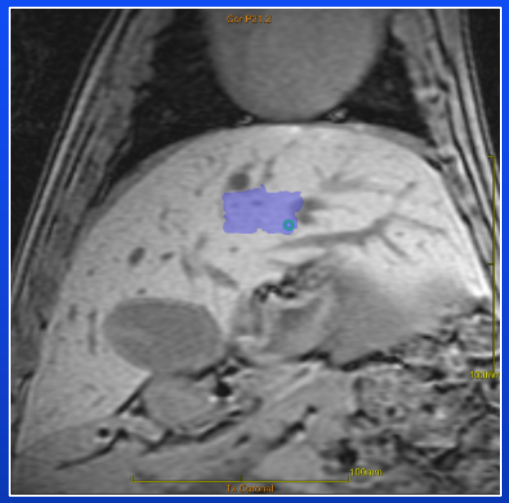

Treated dose following FUS treatment shown on T1w MR

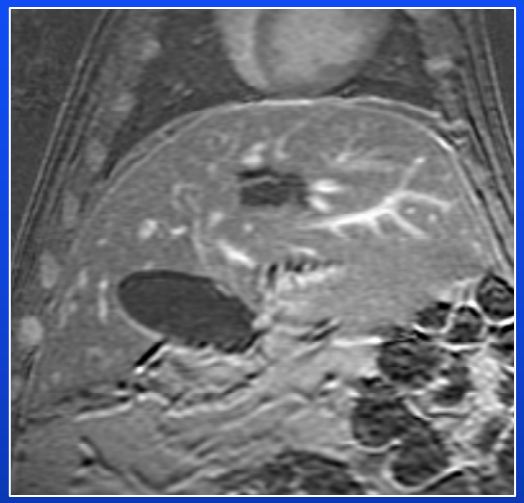

Contrast enhanced T1w subtraction image showing the lesion.

Pathology after 4 days

Microscopy pathology

MRgFUS for Palliation of Bone Metastasis

Treatment principles

- Bone heating is used to ablate the adjacent periosteum
- Palliation achieved by the ablation of the bone periosteum, which is the sensory origin of the pain

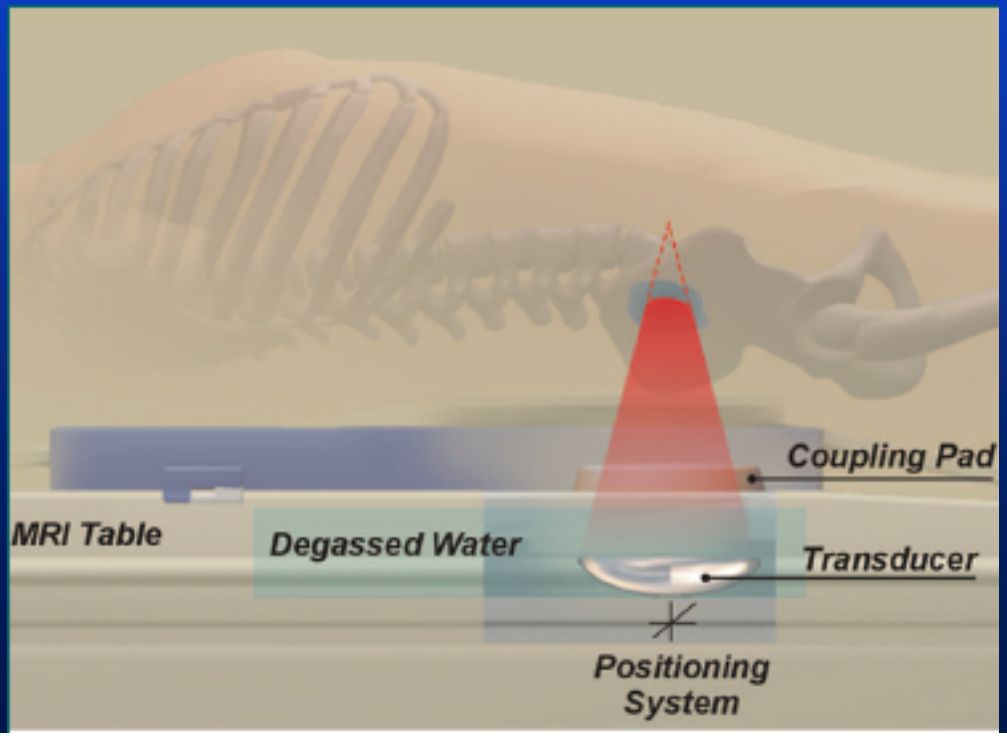

MRgFUS for Palliation of Bone Metastasis
(FCCC's experience)

- metastatic breast cancer
- previous radiation to left shoulder
- OxyContin 100 mg bid
- Oxycodone 30 mg q 4 h prn pain; on average, 3 to 4 doses per day
- Lidoderm 5% patches daily
- pain 8 of 10

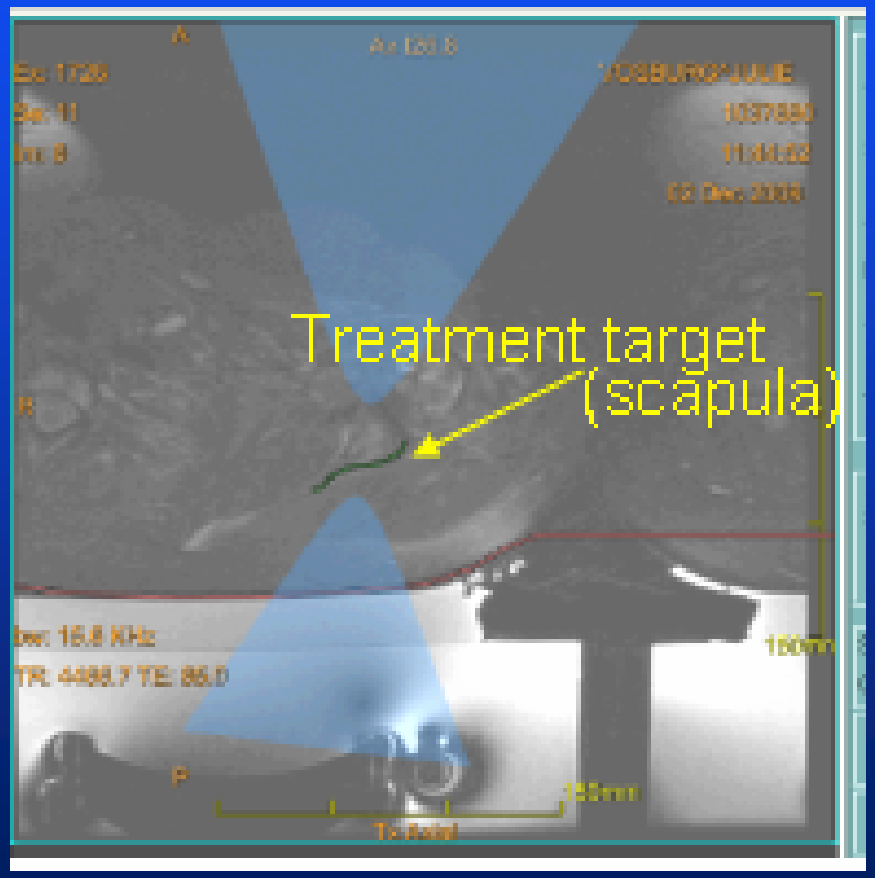

Results (from FCCC)

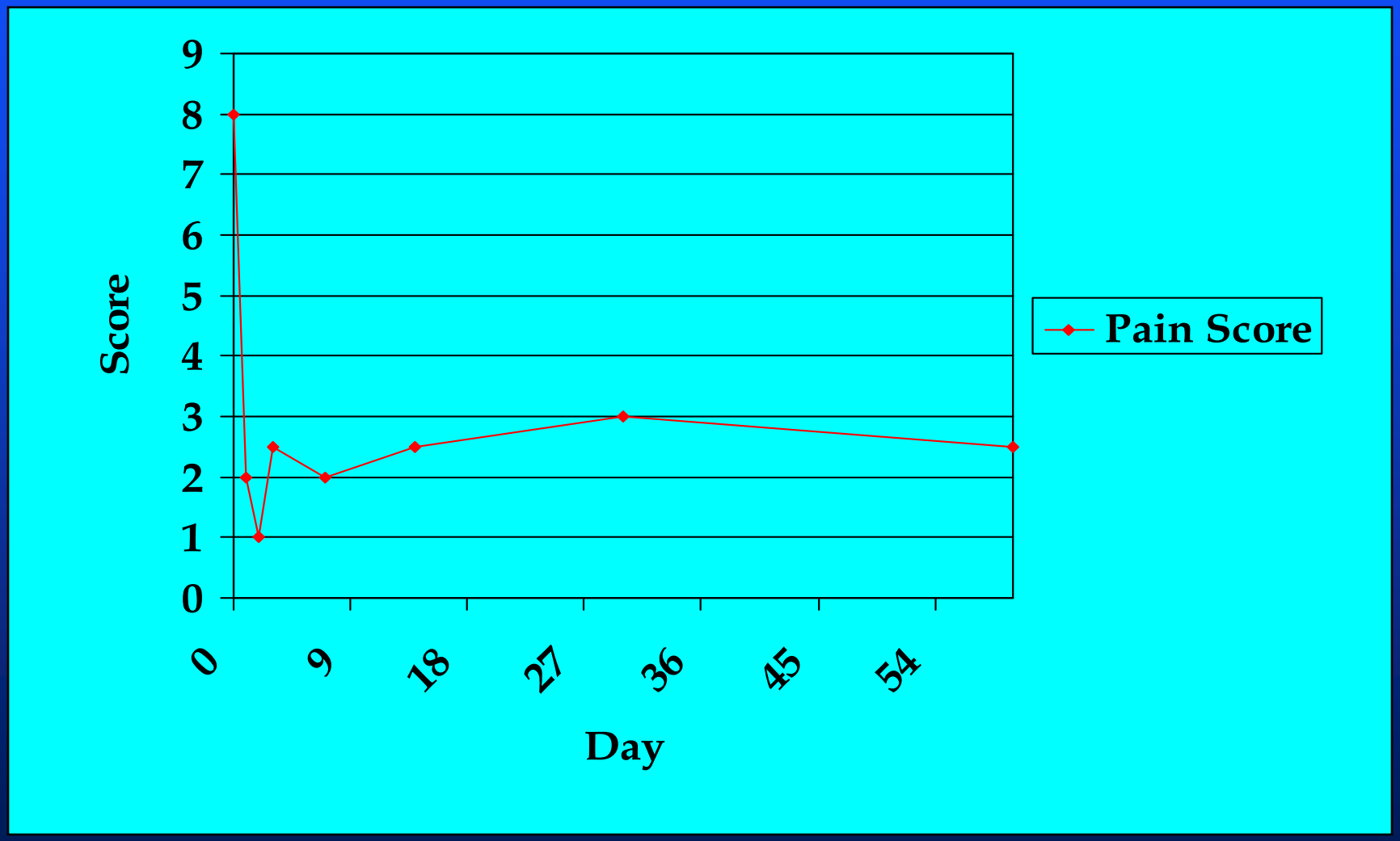

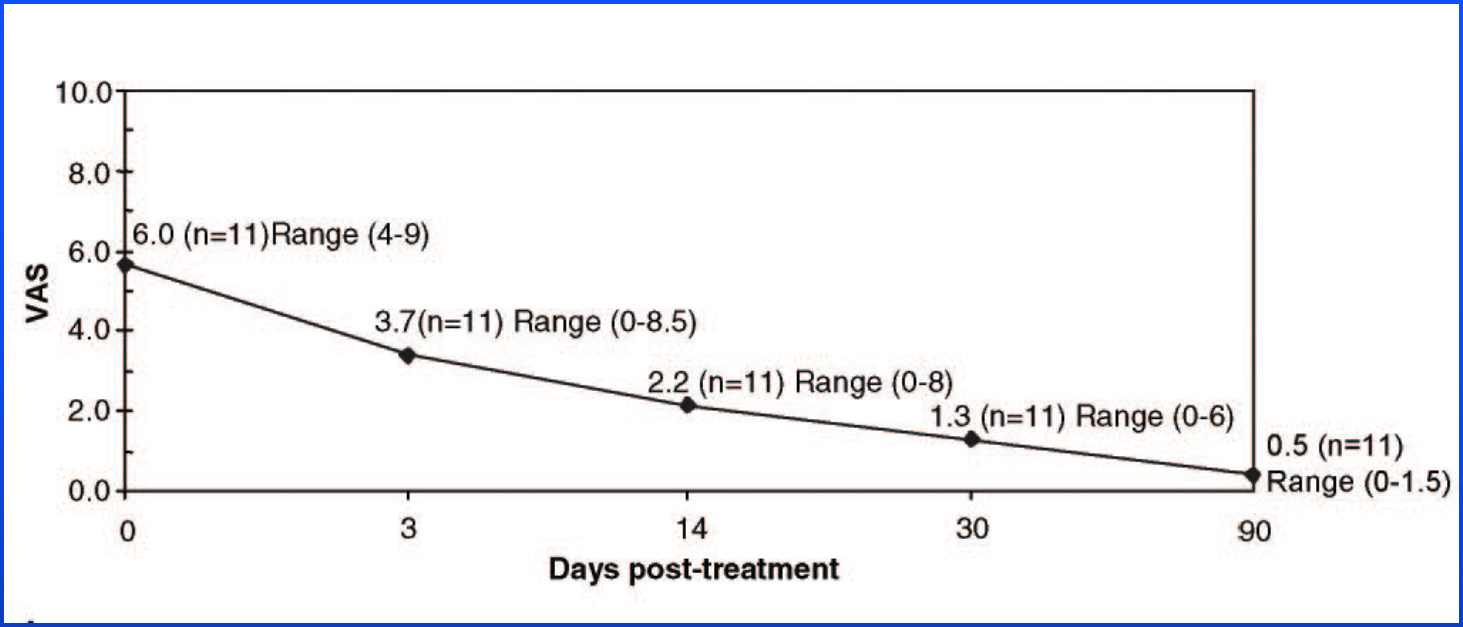

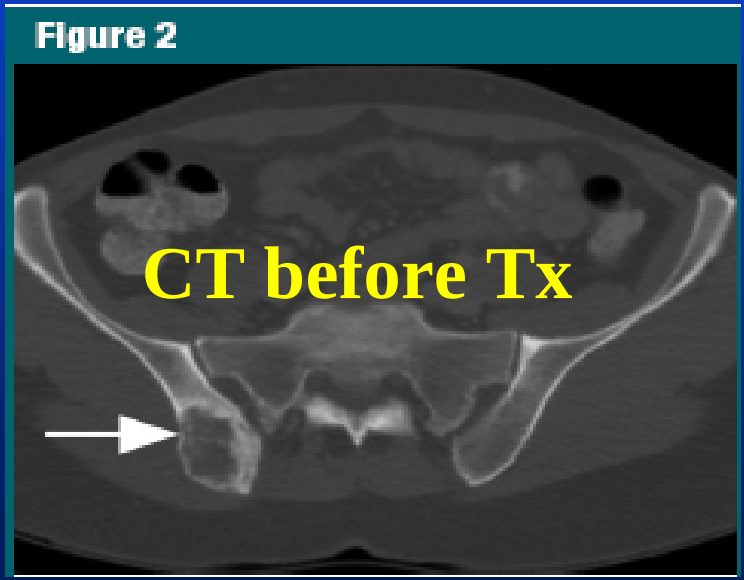

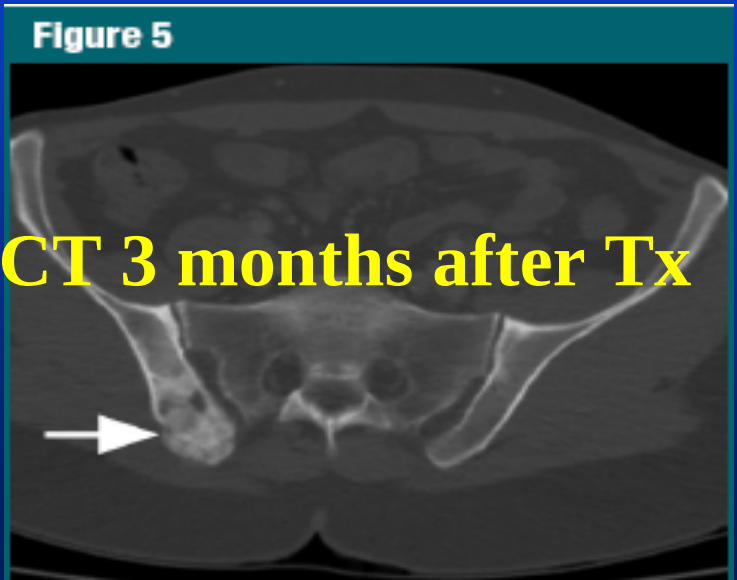

David Gianfelice et al Radiology 2008; 249:355–363

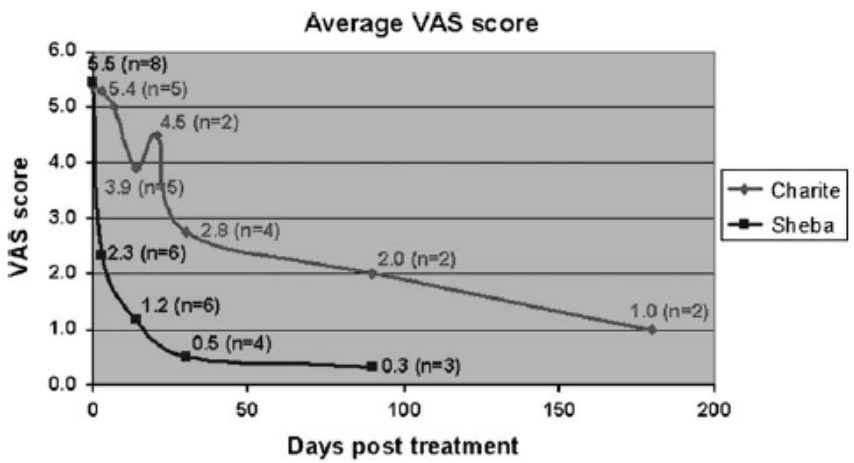

Figure 3. Average visual analog scale score of 13 treated patients (15 treatments) during follow-up.

Catane et al Ann Oncol 18:163-7; 2007

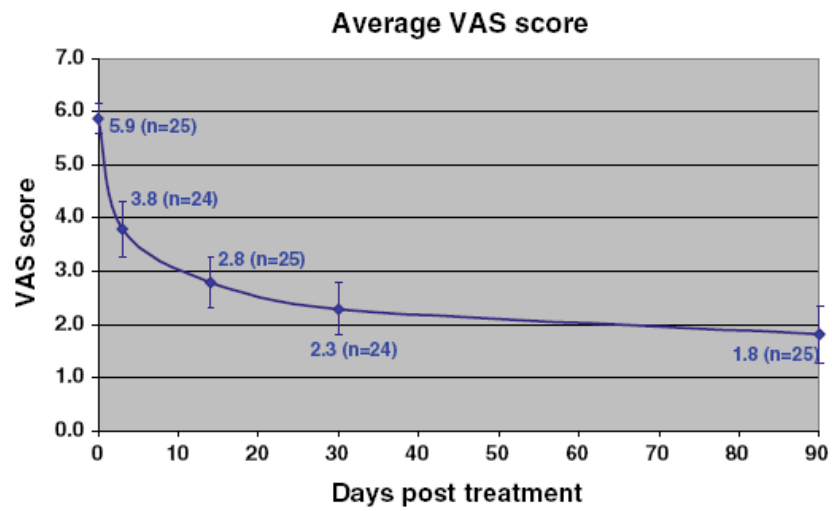

Liberman et al Ann Surg Oncol 16:140-6; 2009

Prostate Cancer- Endorectal System

- Endorectal phased array probe
- Steerable beam for focal spot size control (2 x 7mm to 10 x 30mm) for fast treatment and to prevent complications related to nerve bundle
- Combined pelvic and endorectal imaging coil for high resolution target definition

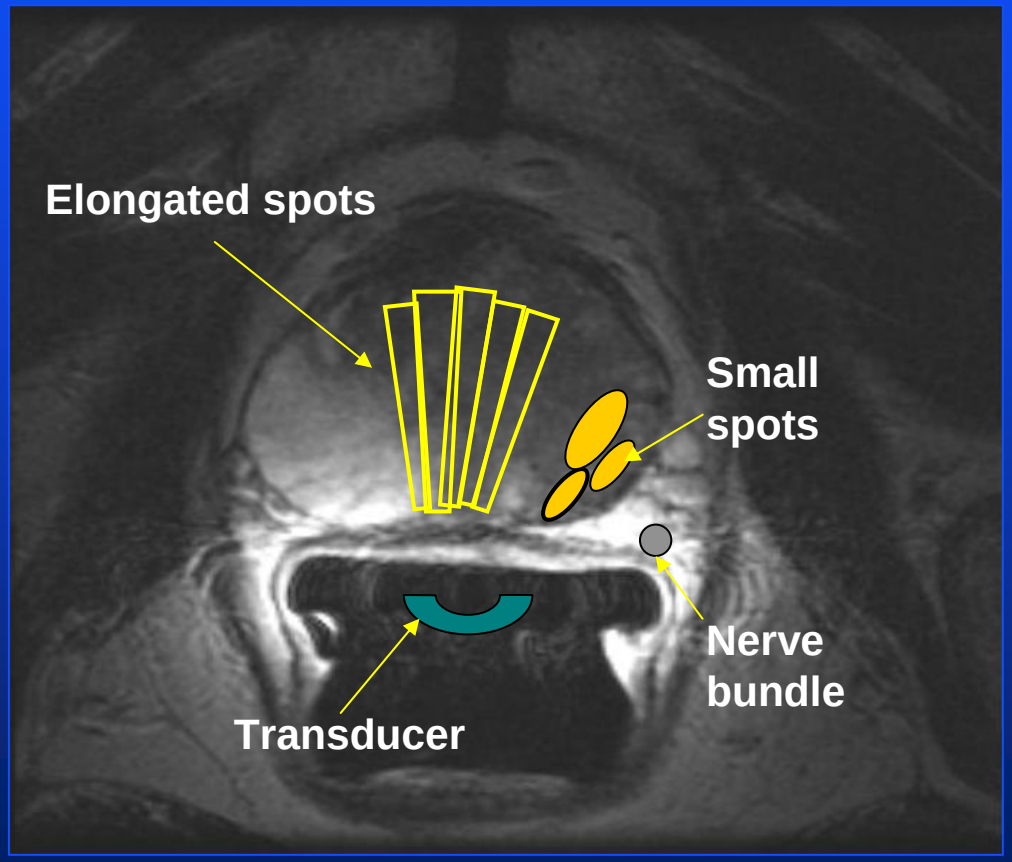

Steerable beam and spot size control

Animal Studies

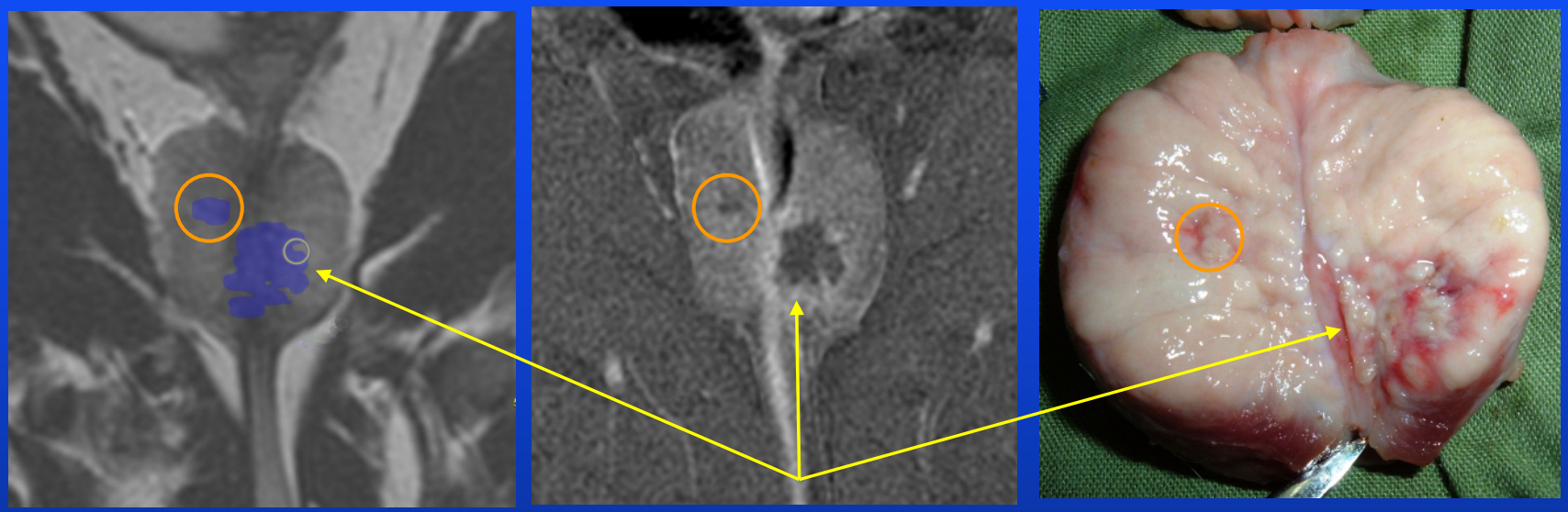

Accumulated thermal dose following FUS treatment shown on T2w MR coronal image

Contrast enhanced T1w subtraction image showing the lesion

Macro pathology image following the procedure showing the ablated areas

- Correlation between thermal dose, non-perfused volume (NPV) and gross pathology

Courtesy of Sheba Hospital, Tel-Aviv, Israel

MR guided **Pulsed** FUS for Enhancement of Local Gene/Drug delivery

- Enhancement of drug delivery to tumors with MRgFUS demonstrated in animals modes

  Nelson JL et al Cancer Res 62:7280-7283 (2002)
  Yuh EL et al Radiology 234(2): 431 – 437 (2005)
  Hynynen K. Expert Opin Drug Deliv 4(1):27-35, (2007)

- Mechanism: non-thermal effect (stable cavitation)
  → increase vascular, cell membrane permeability
  → concentrate macromolecular pharmaceutical agents to the treatment target without permanently damaging the tissue

- Applications of pulsed HIFU to enhance the delivery for cancer treatment in chemotherapeutic and gene therapy

Enhanced Drug Delivery

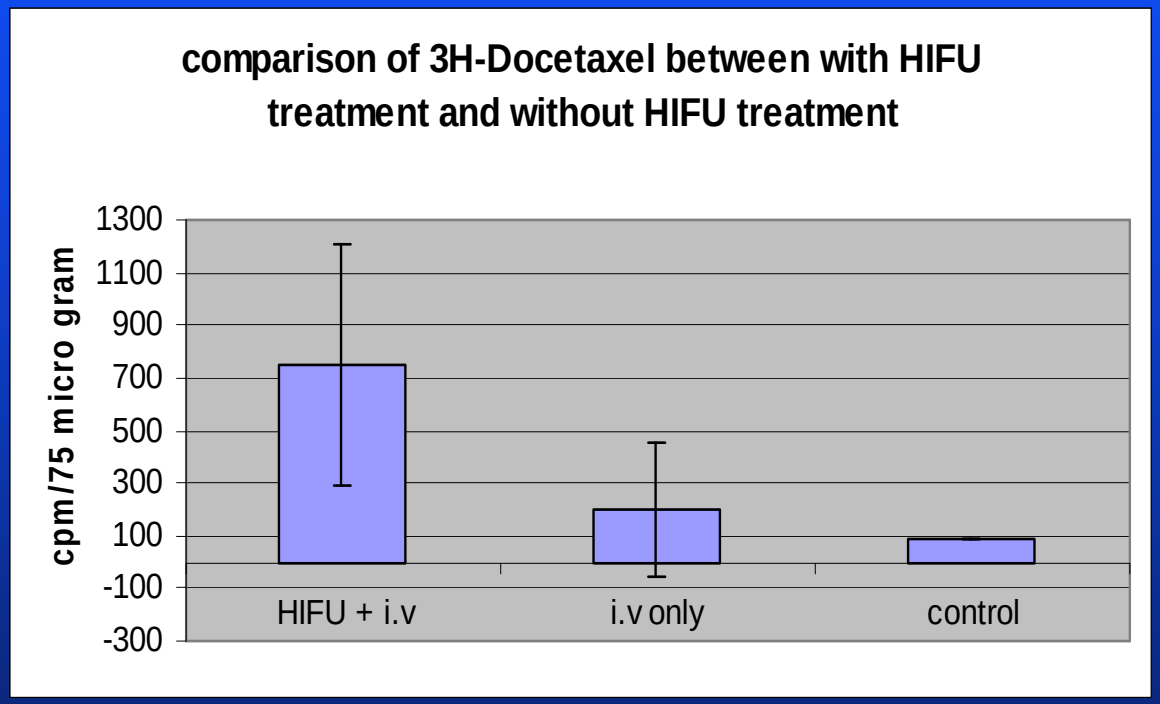

- Radioactive tritiated docetaxel used to determine the uptake in prostate tumor

Chen et al. at FCCC

Conclusions

- MRgFUS is a noninvasive, alternative therapeutic tool for cancer treatment
- Need large volume of published clinical data from multiple centers to support early experience
- Technological advances should help overcome some of the comparative limitations