Coronary Magnetic Resonance Imaging

Matthias Stuber, PhD

Associate Professor
Division of MRI Research
Johns Hopkins University
Baltimore, MD

- The Need for MRI

Background

- X-ray coronary angiograpy (gold standard)
  - Invasive
  - Radiation exposure for operator and patient
  - Small, but significant risk of complications
  - Substantial minority of patients are found to have no significant coronary stenosis (~30-50%)[1]
  - High procedural costs ($3000-$6000)[2]
  - Inability to identify early atherosclerotic disease
- Both in the USA and in Germany ~1 million x-ray coronary angiograms are performed each year[2]

[1]Budoff et al. *Circulation* 1996; 93: 898

[2]2002 AHA Heart and Stroke Statistical Update

Motivation

- Need for an *alternative*, *non-invasive*, more *cost efficient* & *patient friendlier* technique, which….
  - *Accurately detects significant (≥50%) CAD*
  - *Rules out non-significant CAD*
- ⇒ Coronary Magnetic Resonance Angiography (MRA)

- Challenges

Technical Challenges

- Small caliber & geometry of the coronary arteries
  - Necessitates a *high spatial resolution* & sufficient *volumetric coverage.*
- Contrast
  - Contrast enhancement between coronary blood-pool, and surrounding tissue (epicardial fat, myocardium).
- Myocardial motion
  - Effective suppression of intrinsic (RR-interval) and extrinsic (respiration) myocardial motion.

Technical Challenges

Intrinsic: Cardiac cycle: ~60/min; ~2cm
Extrinsic: Respiratory cycle: ~12/min; ~2cm

Expiration

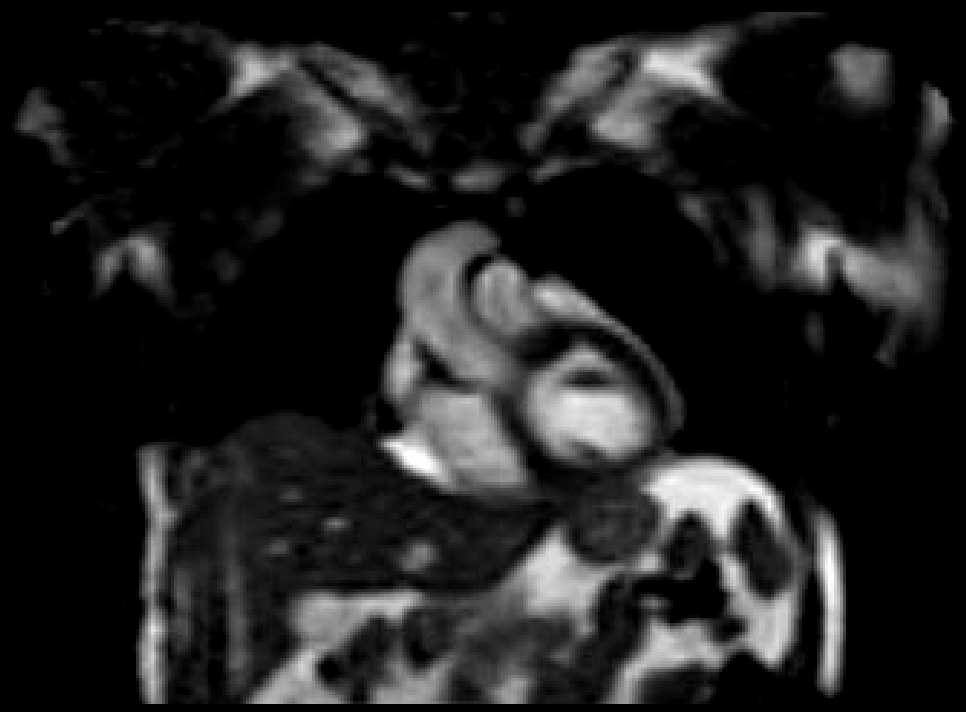

Inspiration

32cm

- Solutions

Technical Challenges & Solutions

- No motion suppression
- No contrast enhancement

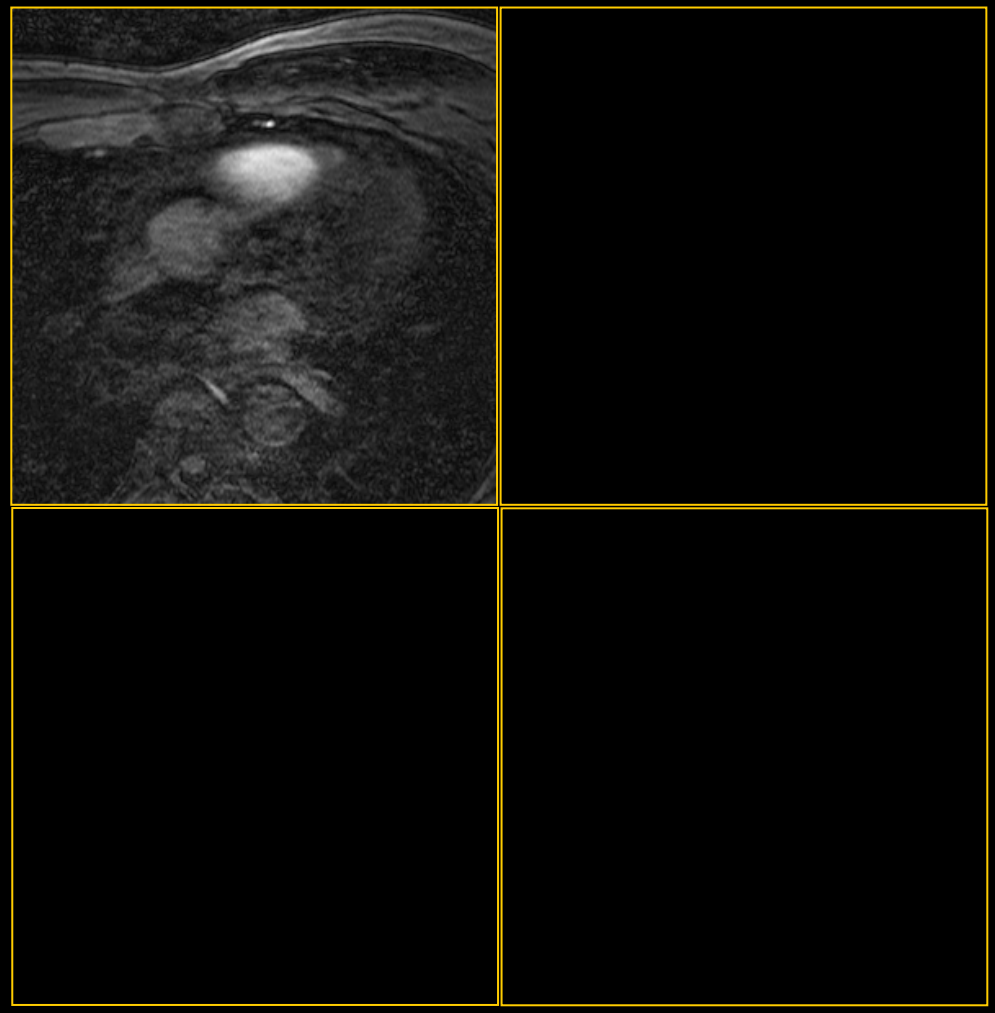

Technical Challenges & Solutions

- Suppression of *intrinsic* myocardial motion
  - *ECG triggering*, *segmentation* of data acquisition[1], *late diastolic* image acquisition[2]

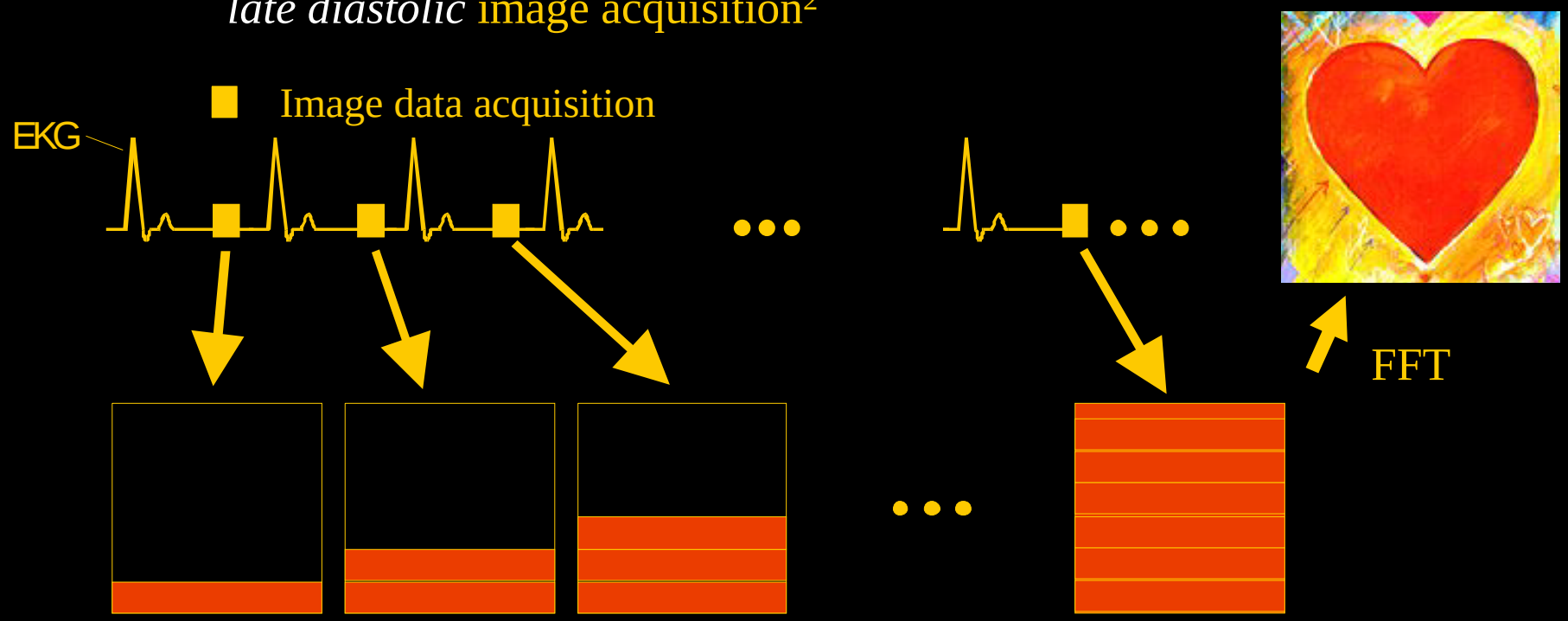

1) Edelman RR, Manning WJ, Burstein D. et al.: *Radiology* 181(3); 641-643 (1991).
2) Kim WY, Stuber M, Kissinger KV. et al.: *J Magn Reson Imaging* 14(4); 683-690 (2001).

Technical Challenges & Solutions

- No motion suppression
- No contrast enhancement

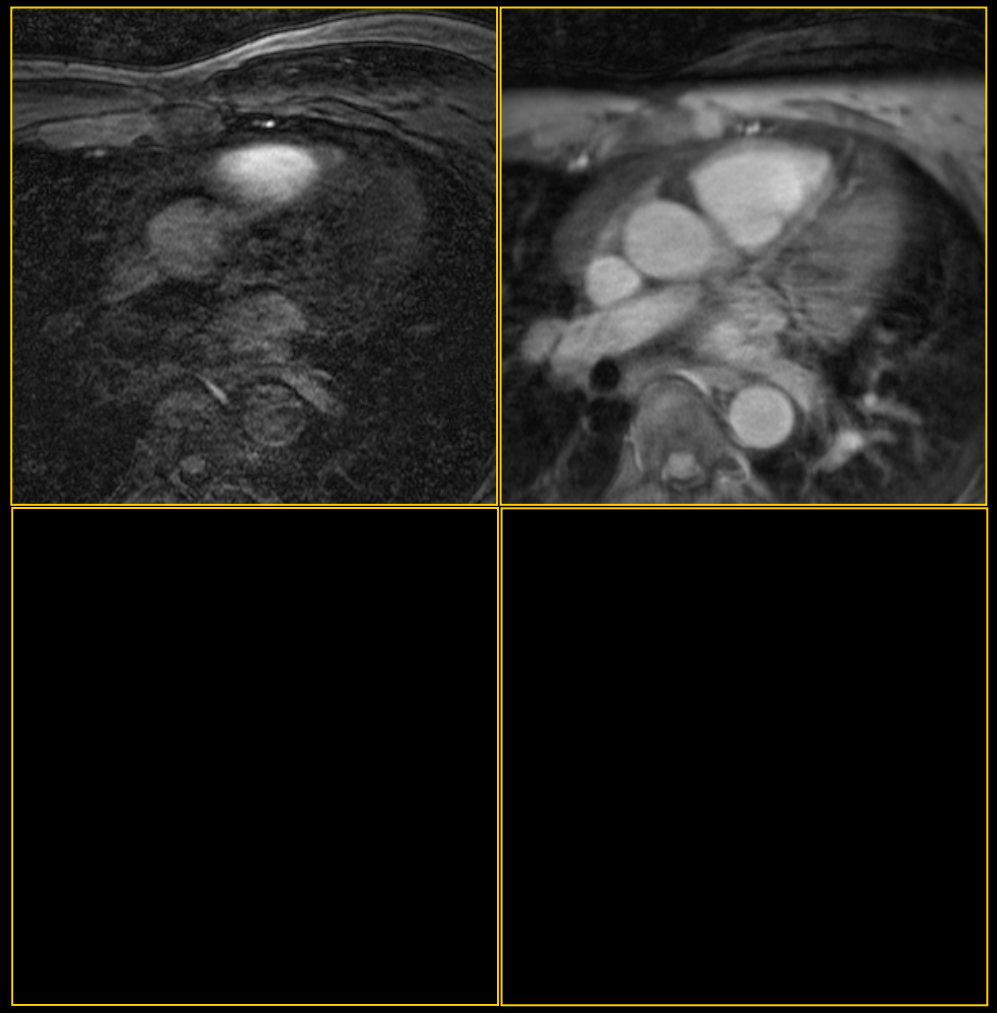

- ECG triggering
- No resp. mot. suppression
- No contrast enhancement

Technical Challenges & Solutions

- Suppression of *extrinsic* myocardial motion
  - Breath-holding[1]
  - Serial averaging[2]
  - Bellows gating[2]
  - Navigators[2,3]
  - ‘Self’ Navigation[4]
  - Hybrid (Navigators & Breath-hold)[5]

1) Edelman RR, Manning WJ, Burstein D. et al.: *Radiology* 181(3); 641-643 (1991).
2) Oshinski JN, Hofland L, Mukundan S. et al.: *Radiology* 201(3); (1996).
3) Li D, Kaushikkar S, Haacke, EM. Et al.: *Radiology* 201(3); (1996).
4) Hardy CJ, Saranathan M, Zhu Y. et al.: *Magn Reson Med*. 2000 Dec;44(6):940-946.
5) Huber M, Oelhafen M, Kozerke S. et al.: *J Magn Reson Imaging* 15(2); 210-214 (2002).

Technical Challenges & Solutions

- Suppression of *extrinsic* myocardial motion
  - Breath-holding
    - Diaphragmatic drift/registration errors in serial breath-holds (~1cm)[1]
    - Major operator and patient involvement
    - Patient compliance

      → *Applicability to patients with coronary disease is limited*

      → *Removed flexibility for* ***enhanced spatial resolution***

  ⇒ **Free-breathing approaches**

1) Danias PG, Stuber M, Botnar, RM et al.: *Am J Roentgenol*, 171(2):395-397, (1998).

Technical Challenges & Solutions

- Suppression of *extrinsic* myocardial motion
  - MR navigator technology: **Navigator gating & tracking**[1]

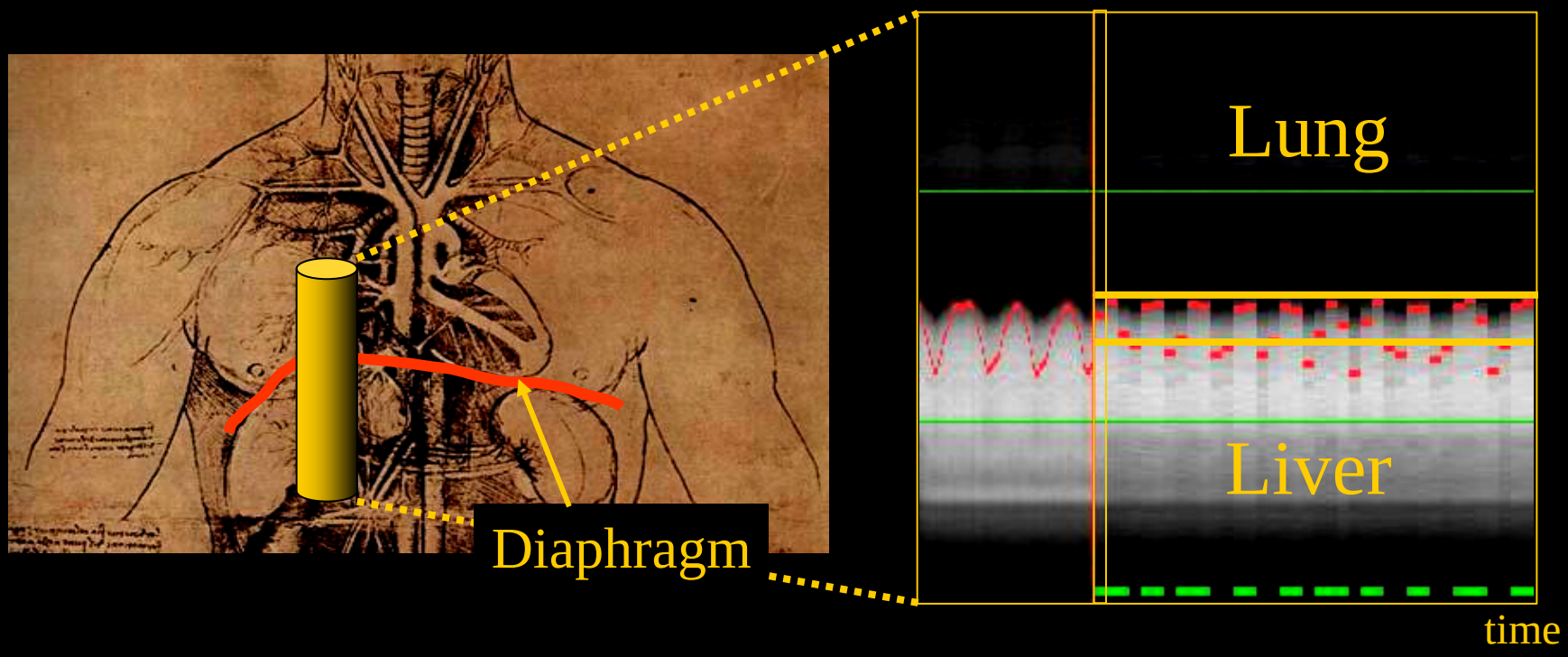

1.) McConnell et al.: *Magn Reson Med* 37(1); 148-152 (1997).

Technical Challenges & Solutions

- No motion suppression
- No contrast enhancement

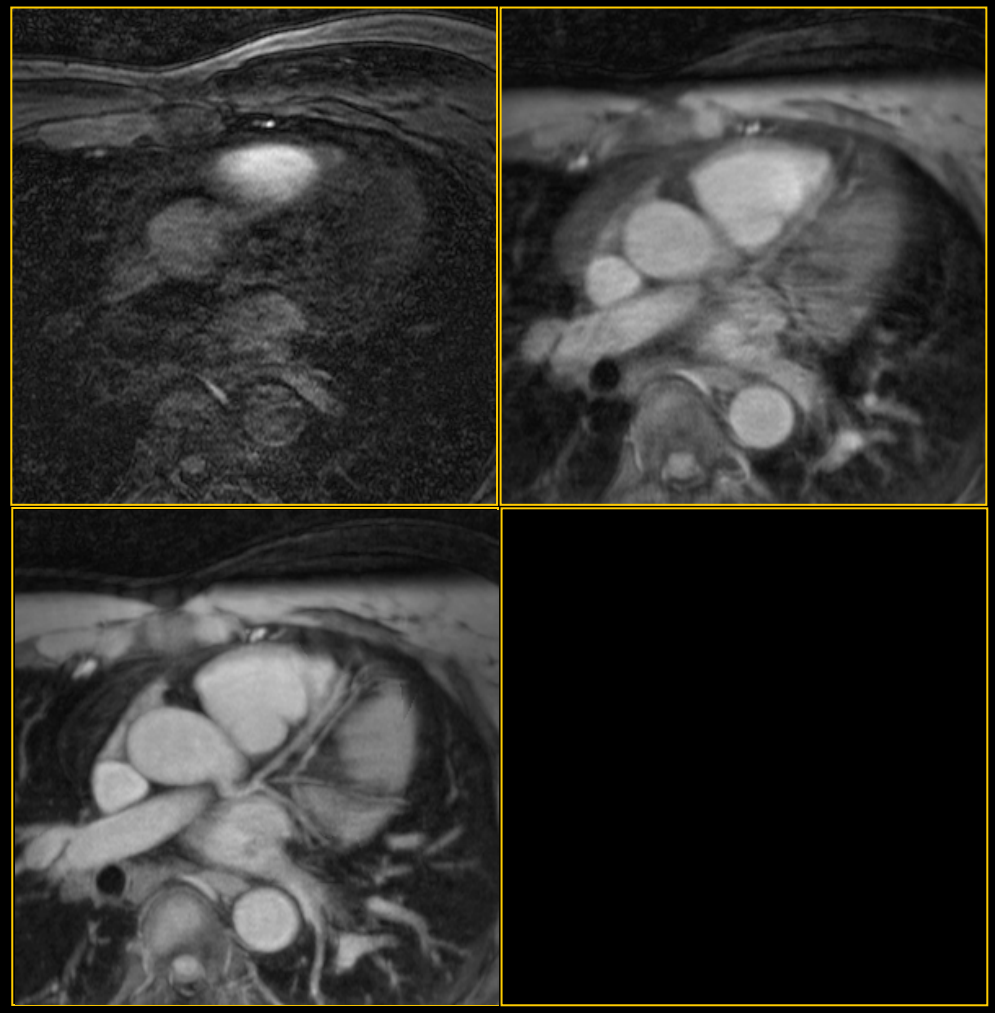

- ECG triggering
- No resp. mot. suppression
- No contrast enhancement

- ECG triggering
- Navigator & free breathing
- No contrast enhancement

Contrast Generation

- Contrast enhancement (lumen *blood-pool* and surrounding *epicardial fat*, *myocardium*).

	T1 [ms]	T2 [ms]	$\Delta\omega_0$ [Hz]	flow
Blood	1200	250	0	yes
Muscle	850	50	0	no
Fat	250	100	220	no

Technical Challenges & Solutions

- Contrast enhancement
  - Endogenous contrast enhancement (T2Prep)

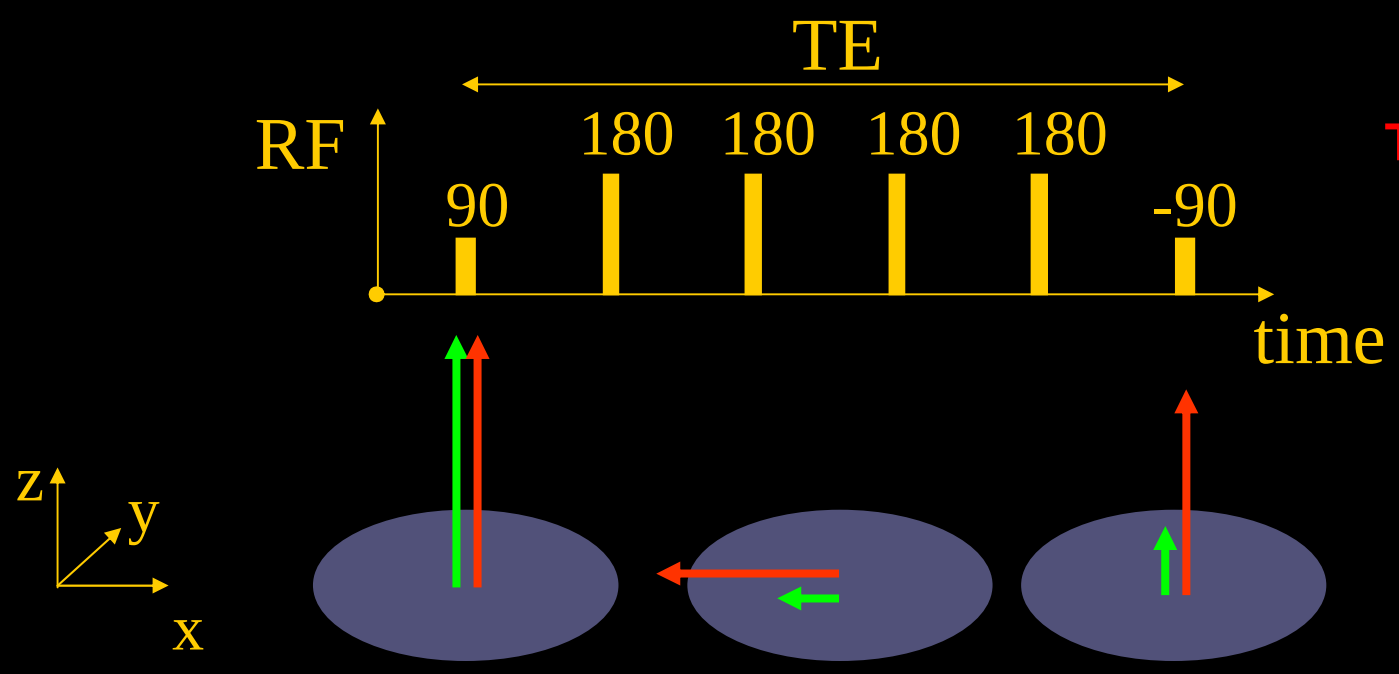

$T2_{Myo}$: 50ms

$T2_{Blood}$: 250ms

1) GA Wright, DG Nishimura, A Macovski, *Magn Reson Med* 17:126-140 (1991).
2) JH Brittain, et al., *Magn Reson Med* 33:689-696 (1995).

Technical Challenges & Solutions

- No motion suppression
- No contrast enhancement

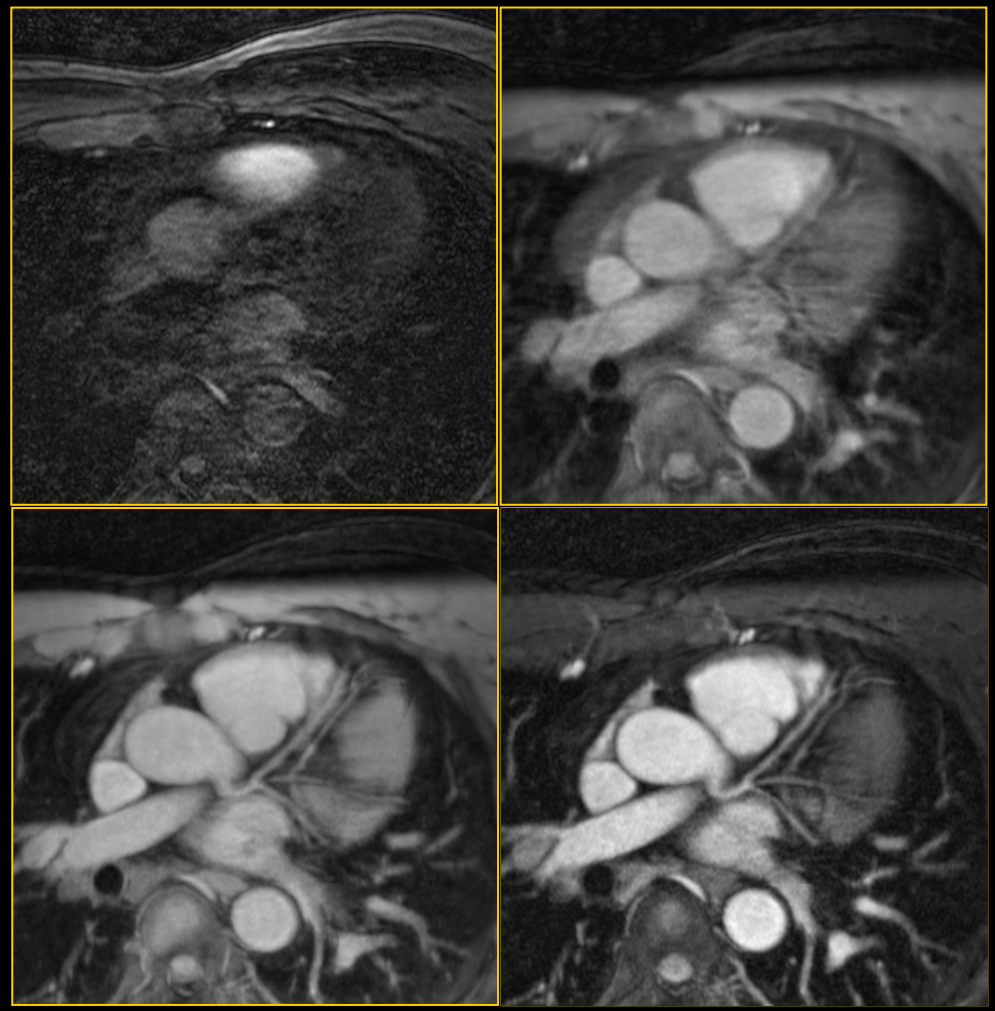

- ECG triggering
- No resp. mot. suppression
- No contrast enhancement

- ECG triggering
- Navigator & free breathing
- No contrast enhancement

- ECG triggering
- Navigator
- T2Prep

- State-of-the-Art & Comparison to Gold Standard

Technical Challenges & Solutions

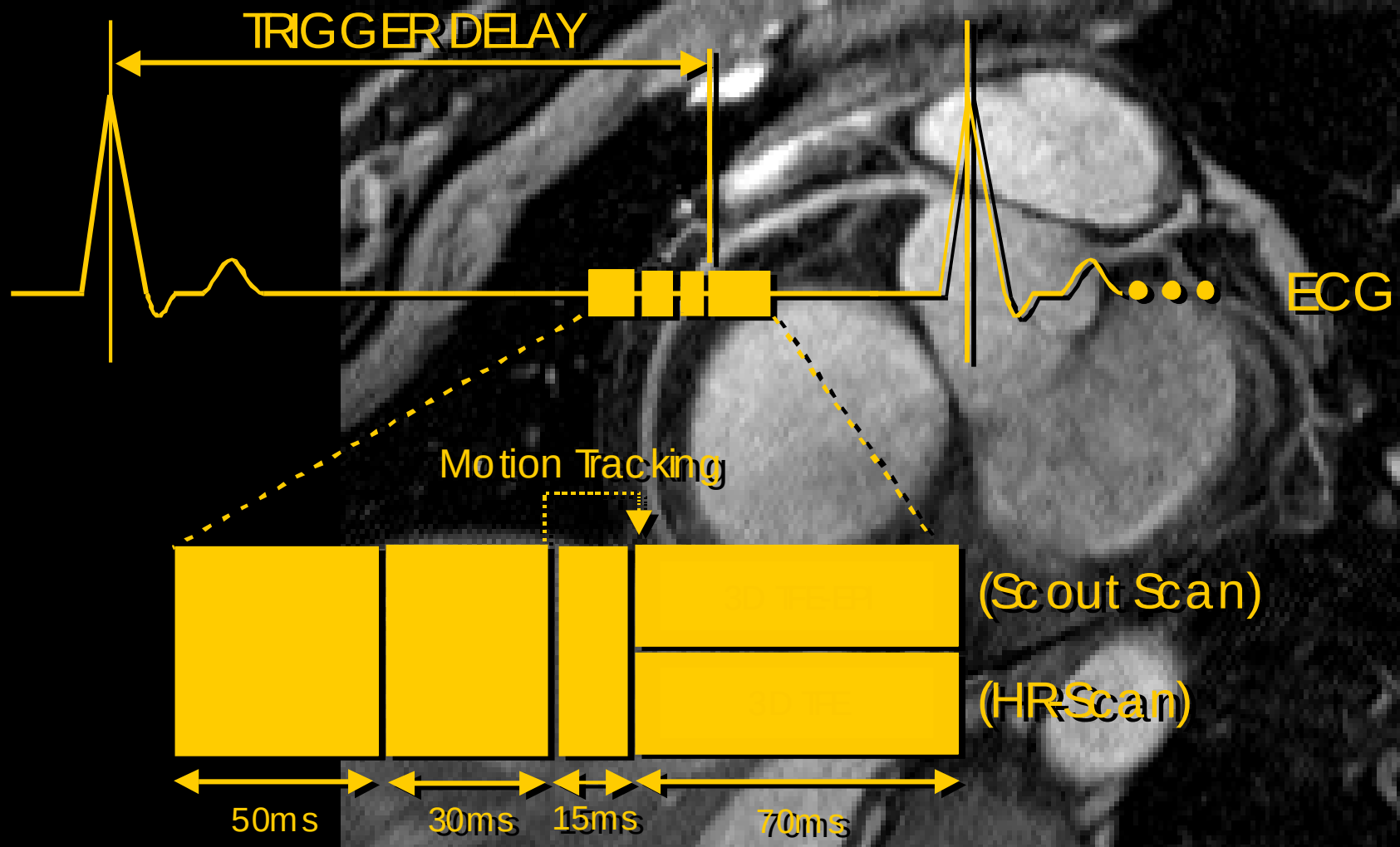

1) Stuber M, Botnar RM, Danias PG et al.: *J Am Coll Cardiol*; 34(2):524-531 (1999).

Single Center Coronary MRA Results*

* Navigators & free breathing

Study (n)	Sensitivity	Specificity
Sandstede'99 (23)	81	89
Huber'99 (?)	73	50
Sardinelli'00 (39)	90	90
Lethimonnier'99 (20)	65	93
Ikonen'00 (14)	84	70
Sommer'02 (77)	81	97

Adapted from: Sommer et al.: Rofo Fortschr Geb Rontgenstr N 2002; 459-466

Multicenter Coronary MRA Study

- Purpose & Methods
  - Using uniform hardware, software & methodology[1,2], to examine the sensitivity, specificity, PPV, NPV of coronary MRA for the diagnosis of significant disease of the proximal coronary arteries.
  - Prospective comparison with gold standard (MR prior to X-Ray coronary angiography, independent core lab)
  - 109 patients from 8 international centers in Philips Cardiac MR Users network.

1) Stuber M, Botnar RM, Danias PG et al.: *J Am Coll Cardiol*; 34(2):524-531 (1999).
2) Botnar RM, Stuber M, Danias PG et al.: *Circulation*; 99(24):3139-3148 (1999).

Multicenter Coronary MRA Results*

* Navigators & free breathing

- Results (Detection of >50% stenosis, n=109)

	Any CAD [%]	**LM/3VD [%]**
Sensitivity	93	100
Specificity	42	85
PPV	70	54
NPV	81	100

1) Kim WY, Danias PG, Stuber M. et al.: *N Engl J Med*;345(26):1863-1869 (2001).

Multicenter Coronary MRA Study

Aarhus Berlin Boston Leiden

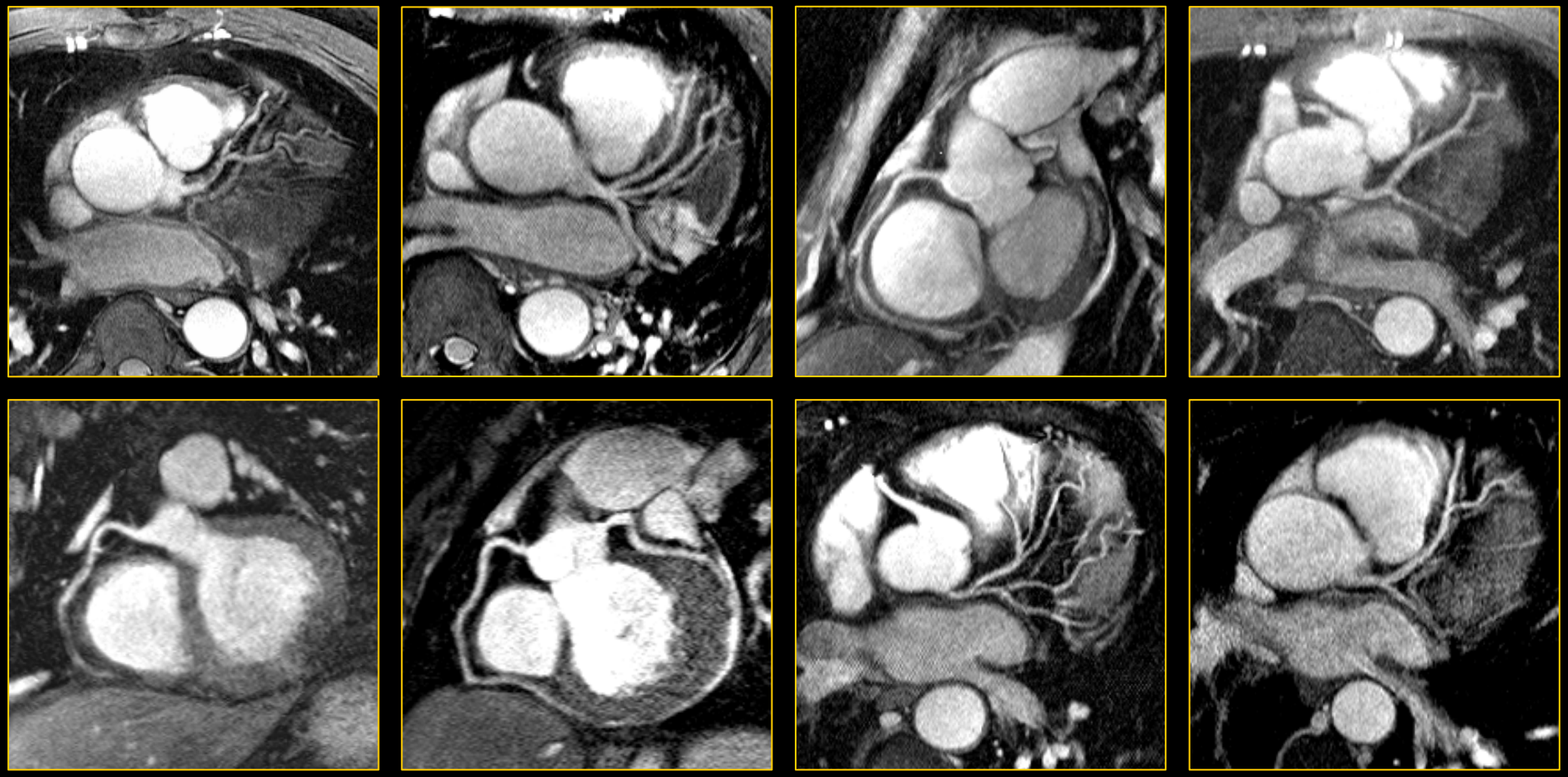

Köln Texas Leeds Zürich

1) Kim WY, Danias PG, Stuber M. et al.: N Engl J Med;345(26):1863-1869 (2001).

Multicenter Coronary MRA Study

Patient with LM/LAD & LCX disease

Patient with 2 lesions in proximal RCA

1) Kim WY, Danias PG, Stuber M. et al.: *N Engl J Med*;345(26):1863-1869 (2001).

Multicenter Coronary MRA Study

- Conclusions
  - Among patients referred for elective coronary angiography, coronary MRA with real-time navigator technology and T2Prep
    - Accurately detects significant (≥50% lumen ∅) coronary artery disease[1].
    - Reliably rules out non-significant coronary artery disease[1]

1) Kim WY, Danias PG, Stuber M. et al.: *N Engl J Med*;345(26):1863-1869 (2001).

Multicenter Coronary MRA Study

- Conclusions

$\Rightarrow$ There is a need for *alternative methods* which

- ultimately improve specificity of coronary MRA in general
- provide additional/different information
- support access to more distal/branching vessels
- Enables visualization of atherosclerotic disease that precedes lumen-narrowing

1) Kim WY, Danias PG, Stuber M. et al.: *N Engl J Med*;345(26):1863-1869 (2001).

- Outlook and Promise

Works in Progress and Outlook

- *Alternative methods* include
  - Contrast agents for coronary MRA
  - SSFP coronary MRA
  - ‘Whole heart’ imaging
  - Arterial spin labeling
  - Interventional coronary MRI
  - Coronary vessel wall imaging, atherosclerosis & molecular imaging
  - High field (3T) coronary MRI

- CONTRAST AGENTS

Contrast Generation

- Contrast agents (Blood-Pool Agents)

	T1 [ms]	T2 [ms]	$\Delta\omega_0$ [Hz]	flow
Blood	~100	250	0	yes
Muscle	~300	50	0	no
Fat	250	50	250	no

Contrast Generation

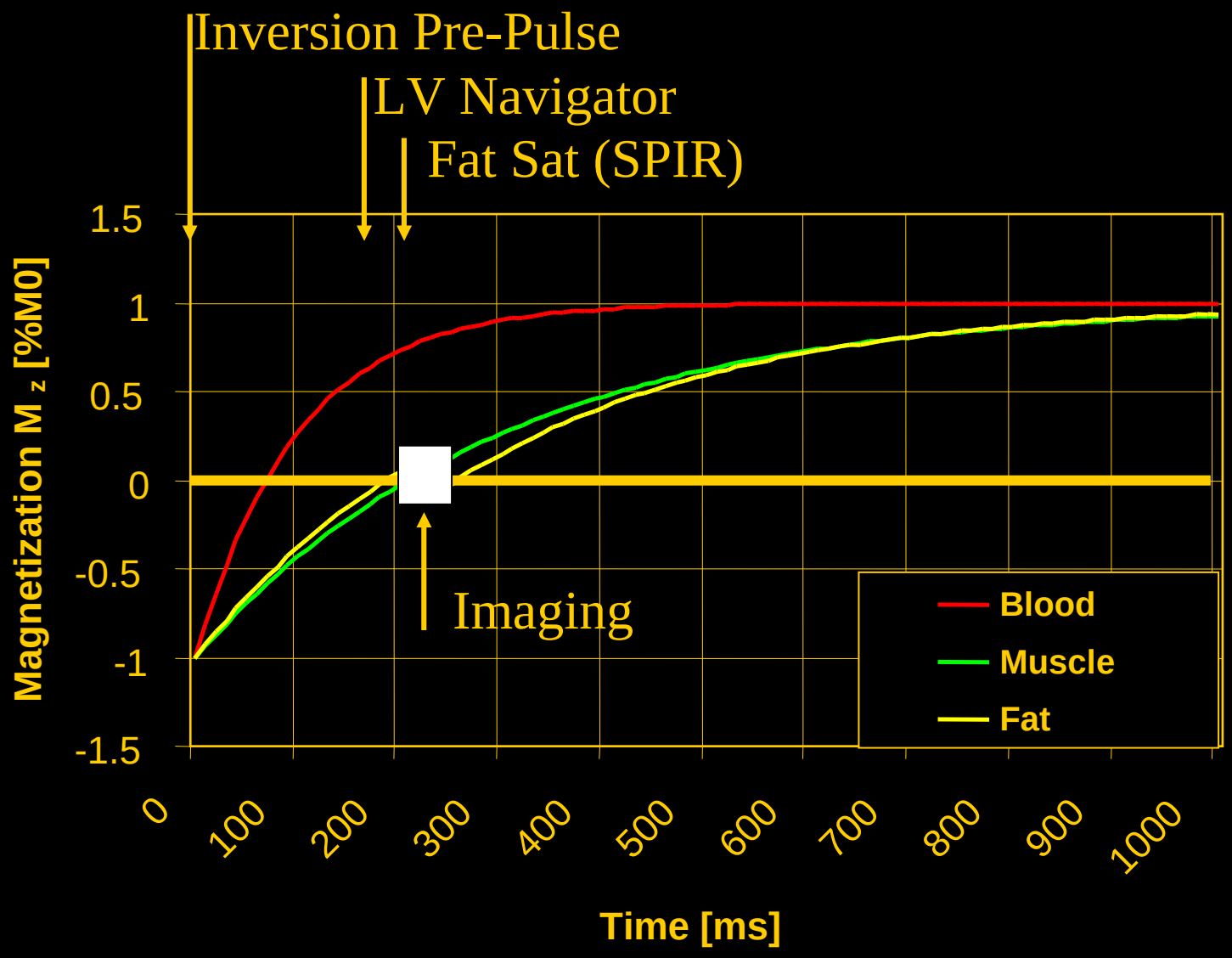

Contrast Generation

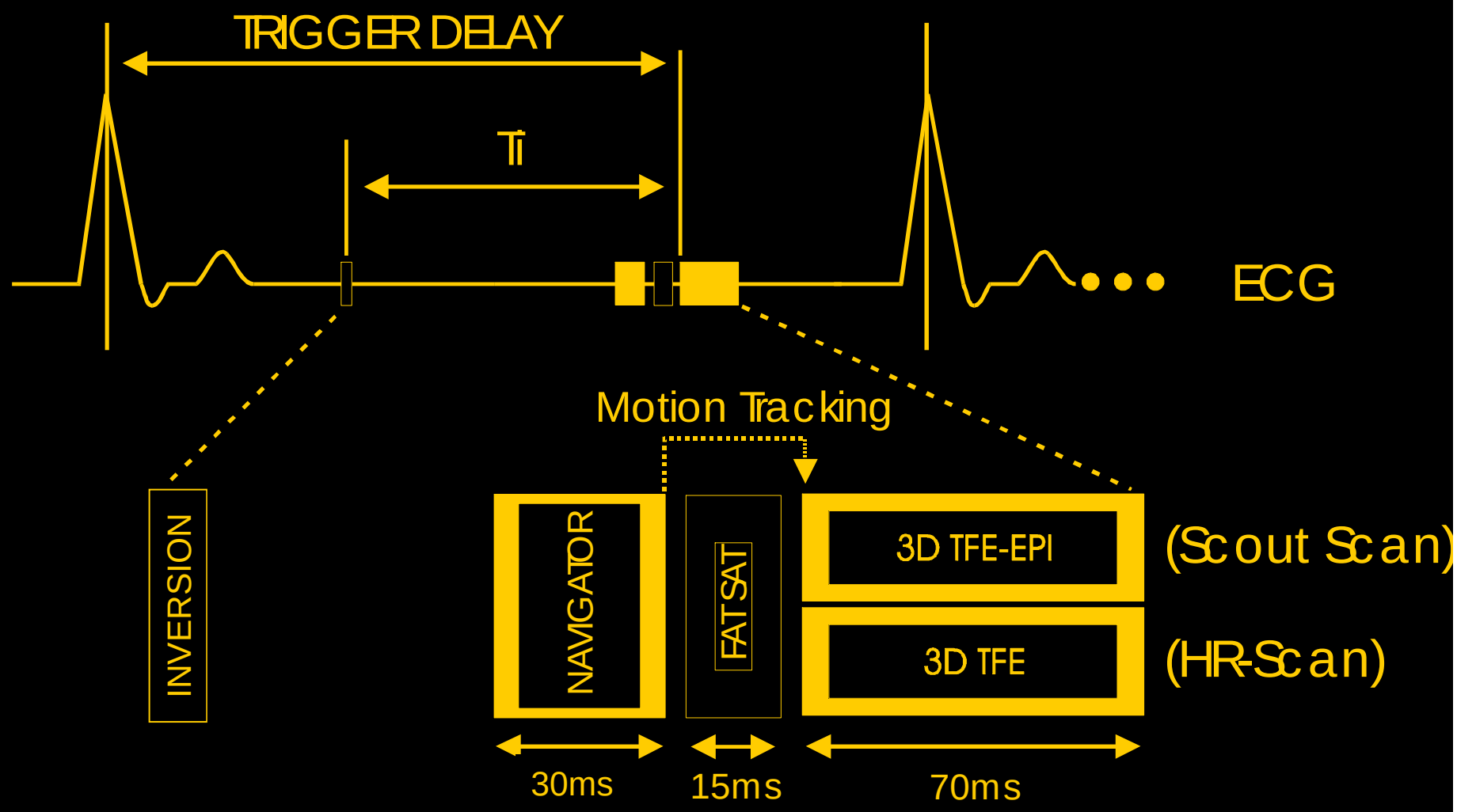

1) Stuber M, Botnar RM, Danias PG et al.: *J Magn Reson Imaging*; 10(5):790-799 (1999).

Intravascular Contrast Agent

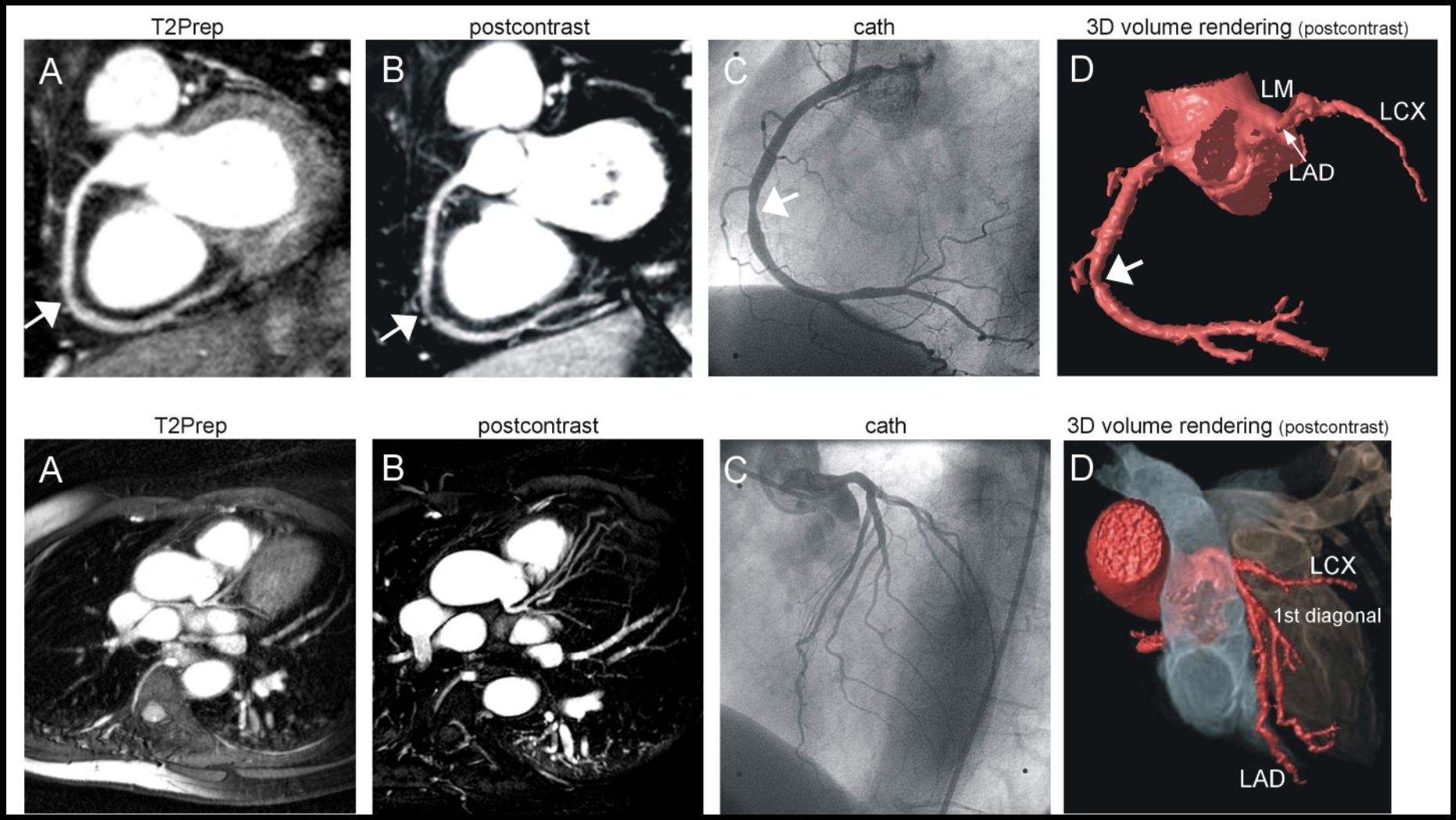

Huber et al.: *Magn Reson Med;* Magn Reson Med. 2003 Jan;49(1):115-21

Courtesy: Paetsch I, Nagel E, Fleck E; Deutsches Herzzentrum Berlin

- Coronary Vessel Wall Imaging

Background

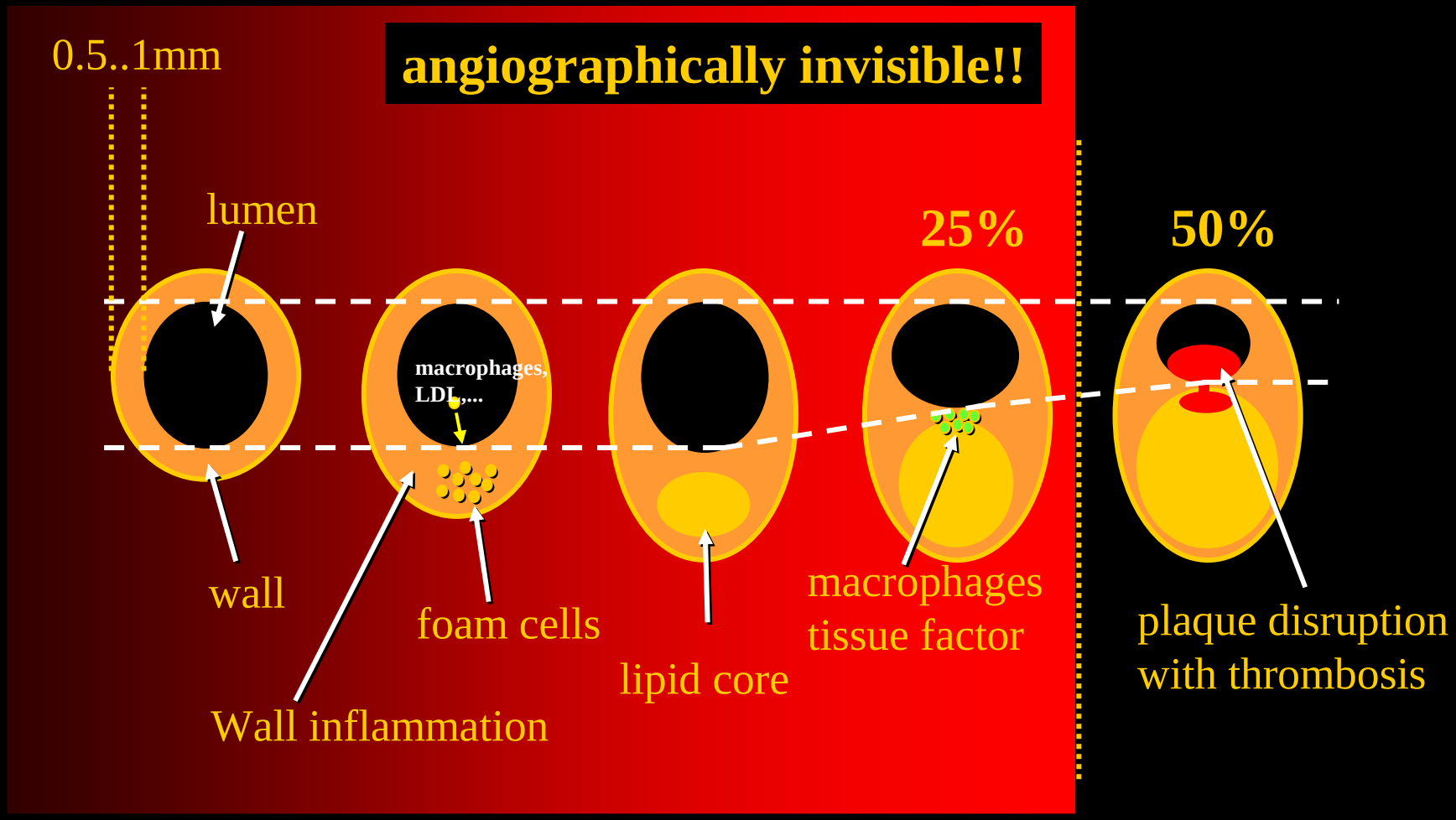

1) Glagov S, Weisenberg E, Zarins CK et al.: *N Engl J Med* 316(22); 1371-1375 (1987).

Introduction

- MRI has demonstrated ability to visualize the vessel wall and its components (carotids, aorta)[1-3]

- Coronary vessel wall imaging is technically very challenging
  - *Small dimensions*
  - *Constant motion*
  - *Contrast ?*

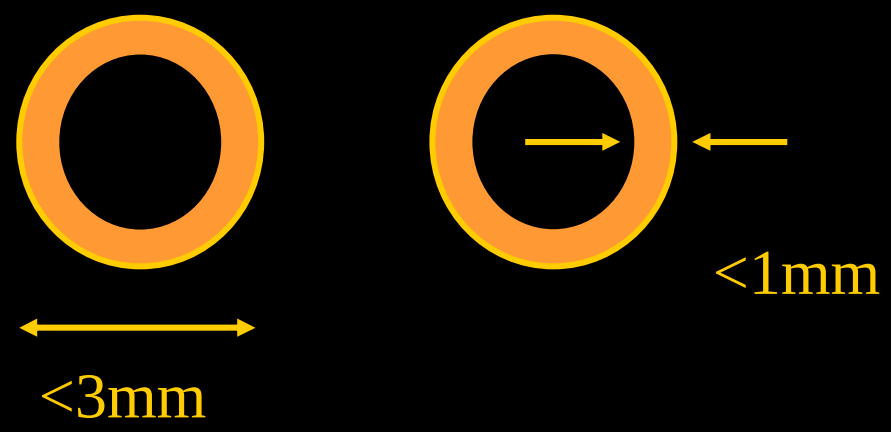

1) Toussaint JF, LaMuraglia GM, Southern JF et al.: *Circulation* 94(5);932-938 (1996).
2) Wasserman BA, Smith WI, Trout HH et al.: *Radiology* 223; 566-573 (2002).
3) Yuan C, Kerwin WS, Ferguson MS et al.: *J Magn Reson Imaging* 15; 62-67 (2002).

Methods: Contrast Generation

- Contrast enhancement concept: ‘Dual inversion’

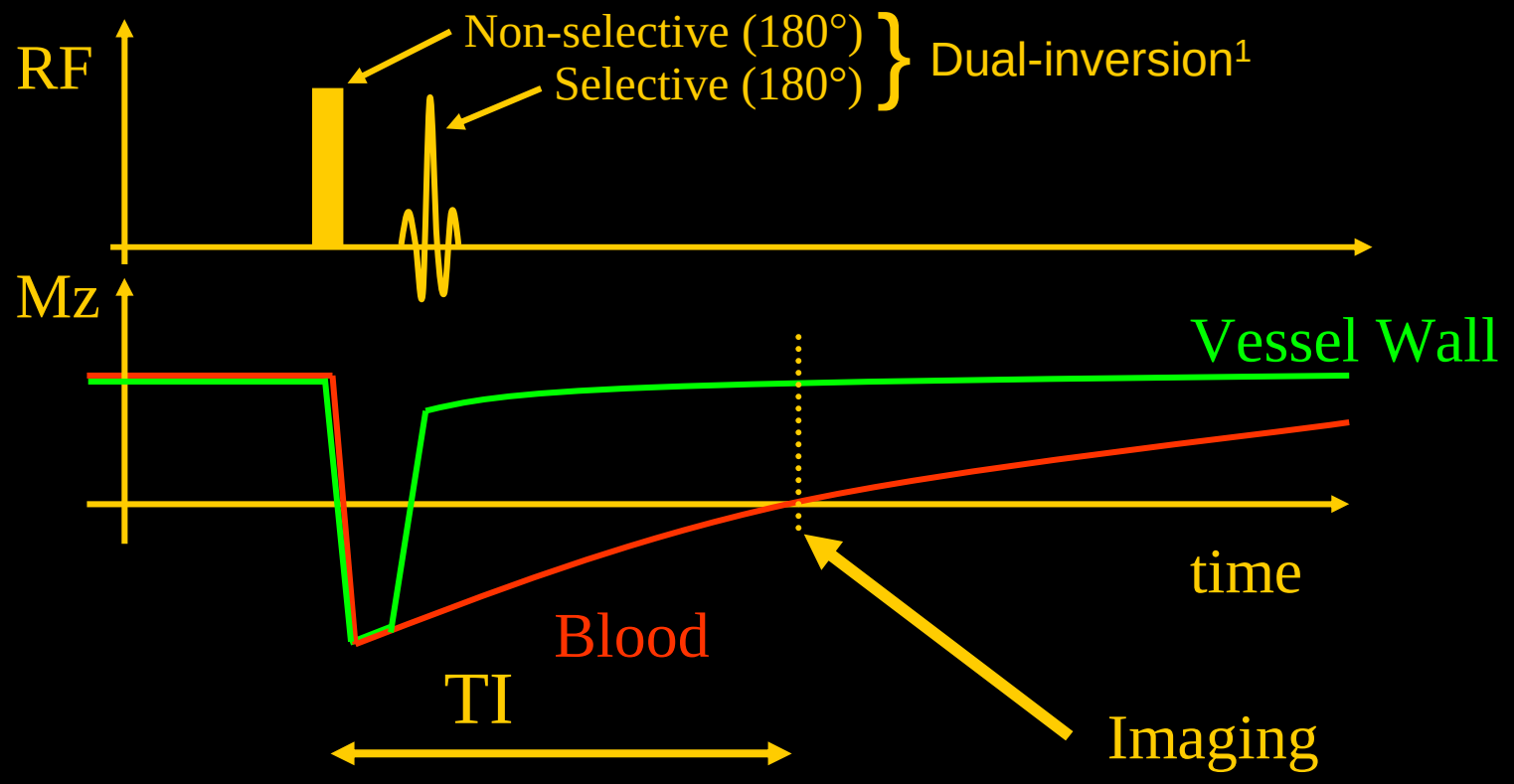

1) Edelman RR, Chien, D, Kim D: *Radiology*; 181(3); 655-660 (1991).

Methods: Motion Suppression

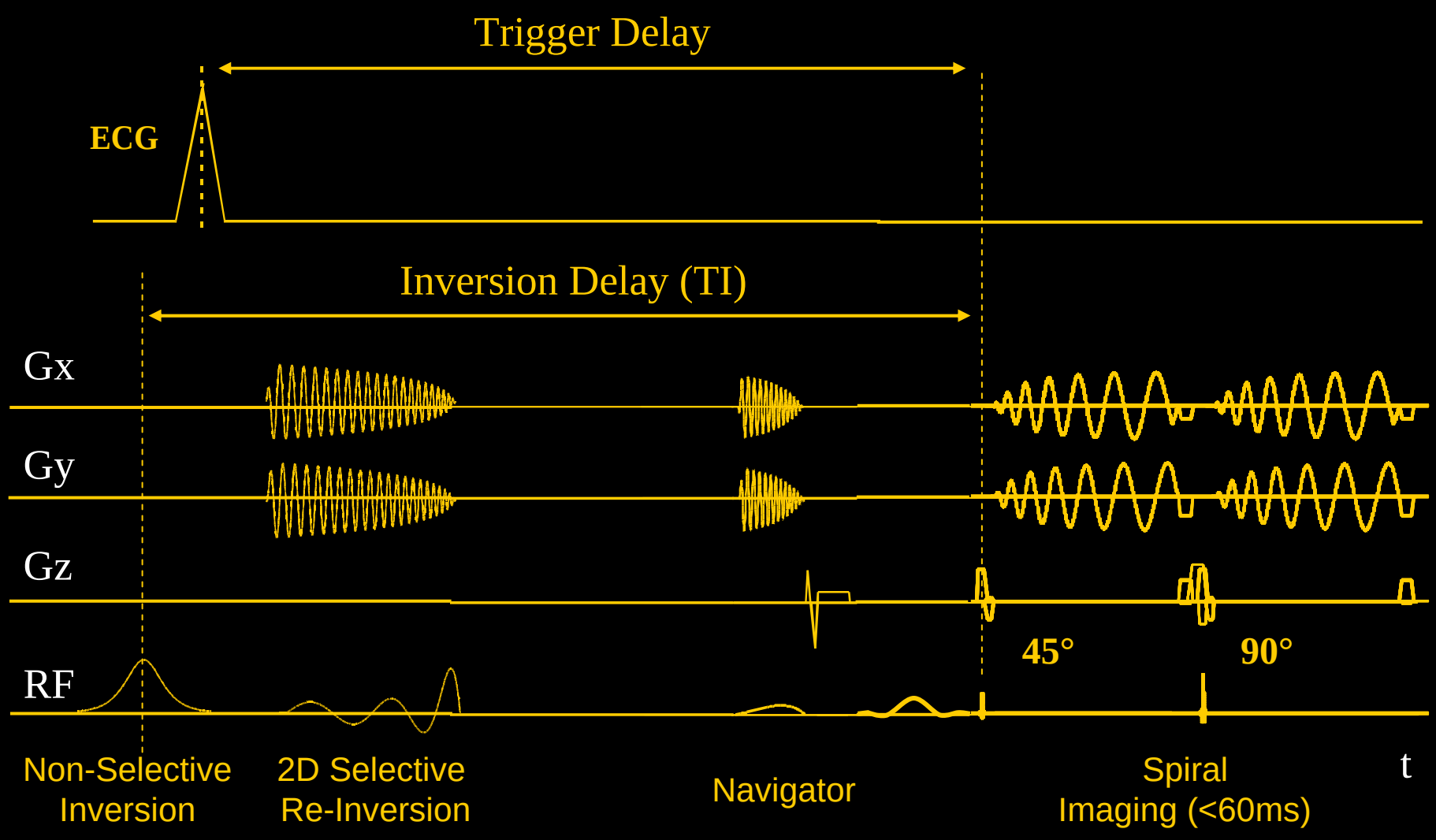

Coronary Vessel Wall Imaging

3D SSFP

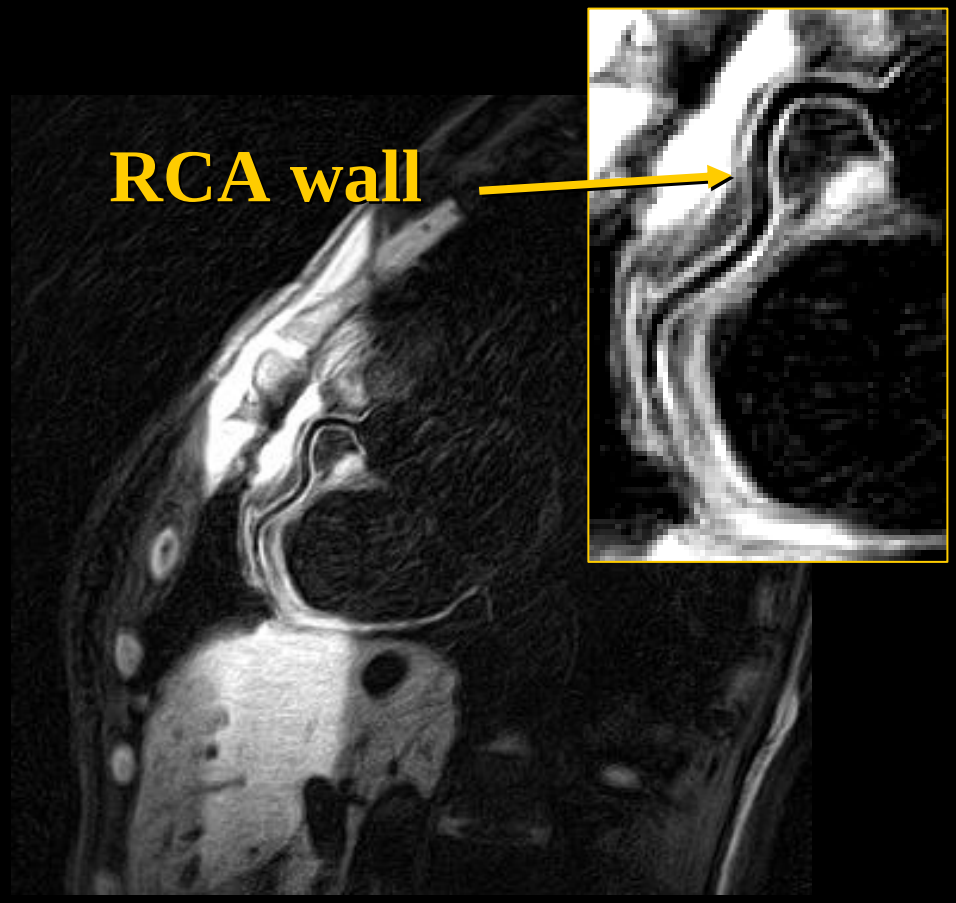

4th Order Local Inversion & 3D Spiral

79y old patient with ”luminal irregularities” in RCA

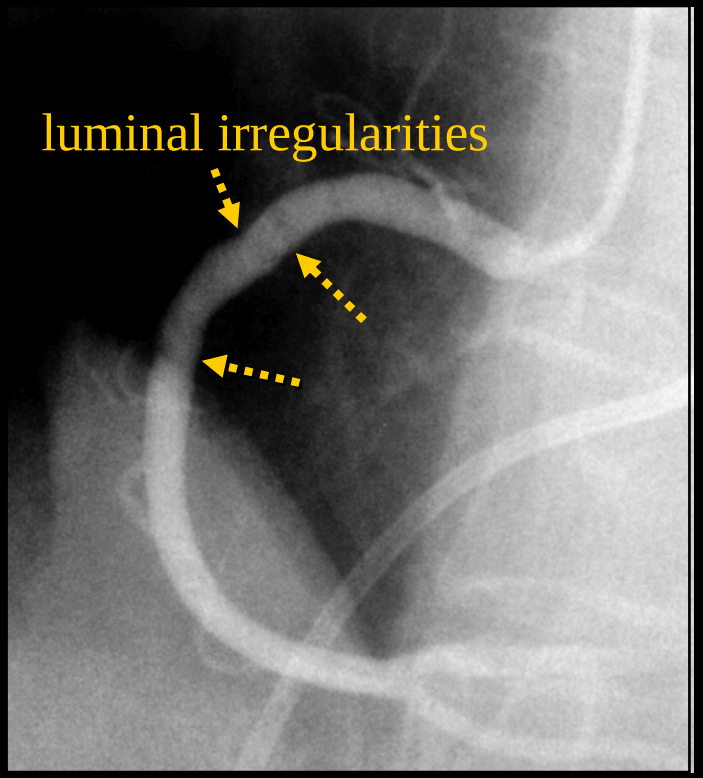

X-ray

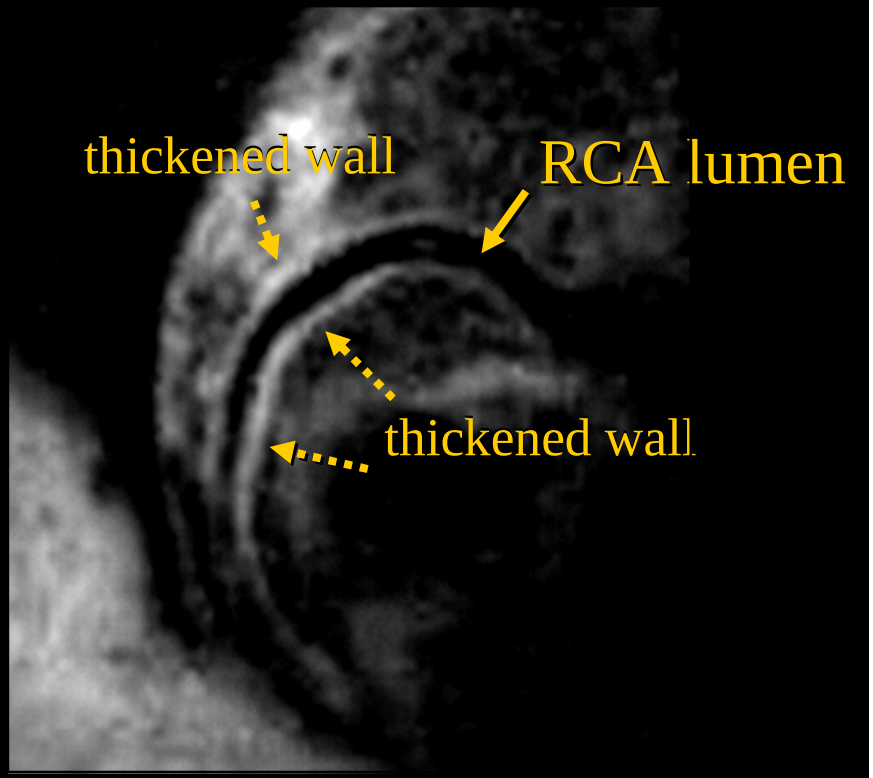

MR wall image

* Botnar RM et al.: *Magn Reson Med* 2001 Nov;46(5):848-54 2002

* Kim W, Stuber M, Manning WJ et. Al.: *Circulation* 2002

RCA Vessel Wall Thickness

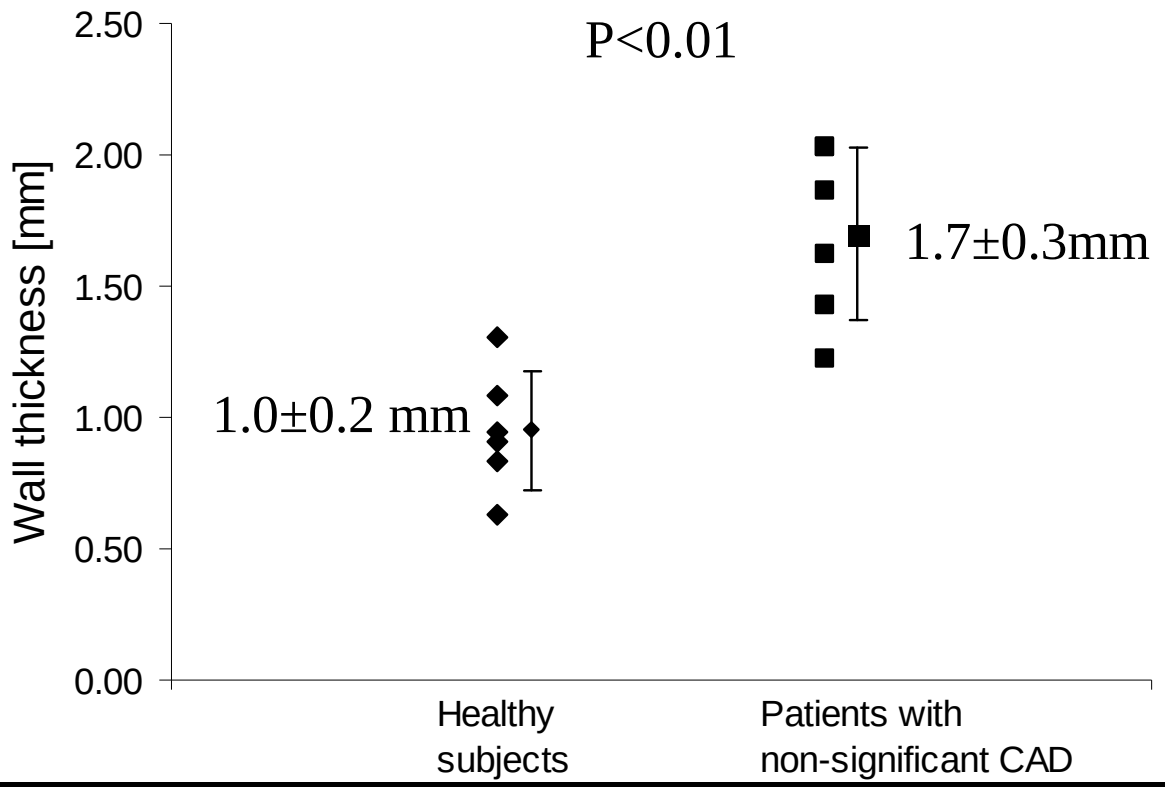

* Kim W, Stuber M, Manning WJ et. Al.: *Circulation* 2002

RCA Lumen Diameter

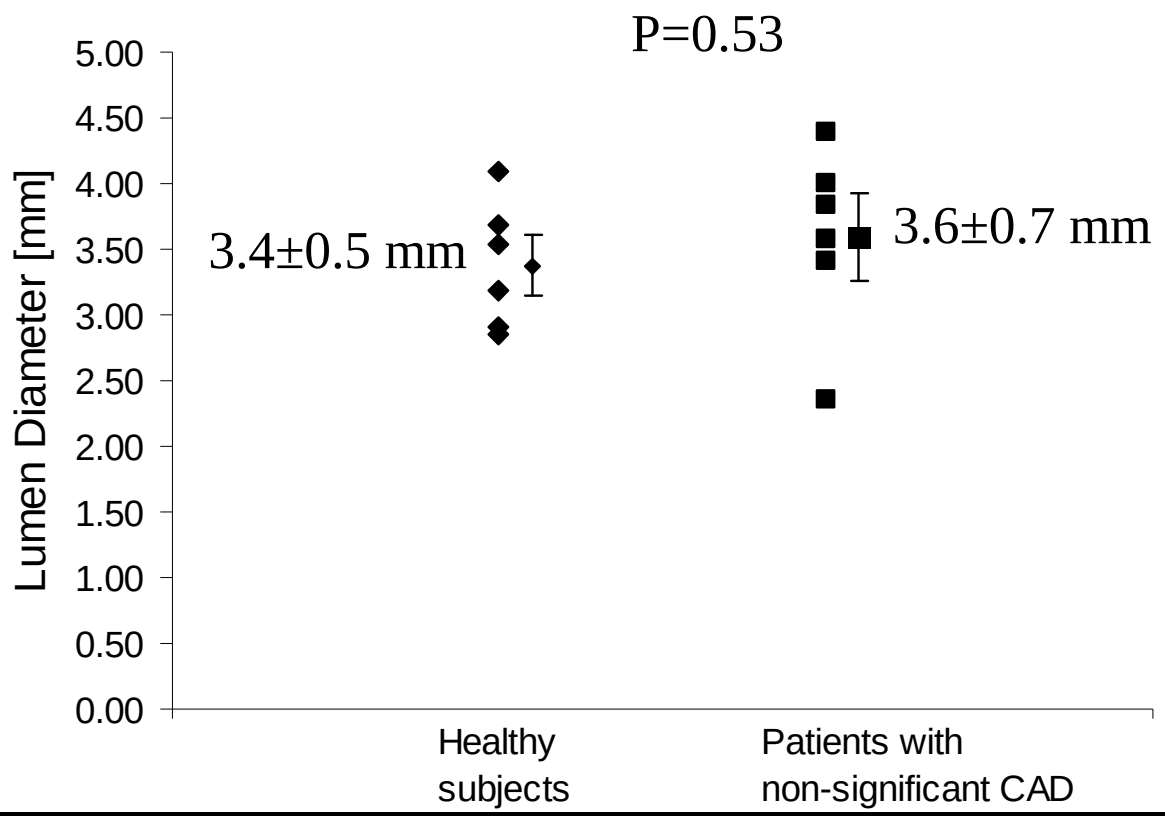

* Kim W, Stuber M, Manning WJ et. Al.: *Circulation* 2002

- High-Field Coronary MRA

Coronary MRA at 3 Tesla

(0.34x0.35x1.5mm voxel size)

- → **MR System**
  - → Philips 3T Achieva
  - → Dual Quasar Gradient System
  - → 6-Element Cardiac SENSE Coil
- → **Imaging Sequence**
  - → 3D TFE
  - → TE/TR: 2.3/7.6ms
  - → Matrix/FOV: 800/270mm
  - → Acquired Voxel Size: 0.34x0.35x1.5mm
  - → Reconstructed Voxel Size: 0.26x0.26x0.75mm
  - → Fat Saturation
- → **Motion Suppression**
  - → *FREEZE* (automated prescription of diastolic rest period)
  - → VECG
  - → Free-Breathing & Real-Time Navigator

M. Stuber, A. Ustun, R.G. Weiss, JHU