Joint Imaging-Therapy Symposium

Imaging, Guidance, and New Technologies in IG Interventions

Jeff Siewerdsen, PhD
Department of Biomedical Engineering
Johns Hopkins University

David Hawkes, PhD
University College
London UK

Paul Keall, PhD
Department of Radiation Oncology
Stanford University

THE DEPARTMENT OF BIOMEDICAL ENGINEERING

DQE → FDK → TRE

These and Other TLAs in the Development of New Technologies for Image-Guided Surgery

Jeff Siewerdsen, PhD
Department of Biomedical Engineering
Johns Hopkins University

Johns Hopkins University
Schools of Medicine and Engineering

Depts. of Biomedical Engineering,
Computer Science and Surgery

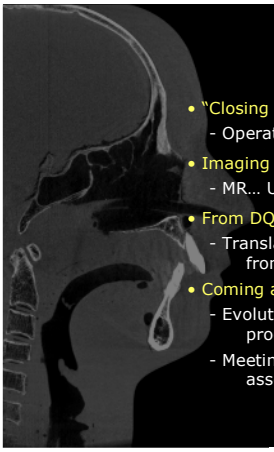

Overview

- "Closing the loop" in image-guided surgery
  - Operating rooms of the future
- Imaging modalities for IGS
  - MR… US… CT… and cone-beam CT
- From DQE to TRE
  - Translation of a new imaging technology from the laboratory to the OR
- Coming advances in IGI
  - Evolution and revolution in image-guided procedures
  - Meeting new standards in technology assessment

New Opportunities in IGI

High-precision imaging / guidance / monitoring / adaptation:

- Maximize the performance of existing techniques
  - Increased target ablation
  - Avoidance of critical structures
  - More efficient therapeutic delivery, workflow
- Expand the application of current techniques
  - Management of otherwise "untreatable" disease
  - Increasingly patient-specific therapies
- Develop entirely new therapeutic approaches
  - Advanced delivery systems (e.g., robotics, PDT, …)
  - Investigate the synergy of adaptive, multi-modality therapies (physical / molecular / cellular / pharmaceutical)
- Expose fundamental factors determining outcome

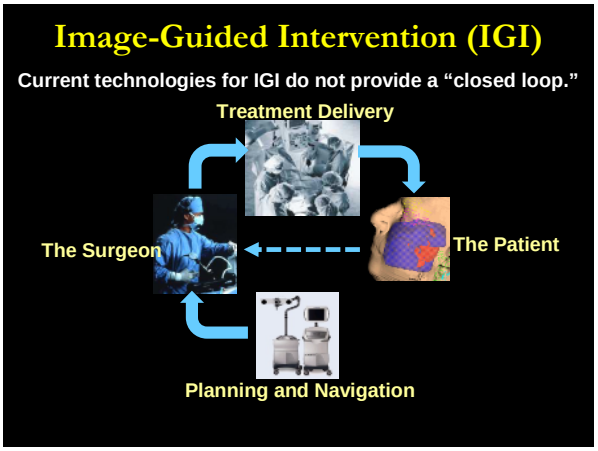
Image-Guided Intervention (IGI)
Current technologies for IGI do not provide a "closed loop."
Treatment Delivery
The Surgeon
The Patient
Planning and Navigation

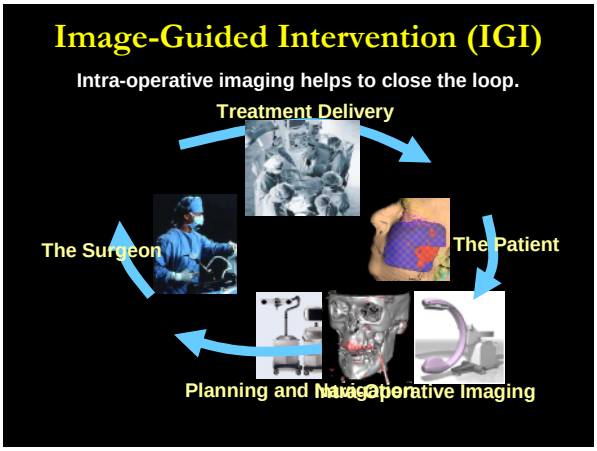
Image-Guided Intervention (IGI)
Intra-operative imaging helps to close the loop.
Treatment Delivery
The Surgeon
The Patient
Planning and Navigation
Intra-operative Imaging

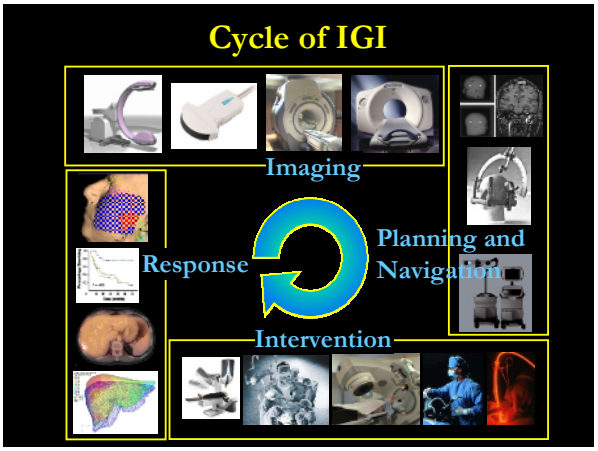
Cycle of IGI
Imaging
Response
Planning and Navigation
Intervention


ORs of the Future
For example: AMIGO: Advanced Multi-Modality Image-Guided OR
F Jolesz, C Timpani, et al., CIMIT, BWH
3T MRI
PET-CT

ORs of the Future

- Emerging themes:
  - Computerized integration of systems / technologies (e.g., planning and real-time navigation)
  - A wealth of data presented intra-operatively
  - Advanced therapy delivery systems (e.g., robotics)
  - Multi-modality imaging
- The immediate challenges:
  - Implementation, integration, and evaluation
  - Comparative effectiveness
- The longer-term challenges:
  - Cost
  - Entirely new technology advances, specific to the OR
  - Streamlined integration with therapy workflow

Imaging for Therapy Guidance

- Imaging technologies
  - Continuous advances in Dx imaging technology apply to Tx imaging as well
  - However, challenges for Tx imaging go beyond direct implementation in the arena of therapy
- Imaging for Tx guidance involves distinct:
  - Imaging tasks
  - Requirements (image quality, speed, accuracy, etc.)
  - Constraints (dose, patient access, etc.)
- Overall challenge:
  - Develop imaging strategies motivated directly by the objectives and constraints of therapy guidance

Imaging Modalities for IGI

X-ray Fluoro / CBCT **CT** **Ultrasound**






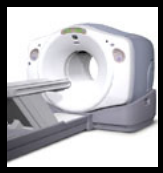

MR **Optical** **Nuclear Medicine**

Imaging Modalities for IGI

X-ray Fluoro / CBCT

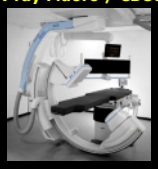


Key Characteristics
- Real-time (or near-real-time)
- Radiation dose ~$^1/_{10}$ – $^1/_2$ of Dx CT
- Sub-mm resolution
- Soft-tissue visibility



Cone-Beam CT

Projection data
Multiple projections
over ~180°

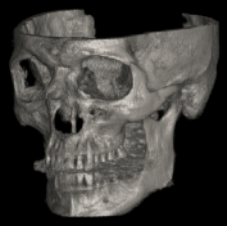

Volume reconstruction
Sub-mm spatial resolution
+ soft tissue visibility

Mobile C-Arm for Intraoperative Cone-Beam CT

Multiple projection images acquired over ~180°
2D Image acquisition
- Nominal: 60 s
- High-speed motor: 10 s
3D Image reconstruction
- Nominal: 60 s
- High-speed recon: 10 s
Radiation dose
- ~1/10th that of Dx CT

Mobile Isocentric C-Arm

Siemens PowerMobil

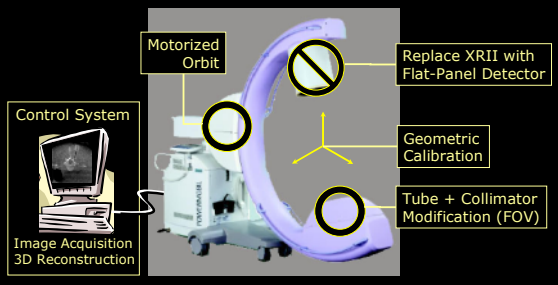

Mobile Isocentric C-Arm

Cone-Beam CT-Capable C-Arm



Pre-clinical platform for multi-mode Fluoro / CBCT guidance

Applications in IG Surgery

- Orthopedic Surgery
- Spine Surgery
- Brachytherapy
- Ear Surgery
- Interventional Radiology
- Urology
- Lung Surgery
- Breast Surgery
- Head and Neck Surgery

Platform for optimizing / integrating imaging and navigation

Applications in IG Surgery

- Orthopedic Surgery
- Spine Surgery
- Brachytherapy
- Ear Surgery
- Interventional Radiology
- Urology
- Lung Surgery
- Breast Surgery
- Head and Neck Surgery

In vivo studies of image quality and geometric precision

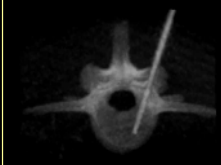

Applications in IG Surgery

- Orthopedic Surgery
- Spine Surgery
- Brachytherapy
- Ear Surgery
- Interventional Radiology
- Urology
- Lung Surgery
- Breast Surgery
- Head and Neck Surgery

Soft-tissue visualization and real-time planning

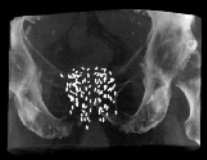

Applications in IG Surgery

- Orthopedic Surgery
- Spine Surgery
- Brachytherapy
- Ear Surgery
- Interventional Radiology
- Urology
- Lung Surgery
- Breast Surgery
- Head and Neck Surgery

Resection of sub-palpable lesions



Applications in IG Surgery

- Orthopedic Surgery
- Spine Surgery
- Brachytherapy
- Ear Surgery
- Interventional Radiology
- Urology
- Lung Surgery
- Breast Surgery
- Head and Neck Surgery

Maximal target ablation and critical structure avoidance

An Integrated Image Guidance System for Head and Neck Surgery

Integration of Image Guidance Systems

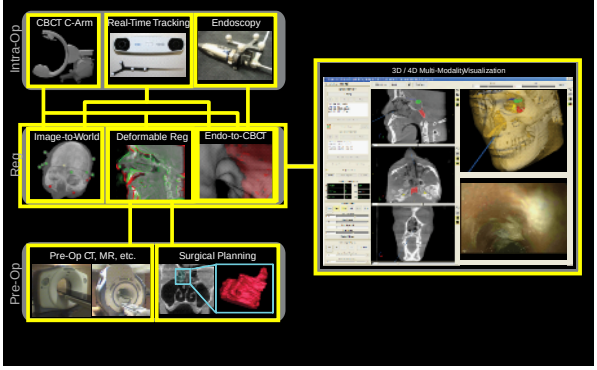

3D Deformable Image Registration

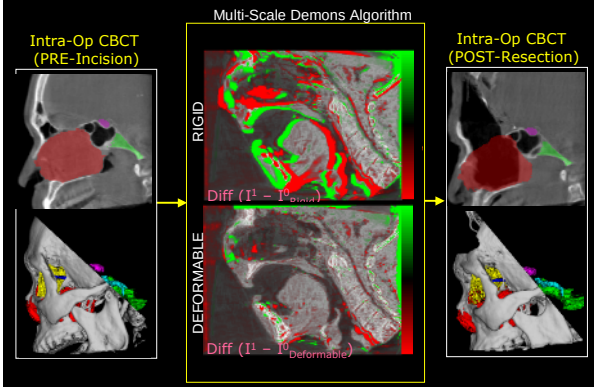

3D Deformable Image Registration: "Demons" Algorithm

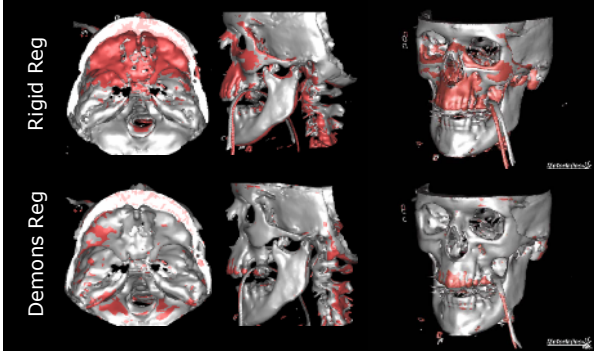

Registration Performance (TRE)

Performance Evaluation
10 Patients
Rigid vs. Demons
6 Anatomical Targets

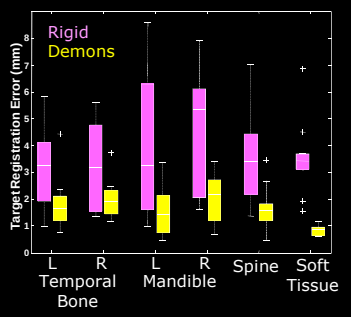

Real-Time Tracking and Navigation

Optimal fiducial arrangements
Automatic registration of image and tracking systems

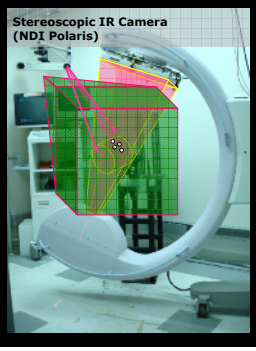

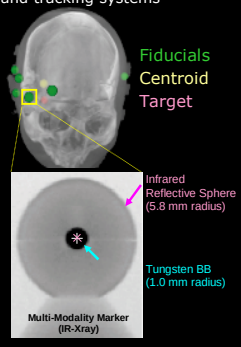

Automatic Tracking Registration

Target Registration Error (TRE)

Manual Registration
TRE = (1.29 ± 0.34) mm
Automatic Registration
TRE = (1.14 ± 0.20) mm
→ Comparable accuracy
→ Improved reproducibility

Markers fixed to cranium surface
TRE = (0.83±0.20) mm
Markers off-surface
(better arrangement for H&N)
TRE = (1.24±0.20) mm
→ NSS (p=0.79)

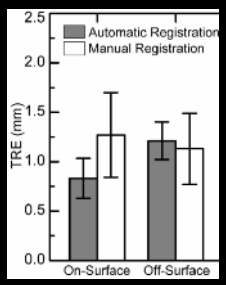

Workflow

Manual Registration: minutes
Automatic Registration: seconds, automatic with each CBCT scan

Integrated CBCT + Endoscopy

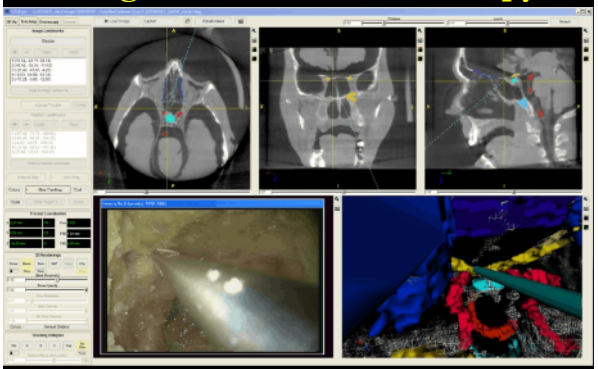

Pre-Clinical Studies

- Tomosynthesis
  - Image quality and dose
  - Localization accuracy
- Temporal Bone
  - Image quality (spatial resolution)
  - Visualization of cochlear implants
- Sinus ablation
  - Identification of CSF leak
  - Frontal recess, ethmoid, sphenoid
- Skull base
  - Completeness of target ablation
  - Avoidance of critical structures
  - Quantitative analysis of surgical performance under CBCT guidance

CBCT-Guided Sinus Surgery

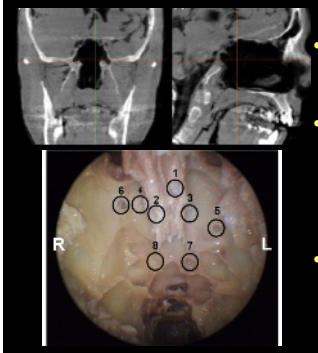

- Identification of CSF Leak
  Cadaver specimen
  Total sinus ablation
- Breach introduced
  Diameter: 1, 2, 4 mm
  1-2: Cribriform
  3-4: Lateral lamella
  5-6: Fovea ethmoidalis
  7-8: Planum
- Observer study
  5 surgeons, 1 radiologist
  5-point detectability scale
  Min detectable breach

CBCT-Guided Sinus Surgery

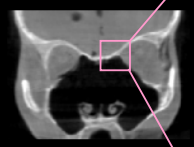

Coronal CBCT

Ethmoid Air Cell Ablation in proximity to Fovea Ethmoidalis

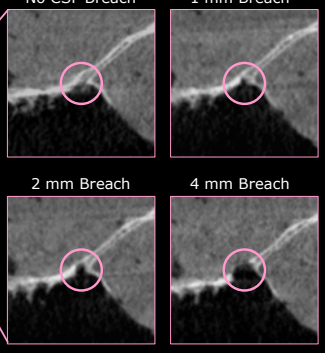

CBCT-Guided Sinus Surgery

Detection of CSF Leak

Rating Scale:

5= Perfectly obvious
4= Visible
3= Visible, but challenging
2= Could be overlooked
1= Unable to identify

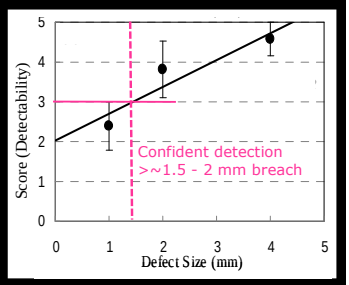

Skull Base Surgery: Target Abation in the Clivus

Intra-Operative CBCT

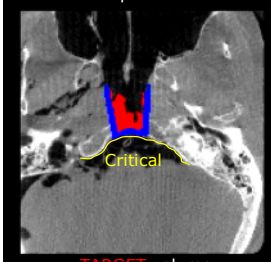

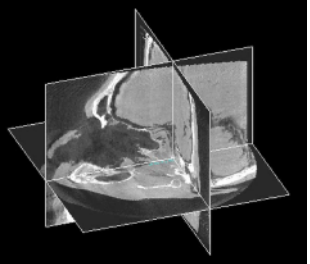

TARGET volume
NORMAL volume

Skull Base Surgery: Target Abation in the Clivus

Intra-Operative CBCT

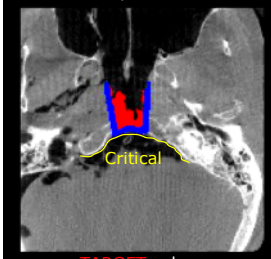

TARGET volume
NORMAL volume

Post-Operative CBCT

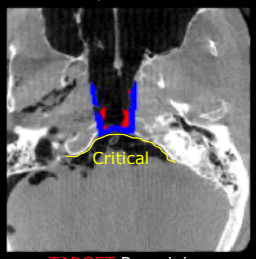

TARGET Remaining
NORMAL Remaining

Quantification of Surgical Performance

Hypothesis-testing framework for evaluation of surgical performance

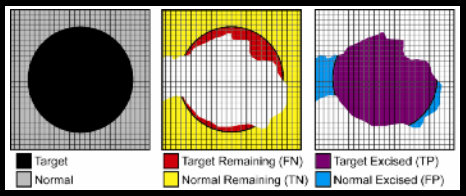

Fraction of Tumor Excised = Sensitivity = $\frac{TP}{TP+FN}$

Positive Predictive Value = PPV = $\frac{TP}{TP+FP}$

Fraction of Normal Remaining = Specificity = $\frac{TN}{FP+TN}$

Negative Predictive Value = NPV = $\frac{TN}{TN+FN}$

CBCT-Guided Skull Base Surgery

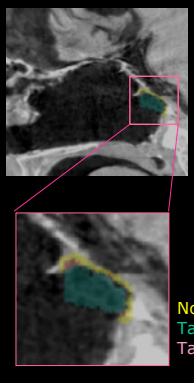

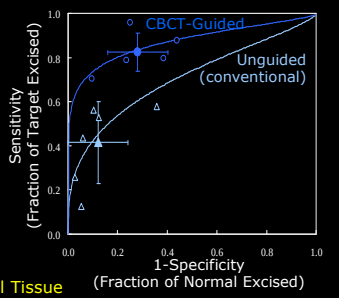

Normal Tissue
Target Volume (excised)
Target Volume (residual)

Translation to Clinical Trials

C-Arm Trials: Mandibulectomy

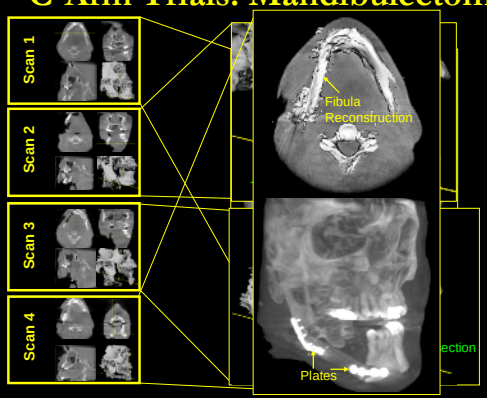

C-Arm Trials: Invasive Tumor

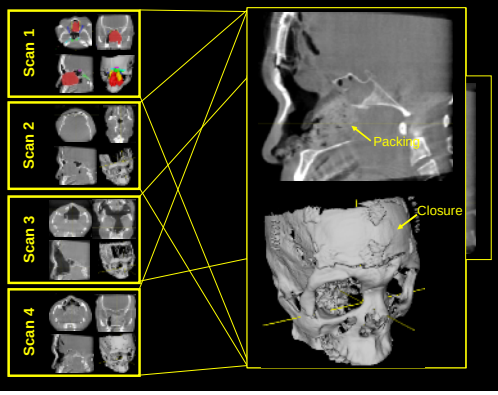

Looking Ahead: Opportunities in IGI

Multi-Modality Intra-Operative Imaging
- Essential to 'closing the loop' in image-guided surgery
  - MR / US / CT / Cone-beam CT
- More than simple translation from Dx to Tx
  - New development for the task of surgical guidance

Integration of Guidance Systems
- Essential to preserving / improving surgical workflow
  - Intraoperative imaging
  - Image registration
  - Planning and real-time navigation
  - 3D visualization
  - Therapeutic delivery (e.g., robotics)

ORs of the Future

Currently characterized by **conglomeration** of technology
- For example: MR/CT/US + Robot
- Engineering challenge is beyond simple integration
  - Rather, a re-engineering effort (or new system altogether) is required according to the surgical task

ORs of the (more distant) future
- Hopefully exceed conglomerate "IGORs" of the present
  - Technologies created specifically for the OR
  - Streamlined integration with surgical workflow

An inter-disciplinary approach to new technologies in the operating theatre
- (Surgeons, Nurses, Anesthesia) + (Physicists, Engineers)
- Radiation therapy offers a successful model example

Demonstrating True Benefit

Such IG systems and ORs will need to meet new standards of performance: **comparative effectiveness**
- Within technology (intra-metrics):
  - Optimal implementation of 'Technology X'
- Between technologies (inter-metrics):
  - Performance of 'Technology X' vs 'Technology Y'
- Clinical justification:
  - Effectiveness of therapy under 'Tech X' vs standard of care

Quantification of surgical performance is key
- Short of randomized clinical trials, approaches like hypothesis-testing could be valuable
- Rigorous computerized planning
- Quantitative evaluation of planned (and delivered) Tx

Acknowledgements

University Health Network
- JC Irish, MD – Surgical Oncology
- G Bachar, MD
- E Barker, MD
- H Chan, PhD
- MJ Daly, MSc
- M Rafferty, MD
- A Vescan, MD

University of Toronto
- N Hamming, MHSc
- S Nithiananthan

Funding Support
- NIH R01-CA112163
- NIH R01-CA127444
- Siemens Healthcare (SP, Erlangen)
- Princess Margaret Hospital Foundation

Cone-Beam CT

Projection data
Multiple projections
over ~180°

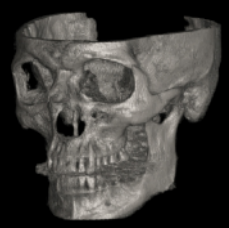

Volume reconstruction
Sub-mm spatial resolution
+ soft tissue visibility

Applications in IG Surgery

- Orthopedic Surgery
- Spine Surgery
- Brachytherapy
- Ear Surgery
- Interventional Radiology
- Urology
- Lung Surgery
- Breast Surgery
- Head and Neck Surgery

Platform for optimizing / integrating imaging and navigation

Applications in IG Surgery

- Orthopedic Surgery
- Spine Surgery
- Brachytherapy
- Ear Surgery
- Interventional Radiology
- Urology
- Lung Surgery
- Breast Surgery
- Head and Neck Surgery

In vivo studies of image quality and geometric precision

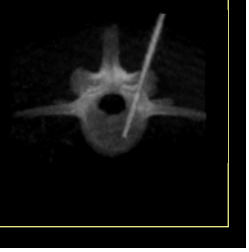

Applications in IG Surgery

- Orthopedic Surgery
- Spine Surgery
- Brachytherapy
- Ear Surgery
- Interventional Radiology
- Urology
- Lung Surgery
- Breast Surgery
- Head and Neck Surgery

Soft-tissue visualization and real-time planning

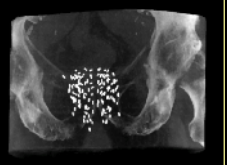

Applications in IG Surgery

- Orthopedic Surgery
- Spine Surgery
- Brachytherapy
- Ear Surgery
- Interventional Radiology
- Urology
- Lung Surgery
- Breast Surgery
- Head and Neck Surgery

Resection of sub-palpable lesions



Applications in IG Surgery

- Orthopedic Surgery
- Spine Surgery
- Brachytherapy
- Ear Surgery
- Interventional Radiology
- Urology
- Lung Surgery
- Breast Surgery
- Head and Neck Surgery

Maximal target ablation and critical structure avoidance

Skull Base Surgery: Target Abation in the Clivus

Intra-Operative CBCT

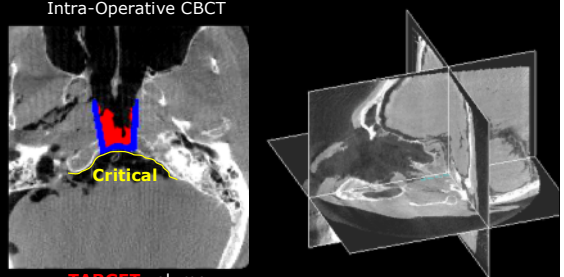

TARGET volume
NORMAL volume

Skull Base Surgery: Target Abation in the Clivus

Intra-Operative CBCT | Post-Operative CBCT

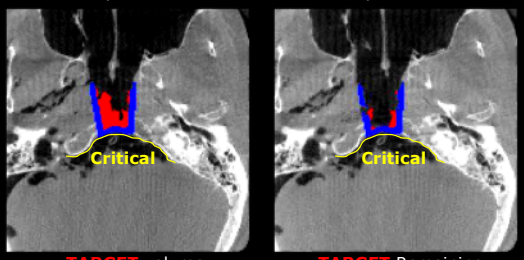

TARGET volume
NORMAL volume

TARGET Remaining
NORMAL Remaining

C-Arm Trials: Maxillectomy