QUANTIFICATION OF CAROTID PLAQUE PROGRESSION and REGRESSION USING 3D ULTRASOUND IMAGING

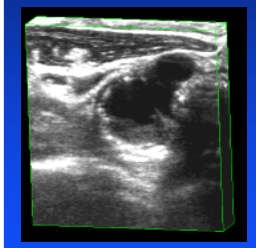

AARON
FENSTER
PhD

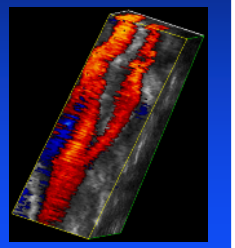

Imaging Research Laboratories
Robarts Research Institute, London, Ontario, Canada

ATHEROSCLEROTIC CAROTID PLAQUE

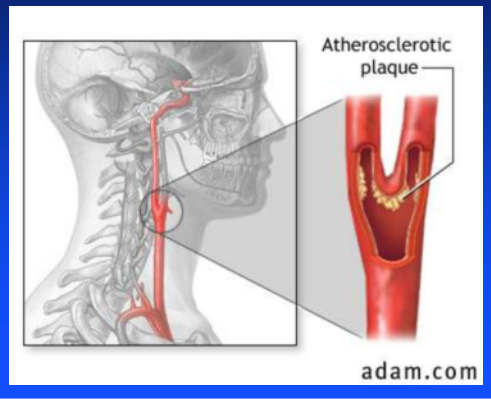

MONITORING PLAQUE CHANGE IN PATIENTS

- Monitoring plaque change is important in evaluating the effectiveness of different treatment or stroke prevention strategies:
  - Medical Intervention (e.g., statins)
  - Dietary Change (e.g., decreasing LDL, saturated fats, salt, increasing whole grains, vegetables, vitamins, antioxidant)
  - Lifestyle Change (e.g., exercising, quitting smoking, managing stress)

MONITORING CAROTID PLAQUE CHANGES

Developing S/W tools to quantify plaque morphology from 3D US images

- 3D distribution of plaque
- Plaque volume
- Surface characteristics
- Plaque “composition”

3D CAROTID ULTRASOUND

3D US: Carotid arteries



3D Volume Rendering

Internal Carotid Artery Plaque

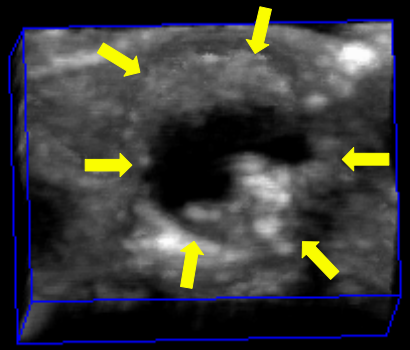

3D US: Ulcerated carotid plaque

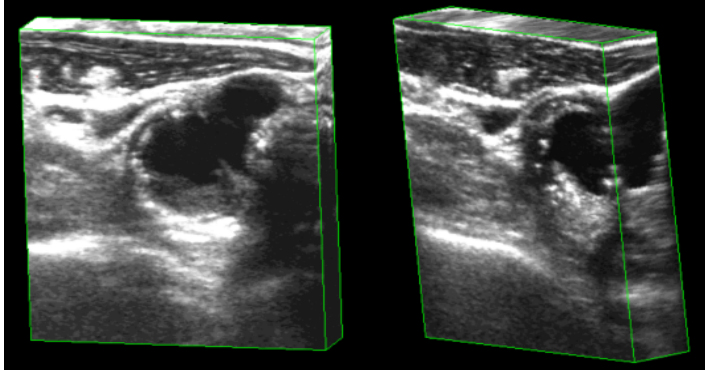

CAROTID PLAQUE: Volume measurement

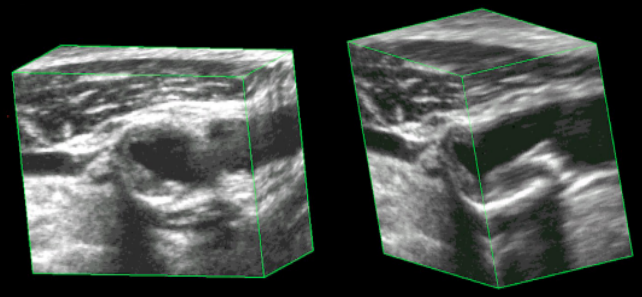

PROCEDURE: Plaque volume

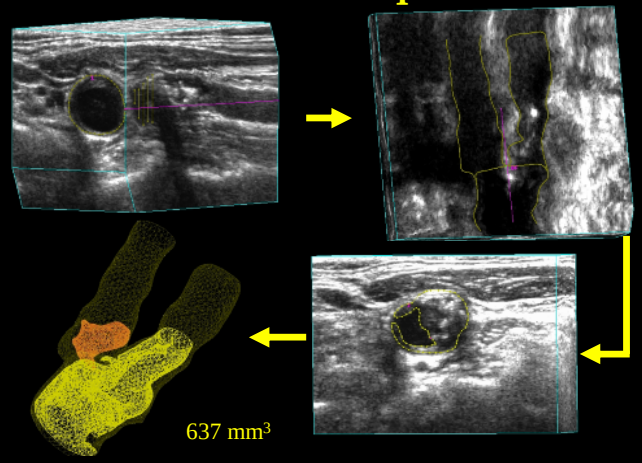

3D US CAROTID PLAQUES: Segmentation

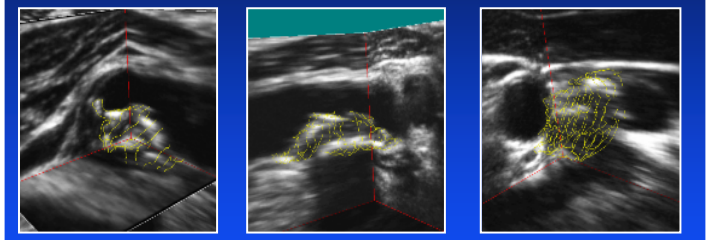

444 mm^3 477 mm^3 103 mm^3

PLAQUE VOLUME: Variability

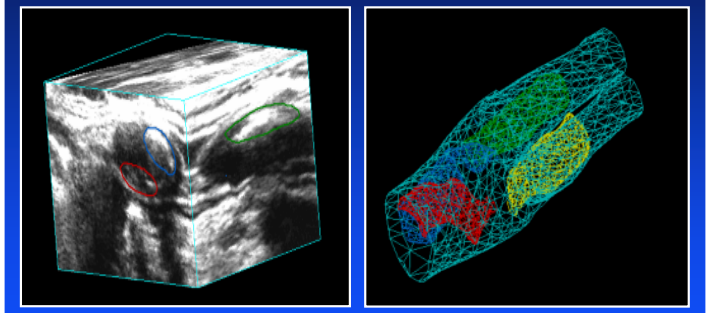

- 40 patients
- 37.4 mm^3 to 604 mm^3
- 5 observers
- 5 measurements/observer/plaque

PLAQUE VOLUME: Variability

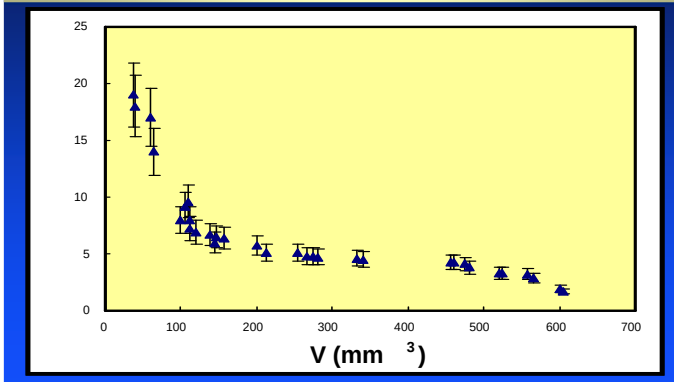

MONITORING PLAQUE REGRESSION & PROGRESSION

Ainsworth, Blake, Tamayo, Beletsky, Fenster, Spence. Stroke 36: 1904-1909, (2006)

STATIN THERAPY

Baseline

3 months

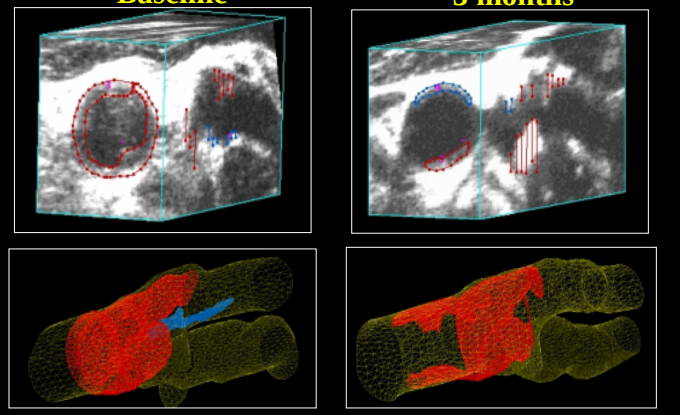

STATIN THERAPY:Plaque volume: Baseline & 3 months

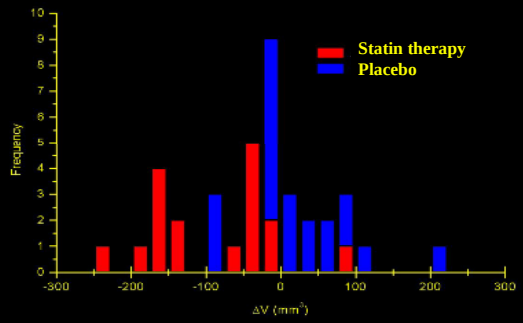

CHANGE IN PLAQUE VOLUME:
2.8*cm* centred on bifurcation

	Mean ΔV (mm^3)	$\sigma_{\Delta V}$ (mm^3)
Statin therapy (n = 17) (V_{mean} = 690 ± 401 mm^3)	-90.2*	85
Placebo (n = 21) (V_{mean} = 722 ± 474 mm^3)	16.8*	74

$\sigma_{operator}$ = 53 mm^3 *P<0.0001

MONITORING LOCAL PLAQUE CHANGES

Chiu, Egger, Spence, Parraga, Fenster. Med. Phys. 35: 3691-3710, (2008)

Segmentation of Carotid US Images

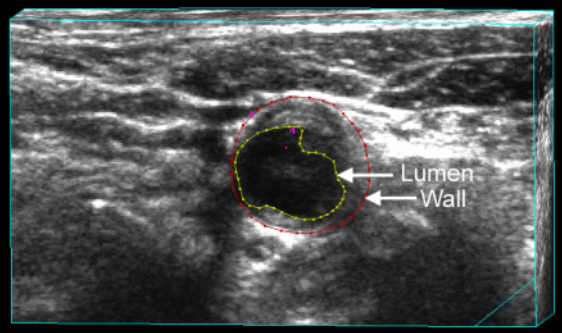

3D US image of the CCA wall and lumen

SEGMENTED CAROTID IMAGE

QuickTime™ and a
Microsoft Video 1 decompressor
are needed to see this picture.

CAROTID WALL BOUNDARY

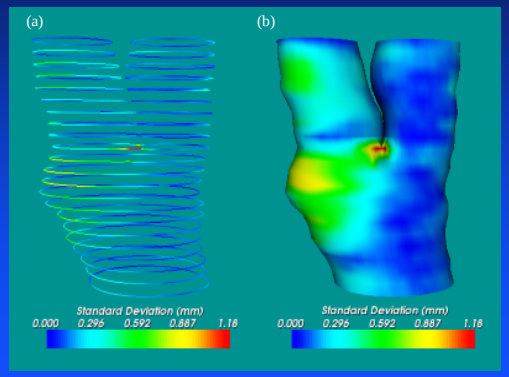

CAROTID LUMEN BOUNDARY

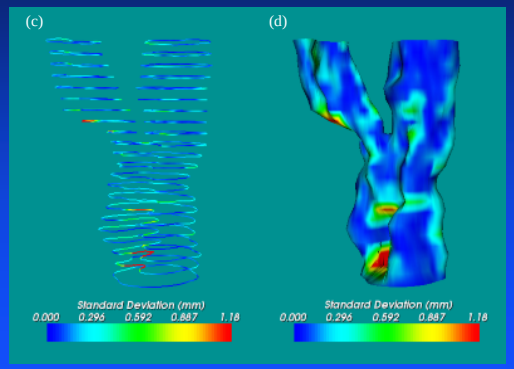

PLAQUE THICKNESS

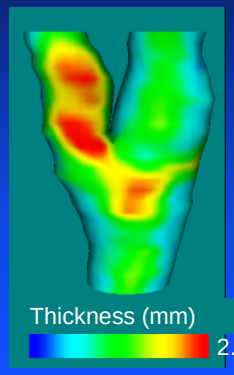

- Plaque thickness: Distance between wall and lumen surface
- Display:
  - Mean vessel wall surface
  - colour-coded plaque thickness map superimposed on mean surface

BASELINE IMAGE

QuickTime™ and a
Microsoft Video 1 decompressor
are needed to see this picture.

BASELINE IMAGE

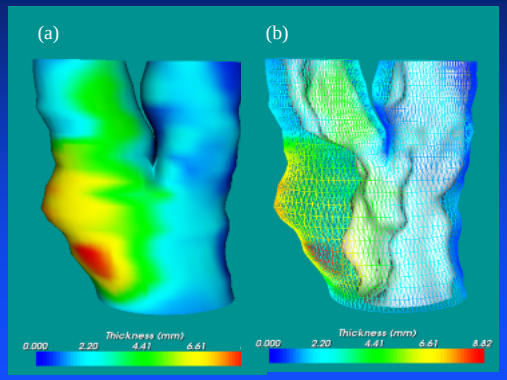

AFTER 3-MONTH STATIN THERAPY

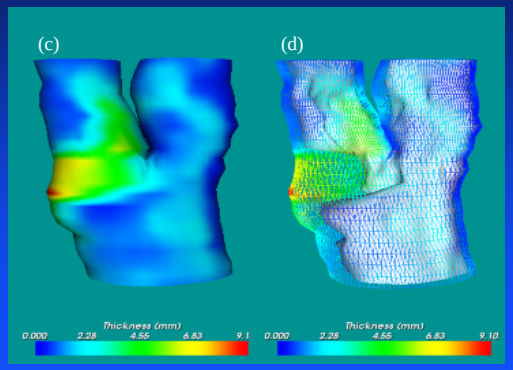

Atorvastatin treatment: Vessel-wall-plus-plaque thickness comparison

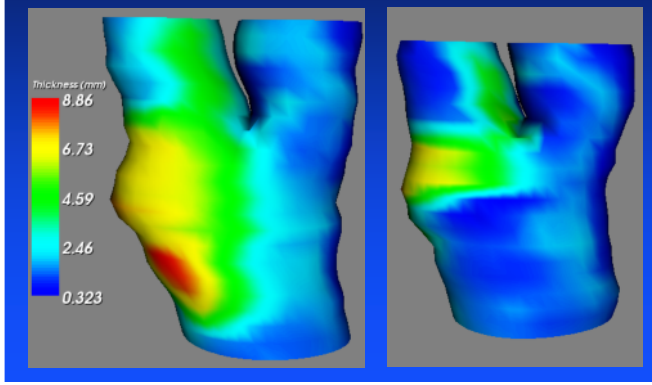

VWT Change: Subject 1

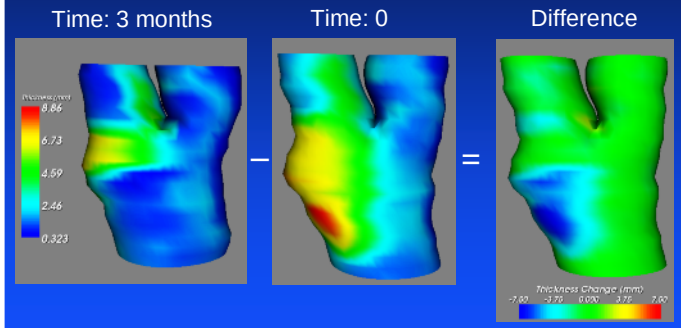

VWT Change: Subject 2

Time: 3 months | Time: 0 | Difference

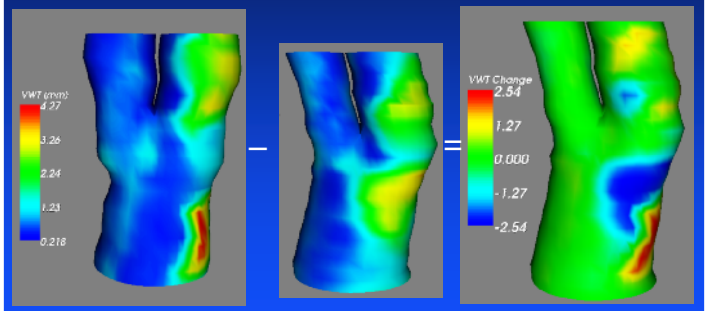

FLATTENING MAP OF 3D *VWT*

- Interpretation and comparison of 3D *VWT* maps are difficult
- The 3D *VWT* maps requires an observer to study them in different angles
- 2D flattened map provides an unobstructed view of 3D *VWT* distribution
- An unobstructed view is particularly important in assisting the interpretation of a geometrically bifurcating map

VWT Change: Flattened Map

Time: 3 months

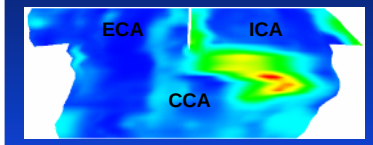

–

Time: 0

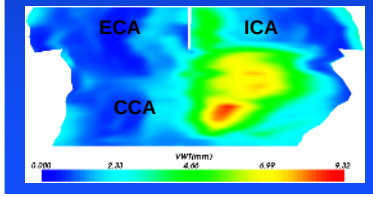

=

Subject 1

Change

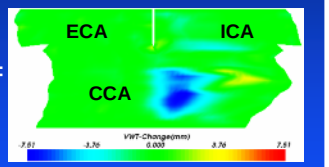

VWT Change: Flattened Map

Time: 3 months

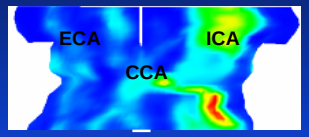

–

Time: 0

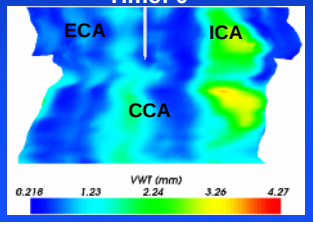

=

Subject 2

Change

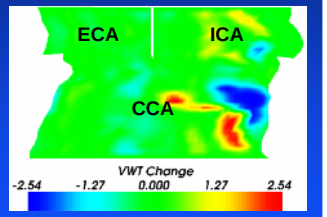

3D CAROTID ULTRASOUND: Summary

- Technique and software for analysis and monitoring of carotid plaque:
  - Software for segmentation well characterized
  - Flattened map approach developed
  - Plaque progression/regression trials ongoing
  - New features ongoing (*e.g.* surface morphology)
  - Many collaborators and users

Thank You

Graduate Students

Jeff Bax, Bernard Chiu, Derek Cool, Paul DeJean, Kayley Ma, Vaishali Karnik Nuwan Nanayakka, Anthony Landry, Manale Saikaly, Adam Waspe, Lauren Wirtzfeld

Software & Electrical Design

Shi Sherebrin, Lori Gardi Igor Gyacskov, Chandima Edrisinghe

Design & Manufacturing

Chris Blake, David Smith, Kerry Knight, Jacques Montreuil, Kevin Barker, Mike Scott

Collaborators

Aaron Ward, Grace Parraga, David Spence, Brian Rutt, James Lacefield, Hanif Ladak, Abbas, Samani, Robert Bartha, Charles McKenzie, Cesare Romagnoli, Anat Kornecki