Strengths and Limitations of Anatomical and Spectroscopic MRI in Radiation Oncology Treatment Planning

John E. Bayouth, PhD
Associate Professor
Director of Medical Physics
University of Iowa

Disclosure

- Research funding support from Siemens Medical Solutions

Learning Objectives

- Widespread applications of MRI in radiation oncology treatment planning
- Assessment of geometric distortion when MRI is utilized as one of several imaging modalities: reproducibility of patient setup and image distortion
- Application of MRI to quantify and validate motion management models
- Review obstacles to clinical utilization of magnetic resonance spectroscopic imaging (MRSI)

Difficulty in Delineation of Clinical Target Volume

Planning ⇒ highly conformal dose distributions

Treatment ⇒ high precision delivery

Contour CTV ⇒ significant subjectivity

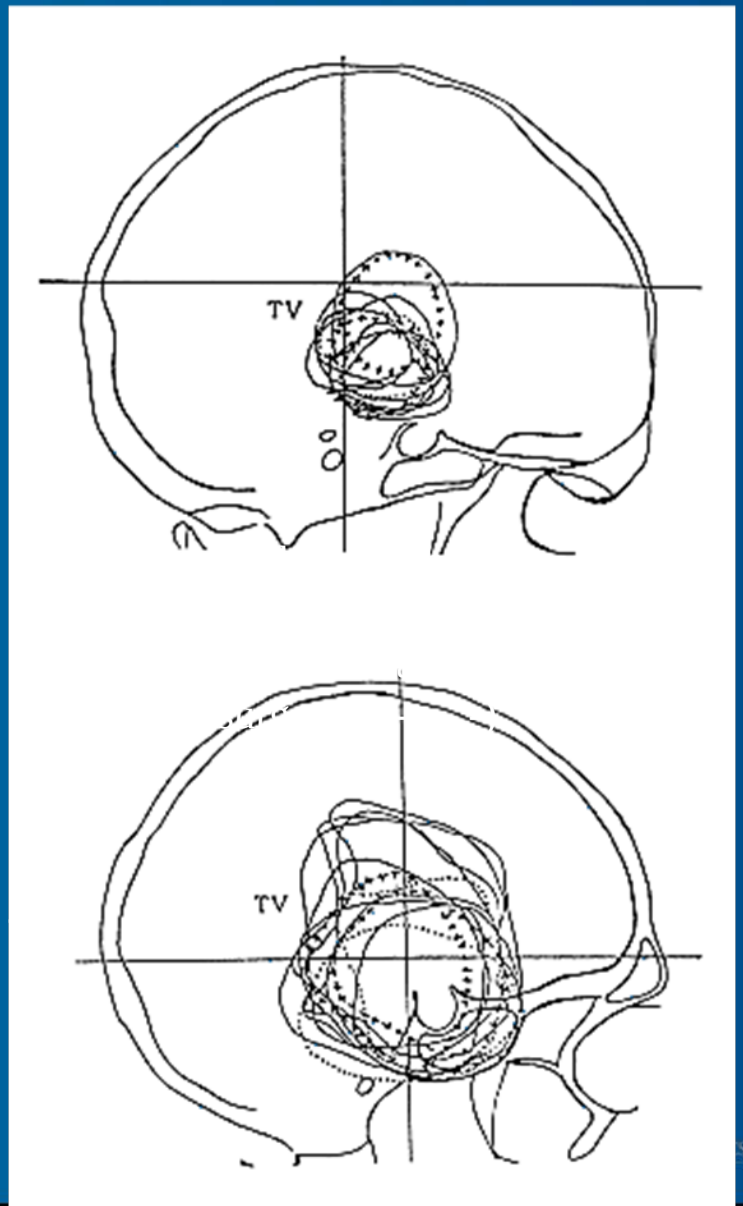

Leunens, G., Menten, J., Weltens, C., Verstraete, J. Vanderschueren, E. (1993), "Quality assessment of medical decision making in radiation oncology: variability in target volume delineation for brain tumors", *Radiother.Oncol.*, **29**, 169-175.

Neuroimaging with MR for RT

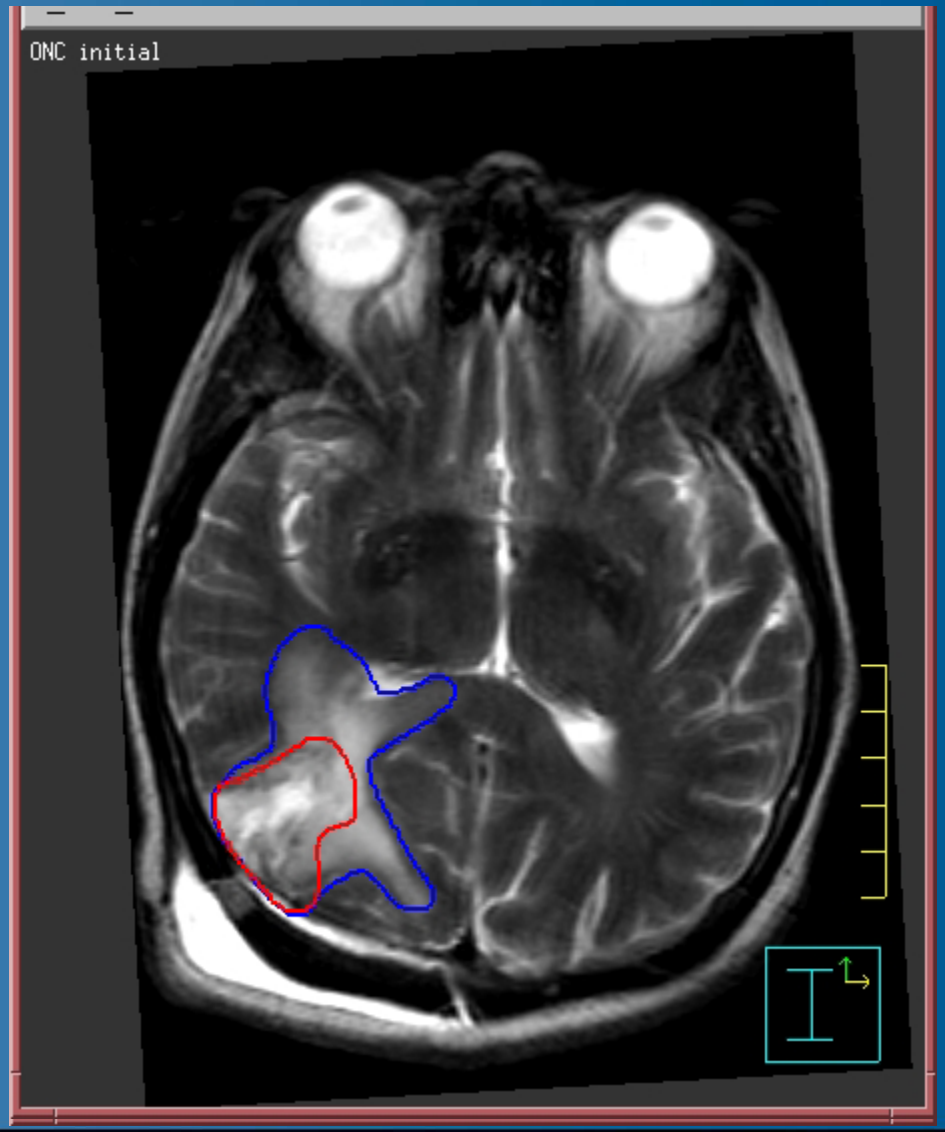

- 56 yr female
- GBM

Neuroimaging with MR for RT

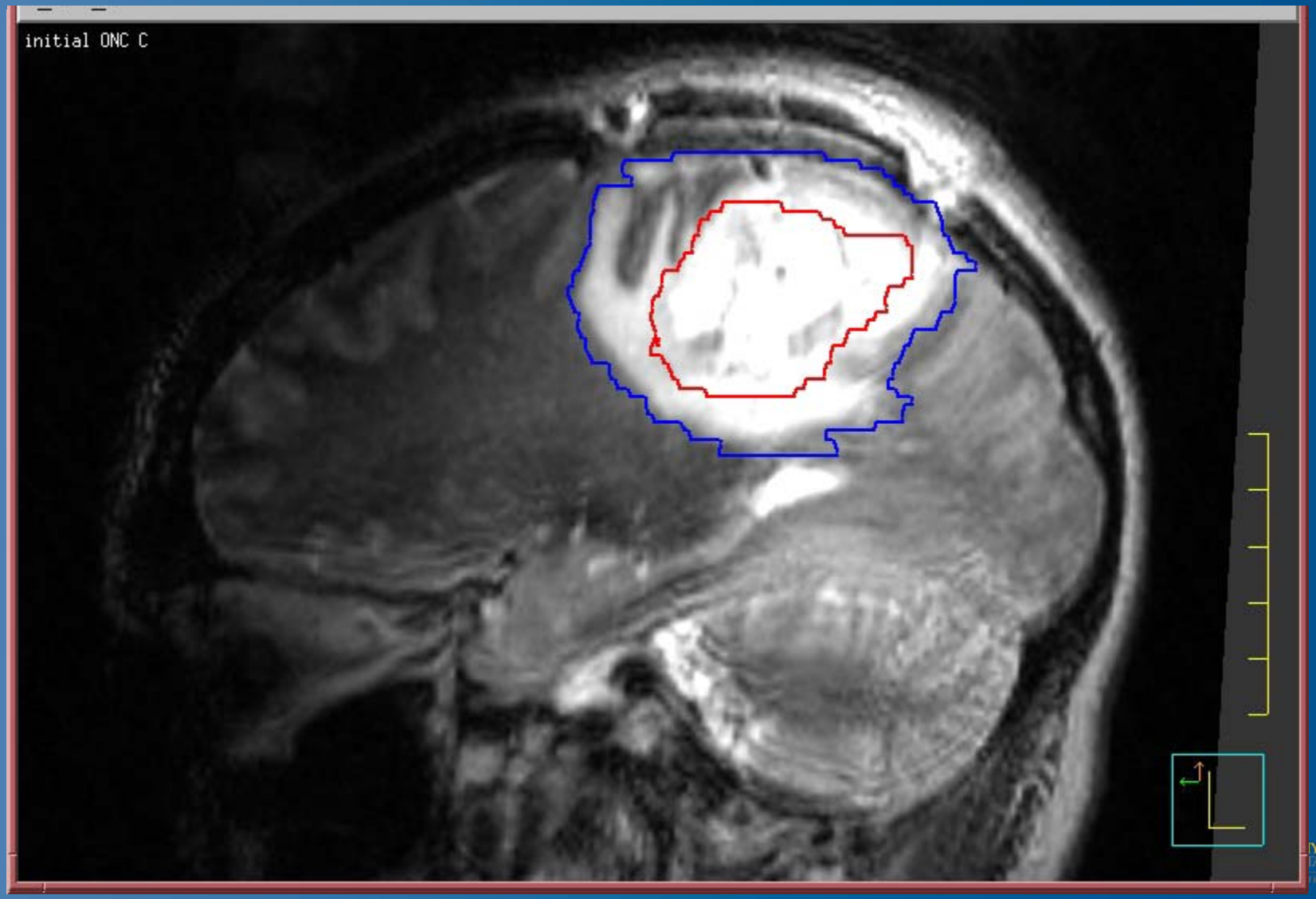

Neuroimaging with MR for SRS

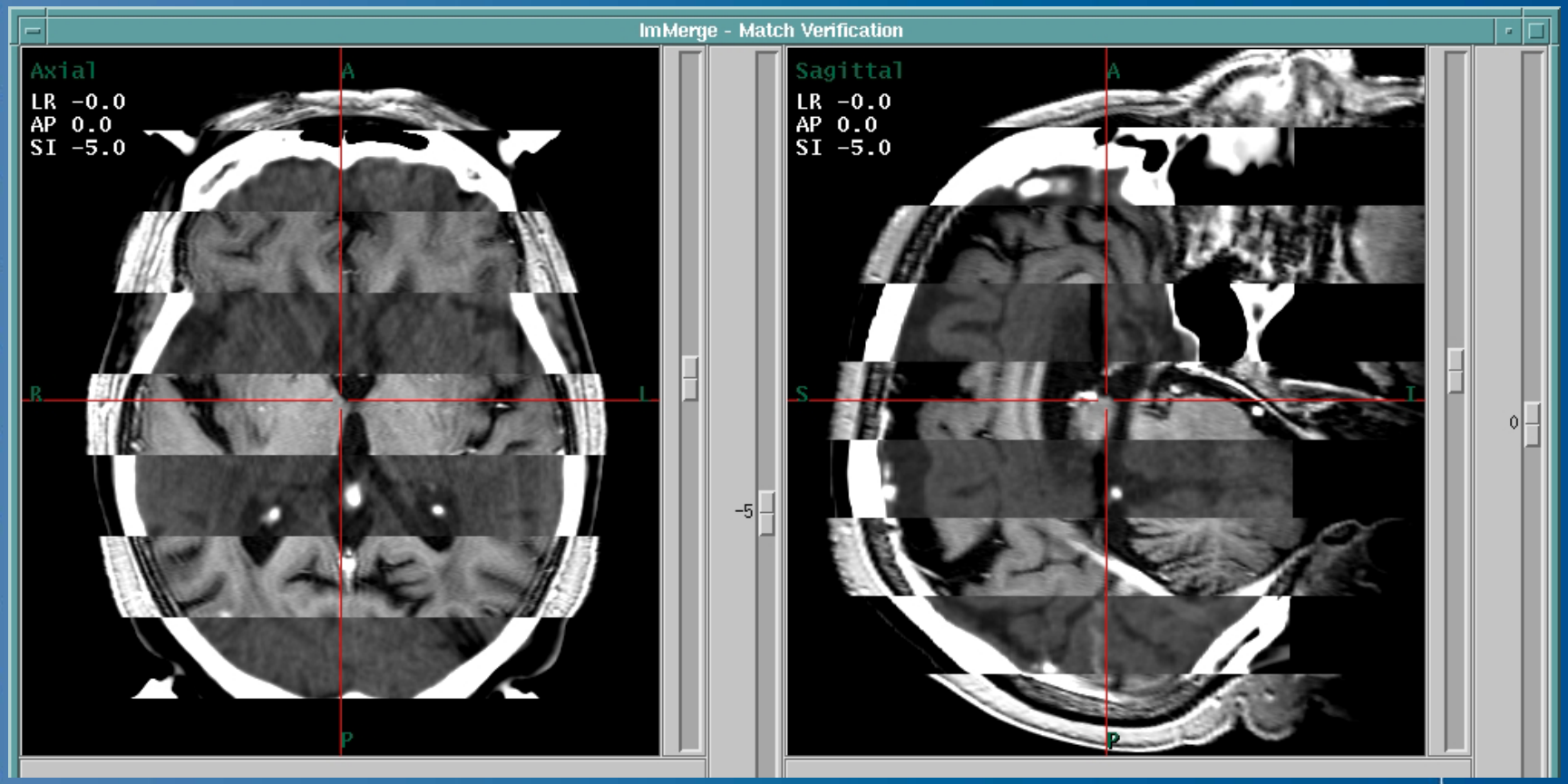

Image Registration Review – H&N

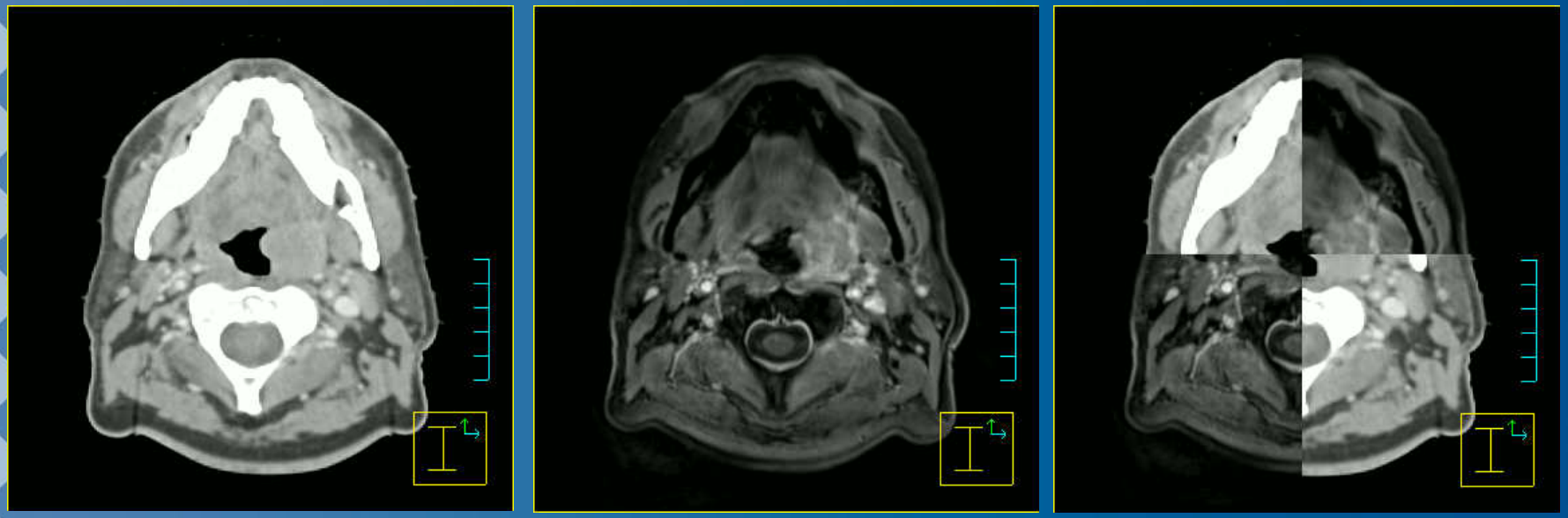

Image Registration Review – H&N

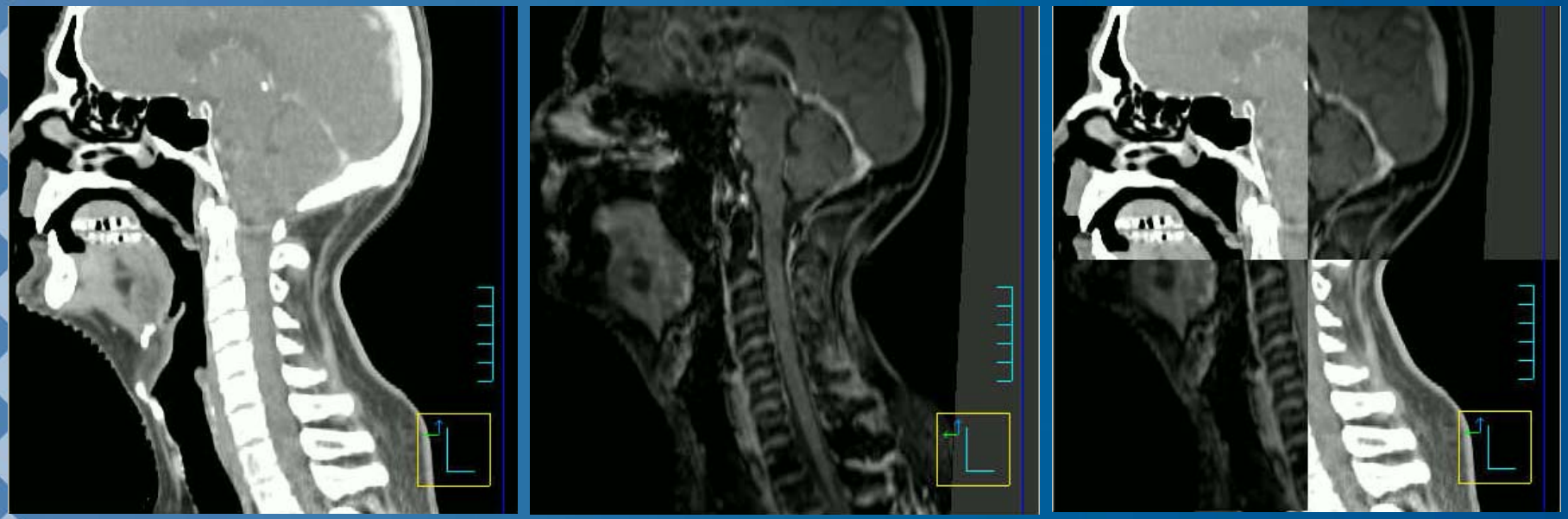

Image Registration Review – H&N

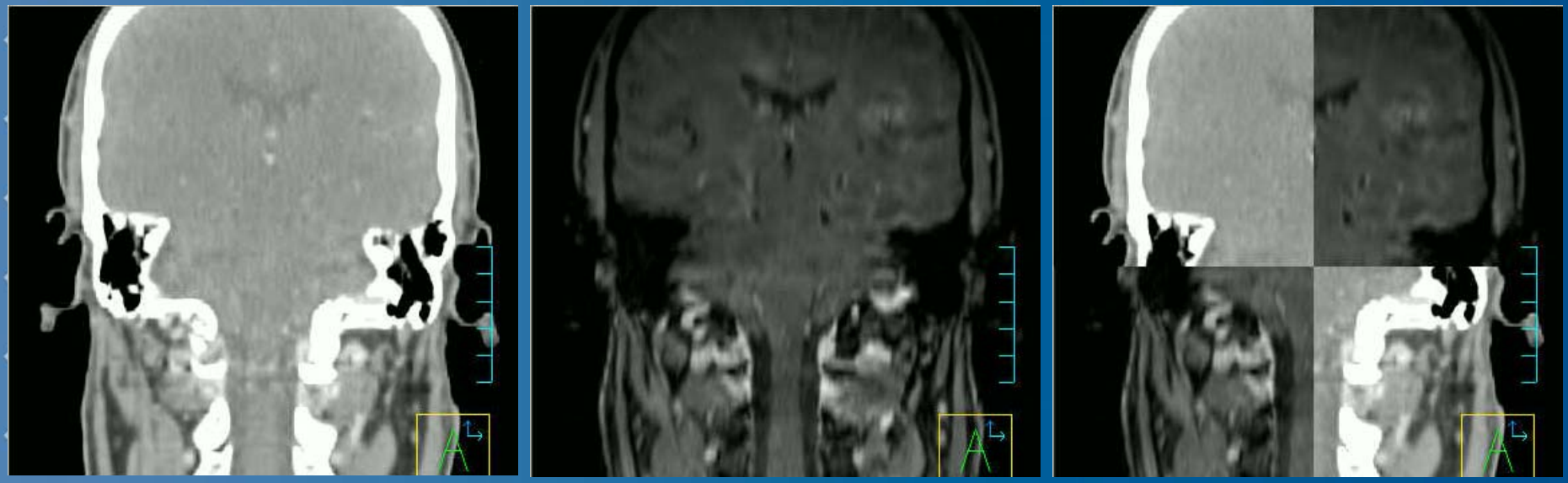

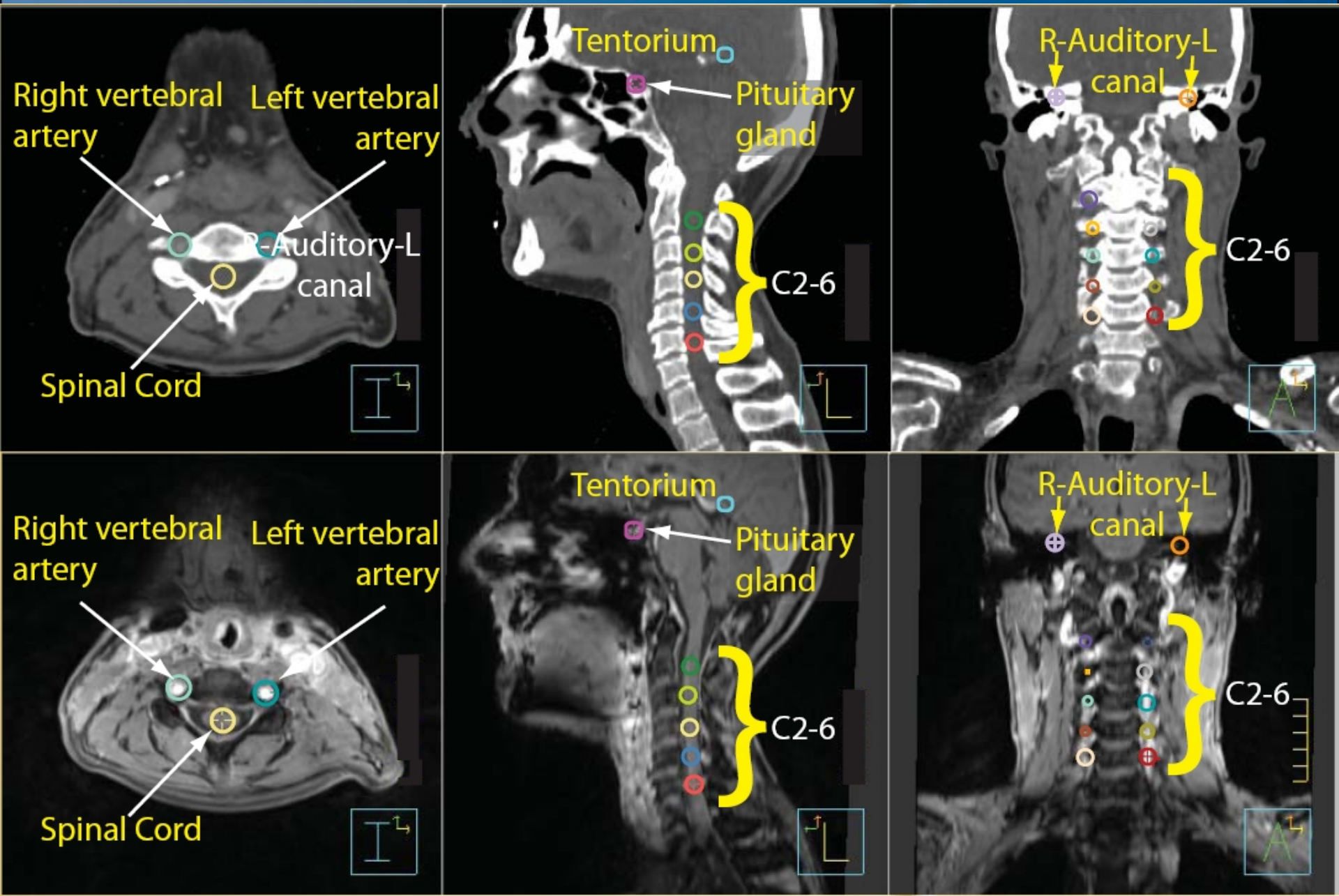
Right vertebral artery
Left vertebral artery
R-Auditory-L canal
Spinal Cord
Tentorium
Pituitary gland
C2-6
R-Auditory-L canal
C2-6
Right vertebral artery
Left vertebral artery
Spinal Cord
Tentorium
Pituitary gland
C2-6
R-Auditory-L canal
C2-6

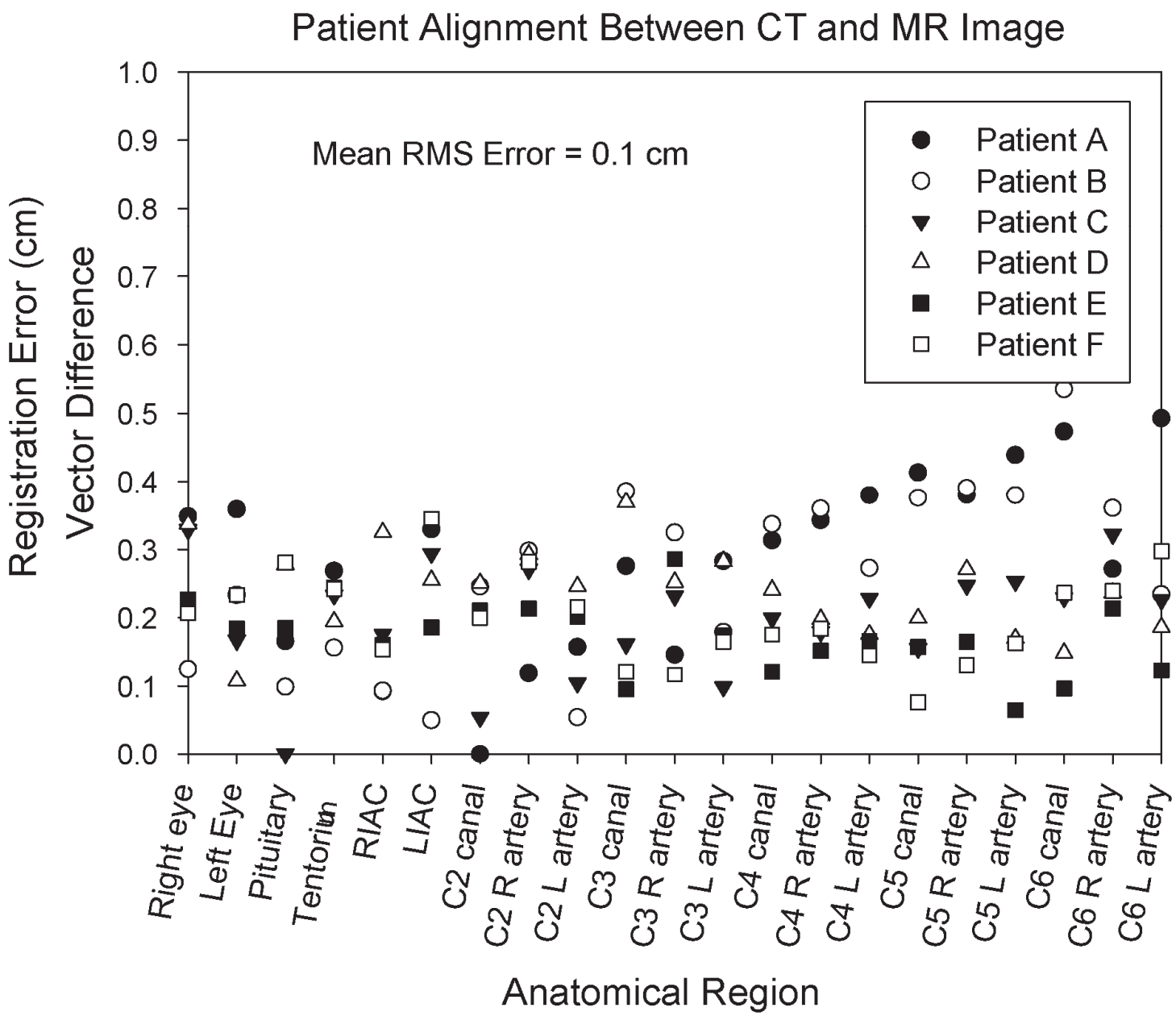
Patient Alignment Between CT and MR Image
Mean RMS Error = 0.1 cm
Patient A
Patient B
Patient C
Patient D
Patient E
Patient F
Registration Error (cm)
Vector Difference
1.0
0.9
0.8
0.7
0.6
0.5
0.4
0.3
0.2
0.1
0.0
Right eye
Left Eye
Pituitary
Tentorium
RIAC
LIAC
C2 canal
C2 R artery
C2 L artery
C3 canal
C3 R artery
C3 L artery
C4 canal
C4 R artery
C4 L artery
C5 canal
C5 R artery
C5 L artery
C6 canal
C6 R artery
C6 L artery
Anatomical Region

Morphological Imaging - Breast

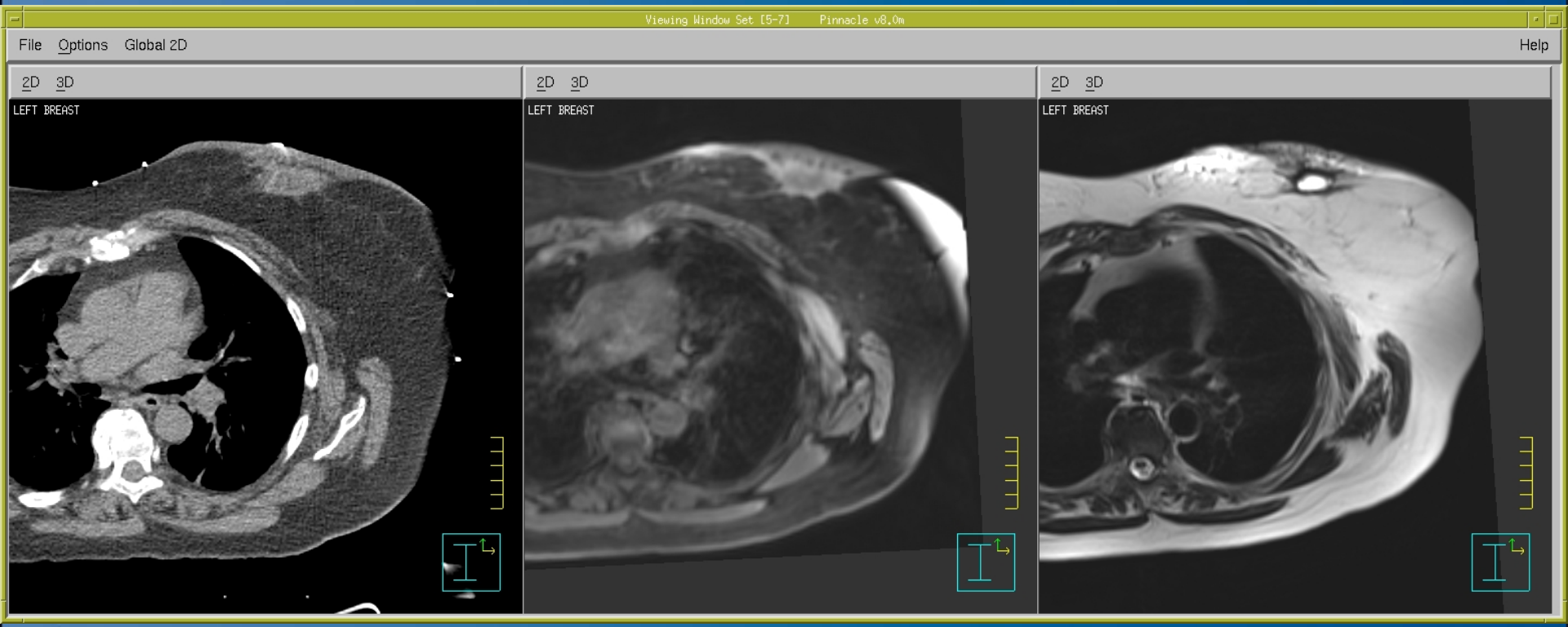

CT

T1

T2

Morphological Imaging - Breast

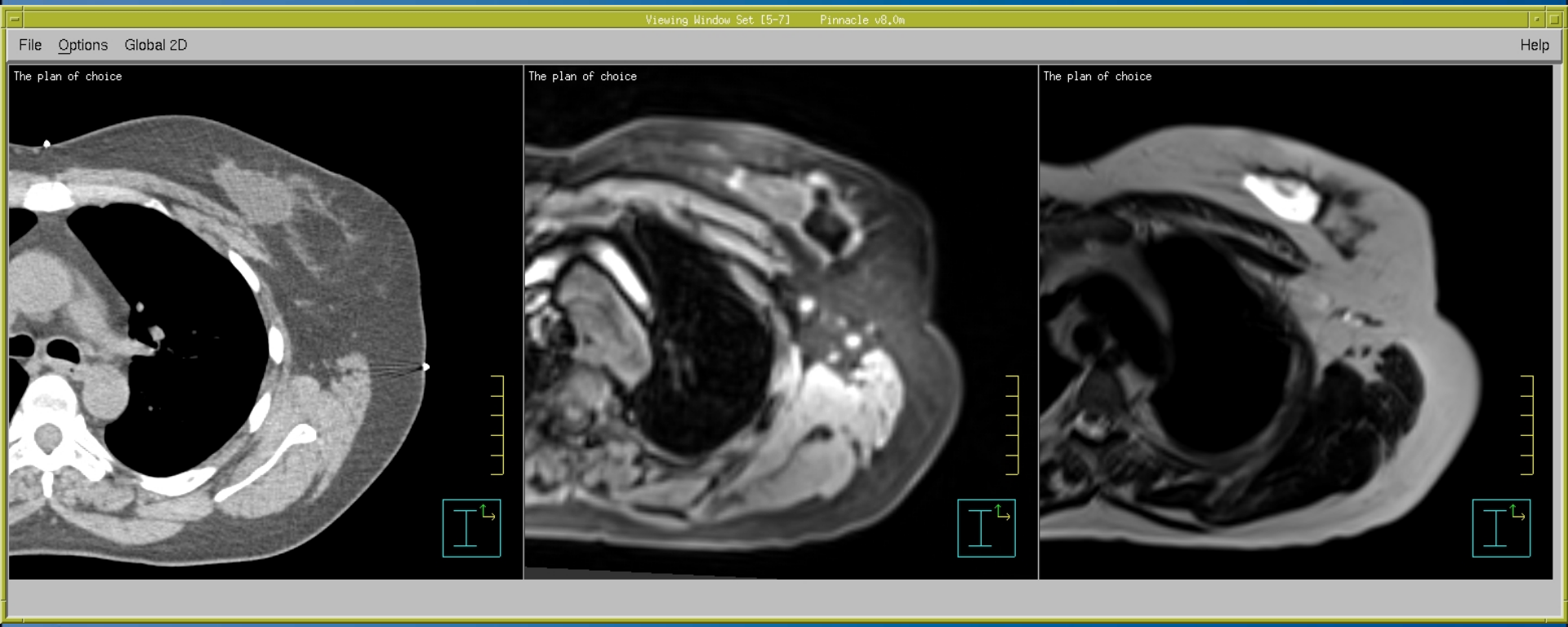

CT

T1

T2

Morphological Imaging - Breast

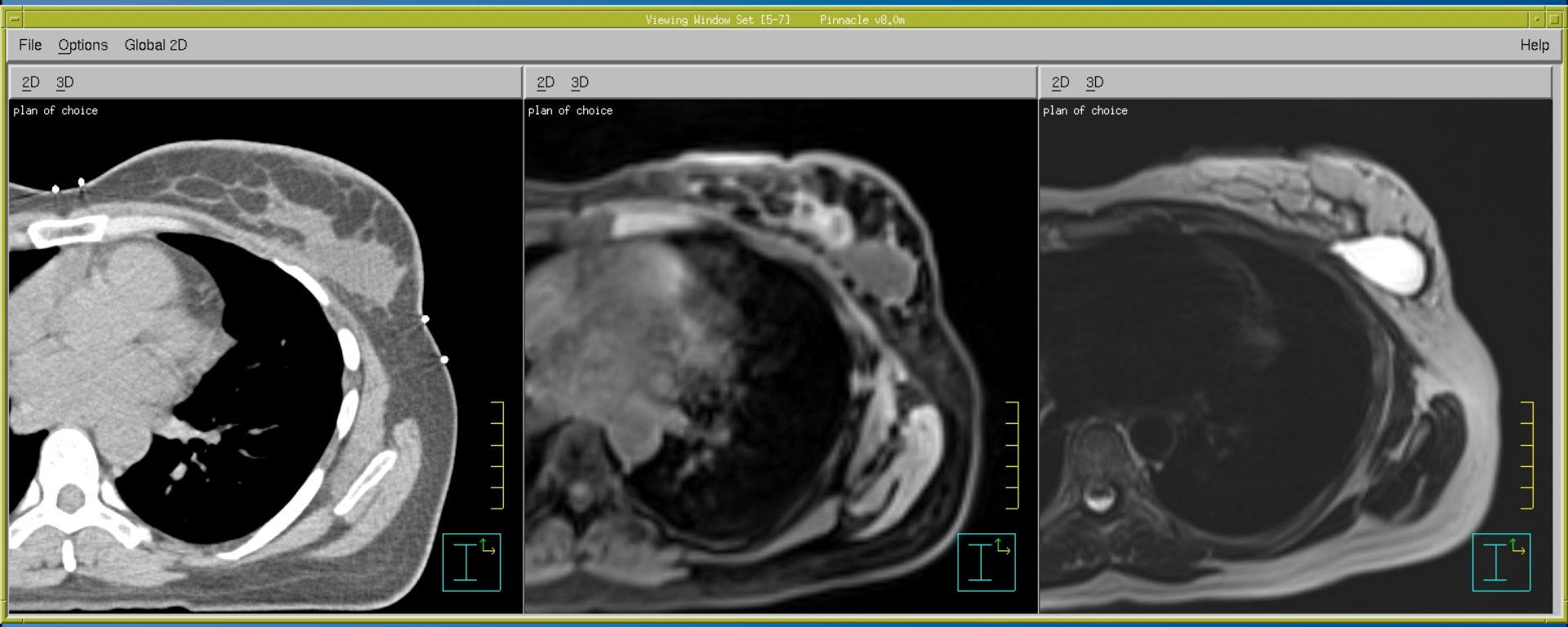

CT

T1

T2

Morphological Imaging - Prostate

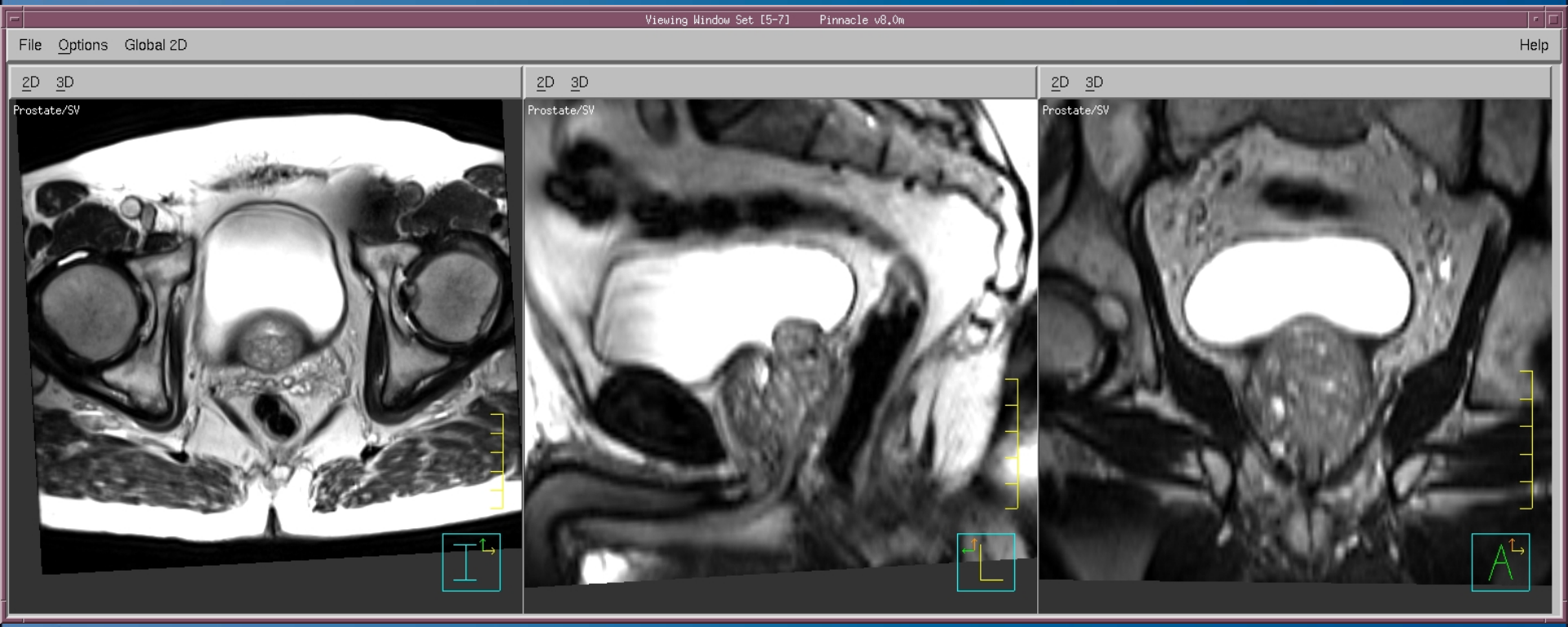

Morphological Imaging - Prostate

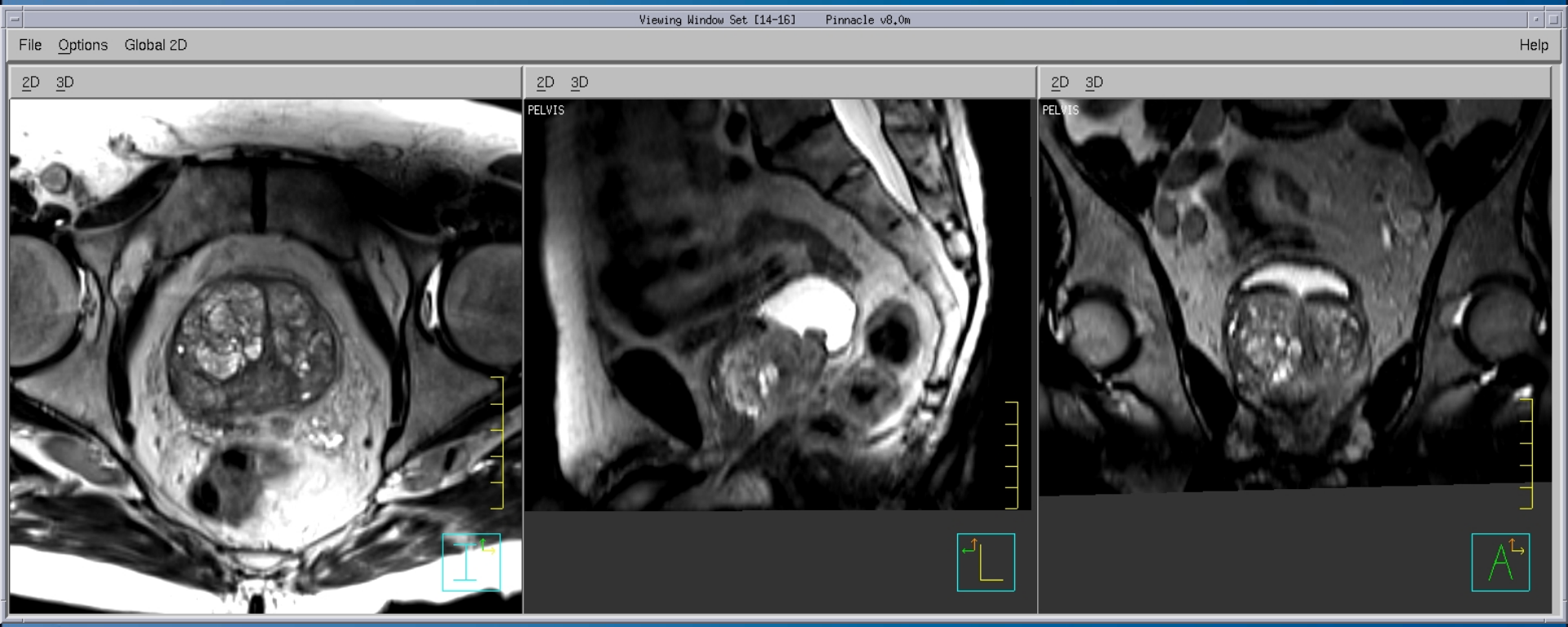

Morphological Imaging - Prostate

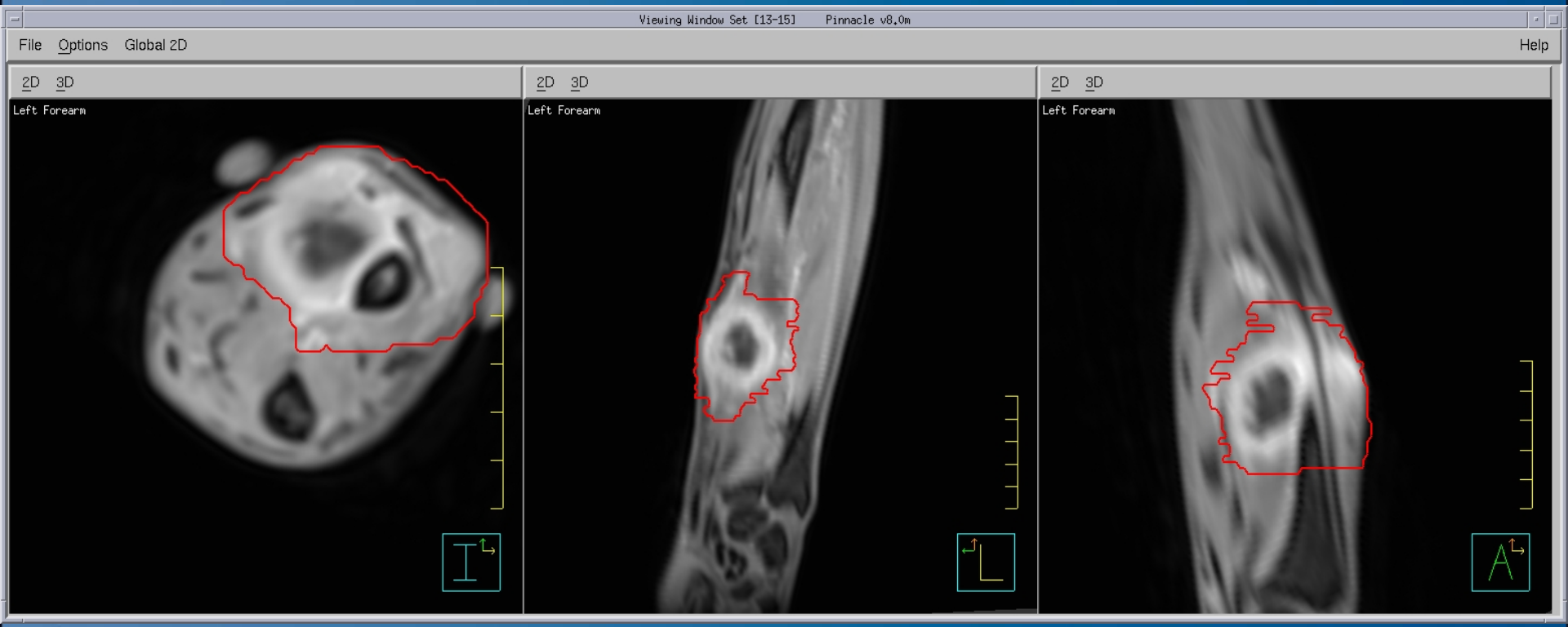

Morphological Changes During RT

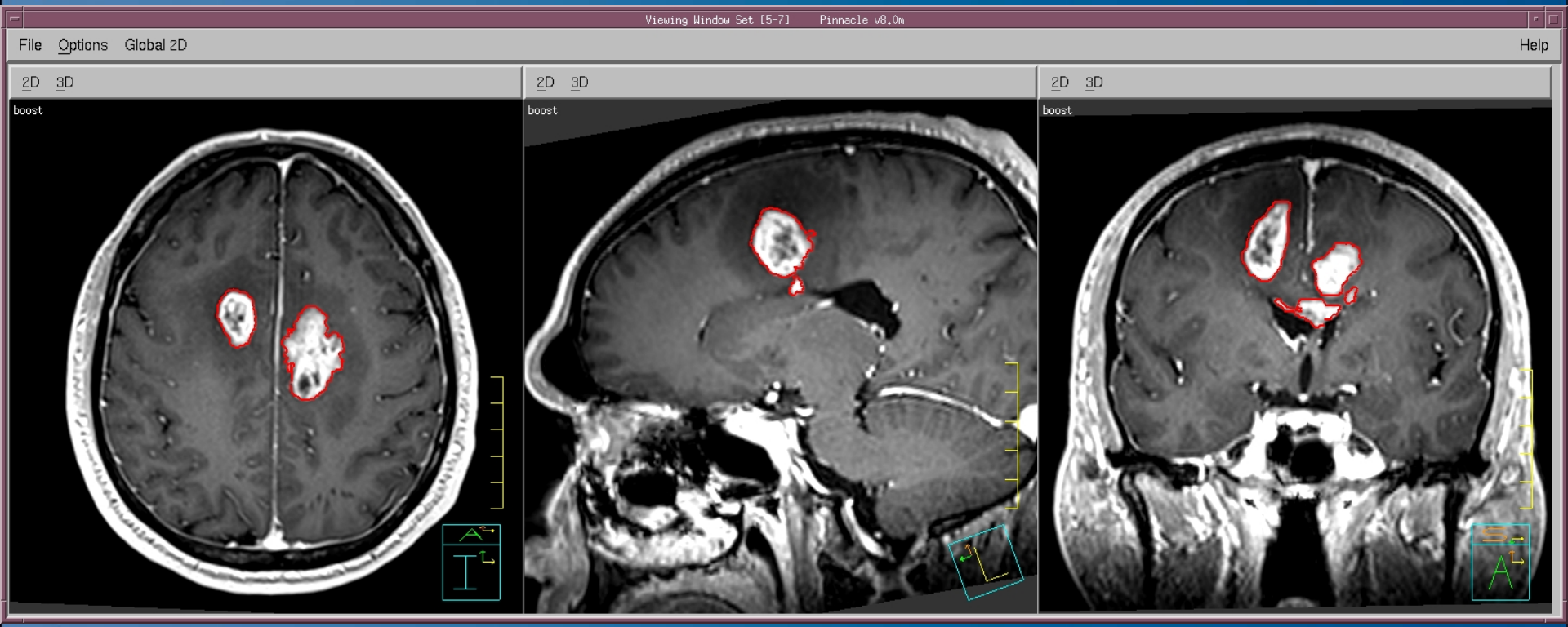

Morphological Imaging - Pelvis

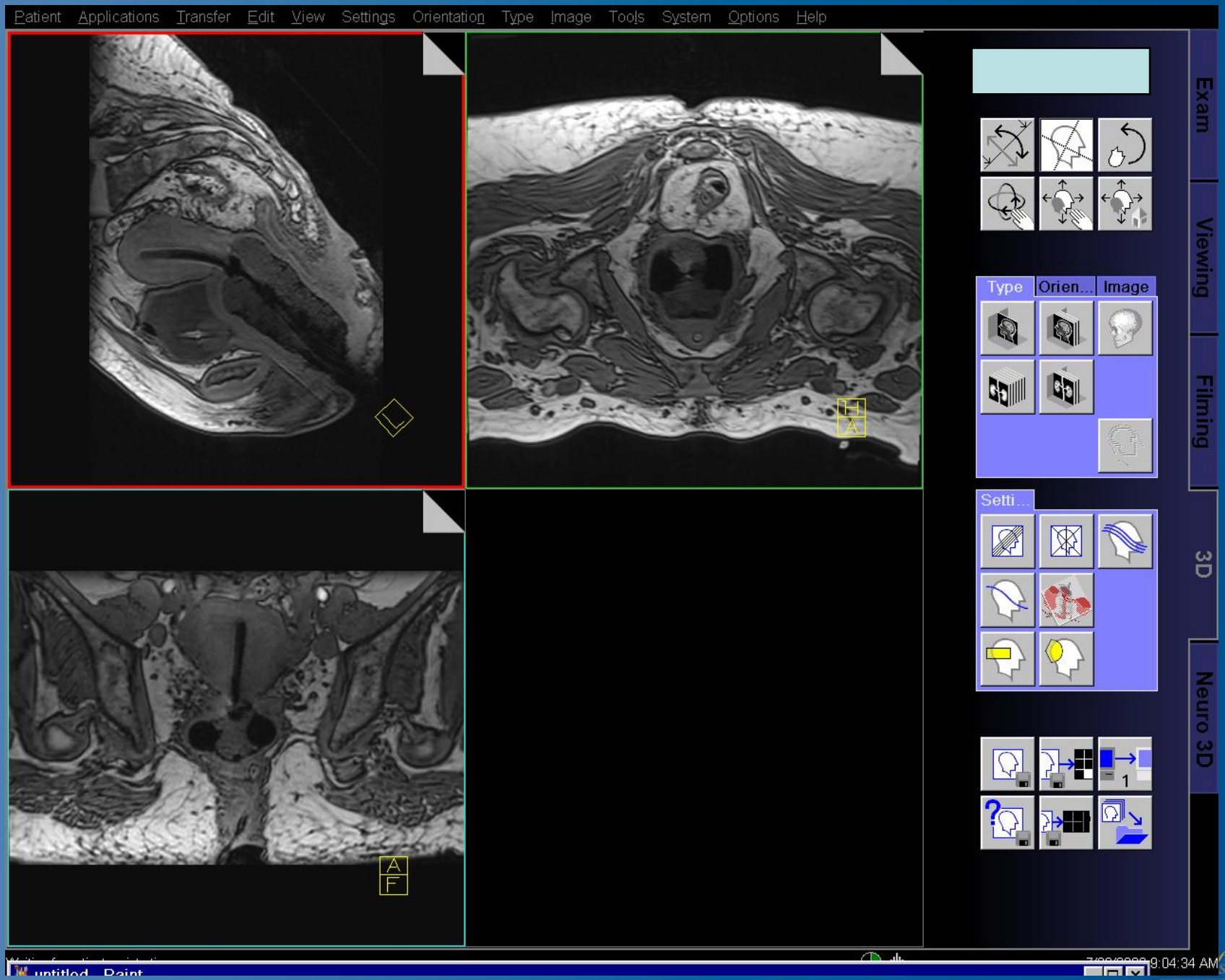
Patient Applications Transfer Edit View Settings Orientation Type Image Tools System Options Help
Exam
Viewing
Filming
3D
Neuro 3D
Type
Orien...
Image
Setti...
L
H
A
A
F
9:04:34 AM

T1 MRI of Pancreas – Free Breathing

T1 MRI of Pancreas –Breath Hold

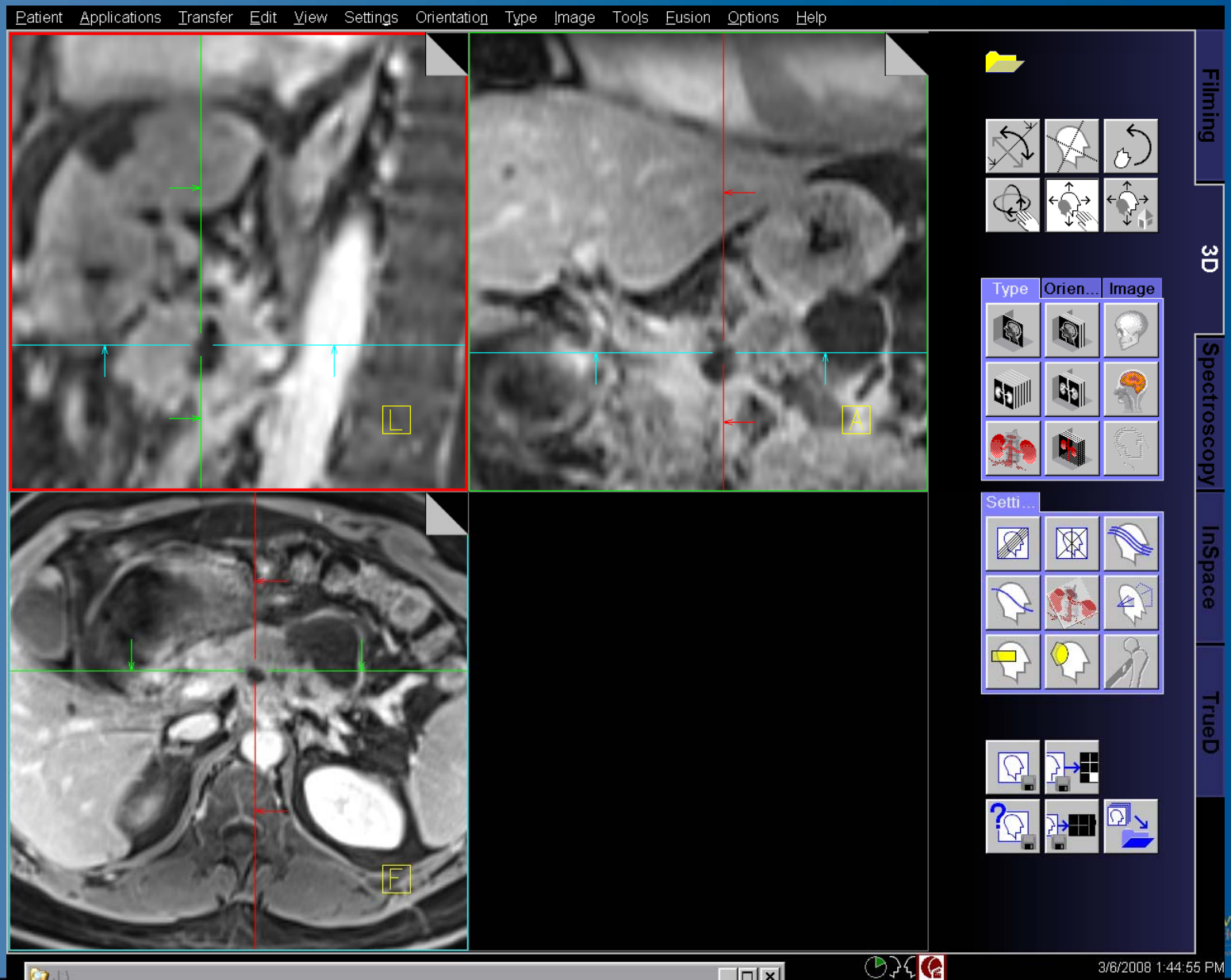

Magnetic Resonance Spectroscopic Imaging

- ***N*-acetyl-aspartate, NAA,**
- **neuronal integrity**
- **choline - cell membrane**
- **creatine / phosphocreatine**

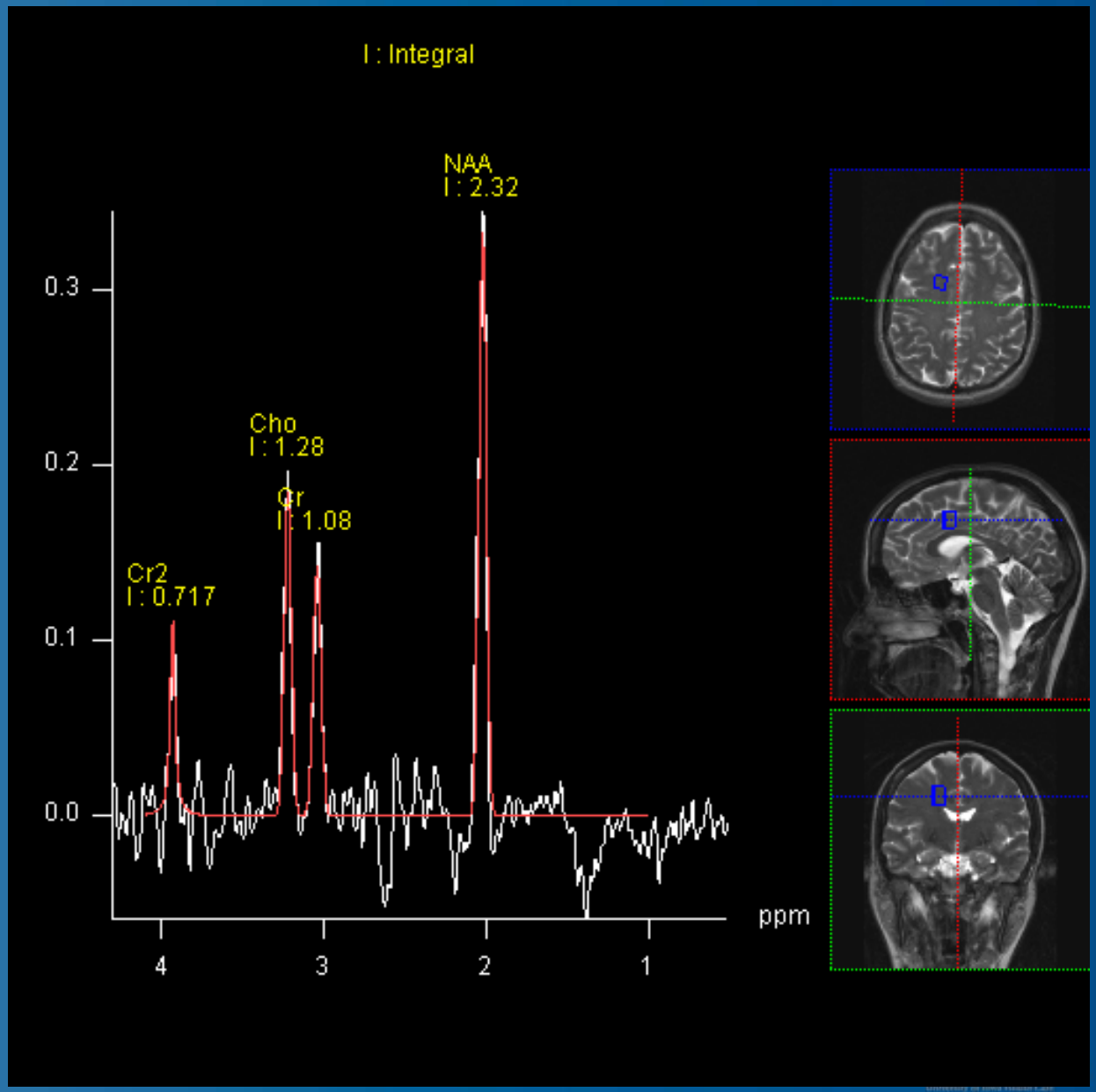

Patient Applications Transfer Edit View Image Tools Scroll Options Help

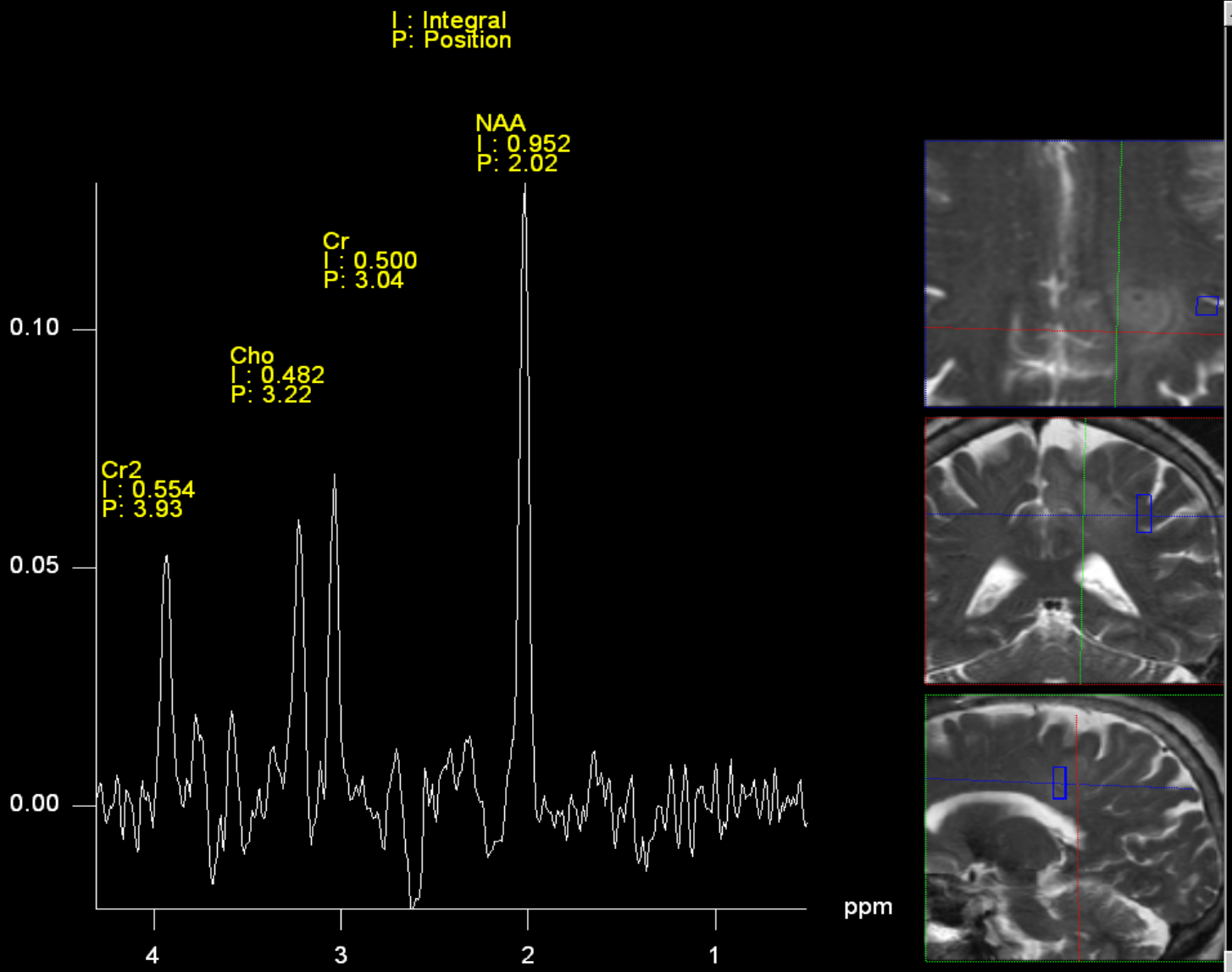

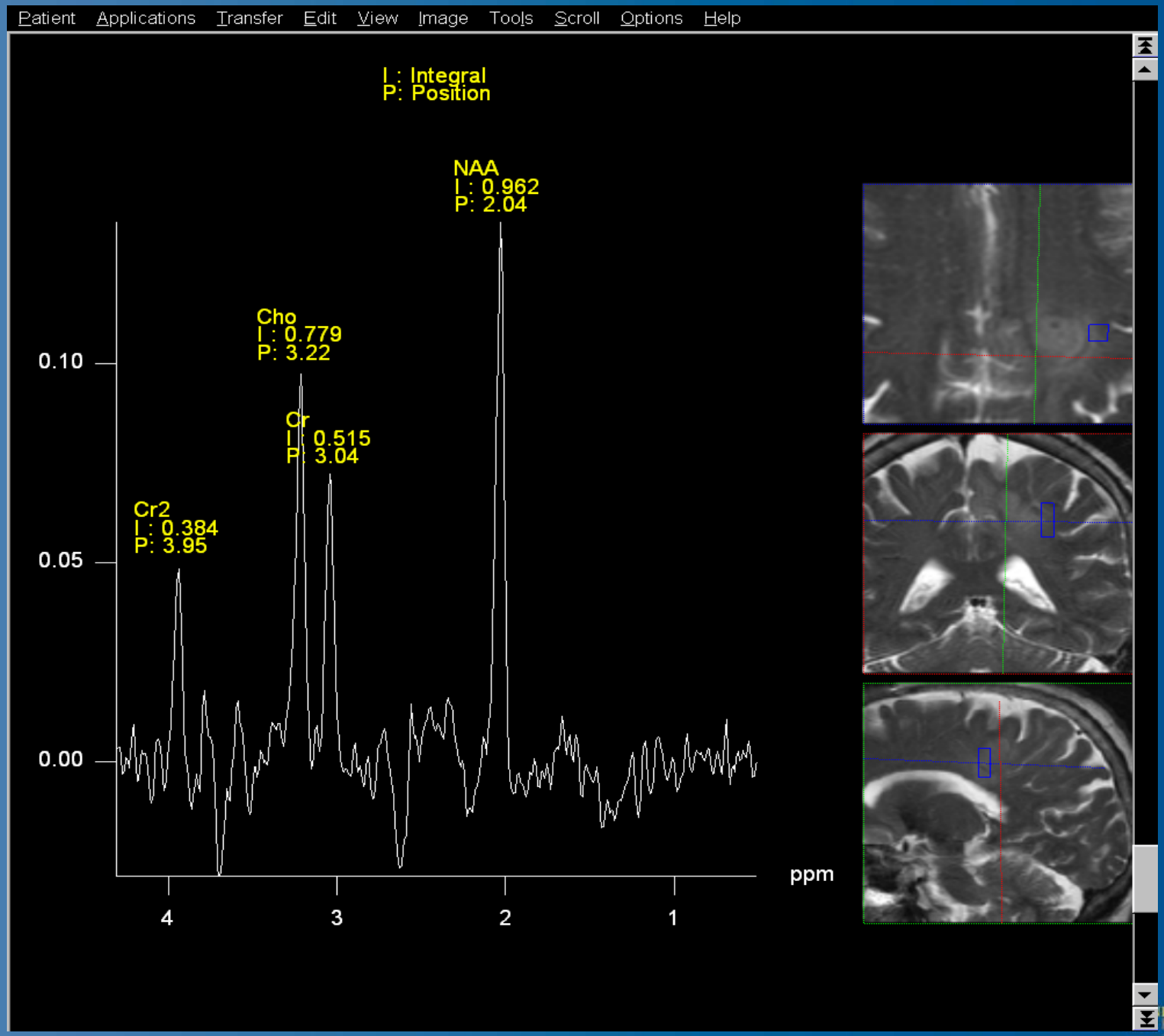

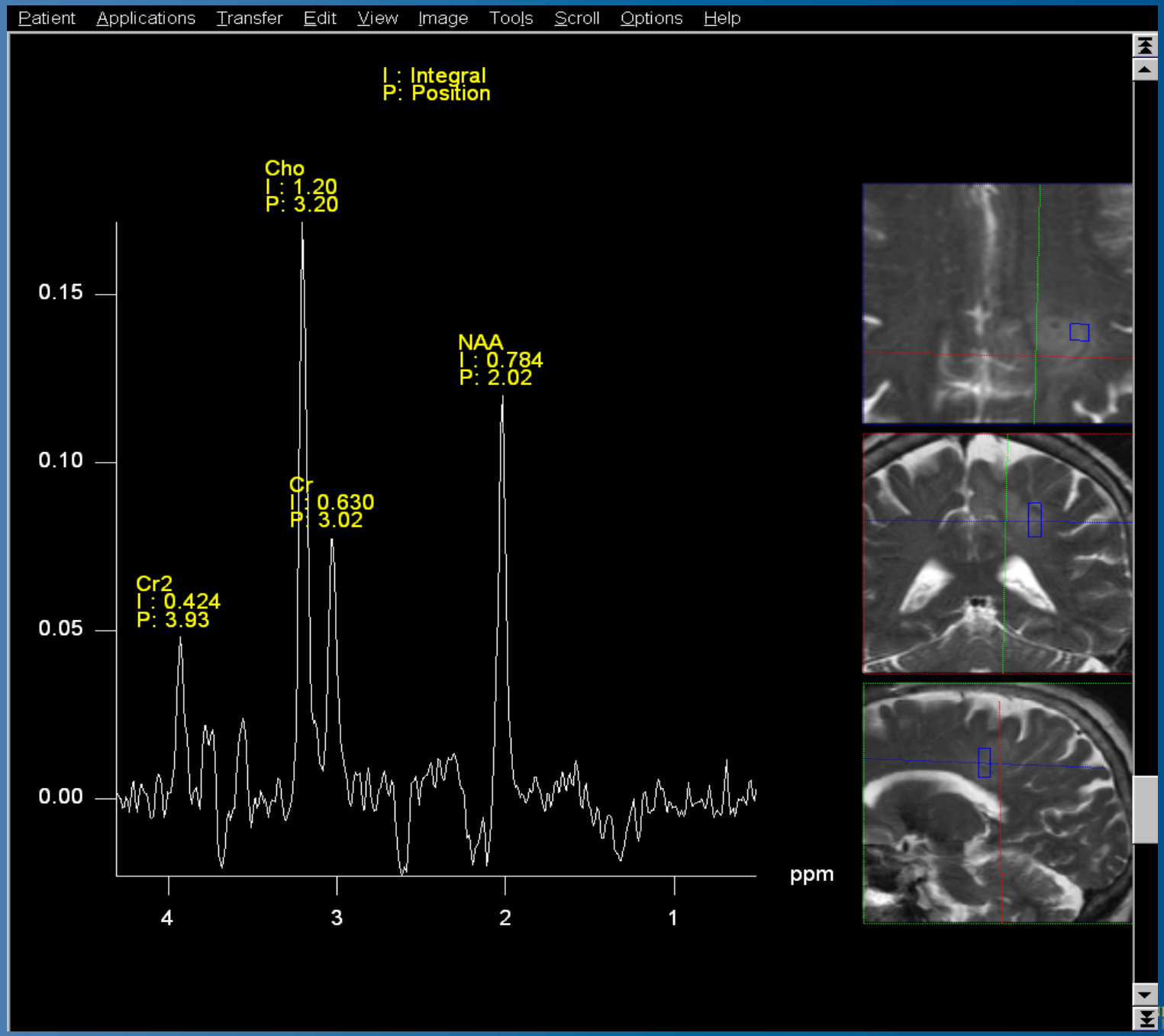

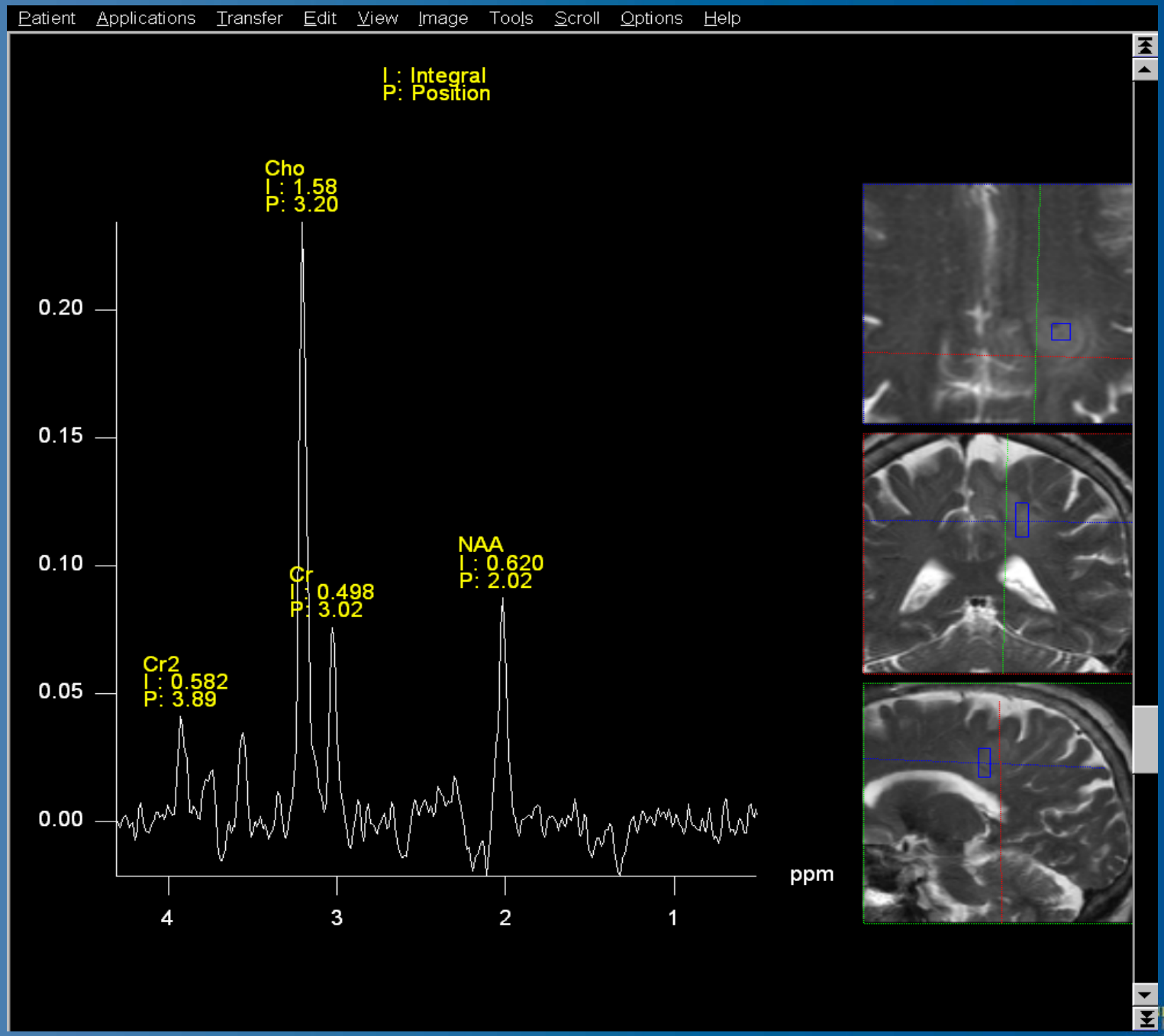

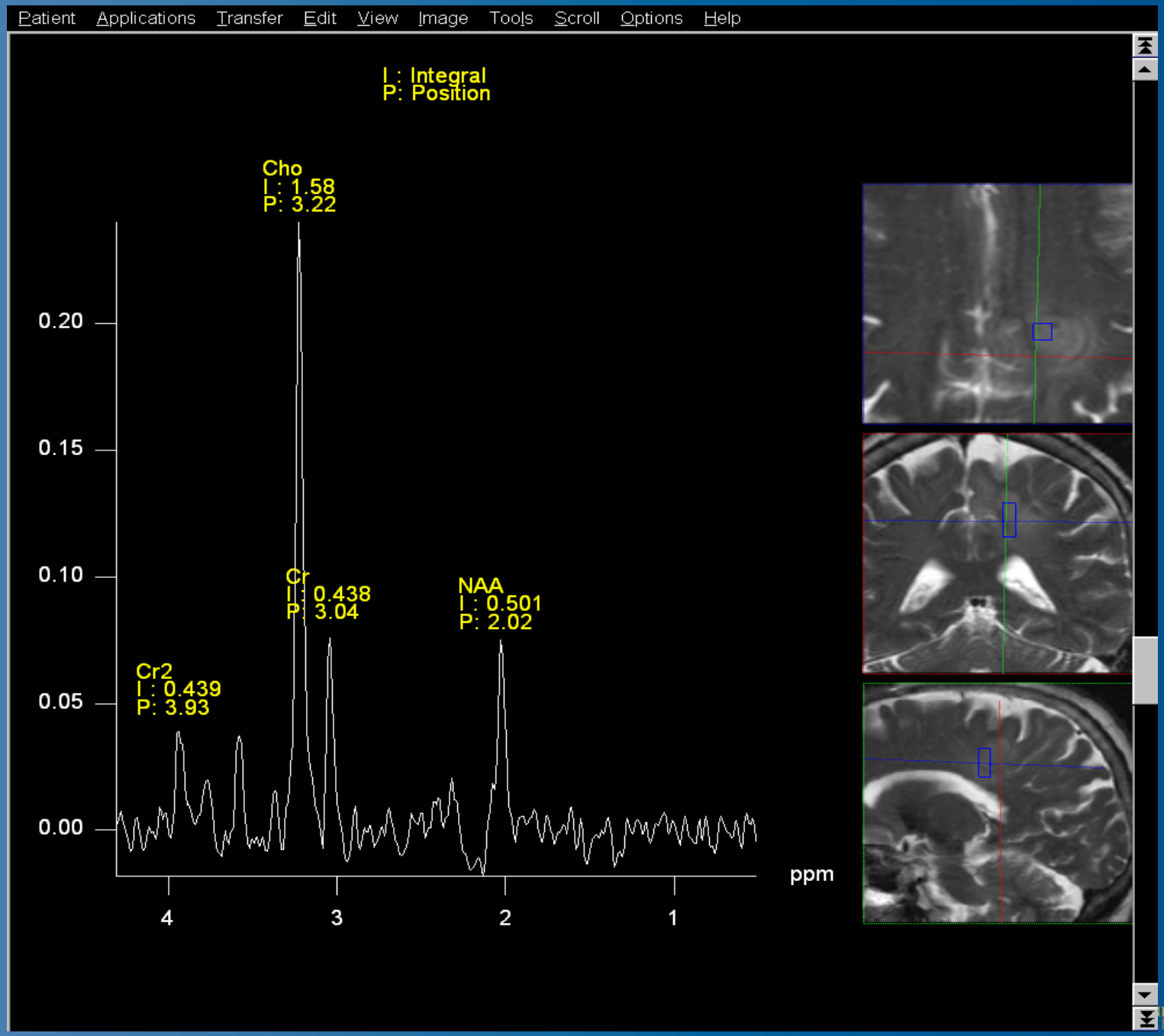

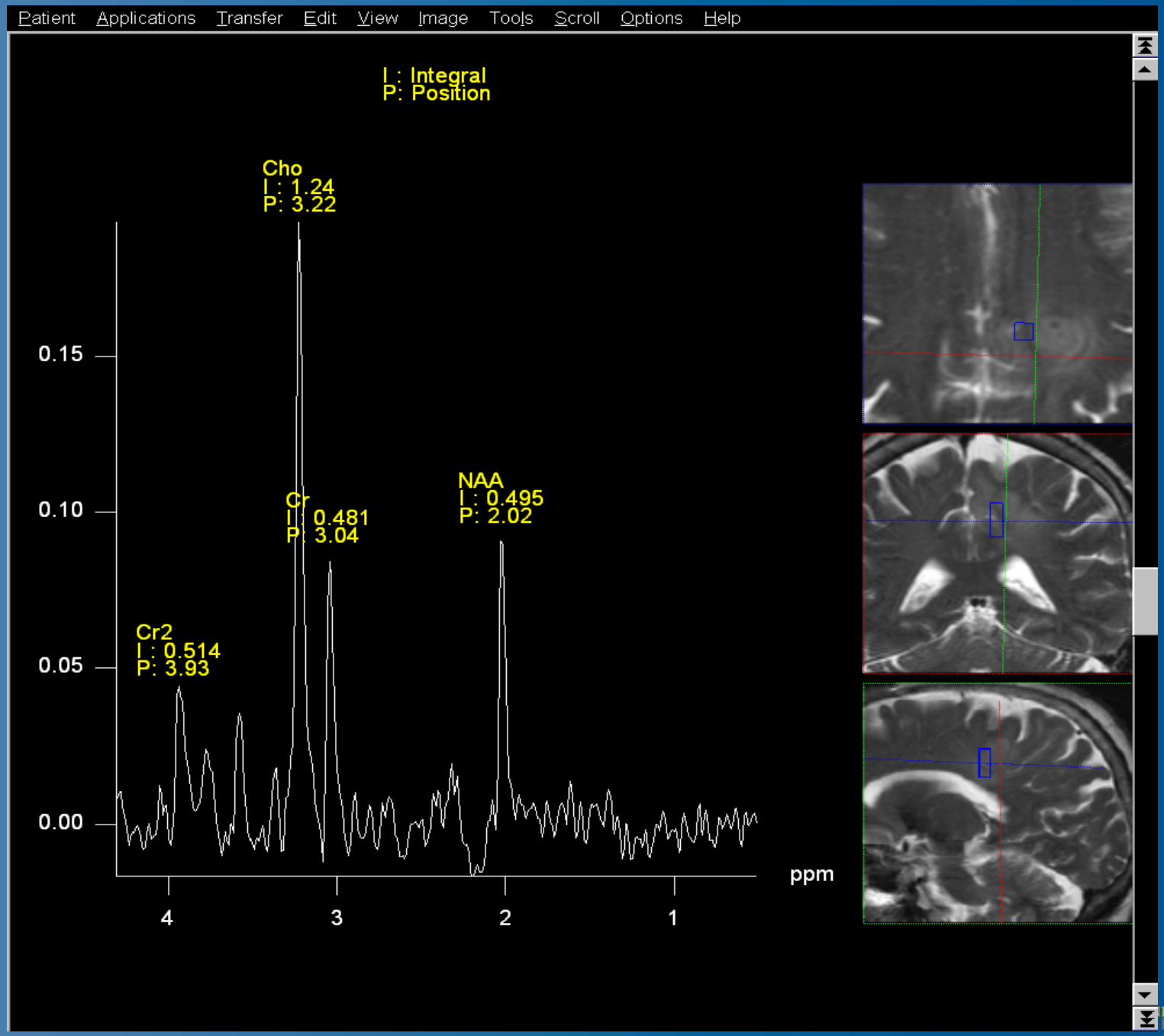

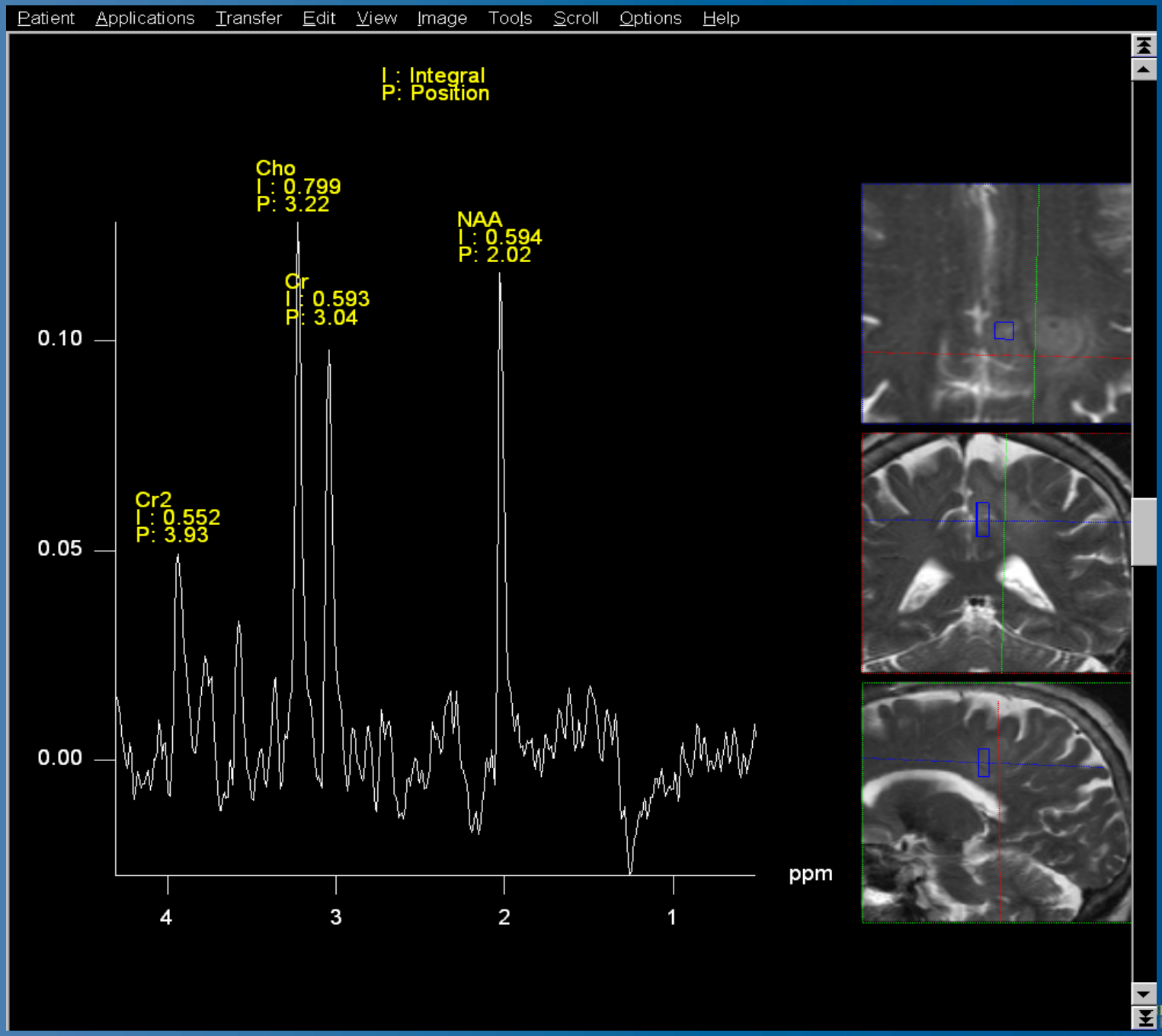

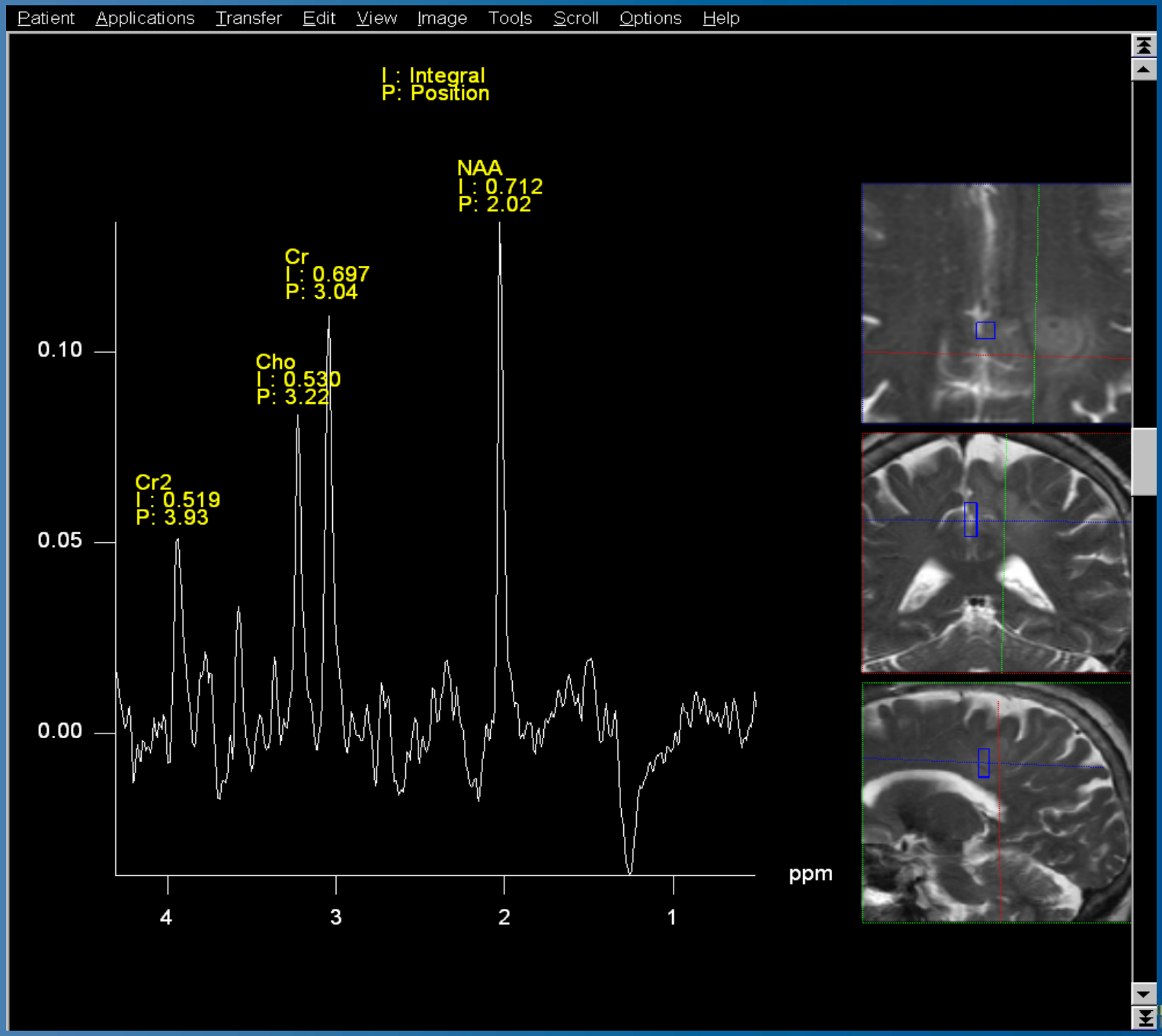

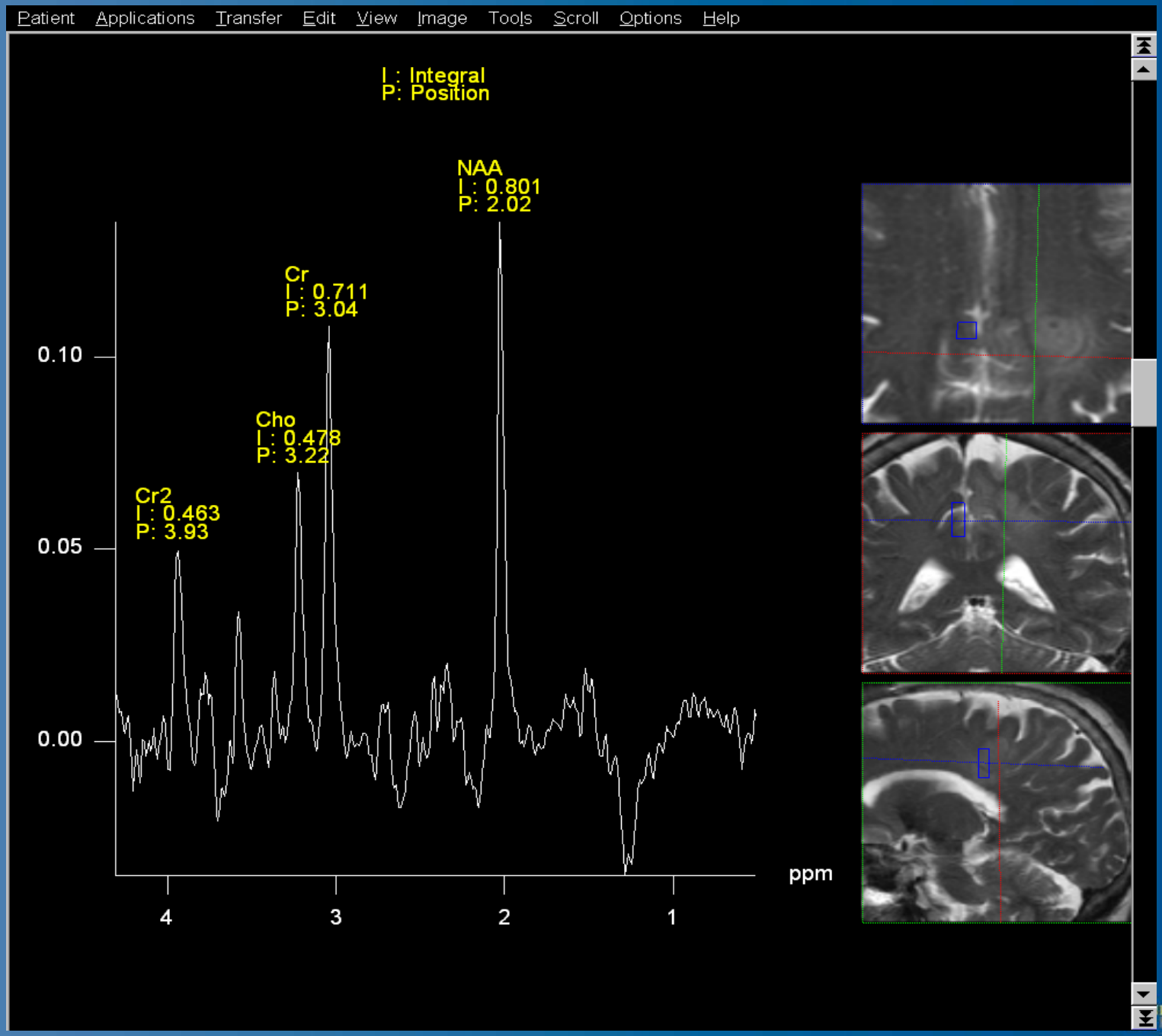

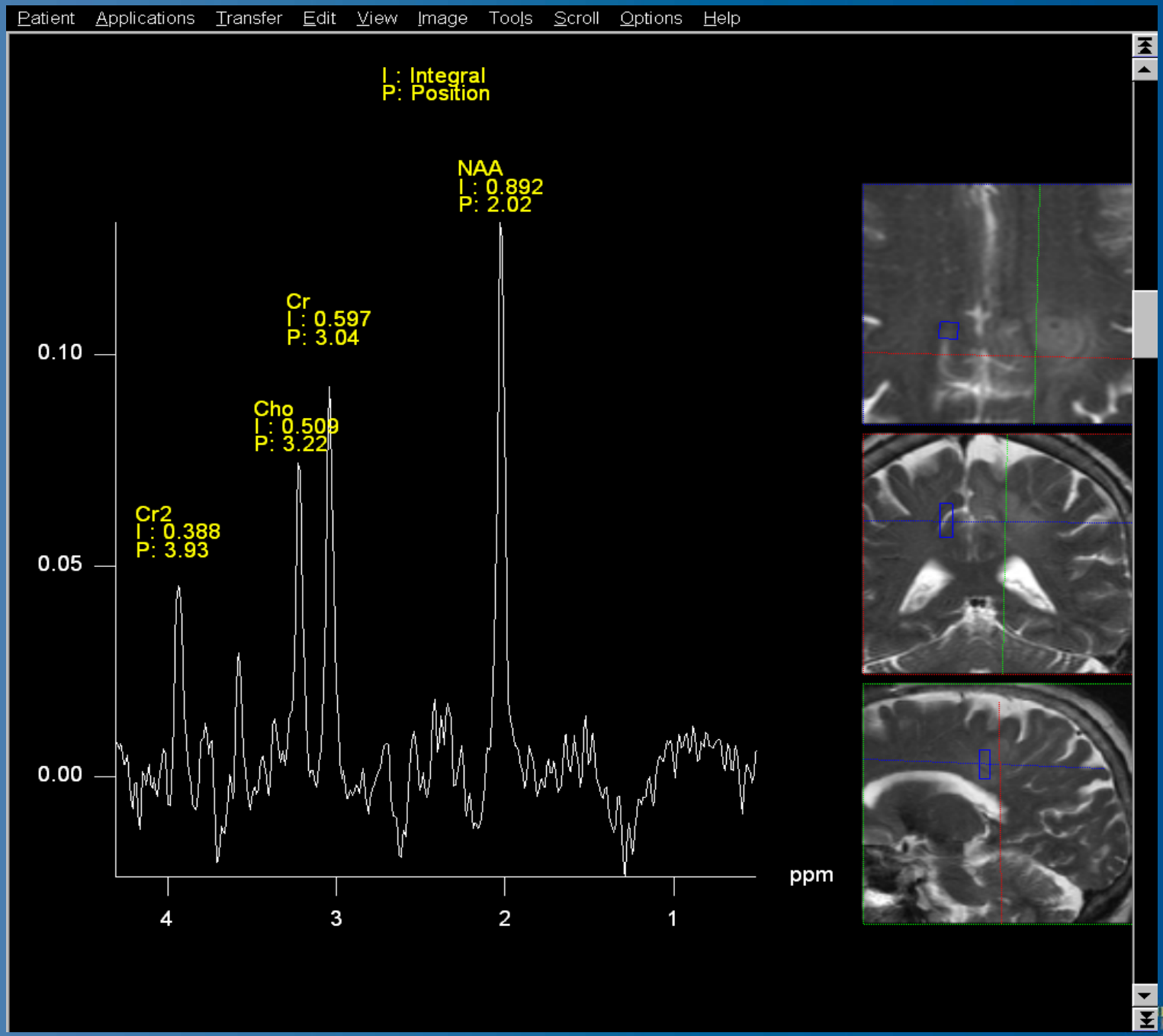

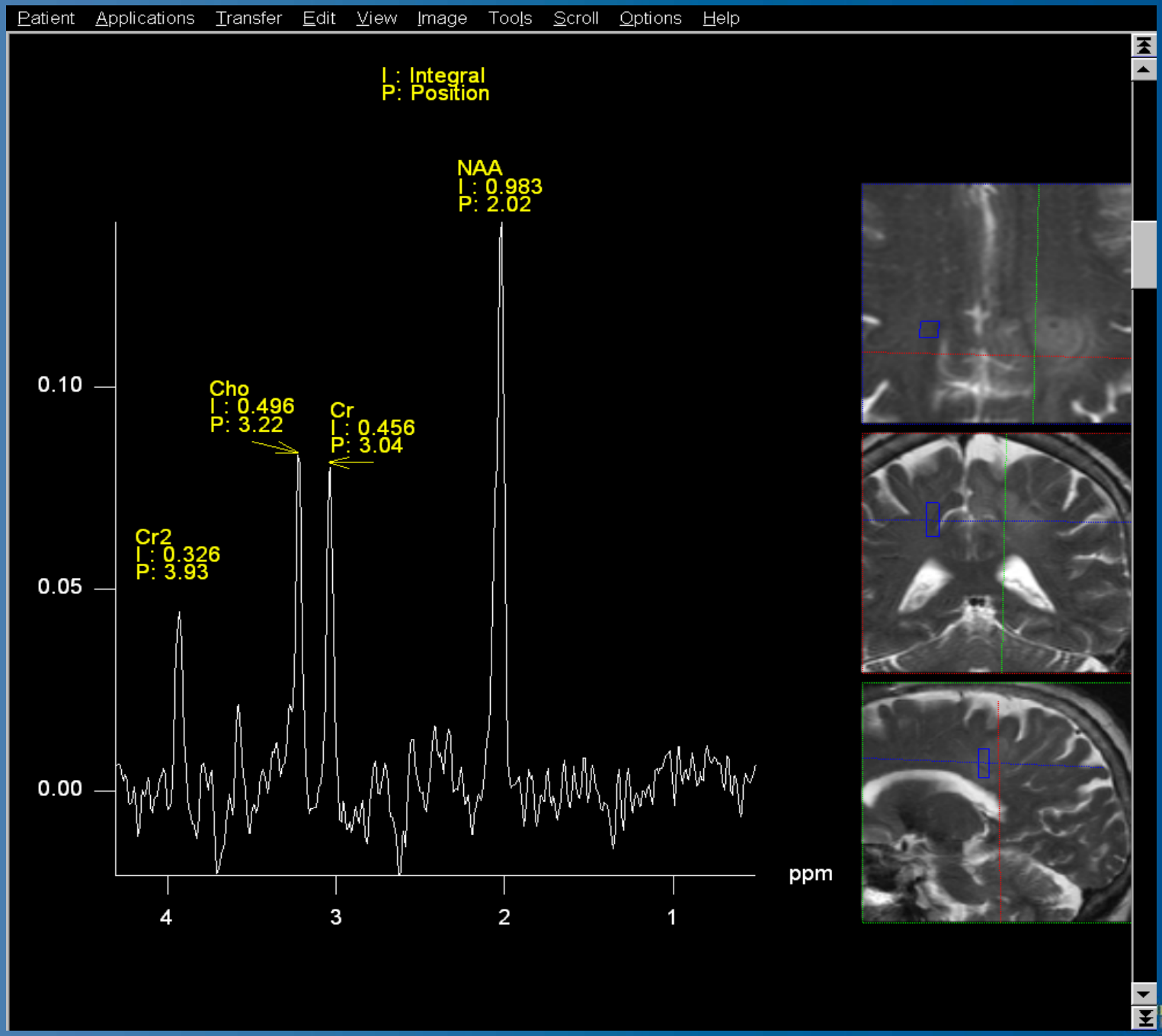

Iso-metabolite Map - GBM

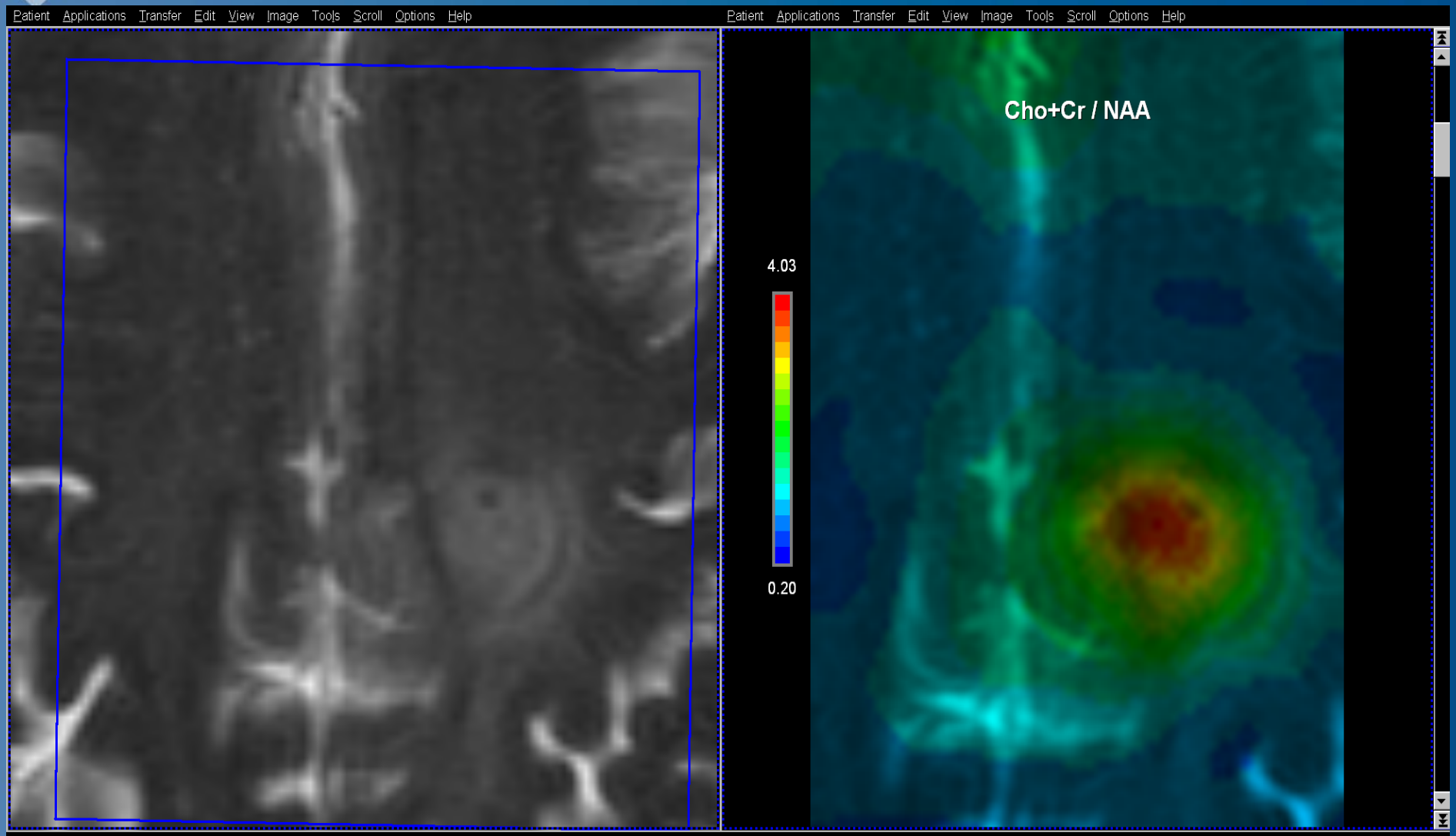

MRSI of Recurrent Glioblastoma

Case #1

Disease extend beyond the region of T_1 contrast enhancement

CE-T1

Cho/NAA

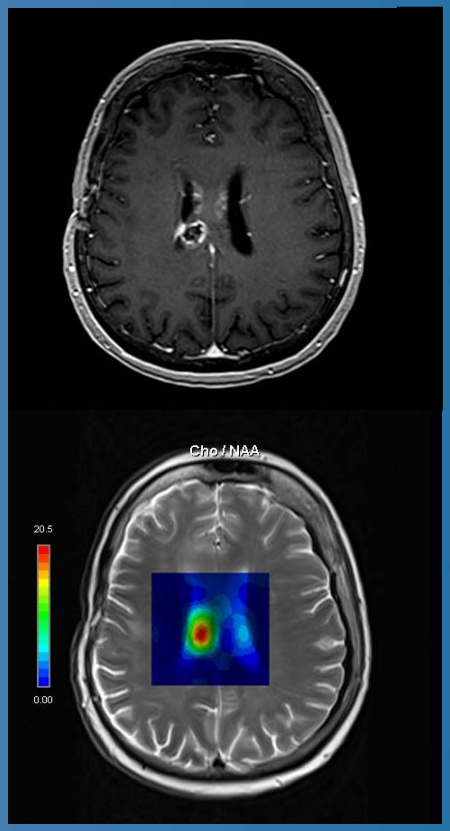

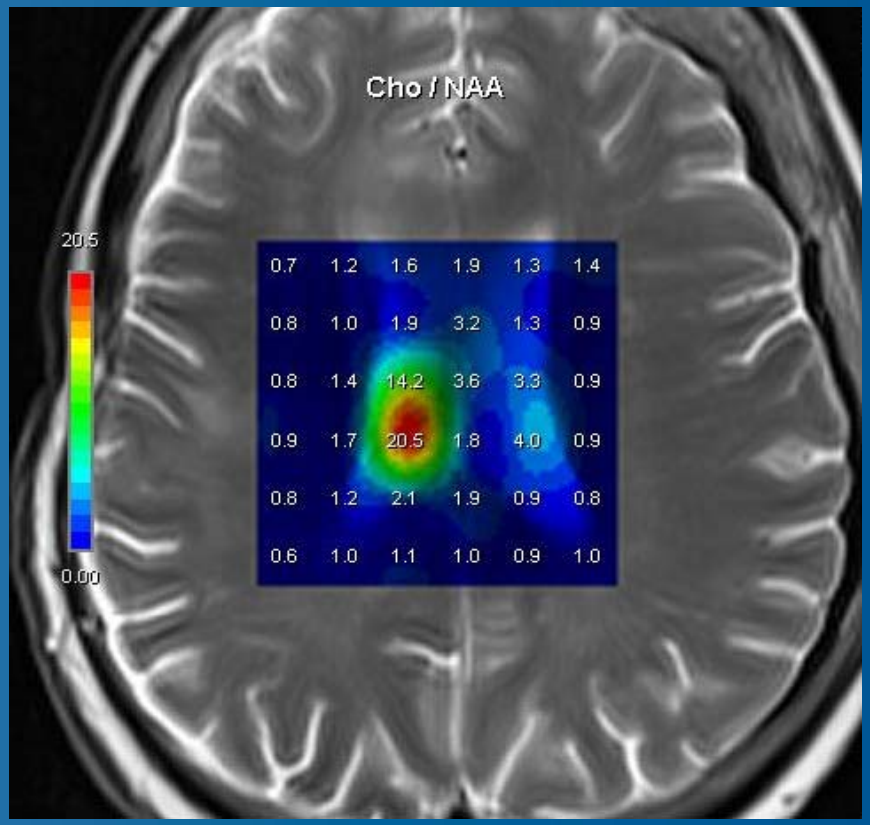

MRSI of Glioblastoma

Case #2

61 yr old Female with disease progression ~2 yr post RT

T2

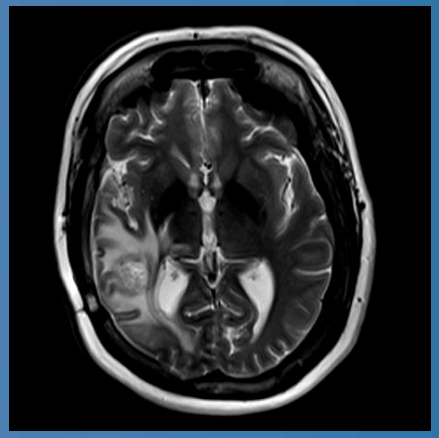

CE-T1

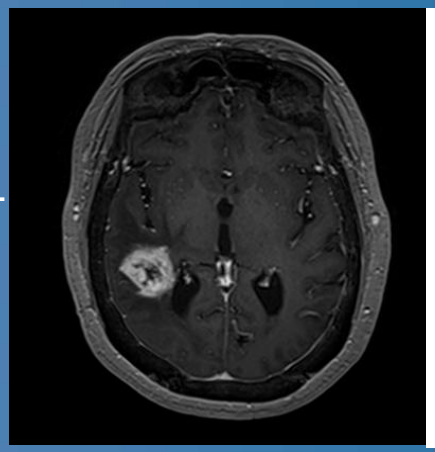

Moderate CNI

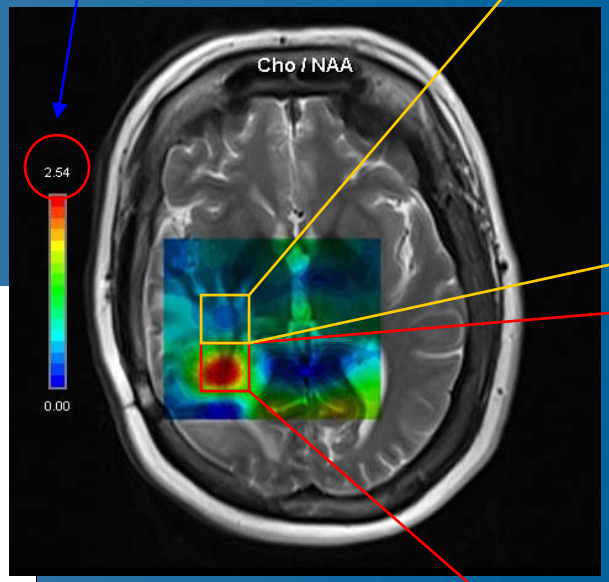

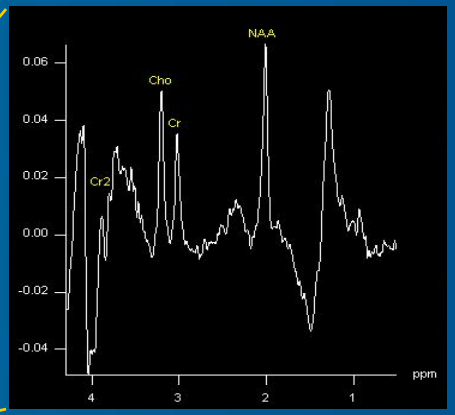

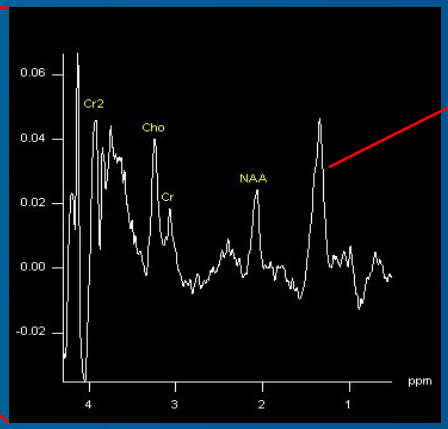

Lipids

Possible post- XRT necrosis!

Contouring the Tumor: Morphology vs. Biology

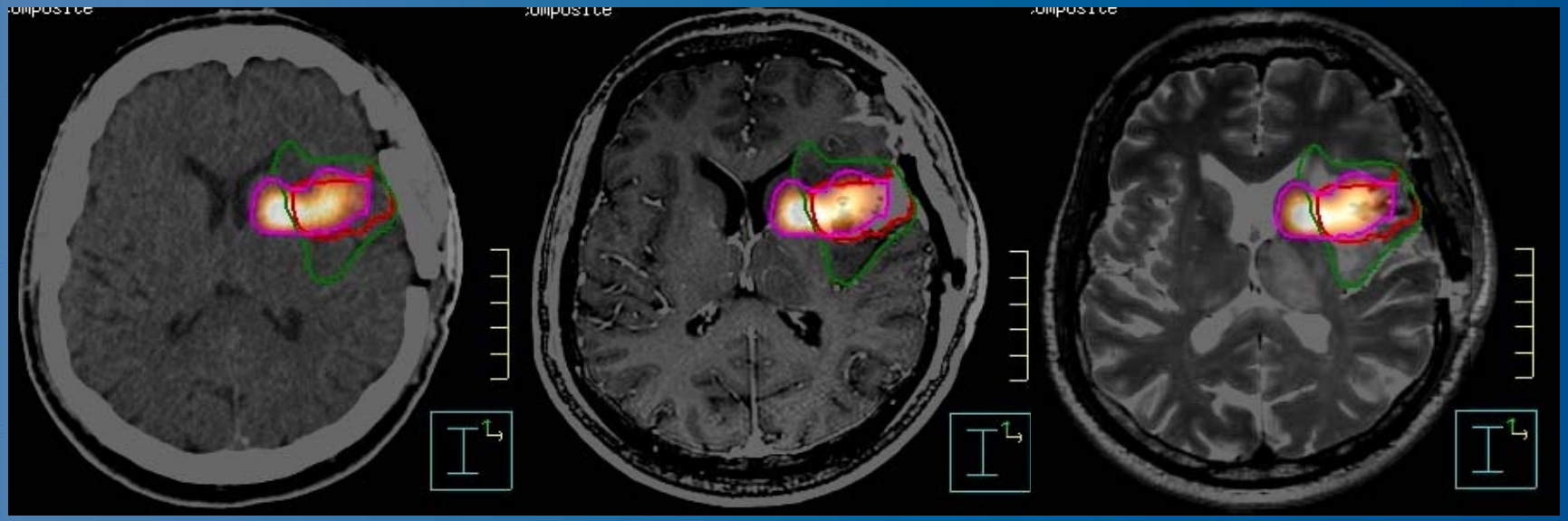

Comparison of conventional CT and MR based GTV, CTV with MRSI derived Choline-to-NAA maps. MRSI fused with CT (left), T1-contrast enhanced MRI (middle), and T2-MRI of rim enhancing GBM lesion. Contours: Cho:NAA = 2.0 → purple, GTV → red, and CTV → Green. Note significant portion of metabolically active tumor fall outside both GTV and CTV.

Contouring the Tumor: Morphology vs. Biology

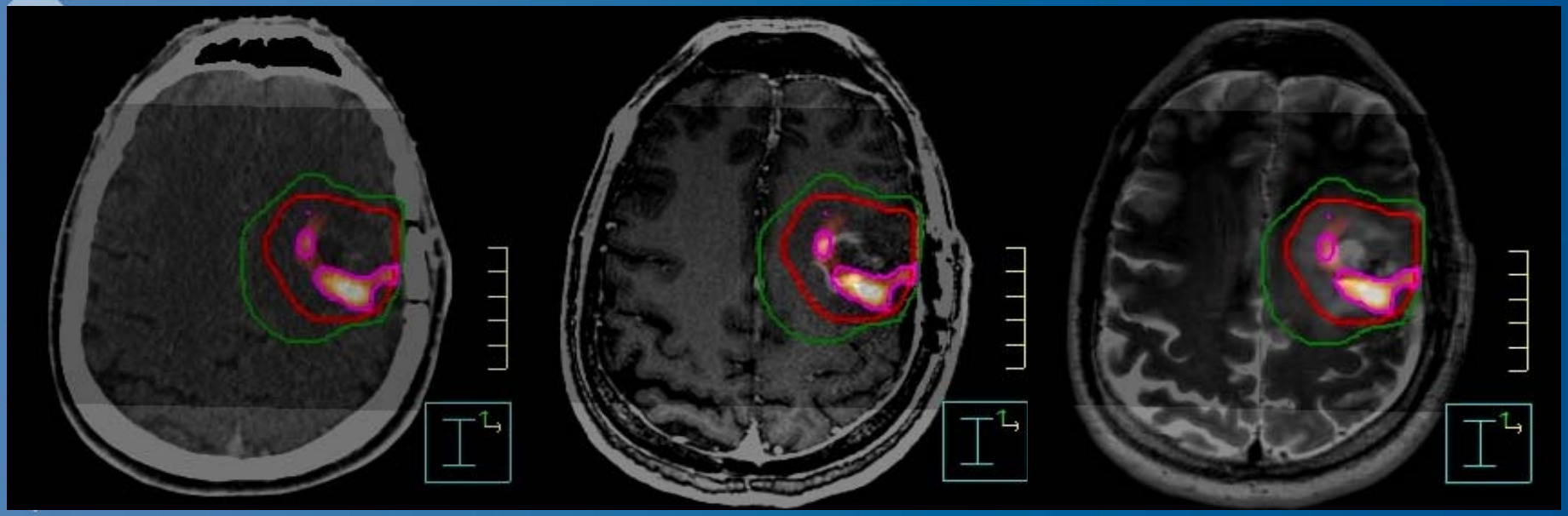

Metabolically active tumor volume covered well within GTV & CTV. MRSI Choline-to-NAA maps fused with CT (left), T1-contrast enhanced MRI (middle), and T2-MRI of rim enhancing GBM lesion. Contours: Cho:NAA= 2.0 → purple, GTV → red, and CTV → Green.

Contouring the Tumor: Morphology vs. Biology

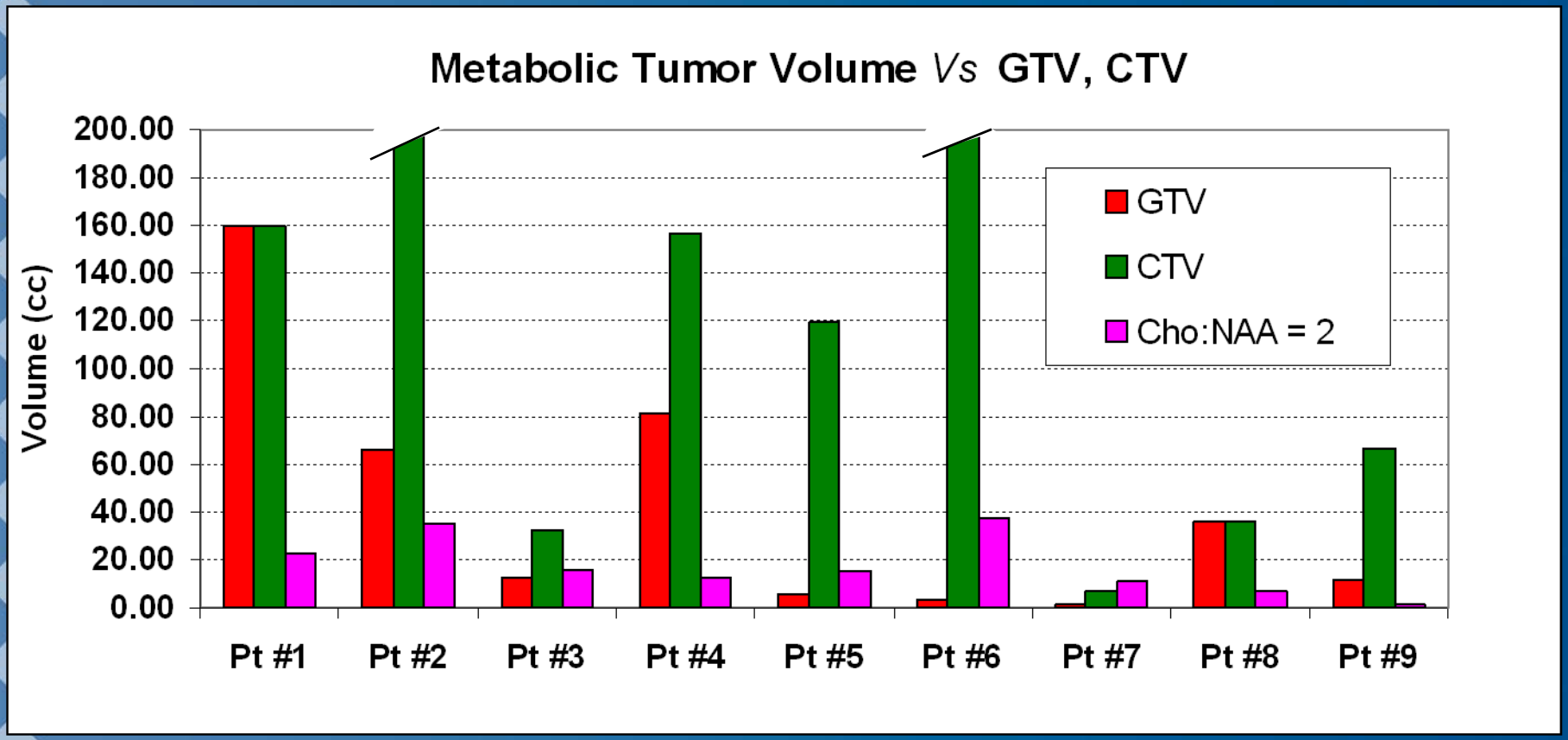

Contouring the Tumor: Morphology vs. Biology

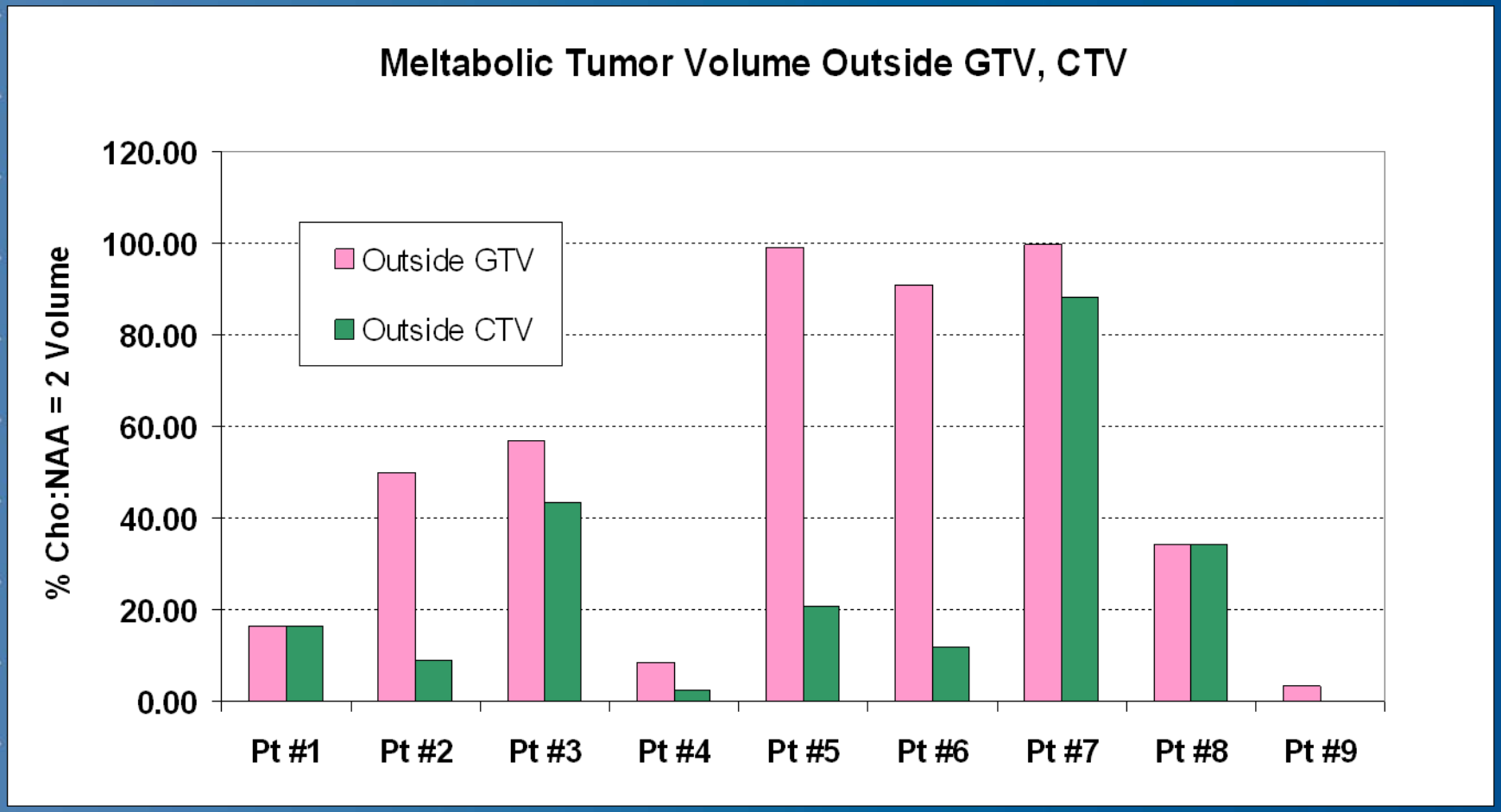

MRSI – Effects of Susceptibility Mismatch

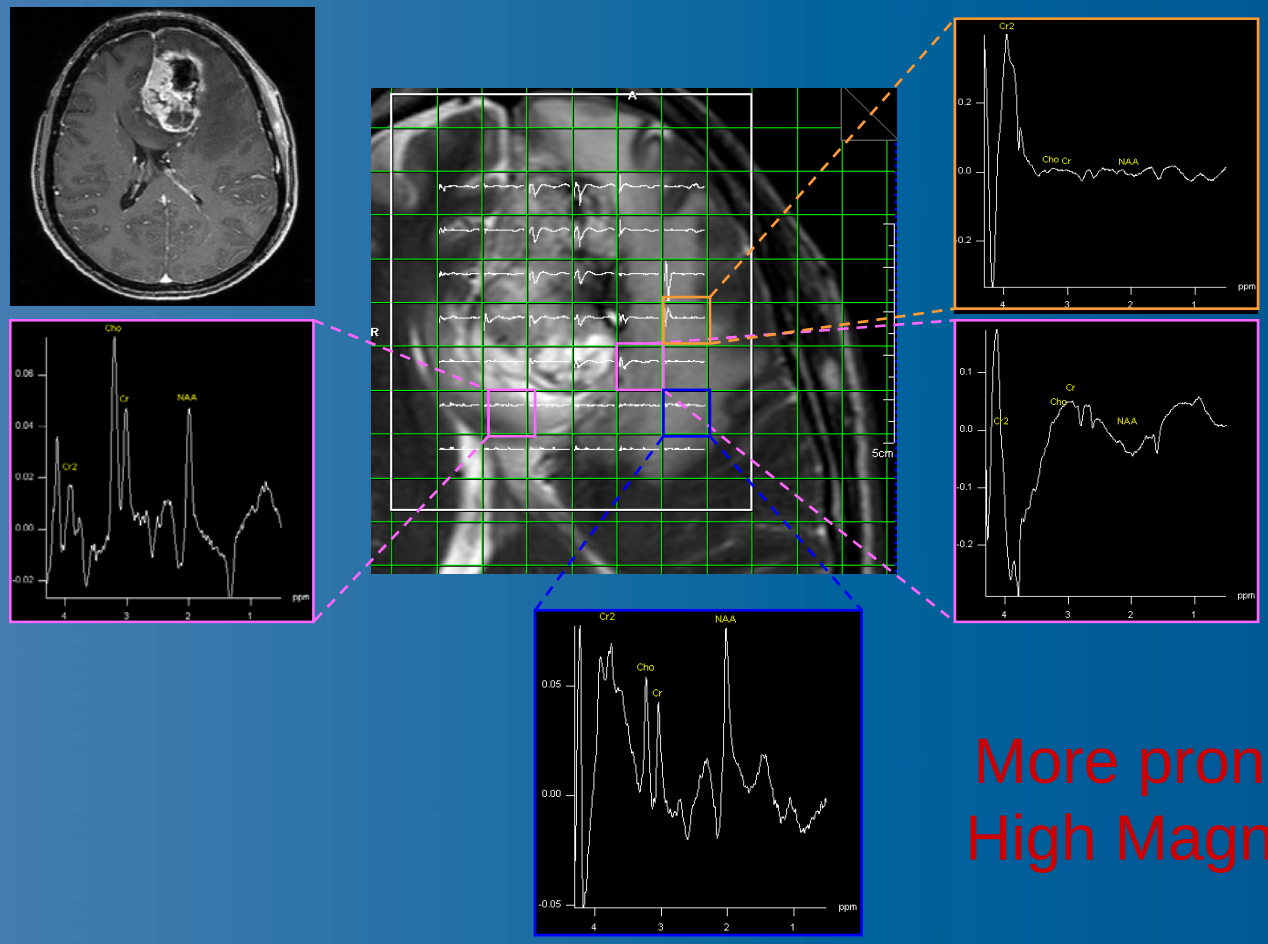

More pronounced @
High Magnetic Field !

Patient Applications Signal Image Protocols Post-processing Syste

I: integral

Cho
I: 0.704

NAA
I: 0.491

Cr
I: 0.379

Cr2
I: 0.505

0.10
0.05
0.00

4 3 2 1

ppm

Post-processing steps

- Water reference processing
- Filter
- Zero-filling
- Fourier transformation
- Frequency shift correction
- Baseline correction
- Phase correction
- Curve fitting

Curve fitti

Calculation range: 1.00 - 4.10 pp

Peak list: Start values > Result value

Peak	Pos/ppm	Amplitude	Width/Hz	Integ
NAA	2.02	0.07	6.20	0.4
Cr	3.04	0.06	5.70	0.3
Cho	3.22	0.10	6.60	0.7
Cr2	3.93	0.05	7.10	0.5

Add... Edit... Delete Hi

Show: Name Pos. Ampl. Width

Break Apply Reset

A

R

5cm

3D

Spectroscopy

Patient Applications Signal Image Protocols Post-processing Syste

I: Integral

Cho
I: 1.18

Cr
I: 0.327

Cr2
I: 0.683

NAA
I: 0.338

0.15
0.10
0.05
0.00

4 3 2 1 ppm

Post-processing steps

- Water reference processing
- Filter
- Zero-filling
- Fourier transformation
- Frequency shift correction
- Baseline correction
- Phase correction
- Curve fitting

Phase corre

Constant phase:	-140.00	deg
Lin. freq. dep. phase:	0.00	deg
Reference frequency:	3.24	ppm
Frequency interval:	1.2	ppm

Keep voxel specific

Break Apply Reset

Delt
Delta
De
Au
Fitti

A
R
5cm

3D
Spectroscopy

So now the MD's want to begin using MRSI data in treatment planning…

- Issues to be addressed when using MRSI clinically:
  - Shimming to achieve uniform magnetic field
  - Finding the peak for each resonance frequency
  - Phase adjustment
  - Spatial distortion
  - Integration into RT planning
  - Fighting with Radiology
  - Buying your own MRI scanner
  - Finding an MRI physicist to work in Radiation Oncology

Data acquisition

↓

Post-processing

↓

Integration into treatment planning

MRSI Integration into Planning

Generation of Metabolic Maps

Normalize E abolic Scale

De on

Re-sample anning CT

Contour Voxels Based On Metabolic Scale

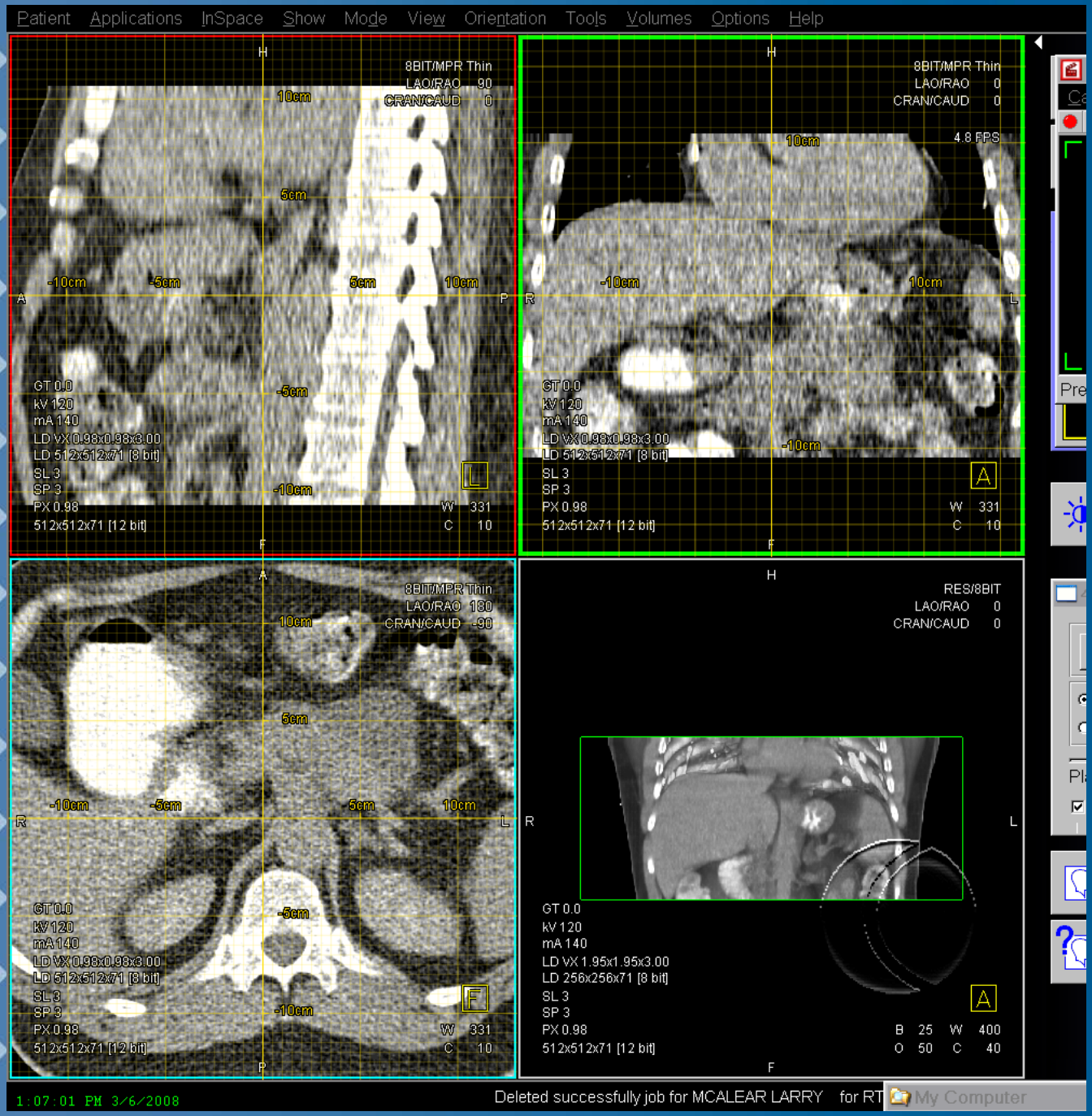

Imaging of Moving Anatomy

3 reasons for MRI

UNIVERSITY of IOWA HOSPITALS & CLINICS

#1 Breath Hold - EXHALE

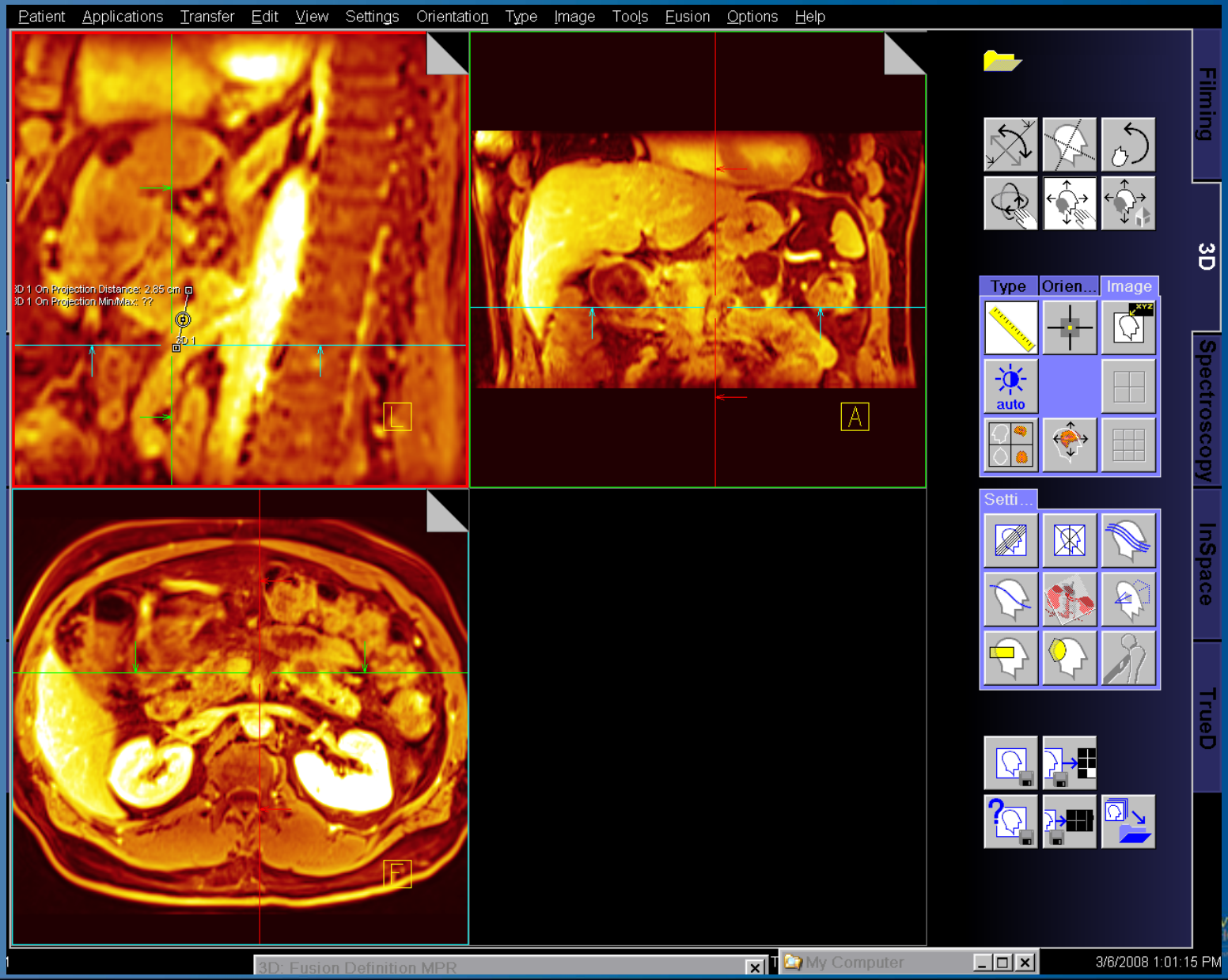

#1 Breath Hold - INHALE

#2 Cine-loop MRI

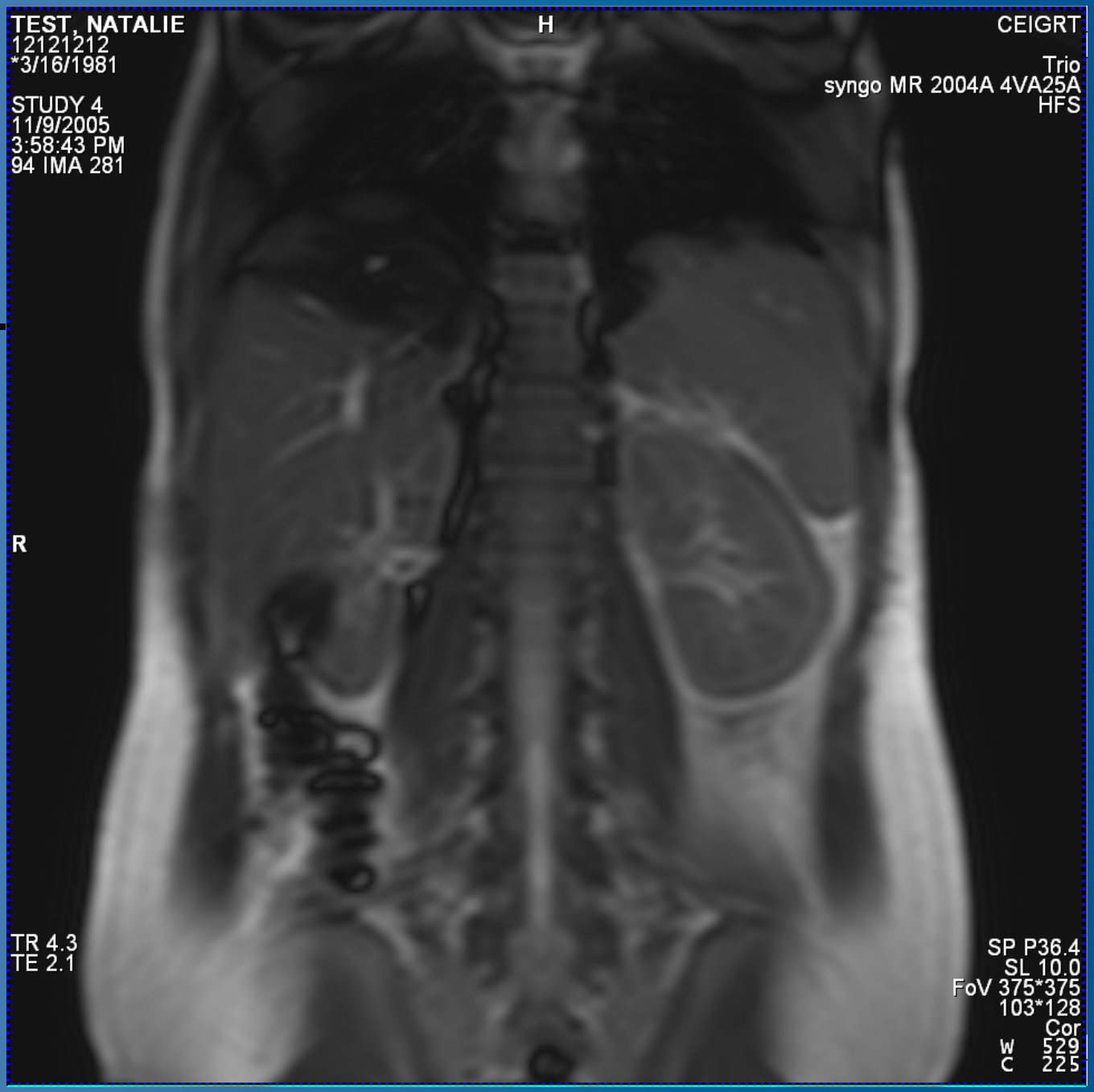

#2b Cardiac Gated MRI

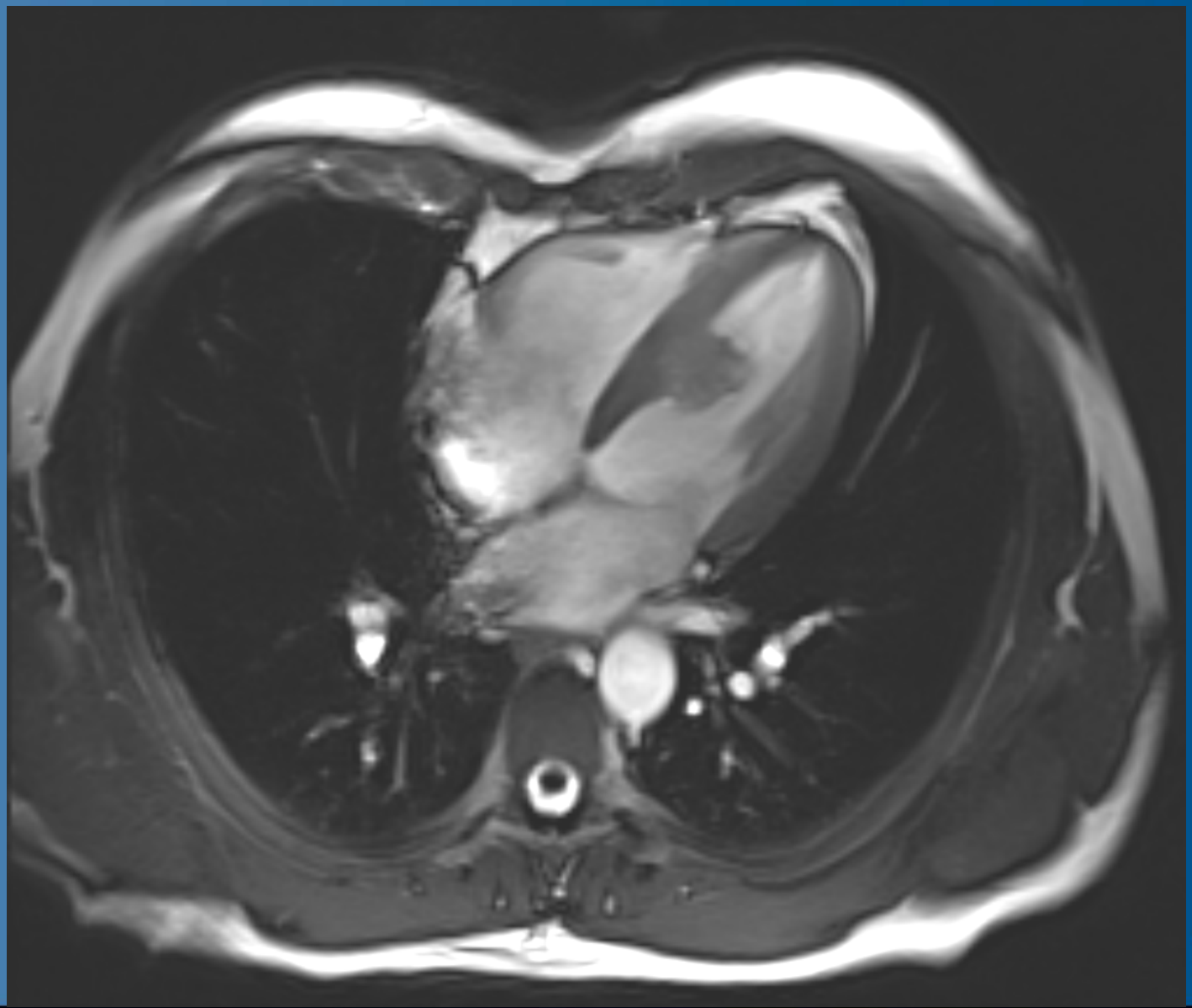

#3

MRI provides better geometry ?

#3

MRI provides better geometry!

MR-PET-CT

- Is there a role for all three imaging modalities in the simulation of Radiation Therapy treatment planning?

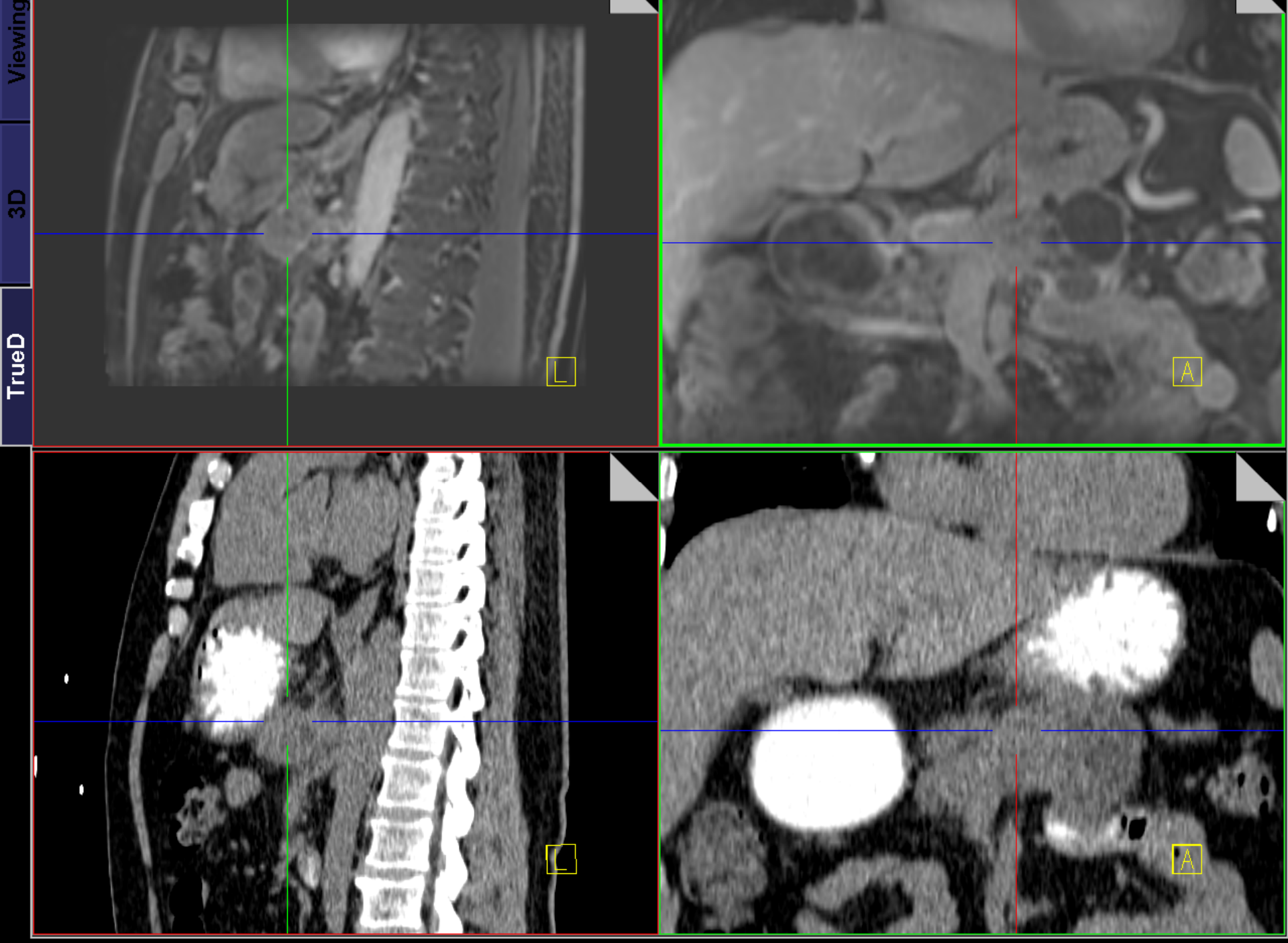
Viewing
3D
TrueD
L
A
L
A

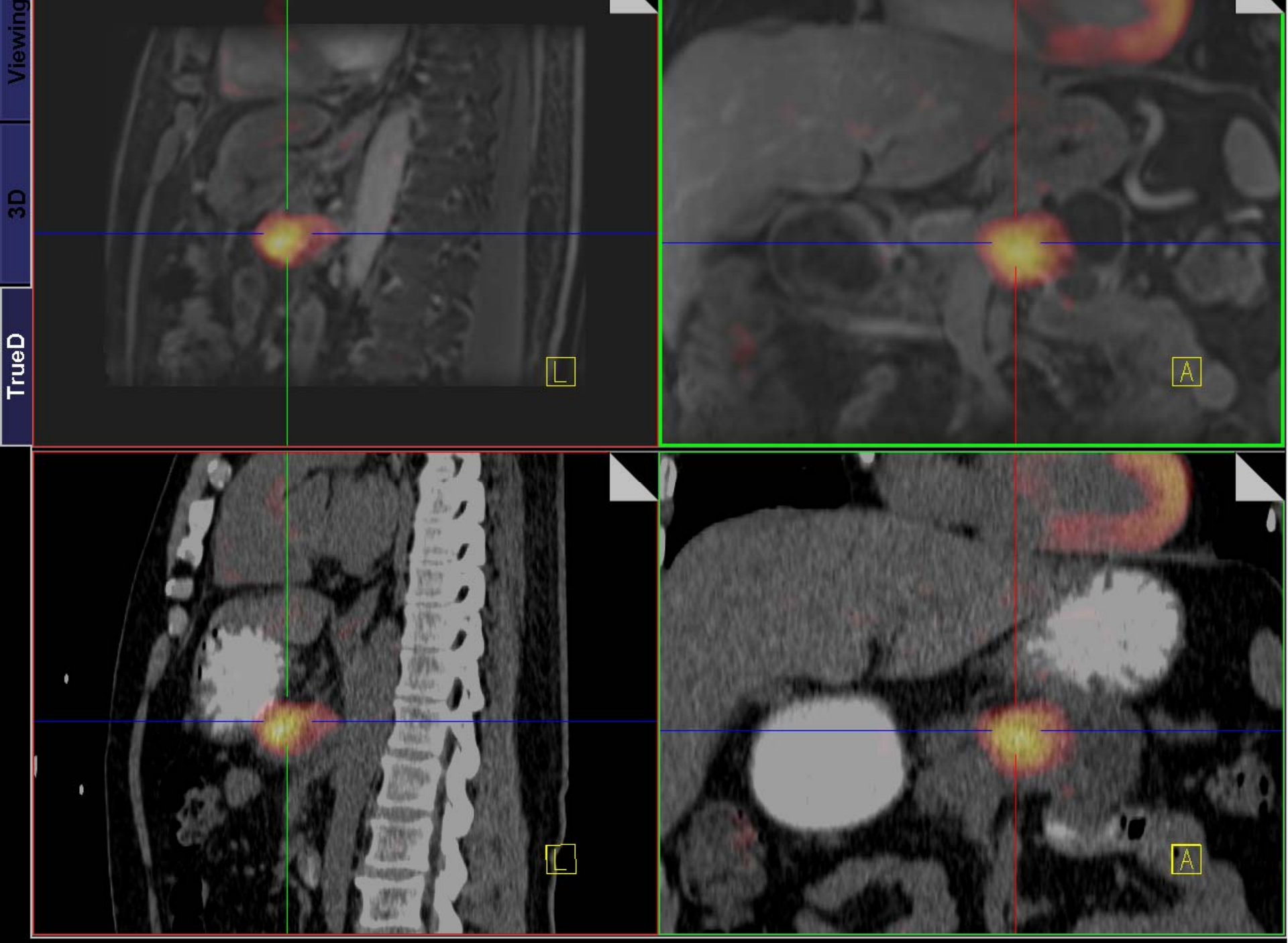
Viewing
3D
TrueD
L
A
L
A

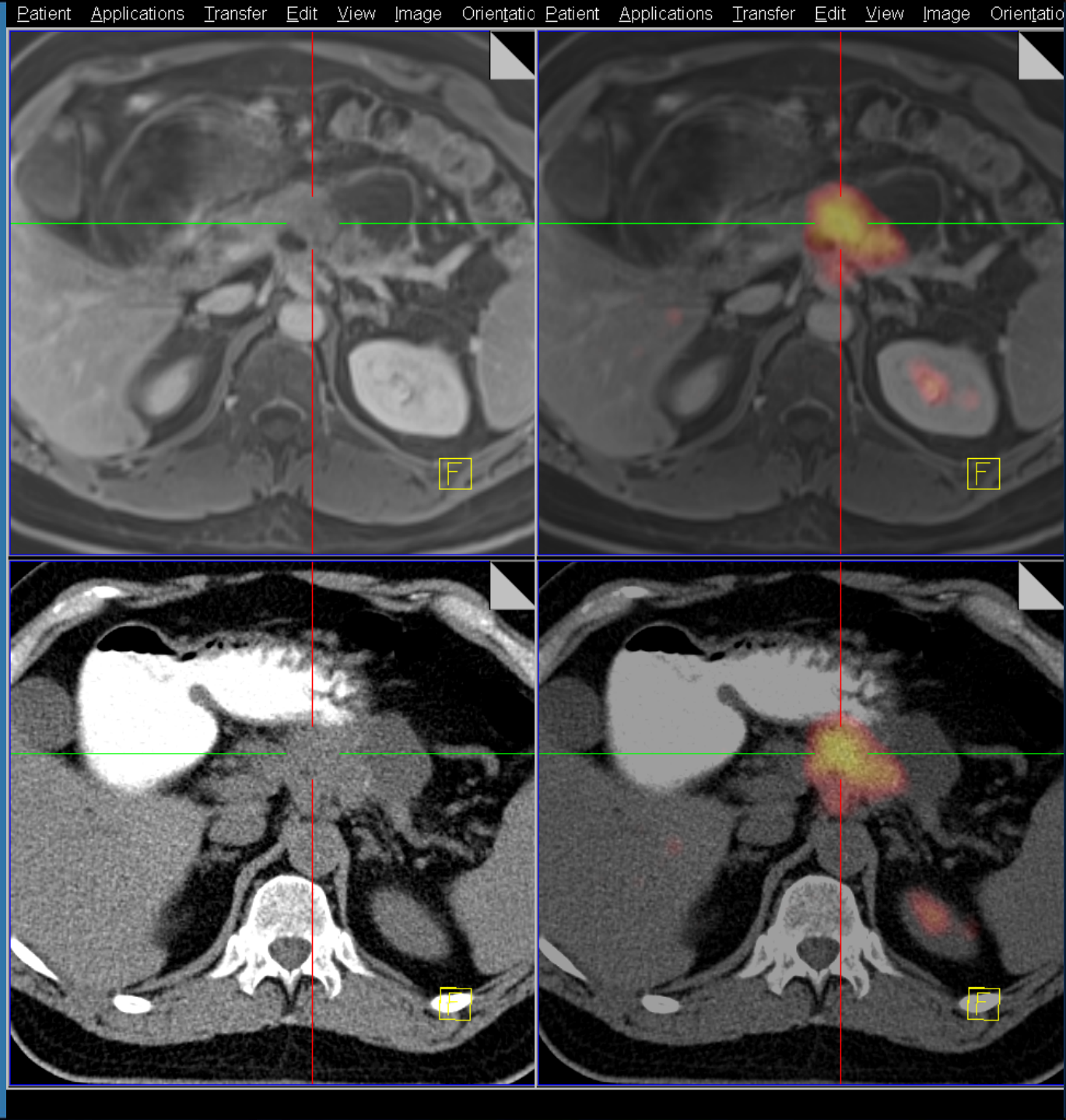
Patient Applications Transfer Edit View Image Orientatio
Patient Applications Transfer Edit View Image Orientatio
F
F
F
F

Patient Applications Transfer Edit View Image Orientation VRT Type Contours Tools Reports Options Help

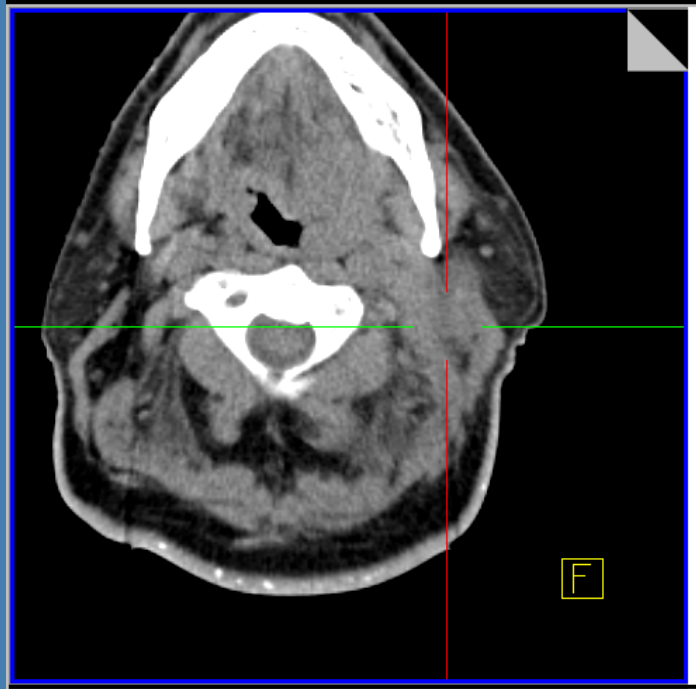

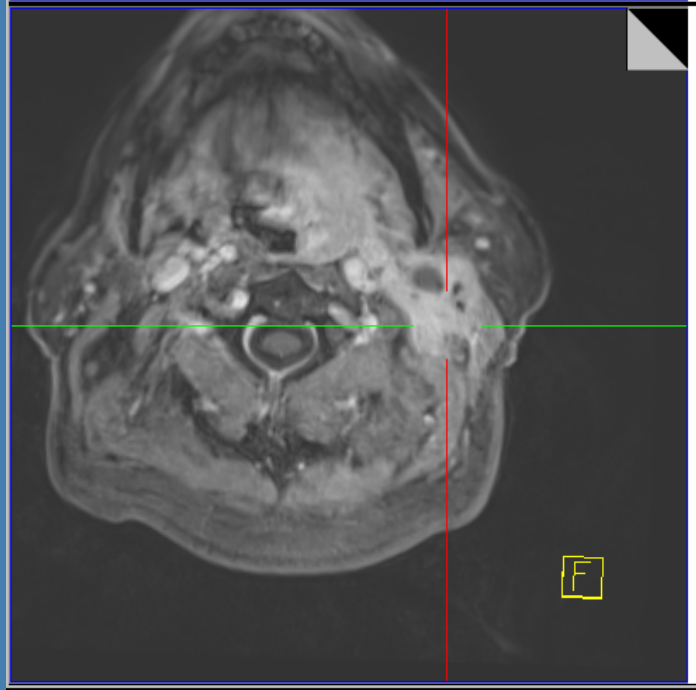

Patient Applications Transfer Edit View Image Orientation VRT Type Contours Tools Reports Options Help

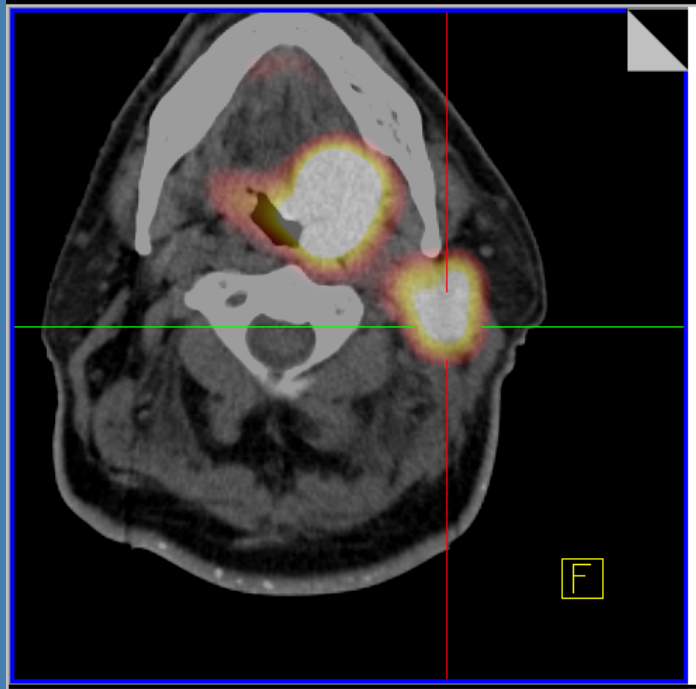

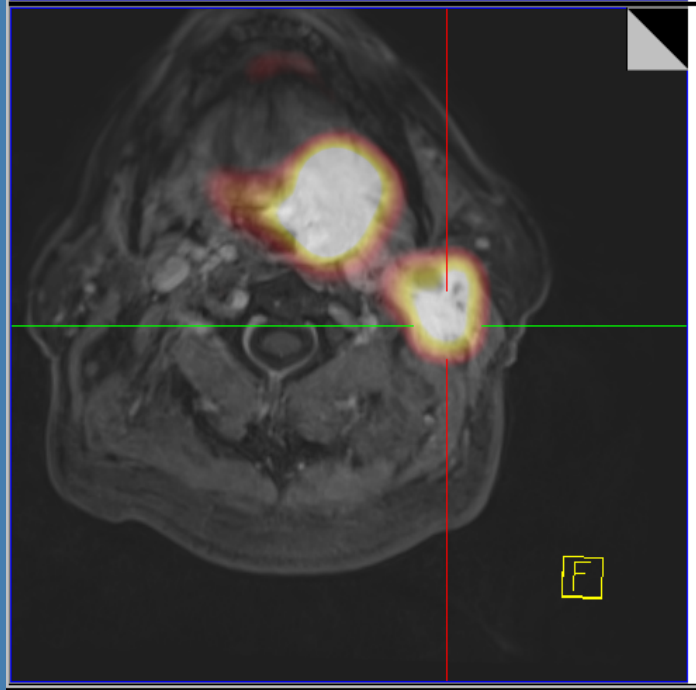

Patient Applications Options Help

Viewing

3D

TrueD

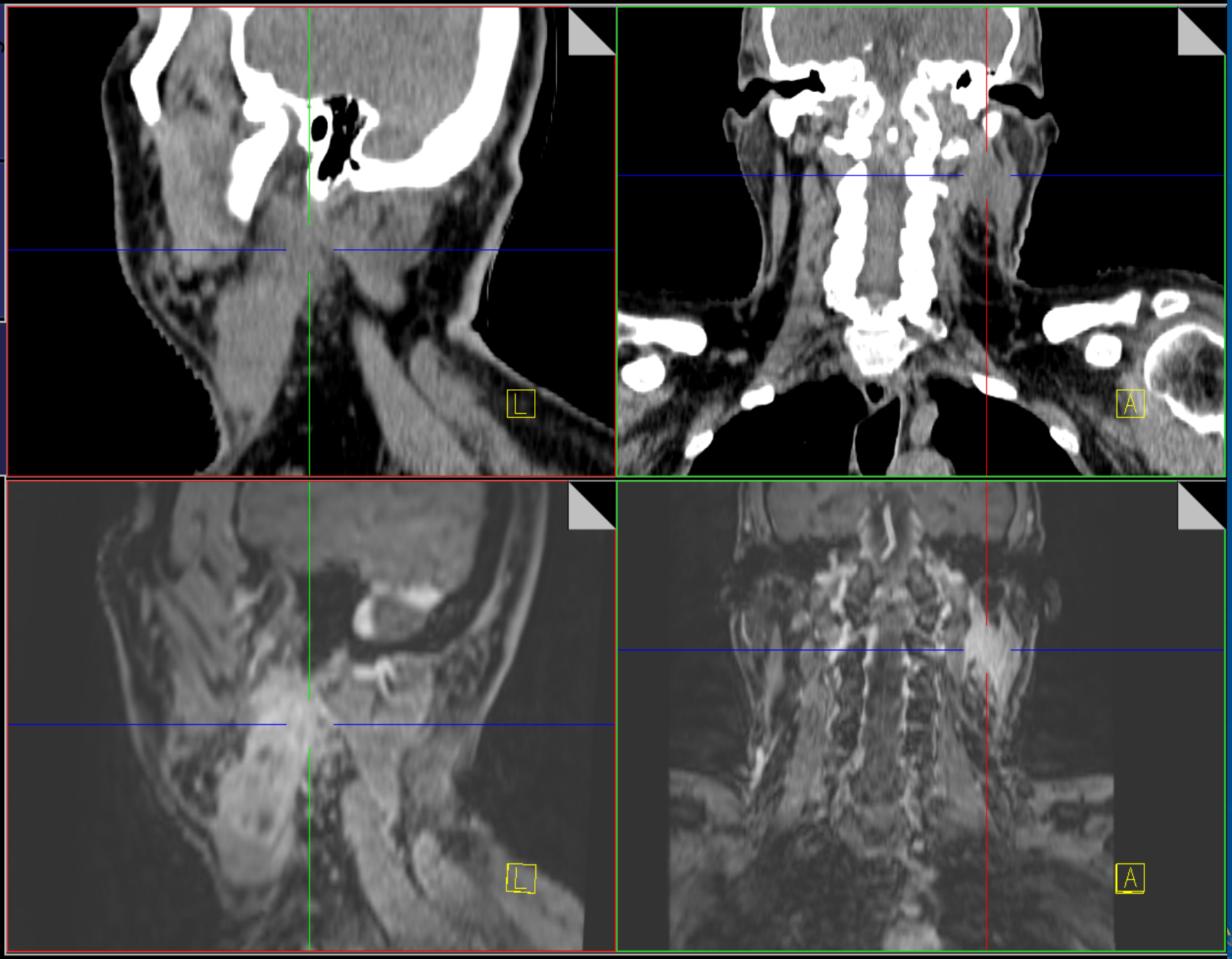

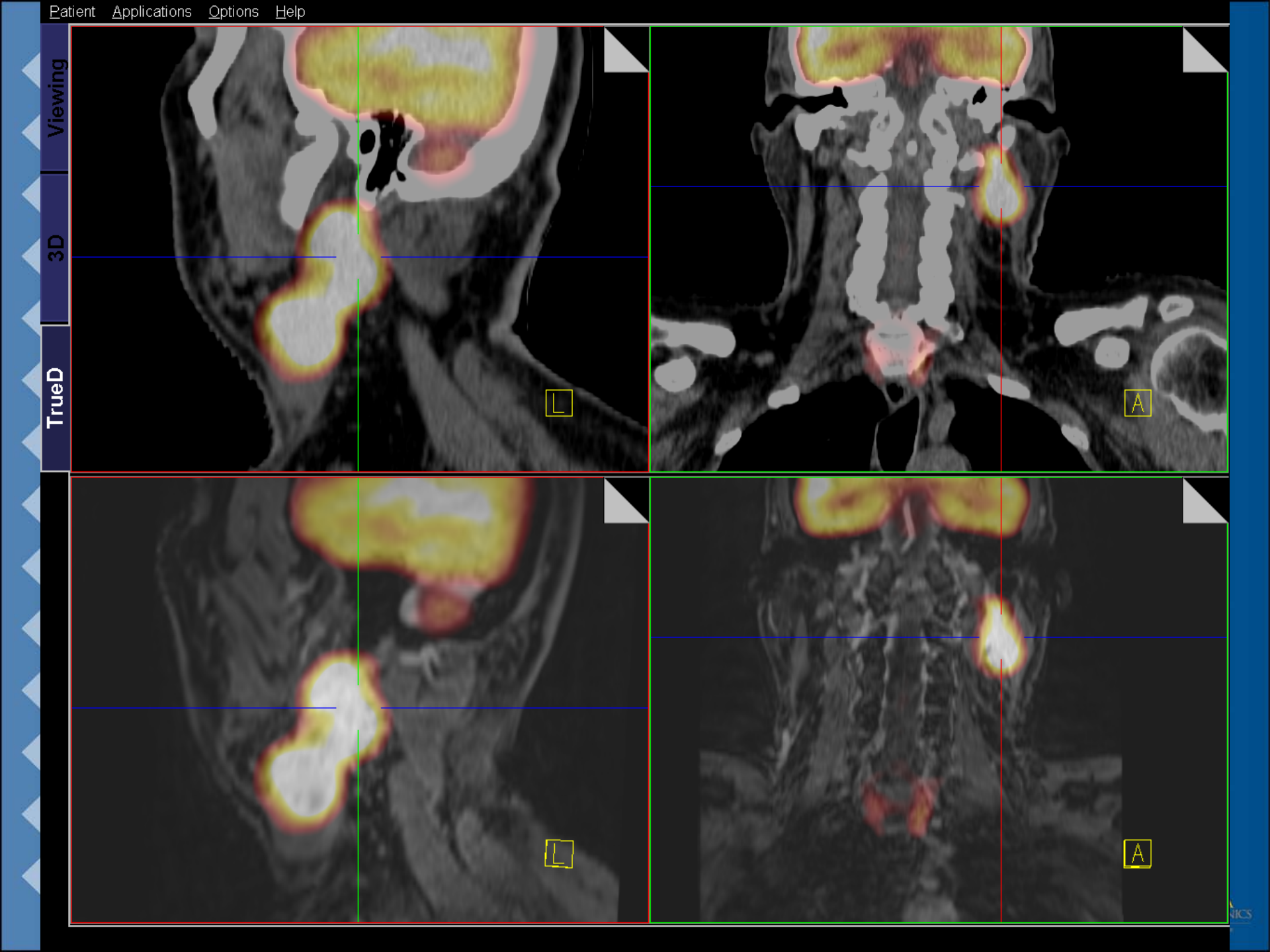
Patient
Applications
Options
Help
Viewing
3D
TrueD
L
A
L
A

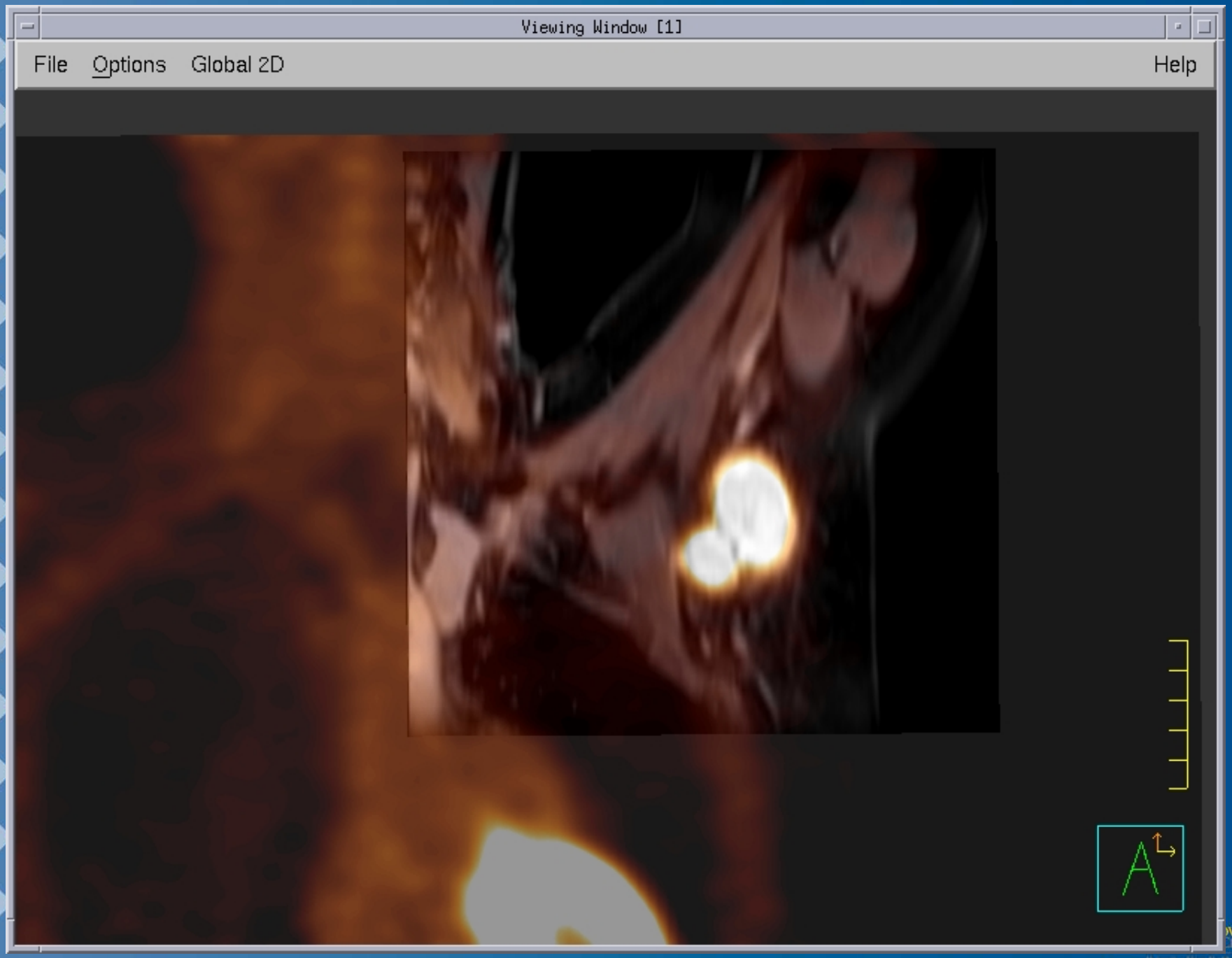
Viewing Window [1]
File
Options
Global 2D
Help

Conclusions

- MRI has widespread applications RT
- Geometric distortion – minimize & quantify
- MRI useful to quantify and validate motion management models
- MRSI shows promise – much work remains before routine clinical use

Acknowledgements

- Manickam Murugandanham, PhD
- RTT's/MR Techs
- RN's
- MD's

UNIVERSITY of IOWA HOSPITALS & CLINICS

University of Iowa Health Care

Siemens 3.0 Tesla Magnetom Trio MR in Radiation Therapy

- Convenient for patients and staff
- Our needs in RT are not necessarily the same as DI's needs
  - High contrast to noise
  - High spatial resolution (thin slices)
  - Full anatomy
  - Minimal spatial distortion
  - Functional imaging
  - Approximating treatment conditions
  - Length of scan time is not critical

So why 3.0 Tesla ?

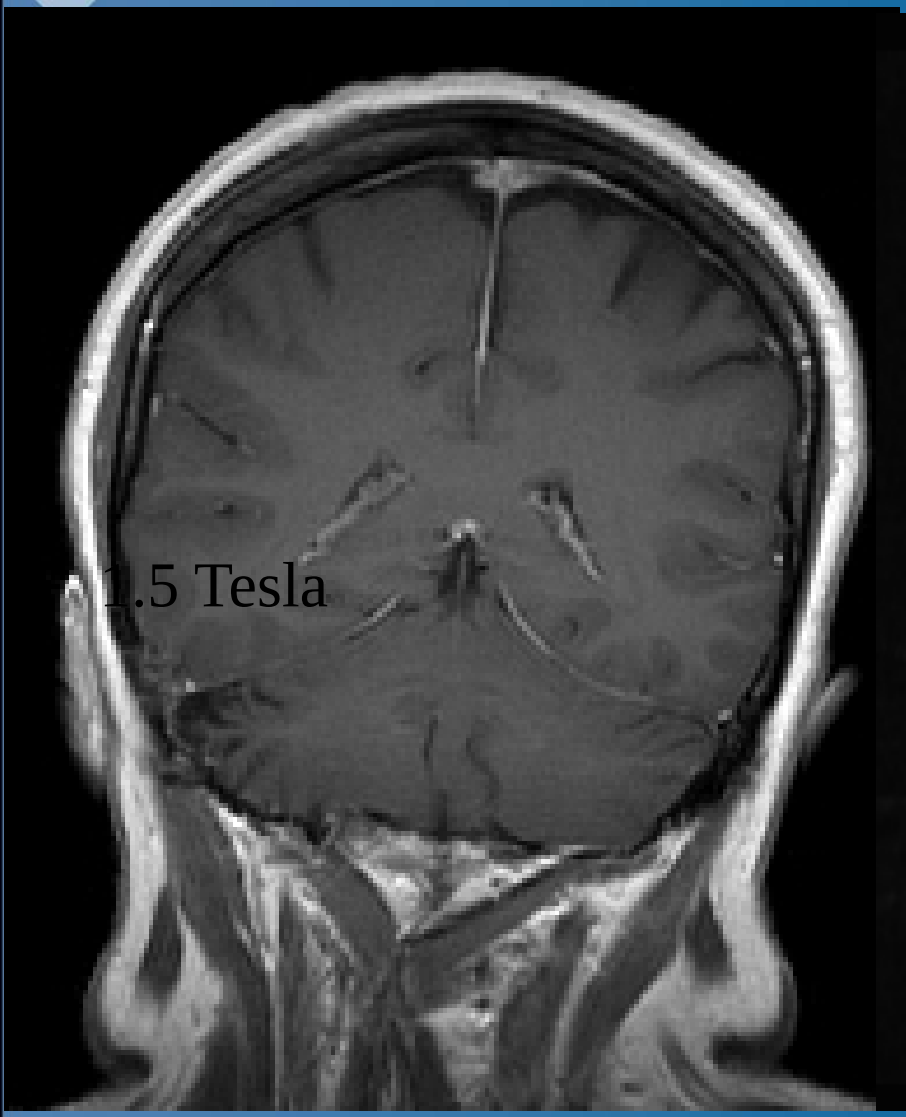

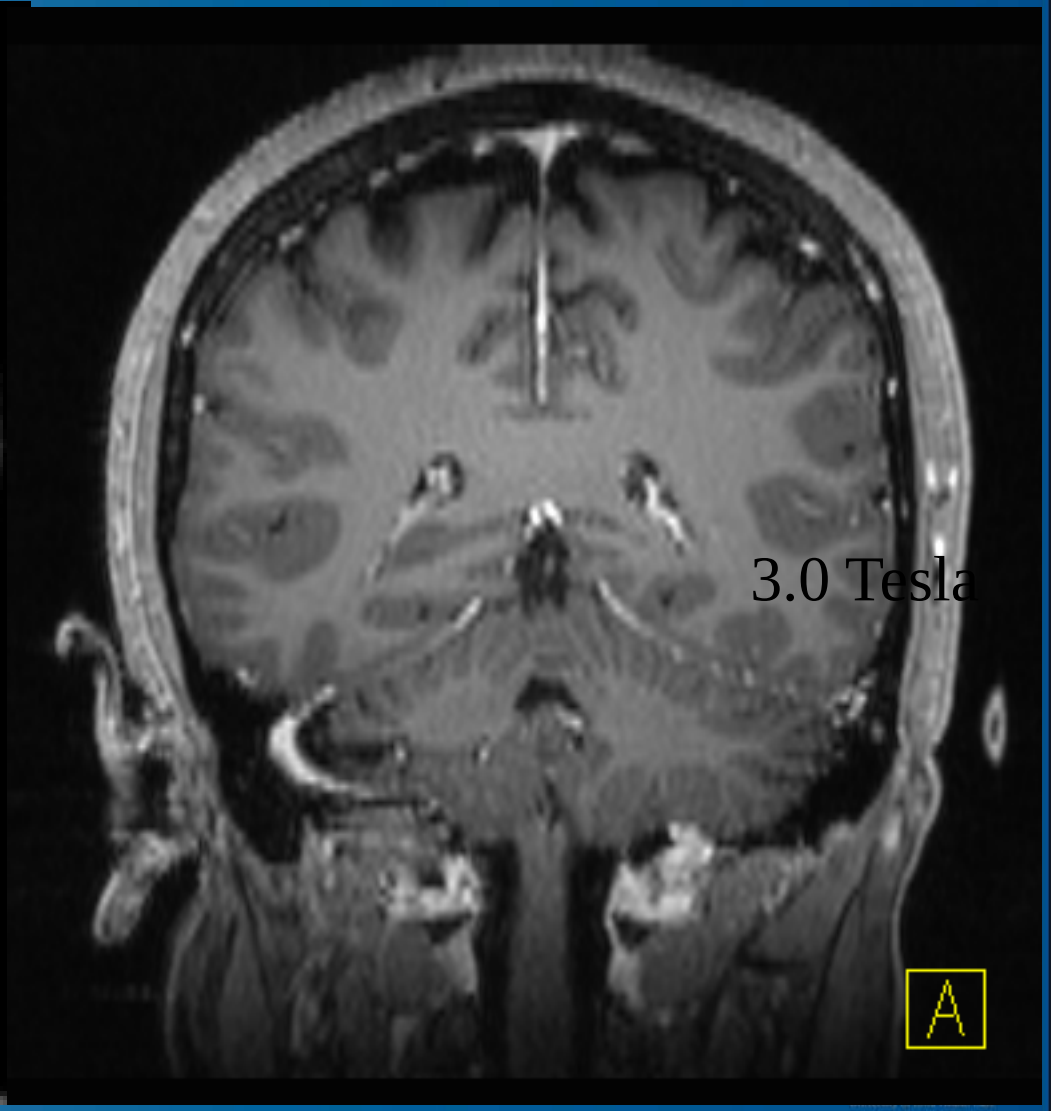

MRSI metabolite ratio (choline-to-NAA) superimposed on…

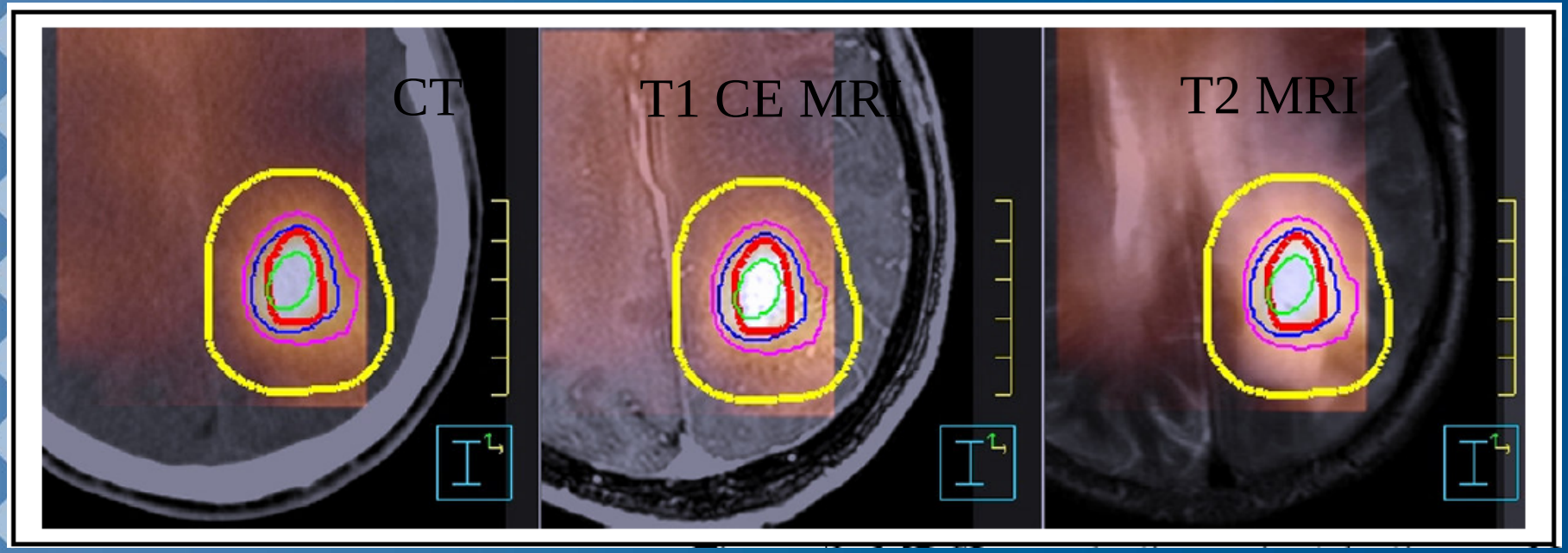

Contours shown represent:

- GTV-T1 (red)
- PTV-conventional (yellow)
- CNI4.0 (green)
- CNI3.0 (blue)
- CNI2.5 (purple)

Table 1. Region of Interest Changes

ROI	Volume (cc)
GTV - T1	3.37
GTV - CNI 4.0	1.35
GTV - CNI 3.0	7.57
GTV - CNI 2.5	14
PTV - conventional	71.9
PTV - MRSI	29.7