Image-Guided and Adaptive Radiation Therapy
Perspectives



Arno J. Mundt M.D.
Professor and Chair
Department of Radiation Oncology
UC San Diego
La Jolla, California

IGRT Today

- Myriad of in-room technologies focusing on improving setup and target localization
- Four major categories based on imaging approach
  - Video
  - Ultrasound
  - Planar
  - Volumetric

Image-Guided RT Technologies

Ultrasound
- BAT
- SonArray
- I-Beam
- Restitu

Video-Based
- Video Subtraction
- Photogrammetry
- AlignRT
- Real-Time Video-Guided IMRT

Planar X-Ray
- EPID
- CyberKnife
- Novalis
- RTRT
- Gantry-Mounted
  - Protoype
    - Tohoku, IRIS
  - Commercial
    - Varian OBI
    - Elekta Synergy

Volumetric
- In-Room CT
  - FOCAL,
  - CT-on-Rails
    - Primaton
    - Varian ExaCT
- Tomotherapy
- MV Cone Beam CT
- kV Cone Beam CT
- MR-Cobalt
- MR-Linac

Related Technologies
- RPM gating/4DCT
- Optical-guided Approaches
- Calypso

Not New

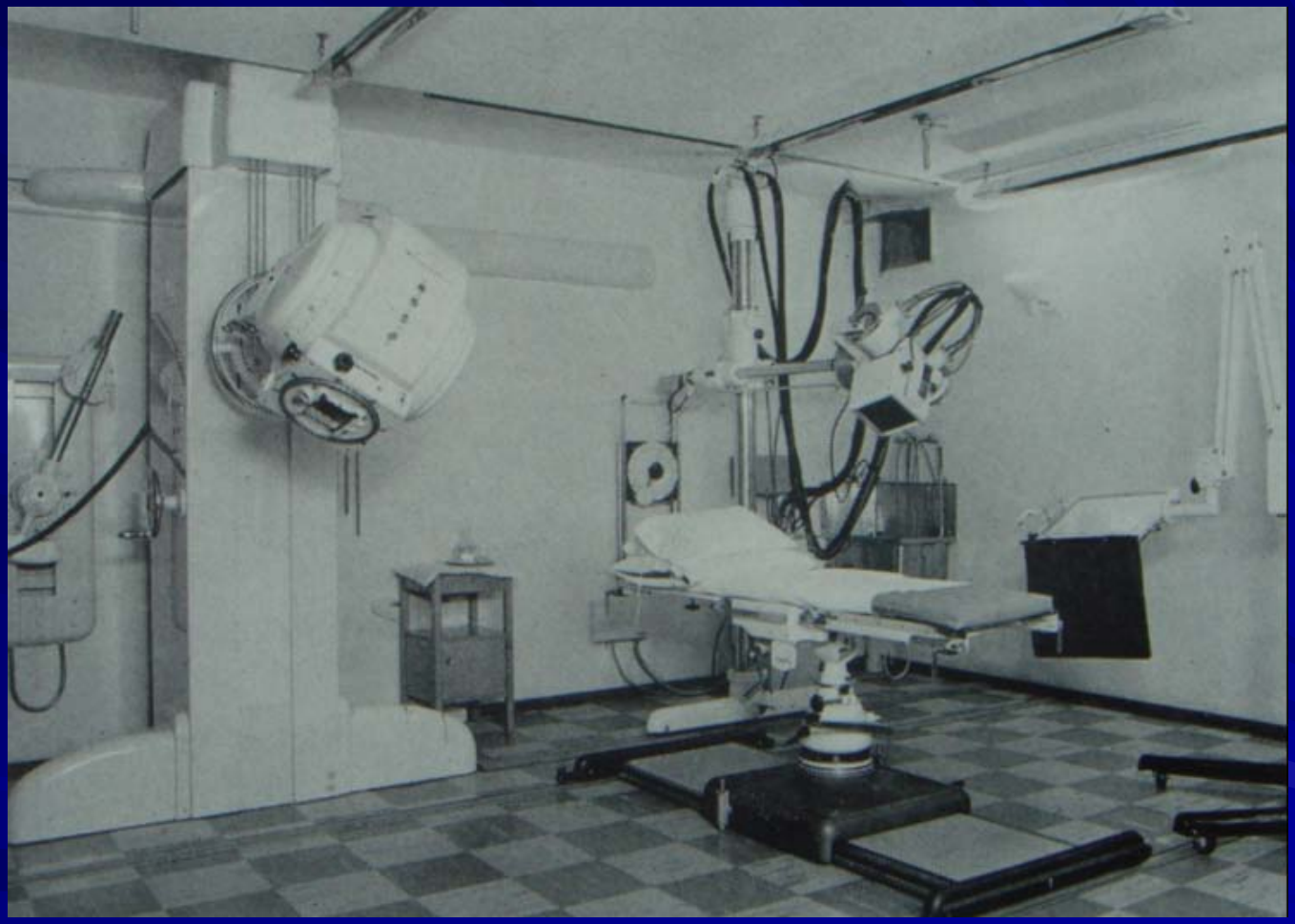

Cobalt-60 unit with in-room kV imaging
Karolinska University (1957)

Integrated Cobalt-kV imaging unit
Princess Margaret Hospital (1959)

Integrated Cobalt-kV imaging unit
NKI Amsterdam (1960)

Early IGRT Technologies

“Patient Repositioning and Motion Detection Using a Video Cancellation System”

Connor WG, Boone ML, Veomett R,
Hicks J, Miller RC, Mayer E, Sheeley N.

International Journal Radiation Oncology
Biology Physics
1:147:1975

Other Modalities

- Subsequently both ultrasound and planar imaging techniques (EPID)
- More recently volumetric approaches

In-Room IGRT Modalities Today
Makes one go absolutely crazy….

Original Article

A Survey of Image-Guided Radiation Therapy Use in the United States

Daniel R. Simpson, BS; Joshua D. Lawson, MD; Sameer K. Nath, BA; Brent S. Rose, BS; Arno J. Mundt, MD; and Loren K. Mell, MD



In Press

- 1600 radiation oncologists surveyed
- Great majority (94%) use some form of in-room IGRT in their patients
- Majority use it only infrequently or rarely
- Predominantly prostate, head/neck, CNS and lung

Simpson et al. Cancer 2010;116;3953

IGRT Survey

Table 3. Proportions of Radiation Oncologists Using In-Room Image-Guided Radiation Therapy to Treat Various Disease Sites

Disease Site	No. of Users (% of All Users)
Genitourinary	328 (91.1)
Head and neck	267 (74.2)
Central nervous system	259 (71.9)
Lung	241 (66.9)
Gastrointestinal	216 (60)
Gynecologic	209 (58.1)
Palliative	164 (45.5)
Breast	160 (44.4)
Lymphoma	144 (40)
Pediatrics	86 (23.9)

Simpson et al. Cancer 2010;116;3953

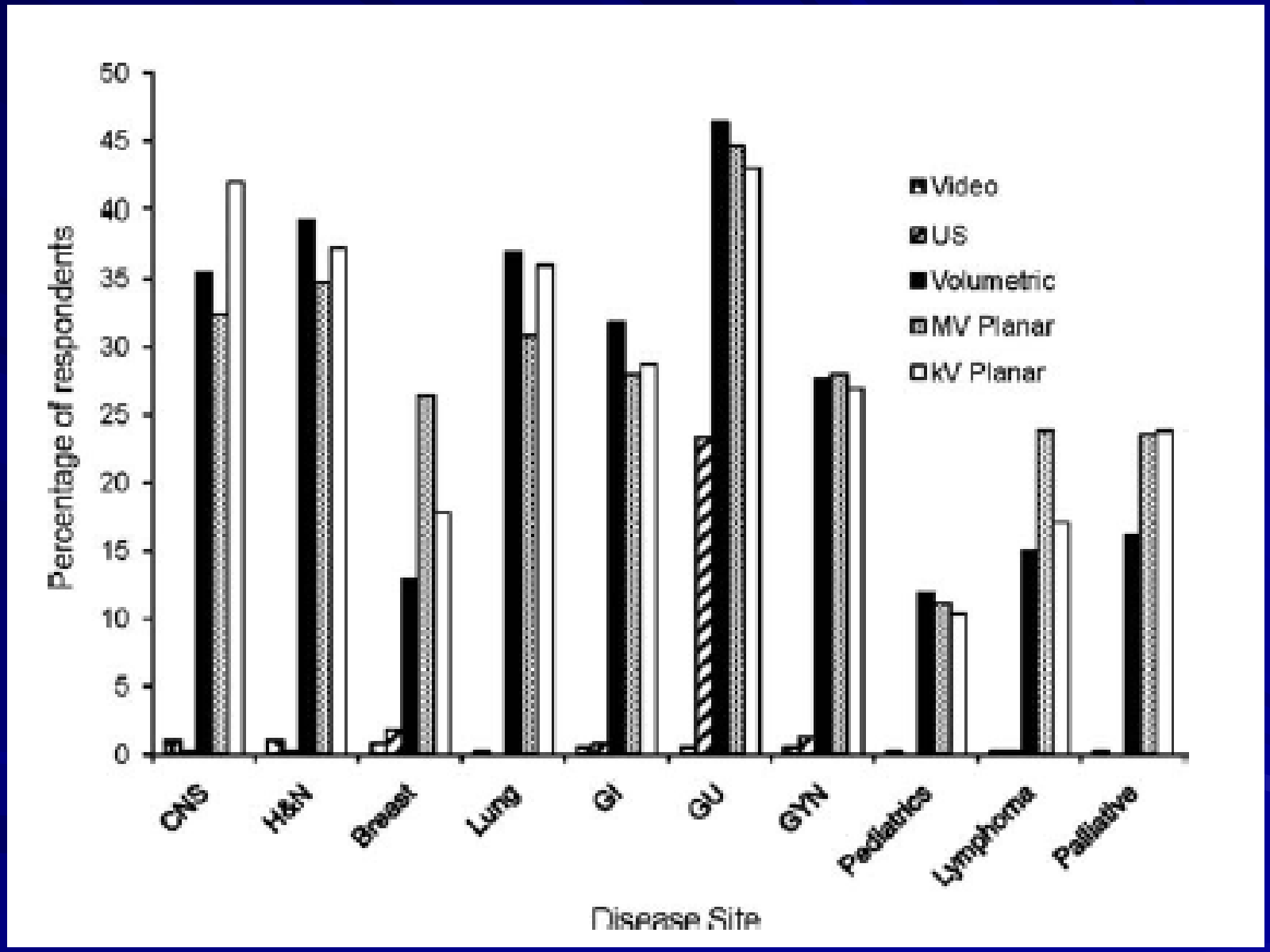

Simpson et al. Cancer 2010;116;3953

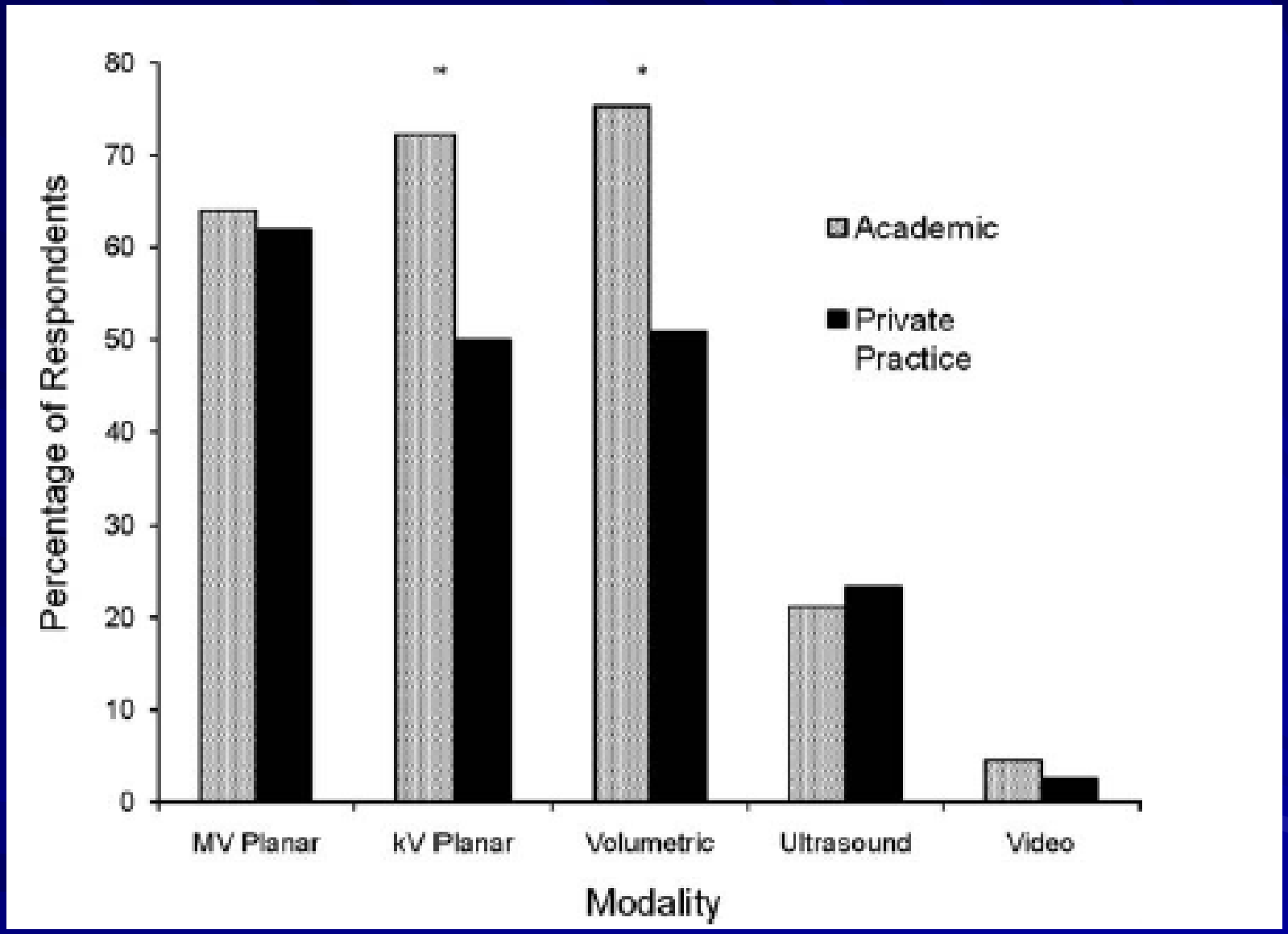

Simpson et al. Cancer 2010;116;3953

Cumulative Adoption

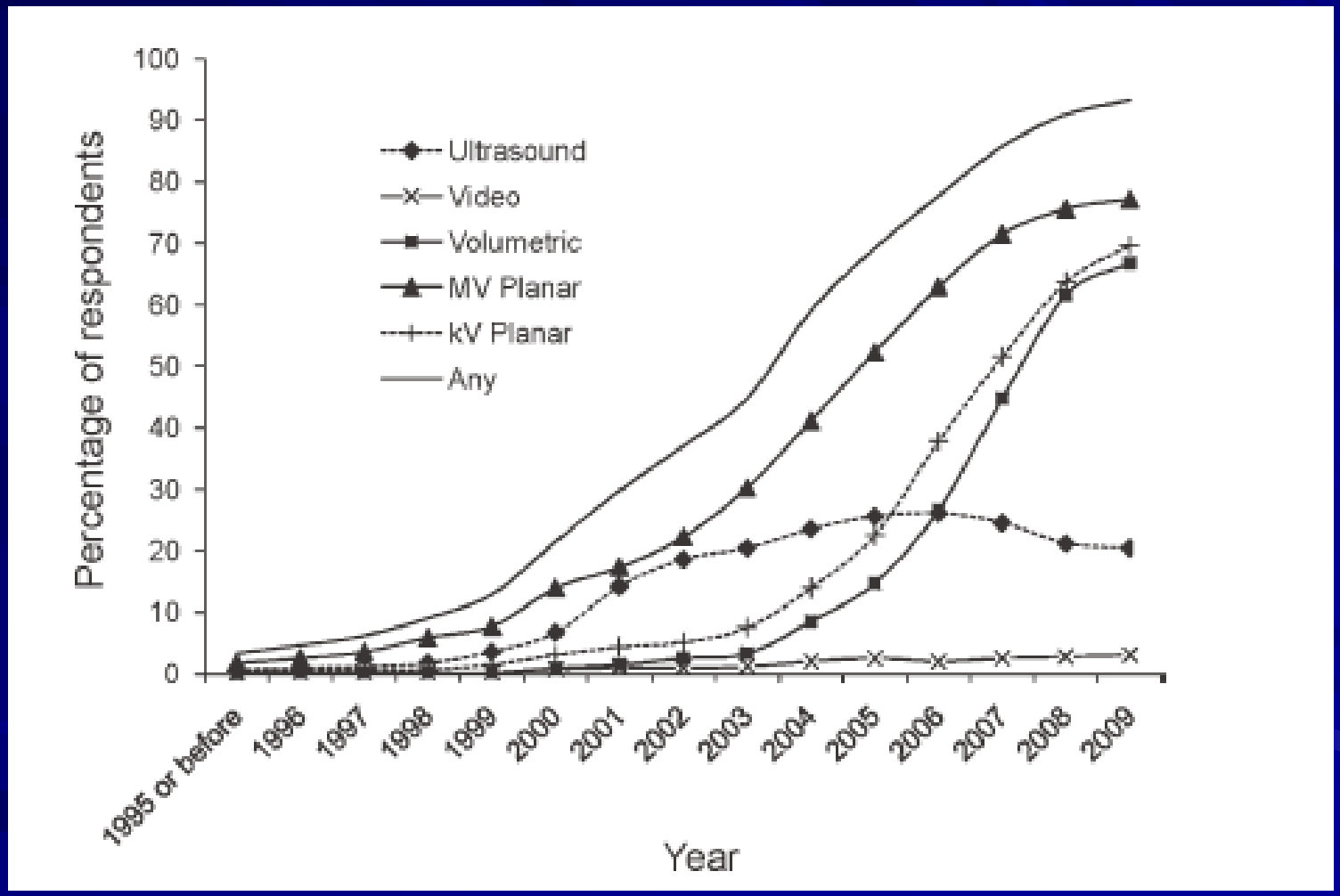

Simpson et al. Cancer 2010;116;3953

IGRT

- Concept of IGRT is actually much broader
- Use of modern imaging modalities, especially those incorporating functional or biological information, to augment target delineation

IGRT

- Variety of sophisticated imaging approaches have used to augment target delineation
- Most attention focused on Positron Emission Tomography (PET)
- Also Magnetic Resonance Imaging (MRI), functional MRI (fMRI), MR Spectroscopy (MRS), and Single Photon Emission Computed Tomography (SPECT)

Image-Guided Treatment Planning

Leong et al. Radiother Oncol 2006;78:254



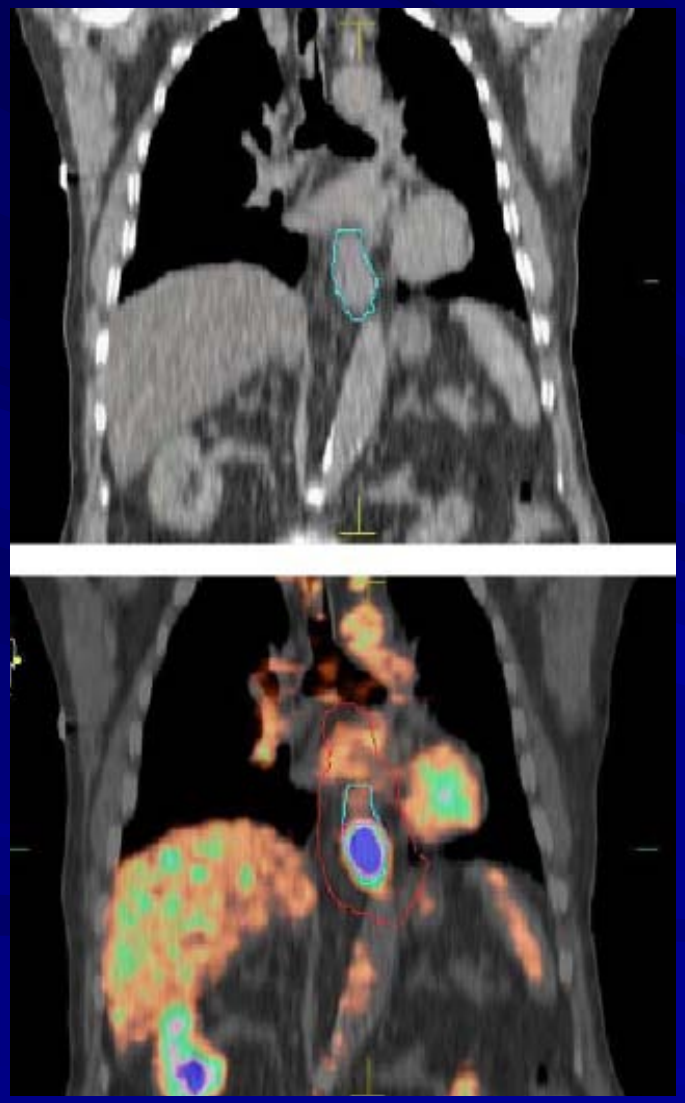

- Increasing interest in using PET and MRI techniques to improve how RT is planned
- Improves our ability to accurately target the tumor

Van Lin et al. Int J Radiat Oncol Biol Phys 2006;65:291

5 Prostate Cancer Pts

MR Spectroscopy (MRS) [^{1}H-Spectroscopy]

Feasibility of identifying intraprostatic lesions

Safely dose escalate to 90 Gy

MR Spectroscopy

CT Simulation

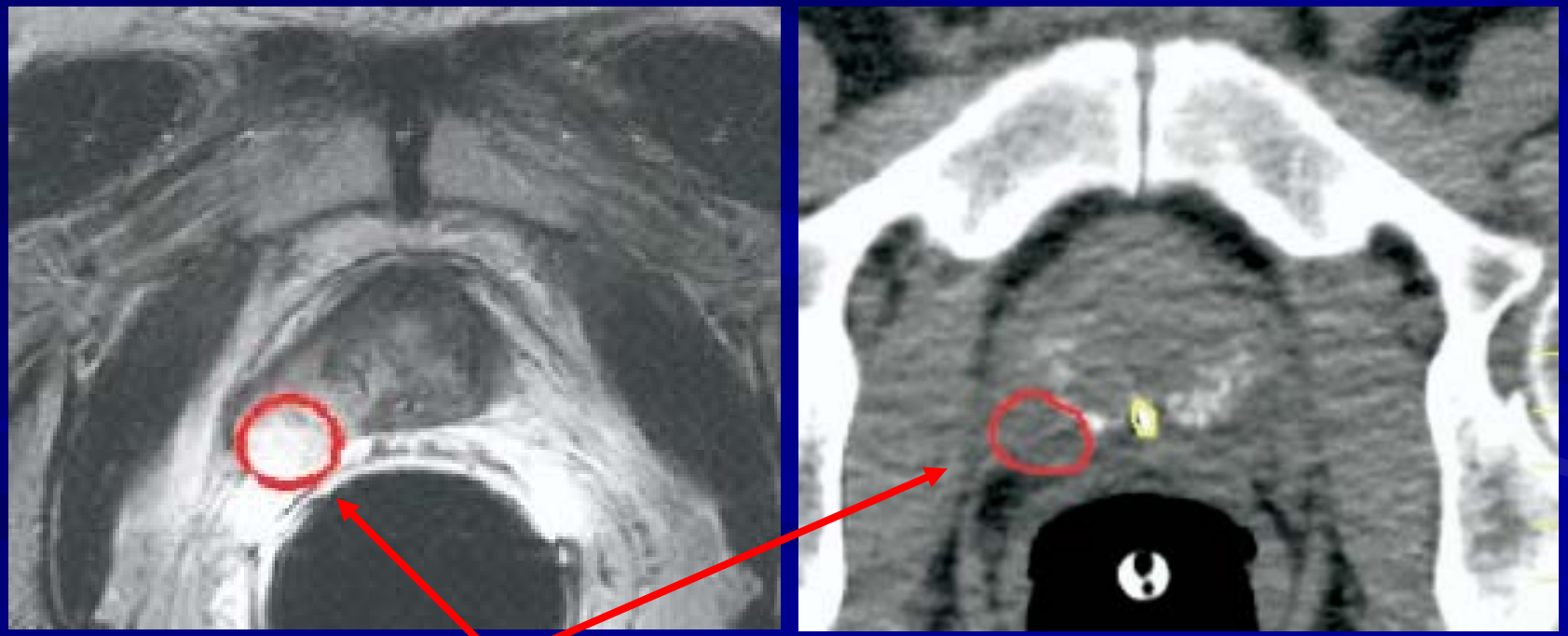

Intraprostatic lesion

Ellis et al. Brachytherapy 2003;2:215

80 low-intermediate risk prostate cancer pts

Prostascint-guided brachytherapy

Regions of ↑uptake escalated to 150%

144 Gy (^{125}I) and 115 Gy (^{103}Pd)

4-year biochemical FFS 97.4%

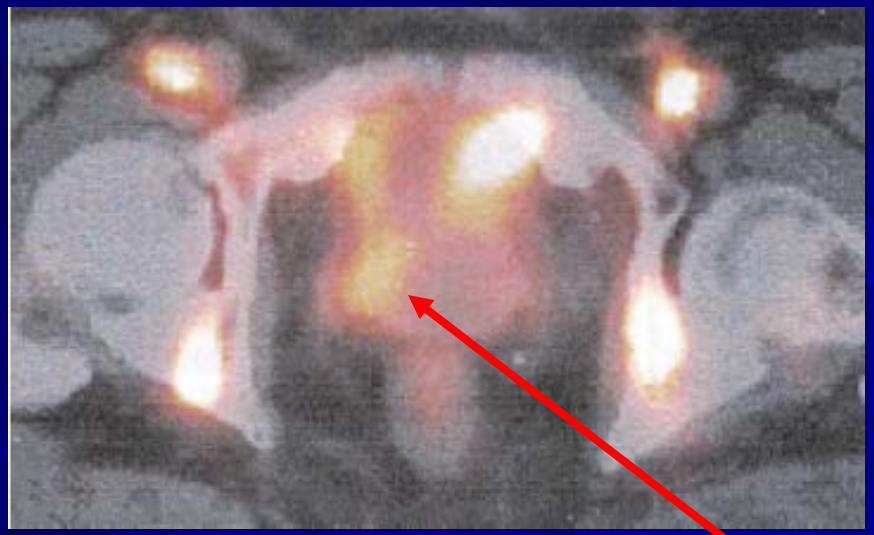

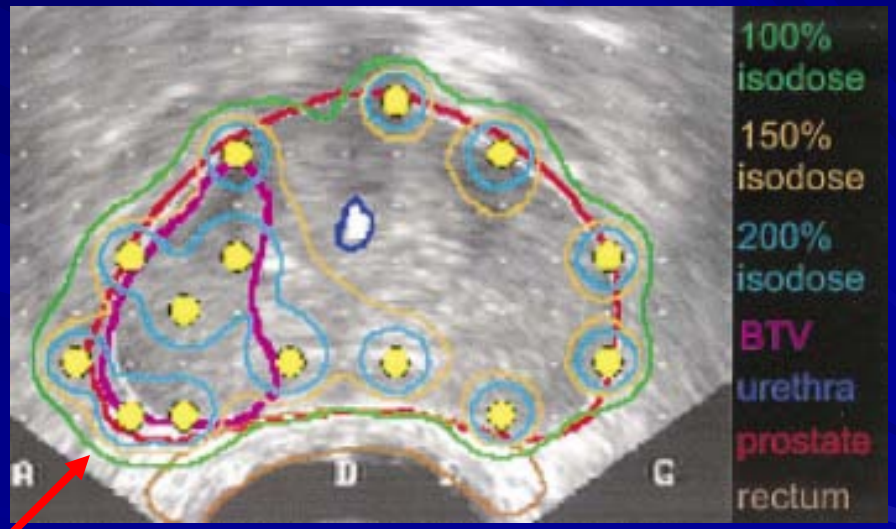

Increased Uptake

T2* Pulse Echo MRI
"Fat Fraction"

Used to differentiate between red and yellow marrow

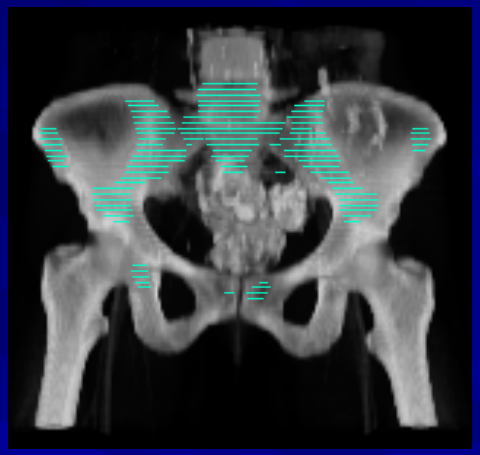

Loren Mell MD
ASCO Young Investigator Award

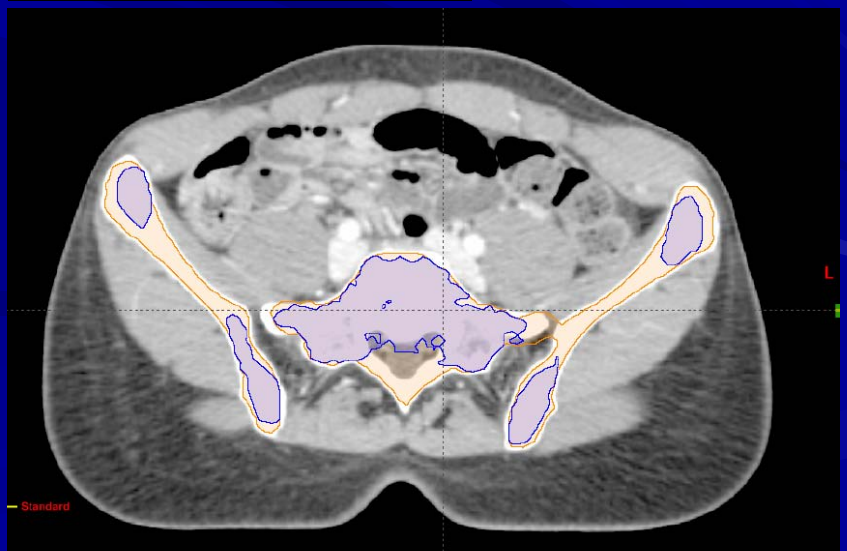

Utilization of Advanced Imaging Technologies for Target Delineation in Radiation Oncology

Daniel R. Simpson, BS, Joshua D. Lawson, MD, Sameer K. Nath, BA, Brent S. Rose, BS, Arno J. Mundt, MD, Loren K. Mell, MD

JACR
Journal of the American College of Radiology
J Am Coll Radiol
2009;6:876

- 1600 radiation oncologists surveyed
- Great majority (95%) have used advanced imaging to augment targeting of tumor
- Majority use it only infrequently or rarely
- Predominantly PET (76%) and MRI (72%)
- Predominantly lung, brain and head/neck tumors

Simpson et al. JACR 2009;6:876

IGRT Survey

Table 3. Prevalence of image-guided target delineation use by disease site

Disease Site	Number of Users (% of All Users)
Central nervous system	286 (79.0)
Head and neck	289 (79.8)
Breast	72 (19.9)
Lung	302 (83.4)
Gastrointestinal	193 (53.3)
Genitourinary	159 (43.9)
Gynecologic	166 (45.9)
Pediatrics	52 (14.4)
Lymphoma	203 (56.1)
Palliative	94 (26.0)

Simpson et al. JACR 2009;6:876

IGRT Survey

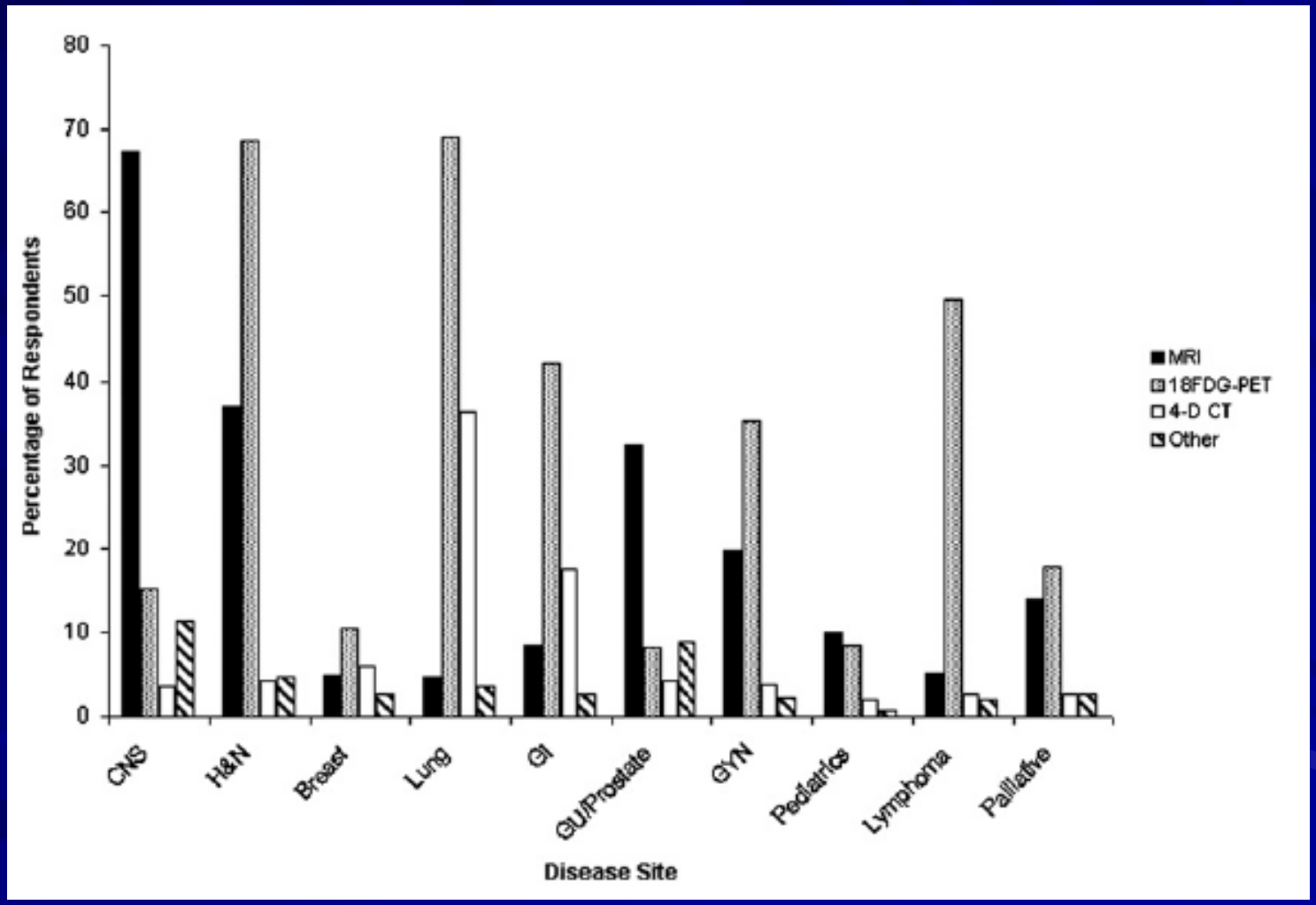

Simpson et al. JACR 2009;6:876

IGRT Survey

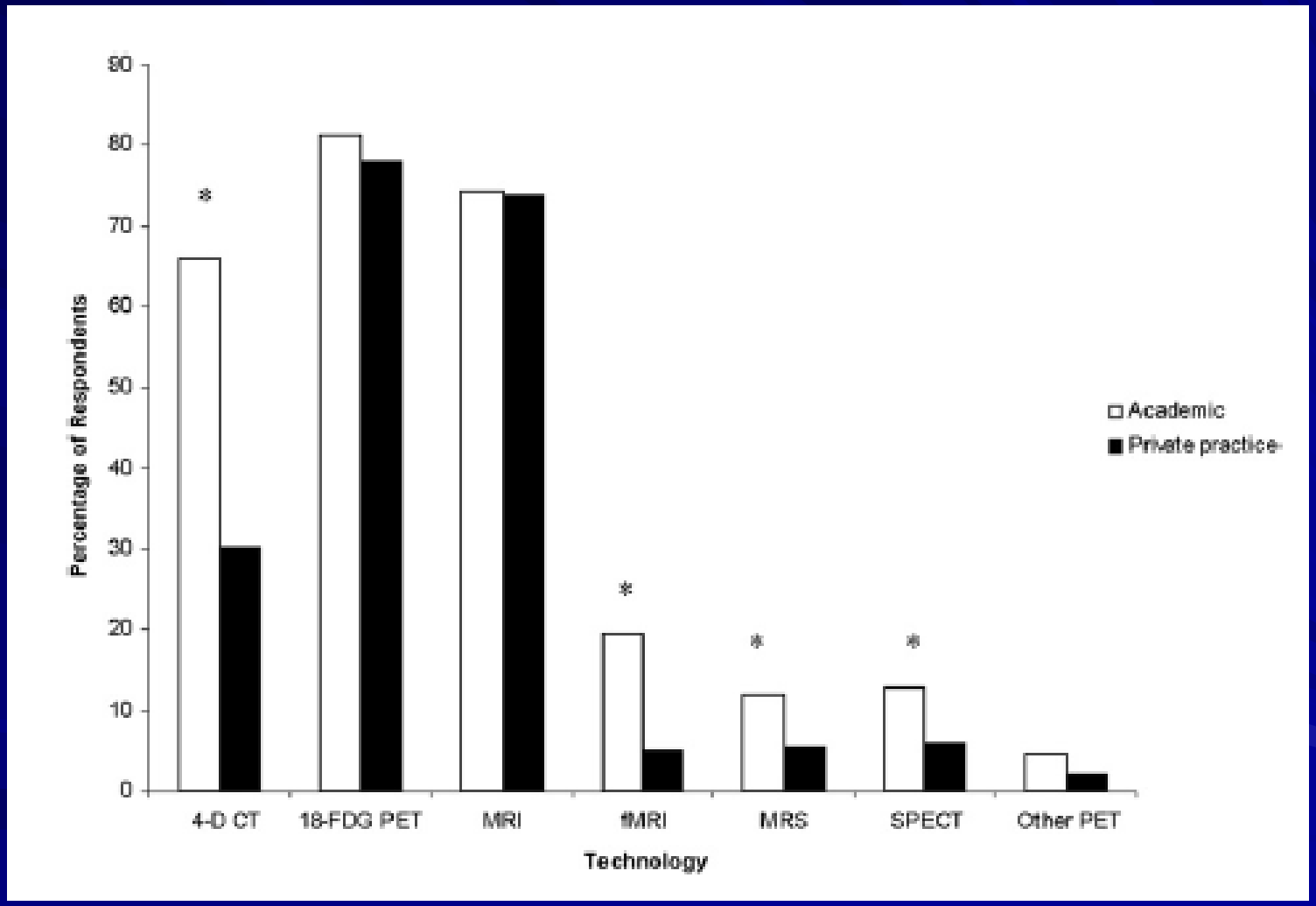

Simpson et al. JACR 2009;6:876

IGRT Survey

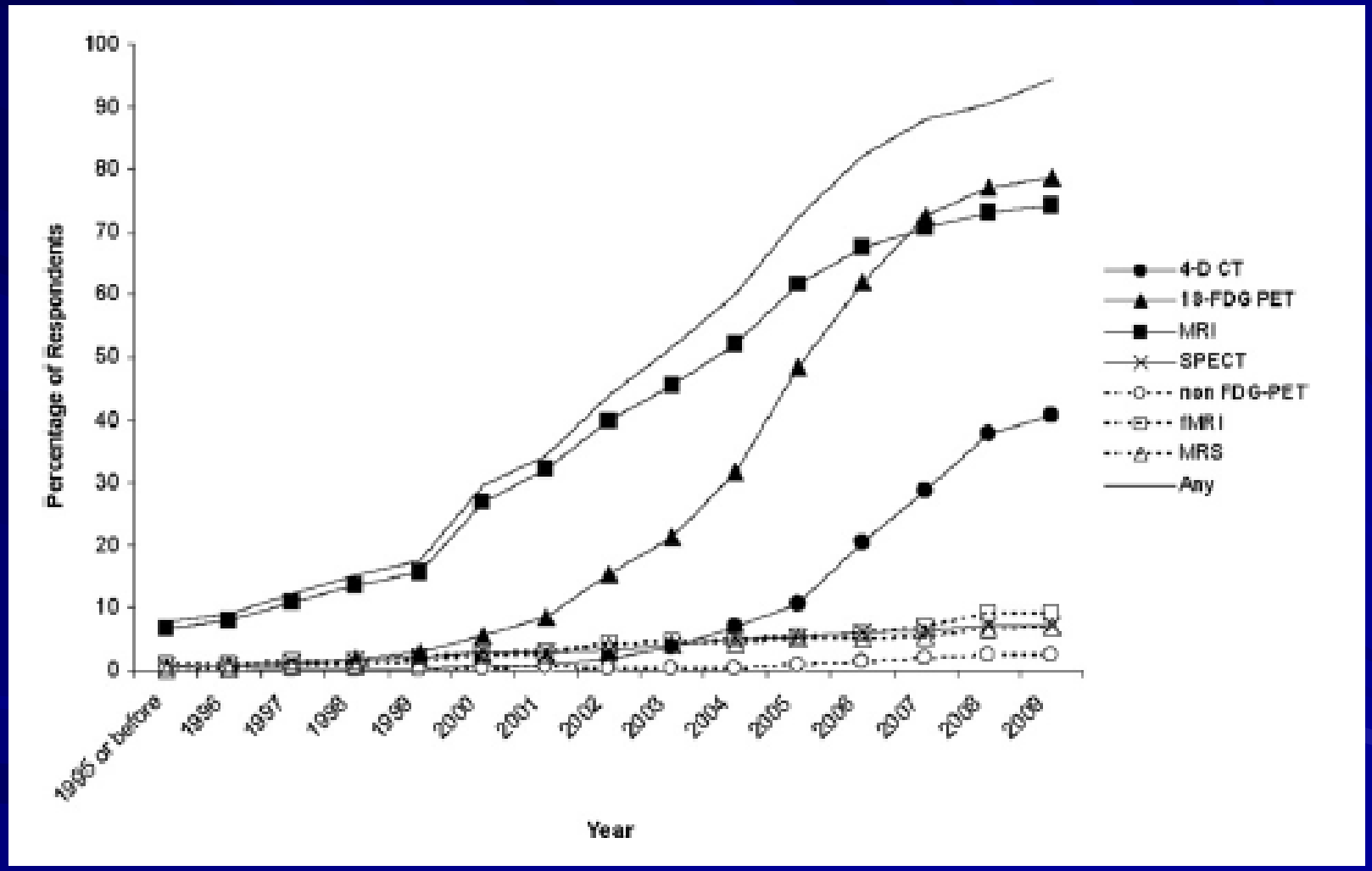

Simpson et al. JACR 2009;6:876

IGRT of Tomorrow

- Will broader even further to include image guided adaptation
- Adapt to changes in the tumor (and patient) detected by imaging during the treatment
- Transform the RT process from a static to a dynamic process

Adapt to What Changes?

- Morphologic
  - Changes in size and/or shape of tumors and normal tissues
- Functional
  - Changes in physiology and biology

Adaptive IGRT

- Morphologic changes are particularly interesting
- Significant impact on the treatment plan

  ↑tumor size → ↓target coverage → ↓LC

  ↓tumor size → ↑normal tissue dose → ↑toxicity

  Δshape → ↓target coverage and ↑normal tissue dose → ↑toxicity and ↓LC
- Adapting to changes may allow us to alter our dose up and/or down

Morphologic Changes

- And such changes are potentially detected with novel in-room imaging (MVCT, CBCT, etc)
- Opens the door for potentially adapting to them on-line

Adaptive IGRT

- Different rationale exists for functional changes
- Functional imaging may identify changes supporting the use of higher doses
- Changes may also be identified which allow dose de-escalation reducing the risk of toxicities
- Functional changes in normal tissues may signal the need to adapt treatment plan avoiding potential toxicities

Adaptive IGRT

- Discussions of adaptive IGRT quickly turn to the technical issues involved
- Purpose here is to review some of the morphologic changes that occur and which may form a basis for adaptive IGRT

Conventional Wisdom

Morphologic changes are not common and occur only in a few tumor sites

Reality

Morphologic changes are common and occur in the great majority of tumor sites

Morphologic Changes

Central Nervous System Tumors

- Most brain tumors have long been thought to change little at all during treatment
- Recent evidence with serial MRI during RT has questioned this belief

EVALUATING CHANGES IN TUMOR VOLUME USING MAGNETIC RESONANCE IMAGING DURING THE COURSE OF RADIOTHERAPY TREATMENT OF HIGH-GRADE GLIOMAS: IMPLICATIONS FOR CONFORMAL DOSE-ESCALATION STUDIES

CHRISTINA TSIEN, M.D.,* DIANA GOMEZ-HASSAN, M.D.,† RANDALL K. TEN HAKEN, PH.D.,* DANIEL TATRO, C.M.D.,* L. JUNCK, M.D., PH.D.,‡ T. L. CHENEVERT, PH.D.,† AND T. LAWRENCE, M.D., PH.D.*

Departments of *Radiation Oncology, †Neuro-Radiology, and ‡Neurology, University of Michigan, Ann Arbor, MI

- 19 high grade gliomas treated with 3DCRT
- T1- and T2-weighted and FLAIR imaging
- Imaged prior to RT, weeks 1 and 3 and post-RT
- Changes at week 3:
  - 2 pts >50% decrease in GTV
  - 12 pts slight rim enhancement or cystic changes
  - 3 pts increased GTV
- Median increase in GTV: 11.7 cc (9.8-21.3 cc)
- Decrease V-95% of the PTV
- No analysis of dosimetric consequences

Tsien et al. Int J Radiat Oncol Biol Phys 2005;62:328

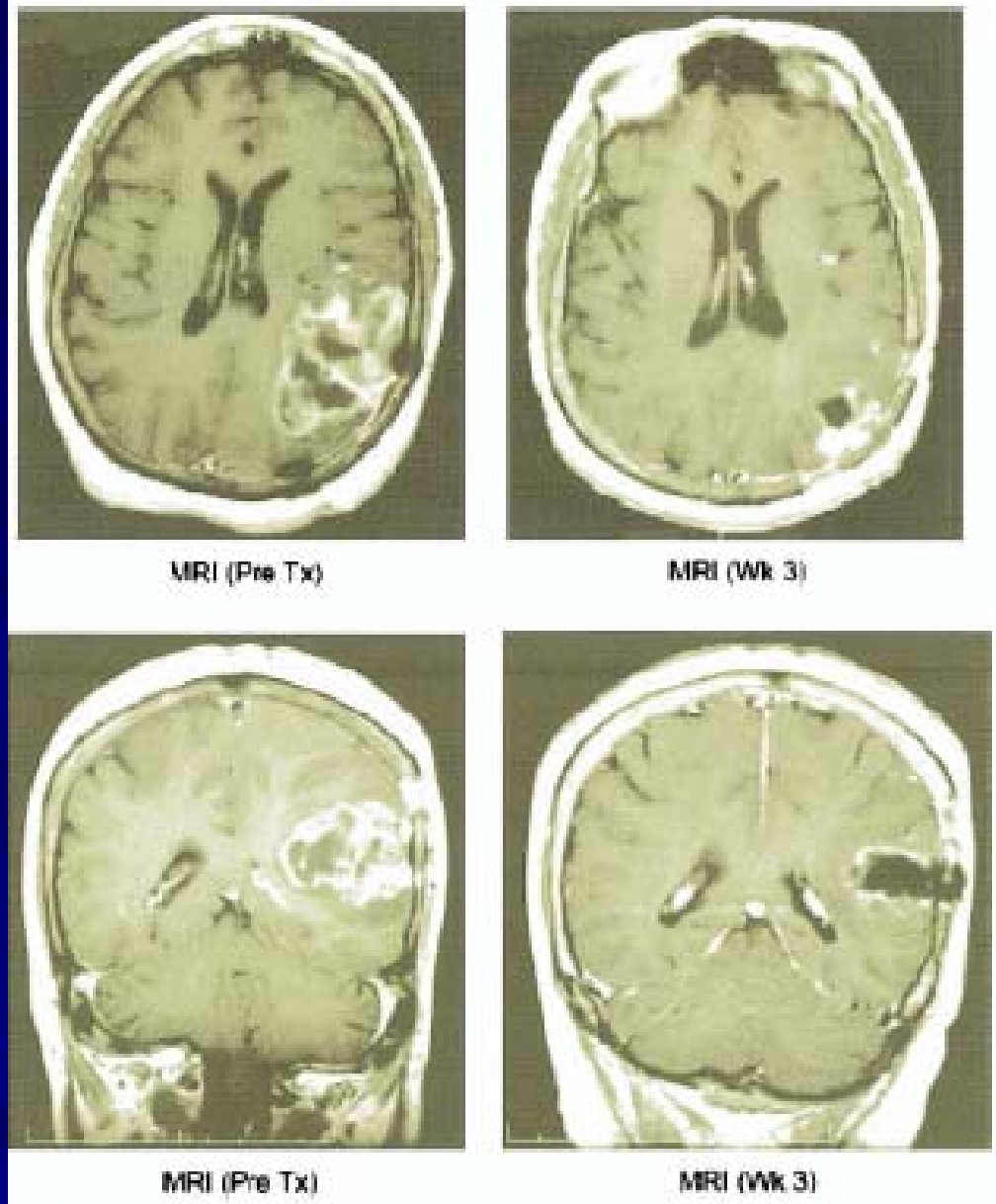

Fig. 1. Grade 3 anaplastic oligoastrocytoma with tumor response Week 3 MRI during radiotherapy.

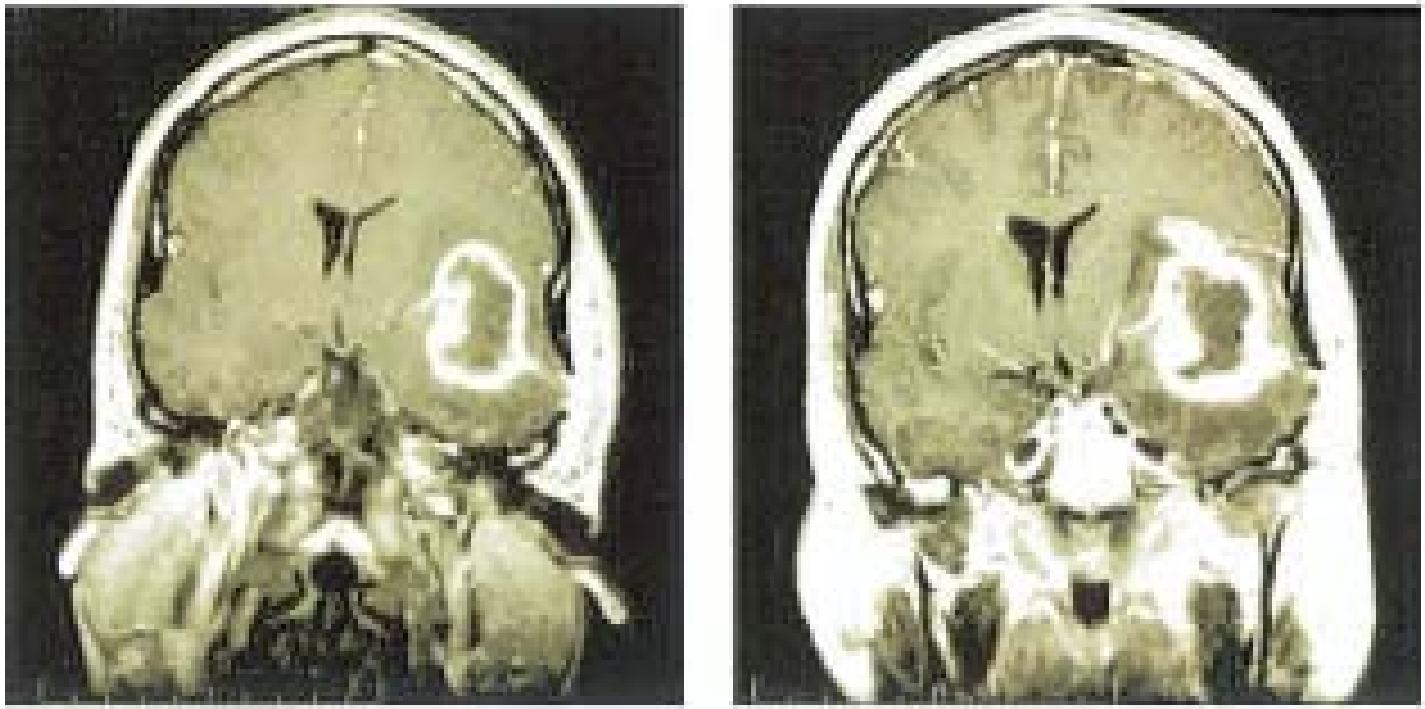

Fig. 4. Grade 4 glioblastoma multiforme with tumor progression at Week 1 MRI (Pre-Tx MRI was performed 1 week before initiation of RT).

Head and Neck Cancers

- Morphologic changes well known in these tumors
- Long been commonplace to re-simulate patients with significant changes including weight loss
- Increased available of in-room images increased our awareness of these changes and their impact on treatment

QUANTIFICATION OF VOLUMETRIC AND GEOMETRIC CHANGES OCCURRING DURING FRACTIONATED RADIOTHERAPY FOR HEAD-AND-NECK CANCER USING AN INTEGRATED CT/LINEAR ACCELERATOR SYSTEM

Jerry L. Barker, Jr., M.D.,* Adam S. Garden, M.D.,* K. Kian Ang, M.D., Ph.D.,* Jennifer C. O'Daniel, M.S.,† He Wang, Ph.D.,† Laurence E. Court, Ph.D.,† William H. Morrison, M.D.,* David I. Rosenthal, M.D.,* K. S. Clifford Chao, M.D.,* Susan L. Tucker, Ph.D.,‡ Radhe Mohan, Ph.D.,† and Lei Dong, Ph.D.†

Departments of *Radiation Oncology, †Radiation Physics, and ‡Biomathematics, The University of Texas M. D. Anderson Cancer Center, Houston, TX

- 14 locally advanced pts imaged using CT-on-rails
- 3 scans per week
- Overall 69.5% shrinkage in GTV
- Average GTV reduction = 0.2 cc/day
- Median percentage shrinkage = 1.8%/day

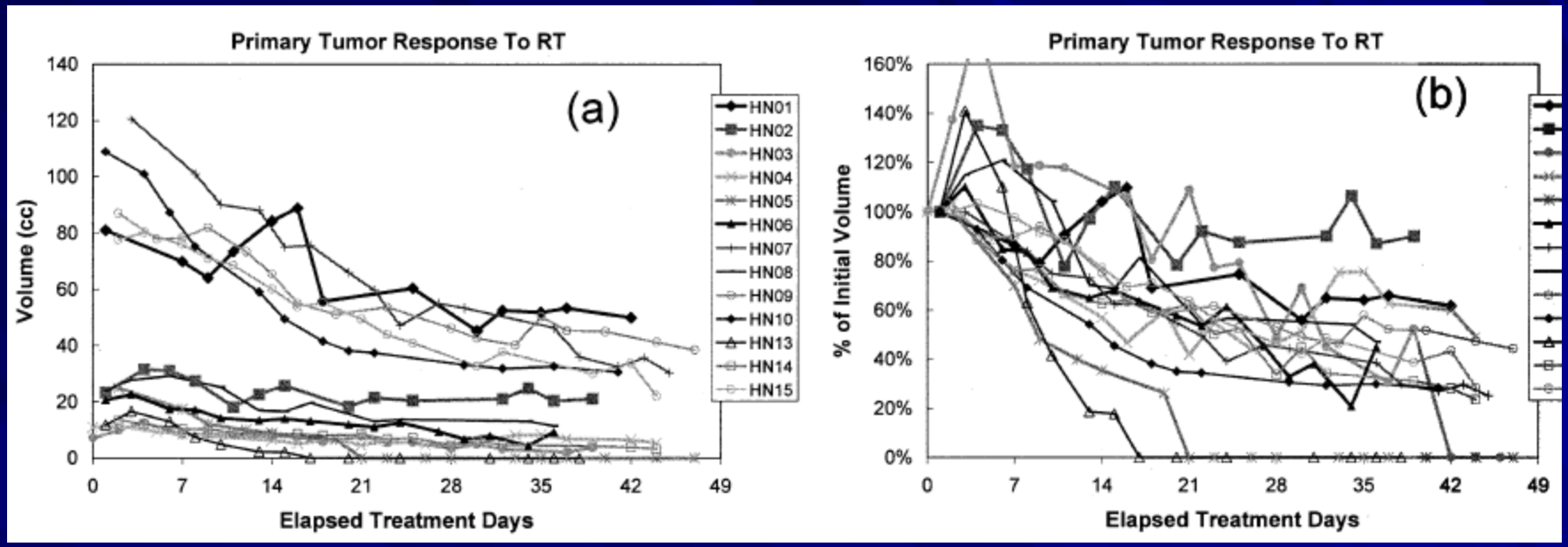
Primary Tumor Response To RT
(a)
Volume (cc)
Elapsed Treatment Days
HN01
HN02
HN03
HN04
HN05
HN06
HN07
HN08
HN09
HN10
HN13
HN14
HN15
Primary Tumor Response To RT
(b)
% of Initial Volume
Elapsed Treatment Days

Pre RT

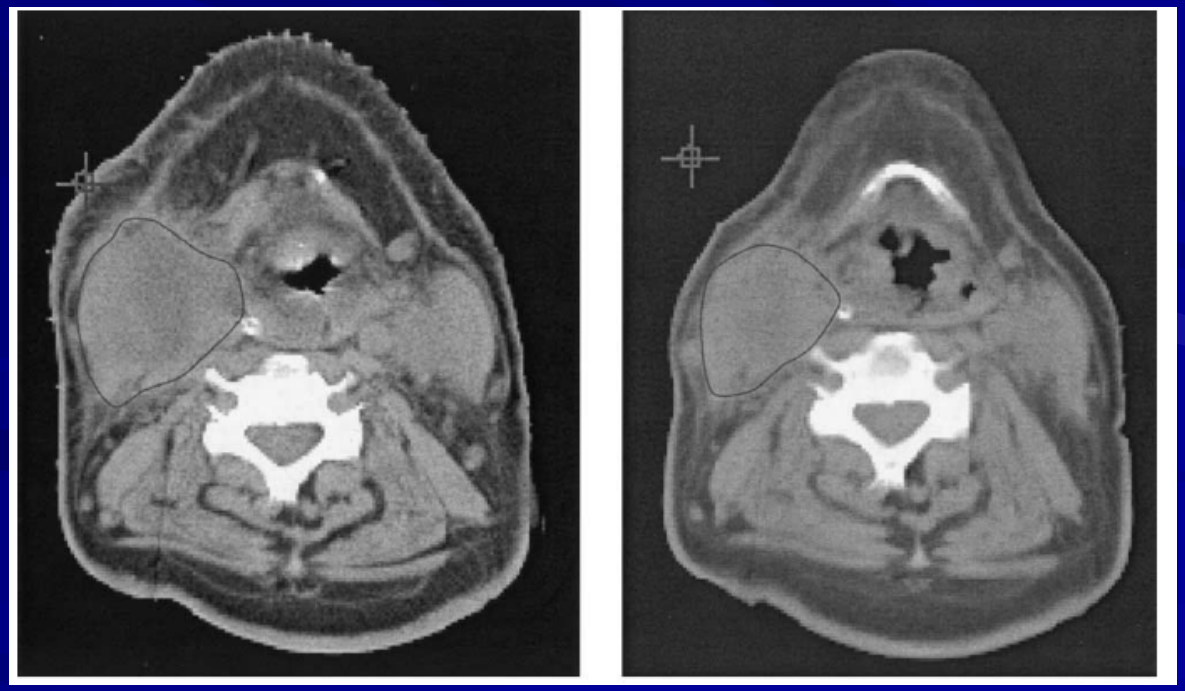

Week 3

Head and Neck Cancers

- Serial imaging during RT also reveals changes in parotid glands
- Glands decrease in volume
- Move medially into high dose volumes

Evaluation of geometric changes of parotid glands during head and neck cancer radiotherapy using daily MVCT and automatic deformable registration

Choonik Lee[a,*], Katja M. Langen[a], Weiguo Lu[b], Jason Haimerl[b], Eric Schnarr[b], Kenneth J. Ruchala[b], Gustavo H. Olivera[b], Sanford L. Meeks[a], Patrick A. Kupelian[a], Thomas D. Shellenberger[c,d], Rafael R. Mañon[a]

[a]*Department of Radiation Oncology, M.D. Anderson Cancer Center Orlando, FL, USA,* [b]*TomoTherapy, Inc. Madison, WI, USA,* [c]*Department of Head and Neck Surgery, M.D. Anderson Cancer Center Orlando, Orlando, FL, USA,* [d]*Department of Head and Neck Surgery, The University of Texas, M.D. Anderson Cancer Center, TX, USA*

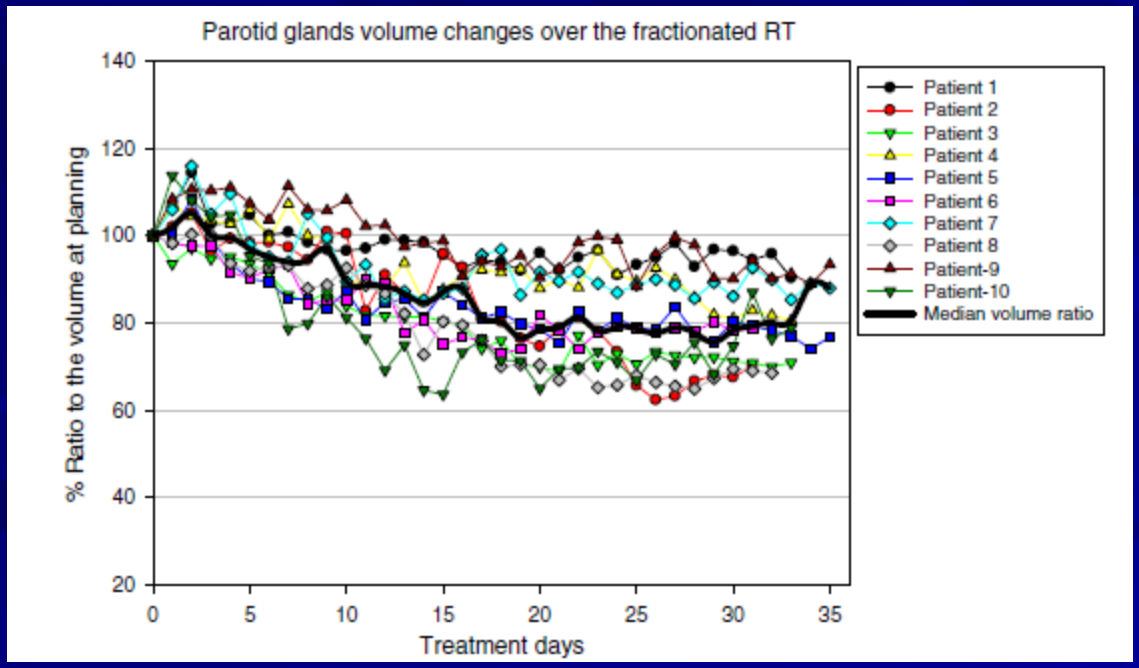

- 10 pts treated with daily MVCT setup using helical tomotherapy
- Average parotid gland volume decrease = 21.3%
- Median rate 0.7%/day

Lee et al. Radiother Oncol 2008;89:81

Parotid Displacement

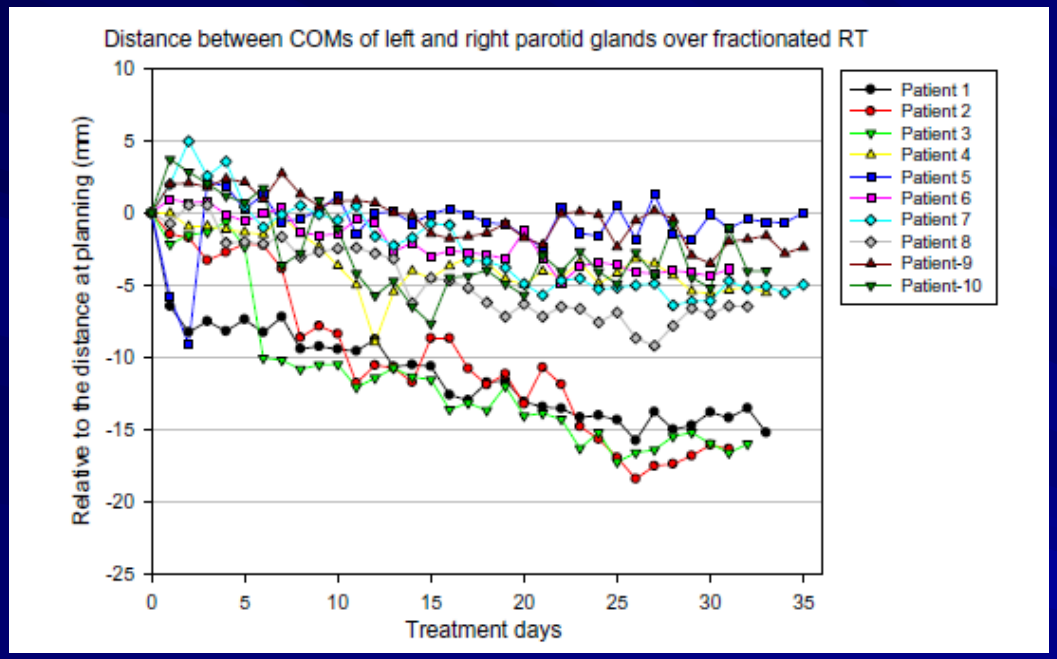

- Mean displacement = 5.3 mm
- Average shift = 0.22 mm per day
- Due to weight loss and regression of bulky nodes

Dosimetric Consequences

- Tumor regression, parotid shrinkage and displacement and weight loss all result in higher than planned parotid doses
- Higher doses result also in other normal tissues including the spinal cord

Would adapting help?

CLINICAL INVESTIGATION Head and Neck

REPEAT CT IMAGING AND REPLANNING DURING THE COURSE OF IMRT FOR HEAD-AND-NECK CANCER

ERIC K. HANSEN, M.D.,* M. KARA BUCCI, M.D.,* JEANNE M. QUIVEY, M.D.,* VIVIAN WEINBERG, PH.D.,† AND PING XIA, PH.D.*

- 13 patients replanned midway through treatment due to tumor regression and weight loss
- No re-planning → ↓target coverage and ↑normal tissue dose
  - V95% of the PTV reduced in 92% of patients
  - Spinal cord max increased in all 13 patients
  - Brainstem max increased in 85%
- Re-planning ↑target coverage and normal tissue sparing

Barker et al. Int J Radiat Oncol Biol Phys 2004;59:960

Lung Cancer

- Morphologic changes well known in these tumors
- Long been commonplace to re-simulate patients with changes seen on portal films
- Increased available of in-room images increased our awareness of these changes and their impact on treatment

CLINICAL INVESTIGATION Lung

QUANTIFICATION OF TUMOR VOLUME CHANGES DURING RADIOTHERAPY FOR NON–SMALL-CELL LUNG CANCER

JANA FOX, M.D.,* ERIC FORD, PH.D.,* KRISTIN REDMOND, M.D.,* JESSICA ZHOU, B.S.,* JOHN WONG, PH.D.,* AND DANNY Y. SONG, M.D.*

*Department of Radiation Oncology and Molecular Radiation Sciences, Johns Hopkins University School of Medicine, Baltimore, MD

- 22 stage I-III lung cancer patients
- Pre and mid-treatment CT (30 and 50 Gy)
- Mean GTV reduction
  - On first scan: 24.7%
  - On second scan: 44.3%
- Largest reduction occurred in majority of patients by the first scan (30 Gy)

Fox et al. Int J Radiat Oncol Biol Phys 2009;74:341

Pre-Treatment

30 Gy

50 Gy

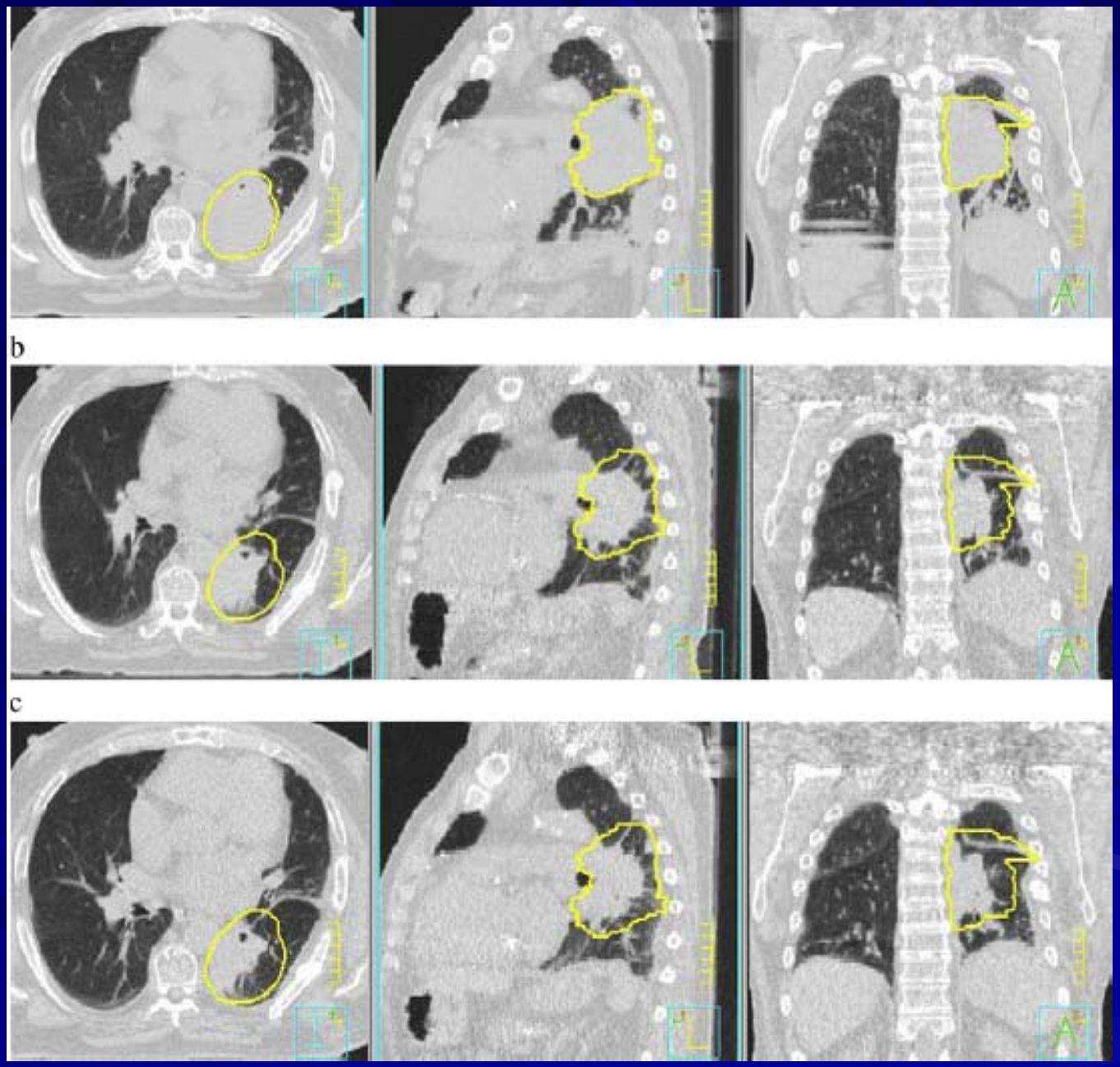

Sometimes tumor volumes increase

ROLE OF ADAPTIVE RADIOTHERAPY DURING CONCOMITANT CHEMORADIOTHERAPY FOR LUNG CANCER: ANALYSIS OF DATA FROM A PROSPECTIVE CLINICAL TRIAL

FEMKE O. B. SPOELSTRA, M.D.,* JASON R. PANTAROTTO, M.D., F.R.C.P.C.,* JOHN R. VAN SÖRNSEN DE KOSTE, PH.D.,* BEN J. SLOTMAN, M.D., PH.D.,* AND SURESH SENAN, M.R.C.P., F.R.C.R., PH.D.*

*Department of Radiation Oncology, VU University Medical Center, Amsterdam, The Netherlands

- 21 lung cancer patients
- Repeat 4DCT after 15 fractions
- Mean reduction in internal target volume (ITV) = 34 cc
- Mean overall PTV reduction = 55.6 cc
- 6/21 patients had a larger ITV
- % increase of 6%, 21% and 47%

Spoelstra et al. Int J Radiat Oncol Biol Phys 2009;75:1092

Does Adapting to Changes Help?

Results are Mixed

ADAPTIVE RADIOTHERAPY PLANNING ON DECREASING GROSS TUMOR VOLUMES AS SEEN ON MEGAVOLTAGE COMPUTED TOMOGRAPHY IMAGES

CURTIS WOODFORD,* SLAV YARTSEV, PH.D.,* A. RASHID DAR, M.D.,*† GLENN BAUMAN, M.D.,*† AND JAKE VAN DYK, M.SC.*†

* London Regional Cancer Program, London Health Sciences Centre, London, Ontario, Canada; and
† The University of Western Ontario, London, Ontario, Canada

- 17 lung cancer patients
- Daily MVCT using helical tomotherapy
- Mean GTV decrease: -0.79%/day
- Adapting re-planning beneficial in some but not all pts
- Two groups benefited:
  - Patients with a global linear decrease
  - Patients with an initial plateau then rapid decrease
- No benefit in 24% of patients with variable or no clear GTV decrease

Woodford et al. Int J Radiat Oncol Biol Phys 2007;69:1316

Gastrointestinal Cancers

- Limited data assessing morphologic changes occurring during treatment in GI tumors
- No data on the dosimetric consequences of these changes

BIOLOGICAL IMAGE-GUIDED RADIOTHERAPY IN RECTAL CANCER: CHALLENGES AND PITFALLS

Sarah Roels, M.D.,* Pieter Slagmolen,† Johan Nuyts, Ph.D.,‡ John A. Lee, Ph.D.,§ Dirk Loeckx, Ph.D.,† Frederik Maes, Ph.D.,† Vincent Vandecaveye, M.D.,‖ Sigrid Stroobants, M.D., Ph.D.,‡ Nadine Ectors, M.D., Ph.D.,¶ Freddy Penninckx, M.D., Ph.D.,# and Karin Haustermans, M.D., Ph.D.*

- 15 locally advanced rectal cancer pts
- MRI pre-RT, after 10 fractions and post-RT
- Significant reductions in tumor volumes at each point
  - Pre-treatment tumor volume = 27.1 cc
  - After 10 fractions = 13.4 cc
  - Post-treatment = 6.7 cc

Roels et al. Int J Radiat Oncol Biol Phys 2009 (in press)

Breast Cancer

- Another tumor site in which little or no changes are thought to occur
- Most likely due to the preponderance of early stage patients treated with adjuvant RT
- However, even in those women, a variety of morphologic changes occur during RT

PLANNING THE BREAST TUMOR BED BOOST: CHANGES IN THE EXCISION CAVITY VOLUME AND SURGICAL SCAR LOCATION AFTER BREAST-CONSERVING SURGERY AND WHOLE-BREAST IRRADIATION

KEVIN S. OH, M.D.,* FENG-MING KONG, M.D., PH.D.,* KENT A. GRIFFITH, M.P.H., M.S.,† BETH YANKE, C.M.D.,* AND LORI J. PIERCE, M.D.*

*Department of Radiation Oncology, University of Michigan Medical School, Ann Arbor, MI; and †Biostatistics Unit of the University of Michigan Comprehensive Cancer Center, Ann Arbor, MI

- 30 early stage breast cancer pts
- Conventional CT pre-RT and at 40 Gy
- 95% had significant reductions in the lumpectomy volume
- Mean volume pre-RT = 32.1 cc
- Mean volume at 40 Gy = 25.1 cc
- Overall mean reduction of 22.5%
- No change in the overall breast volume (0.11% reduction)

Oh et al. Int J Radiat Oncol Biol Phys 2006;66:680

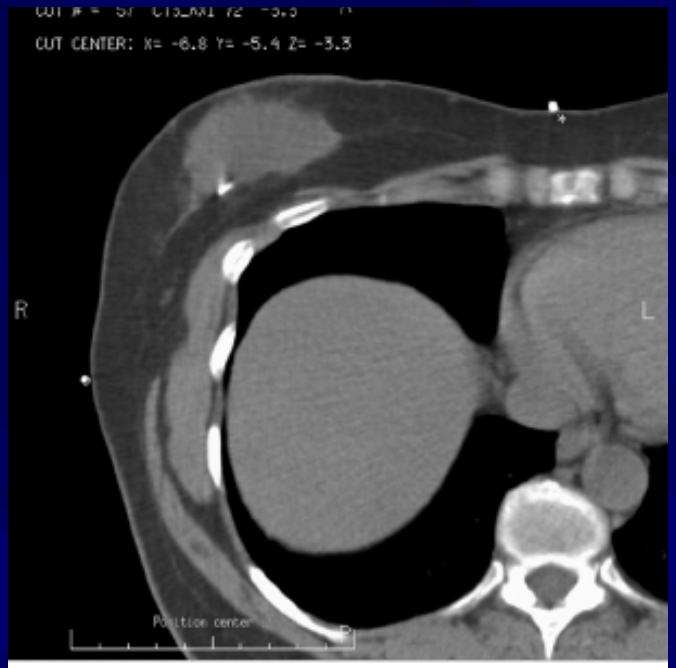
CUT CENTER: X= -6.8 Y= -5.4 Z= -3.3
R
L

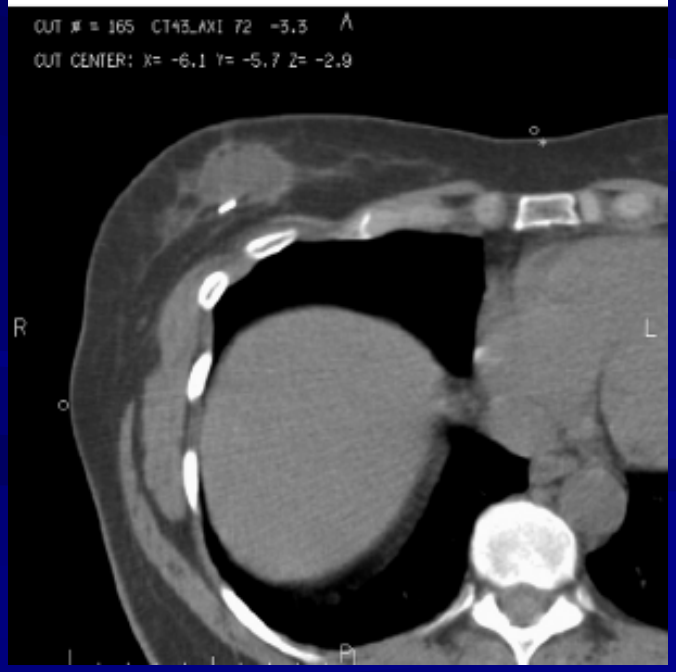
CUT # = 165 CT43_AXI 72 -3.3
CUT CENTER: X= -6.1 Y= -5.7 Z= -2.9
R
L

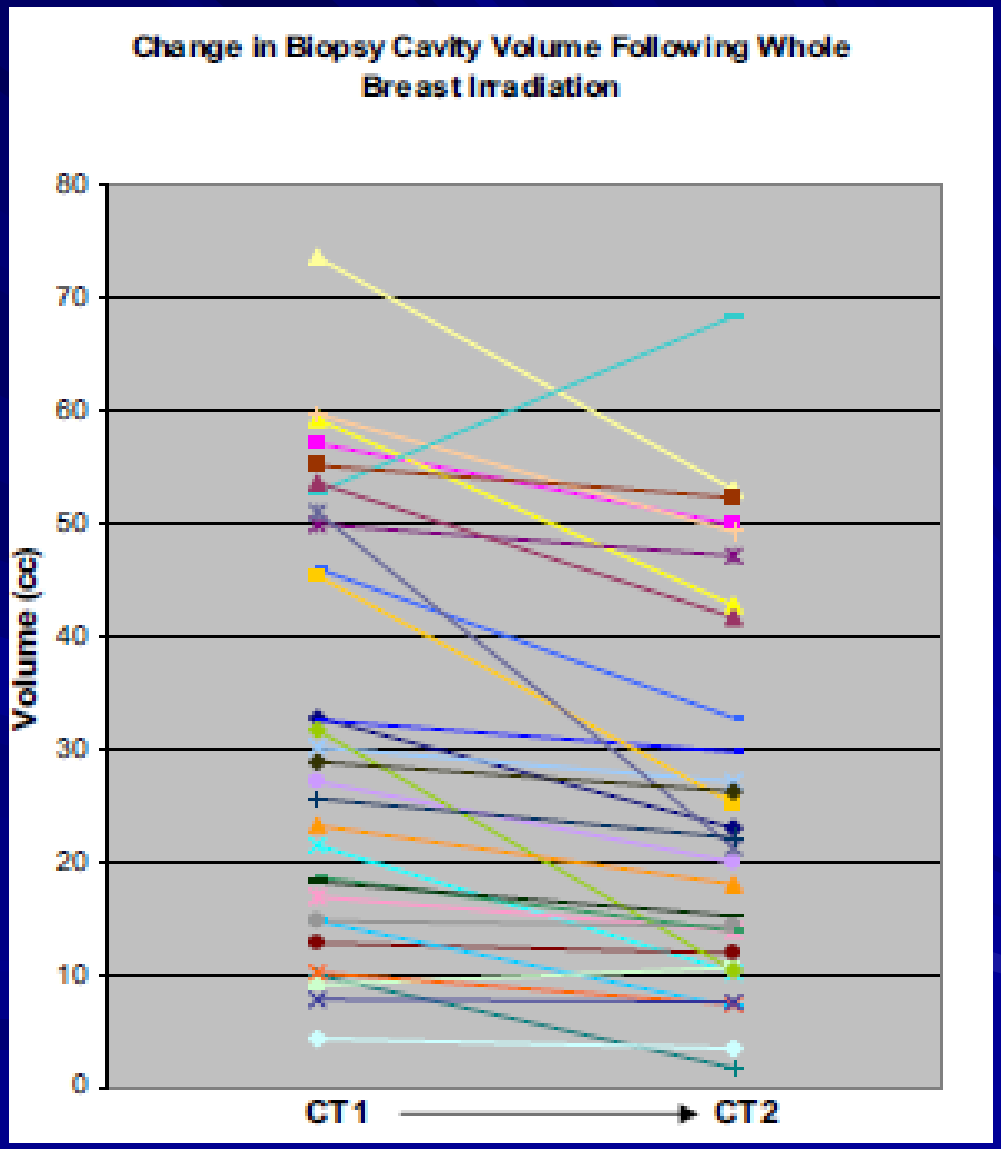
Change in Biopsy Cavity Volume Following Whole Breast Irradiation
Volume (cc)
0
10
20
30
40
50
60
70
80
CT1
CT2

Would adapting help?

Nichols et al.
ASTRO 2009

- 40 early stage breast cancer patients
- CT pre-RT and again at 37.8-41.4 Gy
- In women with >35% reduction in lumpectomy cavity, replanning significantly reduced the V90% volume of the boost sparing more breast tissue
- Mean difference 119 cc
- 25/40 patients had clinically significant changes in boost plans: 13 lower electron energy, 11 smaller cone

Nichol et al. Int J Radiat Oncol Biol Phys [abstract] 2009:75:S212

Genitourinary (GU) Cancers

- Lots of data published regarding morphologic changes in prostate and bladder cancer patients
- Majority demonstrate that clinically significant morphologic changes occur during RT
- Important since many think that the prostate moves but deforms little

A MAGNETIC RESONANCE IMAGING STUDY OF PROSTATE DEFORMATION RELATIVE TO IMPLANTED GOLD FIDUCIAL MARKERS

Alan M. Nichol, M.D.,*‡ Kristy K. Brock, Ph.D.,* Gina A. Lockwood, M.Math.,† Douglas J. Moseley, Ph.D.,* Tara Rosewall, B.Sc.,* Padraig R. Warde, M.B.,* Charles N. Catton, M.D.,* and David A. Jaffray, Ph.D.*

*Radiation Medicine Program and †Department of Clinical Study Co-ordination and Biostatistics, Princess Margaret Hospital and University of Toronto, Toronto, Canada; ‡Department of Radiation Oncology, BC Cancer Agency and University of British Columbia, Vancouver, Canada

- 25 early stage prostate cancer patients
- All with implanted fiducial markers
- Serial MRI scans (pre-RT and randomly during treatment)
- Prostate volume decreased by 0.5%/fraction
- Fiducial markers in-migrated by 0.05 mm/fraction
- Significant deformations occurred particularly in patients with a history of a TURP

Nichols et al. Int J Radiat Oncol Biol Phys 2007;67:48

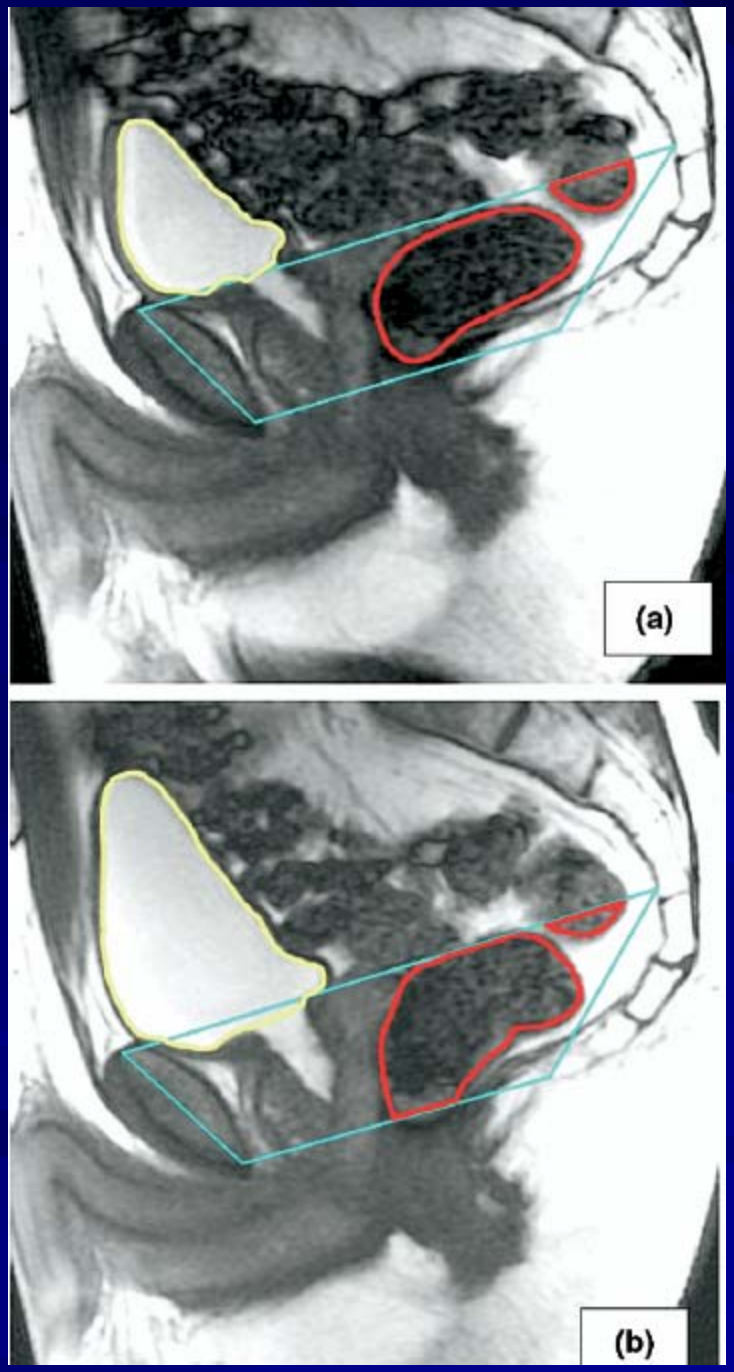

- Significant deformations in prostate volume in a patient with a prior TURP

Do these changes matter? Would adapting to them help?

On-line re-optimization of prostate IMRT plans for adaptive radiation therapy*

Q Jackie Wu[1], Danthai Thongphiew[1,2], Zhiheng Wang[1], Boonyanit Mathayomchan[2], Vira Chankong[2], Sua Yoo[1], W Robert Lee[1] and Fang-Fang Yin[1]

- Daily CBCT imaging of early stage prostate cancer
- Overall volume of prostate changed little
- Large deformations noted anterior portion of the prostate and in the seminal vesicles
- Underdosage of the target tissues
- Re-planning improved target coverage and conformity index
- Improved rectal sparing, no benefit in bladder sparing

Wu et al. Phys Med Biol 2008;53:673

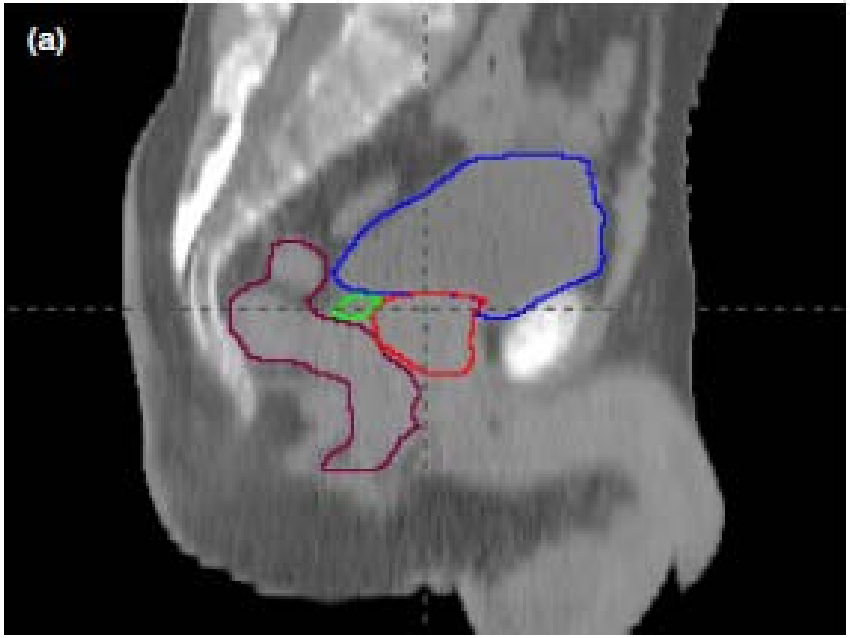

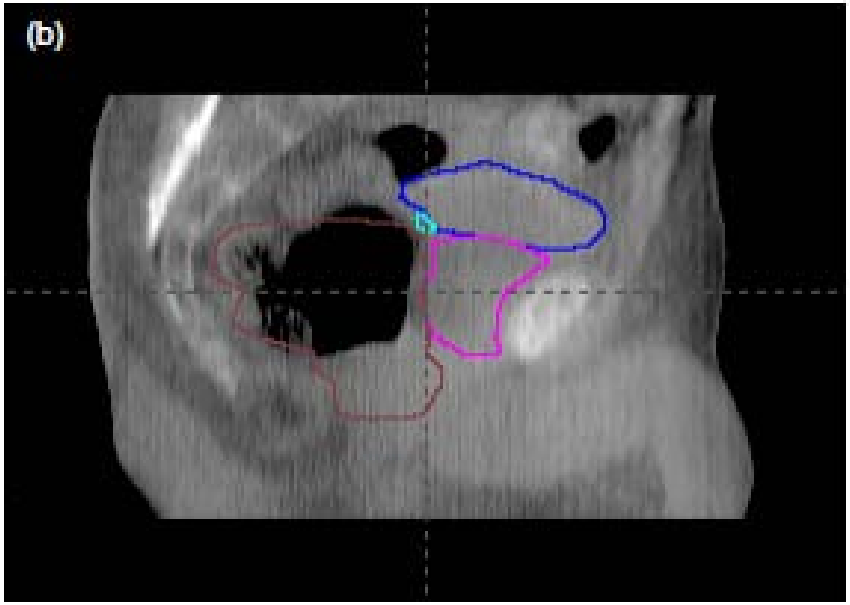

Such large deformations can not be addressed by translational corrections alone

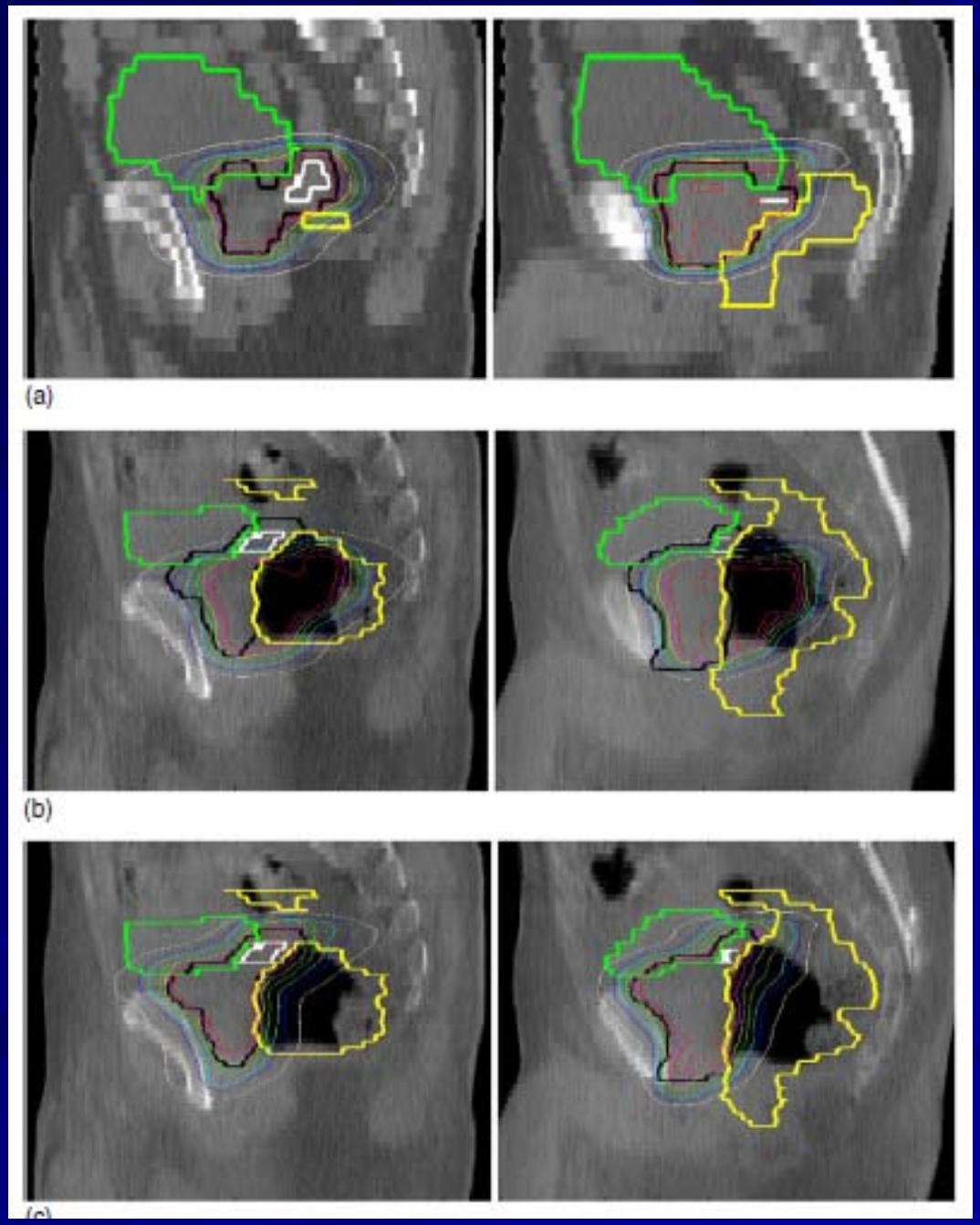

Dose Distributions

Initial Plan

Unadapted Plan

Adapted Plan

ADAPTIVE RADIOTHERAPY FOR INVASIVE BLADDER CANCER: A FEASIBILITY STUDY

FLORIS J. POS, M.D.,* MAARTEN HULSHOF, M.D., PH.D.,† JOOS LEBESQUE, M.D., PH.D.,* HEIDI LOTZ, PH.D.,* GEERTJAN VAN TIENHOVEN, M.D., PH.D.,† LUC MOONEN, M.D., PH.D.,* AND PETER REMEIJER, PH.D.*

*Department of Radiation Oncology, The Netherlands Cancer Institute-Antoni van Leeuwenhoek Hospital, Amsterdam, The Netherlands; †Department of Radiation Oncology, Academic Medical Center, University of Amsterdam, Amsterdam, The Netherlands

- 21 bladder cancer patients
- Partial bladder definitive irradiation
- Serial conventional CT imaging
- Mean GTV decrease by 40 cc (range 4-100 cc)
- Overall decrease 0.09 cc/day
- But no change in 6 and increase in 1 patient
- Also GTV markedly changed in shape during treatment

Pos et al. Int J Radiat Oncol Biol Phys 2006;64:862

Do these changes matter?

- 65% of patients had part of the CTV outside the planning CT-based PTV at least once during RT
- Incomplete coverage of the bladder volume occurred most commonly along the cranial aspect of the bladder
- In only 71% of patients did the GTV receive 95% of the prescribed dose on the weekly scans

Gynecologic Cancers

- No debate that gynecologic tumors, particularly cervical cancer, shrink and deform during treatment
- Many authors have demonstrated this using serial CT, MRI and more recently in-room imaging

CONVENTIONAL, CONFORMAL, AND INTENSITY-MODULATED RADIATION THERAPY TREATMENT PLANNING OF EXTERNAL BEAM RADIOTHERAPY FOR CERVICAL CANCER: THE IMPACT OF TUMOR REGRESSION

LINDA VAN DE BUNT, M.D.,* UULKE A. VAN DER HEIDE, PH.D.,* MARTIJN KETELAARS, PH.D.,* GERARD A. P. DE KORT, M.D.,† AND INA M. JÜRGENLIEMK-SCHULZ, M.D., PH.D.*

Departments of *Radiation Oncology and †Radiology, University Medical Center Utrecht, Utrecht, The Netherlands

- 14 intact cervical cancer patients
- MRI pre-RT and again at 30 Gy mid-treatment
- Mean volume pre-RT = 71 cc
- Mean volume at 30 Gy = 39 cc

Van de Bunt et al. Int J Radiat Oncol Biol Phys 2006;64:189

Pre-Treatment 30 Gy

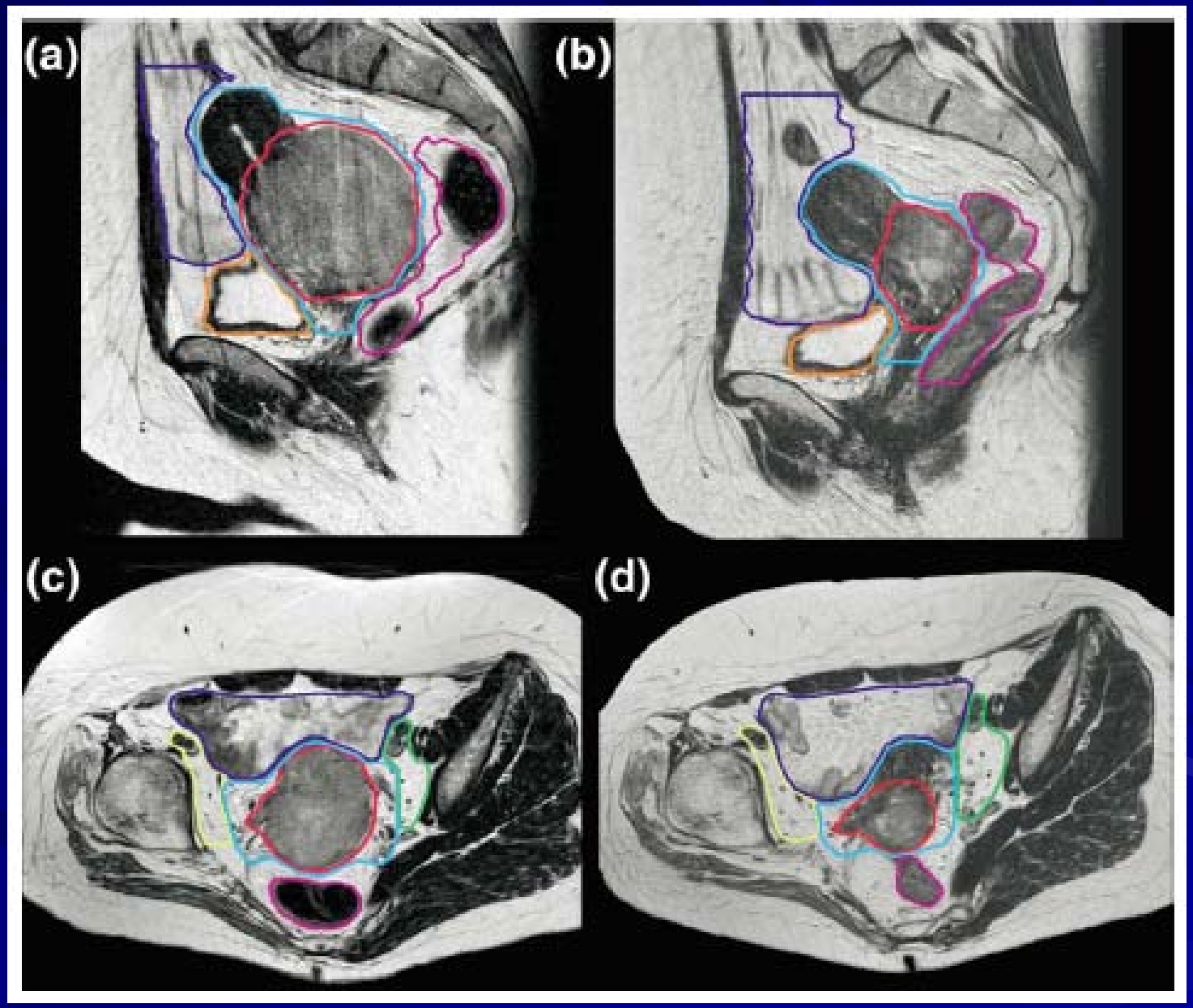

USEFULNESS OF TUMOR VOLUMETRY BY MAGNETIC RESONANCE IMAGING IN ASSESSING RESPONSE TO RADIATION THERAPY IN CARCINOMA OF THE UTERINE CERVIX

NINA A. MAYR, M.D.,* VINCENT A. MAGNOTTA, M.S.,† JAMES C. EHRHARDT, PH.D.,†
JAMES A. WHEELER, M.D., PH.D.,* JOEL I. SOROSKY, M.D.,‡ B.-CHEN WEN, M.D.,*
CHARLES S. DAVIS, PH.D.,§ RETTA E. PELSANG, M.D.,† BARRIE ANDERSON, M.D.,‡
J. FRED DOORNBOS, M.D.,* DAVID H. HUSSEY, M.D.* AND
WILLIAM T. C. YUH, M.D., M.S.E.E.†

- 60 intact cervical cancer patients
- MRI pre-RT, at 2-2.5 weeks, at 4-5 weeks and post-RT
- Median volumes
  - Pre-RT 54 cc
  - 2-2.5 weeks 31 cc
  - 4-4.5 weeks 7 cc
  - Post-RT 0 cc

Mayr NA et al. Int J Radiat Oncol Biol Phys 1996;35:915

Gynecologic Cancers

- Huh et al. evaluated 66 cervical cancer pts with serial MRI scans
- Significant deformations seen in the cervix, uterus and normal tissues
- Changes most pronounced in younger women (< age 60)

Huh et al. Radiother Oncol 2004;71:73

Do These Changes Matter?

Results are Mixed

PELVIC RADIOTHERAPY FOR CANCER OF THE CERVIX: IS WHAT YOU PLAN ACTUALLY WHAT YOU DELIVER?

Karen Lim, M.B.B.S.,* Valerie Kelly, M.Sc.,* James Stewart, M.A.Sc.,* Jason Xie, M.Sc.,* Young-Bin Cho, Ph.D.,* Joanne Moseley, B. Math.,* Kristy Brock, Ph.D.,*† Anthony Fyles, M.D.,*‡ Anna Lundin, M.Sc.,§ Henrik Rehbinder, Ph.D.,§ and Michael Milosevic, M.D.*‡

- 20 locally advanced cervical cancer patients
- Weekly MRI scans
- MRI plan generated based on pre-RT MRI + 5 mm margins cast onto weekly MRI scans
- Mean GTV D-98 decreased (5017 to 4987 cGy)
- Mean CTV D-98 decreased (4920 to 4865 cGy)
- Accumulated GTV dose >95% in all patients
- Accumulated CTV dose >95% in all but 1 patient (uterus changed from retroverted to anteverted during RT)

Lim et al. Int J Radiat Oncol Biol Phys 2009;74:304

Other results less favorable

Mell et al. (UCSD)
Red Journal (in press)

- 10 cervical cancer patients with daily CBCT
- CTV based on pre-RT imaging cast onto daily CBCT and modified to account for regression and deformation
- Using a 5 mm expansion, the percentage of fractions not covered by the prescription dose was 95.4%
- Even with generous margins (2 cm), the % fractions not covered by the prescription dose was 20%

Would adapting help?

CONVENTIONAL, CONFORMAL, AND INTENSITY-MODULATED RADIATION THERAPY TREATMENT PLANNING OF EXTERNAL BEAM RADIOTHERAPY FOR CERVICAL CANCER: THE IMPACT OF TUMOR REGRESSION

LINDA VAN DE BUNT, M.D.,* UULKE A. VAN DER HEIDE, PH.D.,* MARTIJN KETELAARS, PH.D.,* GERARD A. P. DE KORT, M.D.,† AND INA M. JÜRGENLIEMK-SCHULZ, M.D., PH.D.*

Departments of *Radiation Oncology and †Radiology, University Medical Center Utrecht, Utrecht, The Netherlands

- Explored re-planning mid-way through treatment
- Re-planning improved sparing of the rectum
- In patients with > 20 cc GTV regression, re-planning improved sparing of the bowel as well

Van de Bunt et al. Int J Radiat Oncol Biol Phys 2006;64:189

But what about the rest of treatment?

- A new treatment plan may be beneficial on one day but may be worse on subsequent days

Lawson et al. (UCSD)
ASTRO 2009

- 10 cervical cancer patients with daily CBCT
- 2 IMRT plans were generated
  - initial IMRT plan based on the planning CT
  - Adaptive IMRT plan based on the CBCT at 30 Gy
- Non-adaptive approach used on the initial plan
- Adaptive approach switched to the adaptive plan at 30 Gy
- Adaptive approach improved CTV V100 and conformity index compared to the non-adaptive approach
- Also better bladder and small bowel sparing
- Mixed results in terms of rectal sparing
  - 4 improved, 3 no improvement, 3 worse

Bone Marrow Imaging:
MRI IDEAL Fat Fraction Maps

Pre-Treatment | Mid-Treatment | Post-Treatment

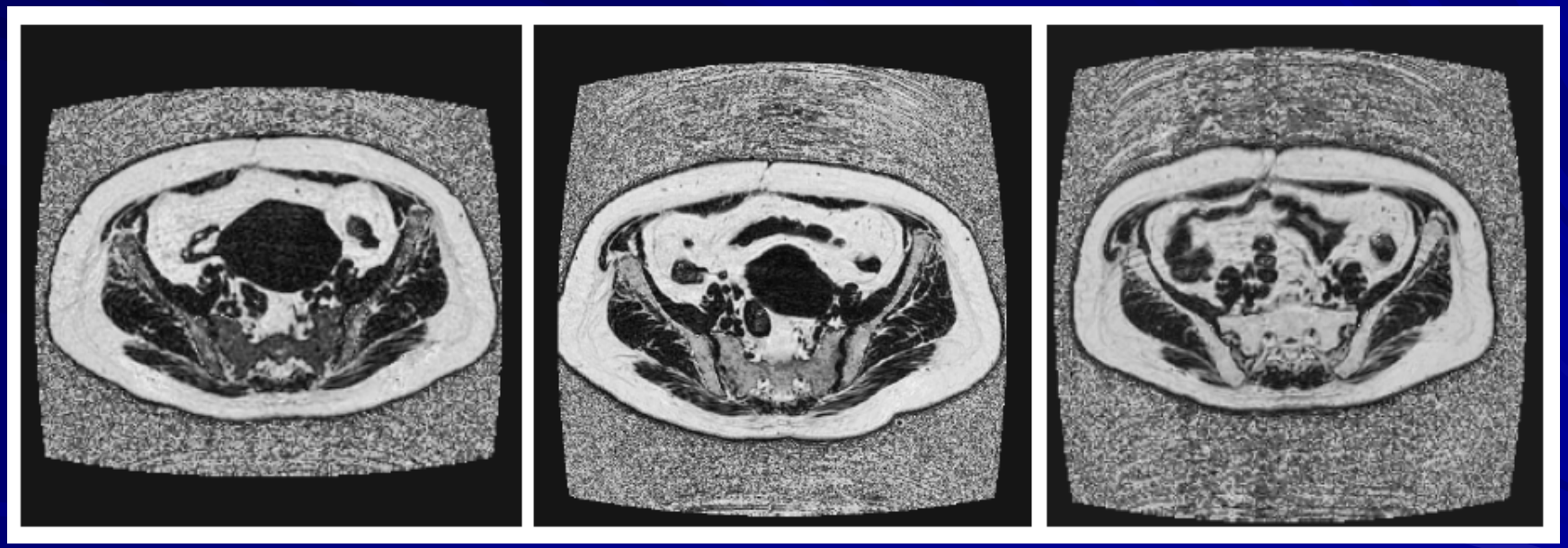

Lymphomas

- One of the most radiosensitive tumors
- Long been commonplace to resimulate patients with significant regression to spare normal tissues

Lymphoma

Renaud et al.
Can J Urol 2009;16:4639

- Bulky abdominal non-Hodgkin's lymphoma patient
- Treated on helical tomotherapy with daily MVCT
- During treatment, GTV shrank by 50.6%
- Re-planning midway through treatment would have reduced the dose to all surrounding normal tissues including the kidneys, liver, spinal cord and bowel
- Mean liver and spinal cord doses could have been reduced by 3.8 and 4 Gy, respectively

Pediatrics

Beltran et al.
St. Jude Children's Hospital
ASTRO 2009

- 10 craniopharyngioma patients
- Median age 8.4 years
- Weekly MRI scans
- Maximum GTV reduction 28.4% (4.1 cc)
- Re-planning based on weekly scans improved the tumor control probability from 90.8% to 85.7%
- No improvements seen in the normal tissue complication probabilities and sparing of normal structures

Adaptive IGRT

- Data shown literally only scratch the surface of the myriad of morphologic changes that are known to occur during RT
- Many other tumors have not yet been evaluated during treatment
- Seems changes are being found wherever and whenever one looks

Adaptive IGRT

- Question quickly turning from do changes occur to should we adapt to them
- Only way to answer whether adaptive IGRT helps or hurts our patients is to perform carefully designed prospective clinical trials

Adaptive IGRT Protocols

Site	Prospective	Protocols
CNS		-
Head and Neck		+
Lung		+
Breast	+	
GI		-
GU		+
Gynecology		+
Lymphoma		-
Pediatrics		-

UCSD Center for Advanced Radiotherapy Technologies (CART)

Thank-you for your attention