Molecular Breast Imaging

Development of a Low-Dose Screening Test for Dense Breasts

Carrie B. Hruska, Ph.D.
Department of Radiology
Division of Medical Physics
Mayo Clinic, Rochester, MN

Conflict of Interest

- **Royalties for technologies licensed to Gamma Medica Ideas**

Mayo's MBI Team

Overview

- **Current methods for screening in dense breasts**
- **Nuclear Medicine's role in breast imaging**
- **Low-Dose Molecular Breast Imaging (MBI)**
  - **Screening in dense breasts**
  - **Other applications**
  - **Limitations and advantages**
  - **Future developments**

Breast Cancer Screening Guidelines

In US, women are urged to get annual screening mammograms starting at age 40

- Long debate about use in women ages 40-49
- USPSTF has recommended against use of routine mammography in women under 50 twice since 1997

November 2009

CLINICAL GUIDELINES | Annals of Internal Medicine

Screening for Breast Cancer: U.S. Preventive Services Task Force Recommendation Statement

SUMMARY OF RECOMMENDATIONS AND EVIDENCE

The USPSTF recommends against routine screening mammography in women aged 40 to 49 years. The decision to start regular, biennial screening mammography before the age of 50 years should be an individual one and take patient context into account, including the patient's values regarding specific benefits and harms. This is a C recommendation.

Annals of Internal Medicine

---

abc NEWS

Stop Annual Mammograms, Govt. Panel Tells Women Under 50

New Guidelines Set Off Debate Over Costs, Benefits of Mammography

By LAUREN COX
ABC News Medical Unit

Nov. 16, 2009—

For the first time in 20 years, a government panel is telling women in their 40s to stop getting routine mammograms and recommending that a host of other breast cancer screenings slow down.

The United States Preventive Service Task Force announced Monday that it recommends against annual mammograms for women age 40 to 49 because, they say, the benefits of testing do not outweigh the "harms" and risks.

The Washington Post

Breast exam guidelines now call for less testing

Change debated
Potential harm of frequent mammograms outweighs benefit, task force says

By Rob Stein, Washington Post Staff Writer
Tuesday, November 17, 2009

"Tens of thousands of lives are being saved by mammography screening, and these idiots want to do away with it," said Daniel B. Kopans, a radiology professor at Harvard Medical School. "It's crazy -- unethical, really."

Support of continued annual screening starting at age 40

- American Cancer Society
- American College of Radiology
- American College of Obstetrics and Gynecology
- Susan G Komen for the Cure
- Radiologic Society of North America
- Medical Centers

- 17 days later, Congress banned the use of these new guidelines in determining insurance coverage

Breast Cancer Screening Guidelines

Should women be screened?

yes, mortality benefit has been shown

Only mammography has demonstrated mortality benefit

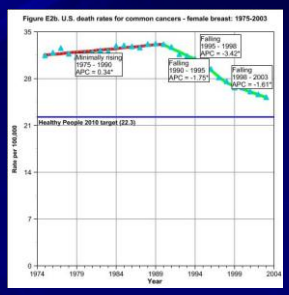

As much as two-thirds of the decline in breast cancer mortality can be attributed to screening mammography

Cancer Intervention and Surveillance Network, NEJM 2005;353:1784-1792

Breast Cancer Screening Guidelines

Should women be screened?

yes, mortality benefit has been shown

When to start?

How often?

***Why** is benefit of mammography less in younger women?*

Why is benefit less for younger women?

Breast Density

- Most important factor in failure of mammography to detect cancer
- Explains 68% of decreased sensitivity in younger women

Buist et al: JNCI, 2004

Breast Density Classification

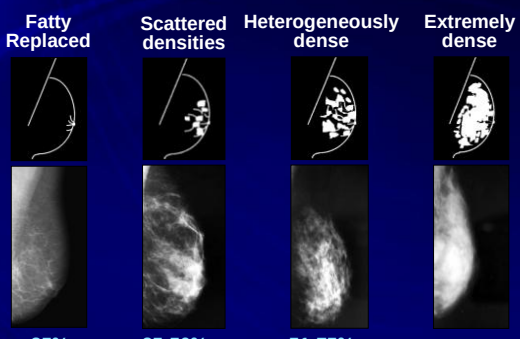

Breast Density by Age

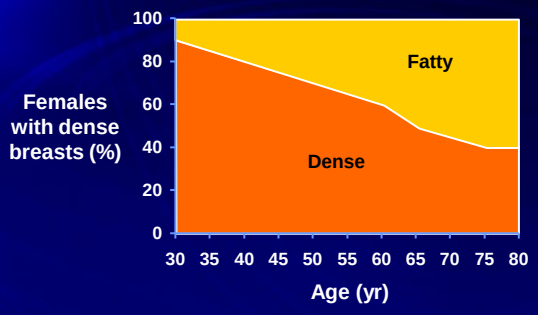

80% have dense breasts at age 40
40% have dense breasts at age 80

Kopans: Breast Imaging, 2nd ed, 1998

Performance of mammography in dense breasts

- Report sensitivity of mammography in extremely dense breasts ranges from 30-63%
  - Using follow-up mammogram findings as reference standard probably results in overestimate of true sensitivity

Mandelson MT et al. JNCI 2000;92:1081-7.
Carney PA et al, Ann Intern Med 2003;138:168-75
Pisano et al, Radiology 2008;246:376-383.

Digital Mammography

- ACRIN DMIST trial
  - 50,000 women screening with both film and digital mammography
  - Single subgroup in whom digital was significantly better than film: pre- or peri-menopausal women <50 years with dense breasts
    - Sensitivity: 59% digital, 27% film

Pisano et al. NEJM 2005; 353:17

Pisano et al, Radiology 2008;246:376-383.

Density is an independent risk factor

- Density strongly associated with risk of developing breast cancer (4-6 x that of fatty replaced breasts)
- Greater likelihood of cancer recurrence in dense breasts

Boyd NF et al. Cancer Epidemiol Biomarkers Prev. 1998; 7:1133-44.

Habel LA et al. Cancer Epidemiol Biomarkers Prev 2010; 19:2488-95.

Breast Density
Comparative Relative Risks

Risk factor	Relative risk
BRCA mutation	20
Lobular carcinoma in situ	8-10
Dense breast parenchyma	4-6
Personal history of breast cancer	3-4
Family history (1° relative)	2.1
Postmenopausal obesity	1.5
Prempro (WHI)	1.26

Population Attributable Risk

- Breast density: 33%
- Family history: 9%
- BRCA 1, 2 mutations: 5%

Boyd NF et al. JNCI 1995; 87: 670–675.

Cuzick J. The Breast 2003; 12: 405-411

What are the current screening alternatives for women with dense breasts?

- **Tomosynthesis**
- **Ultrasound**
- **MRI**

Tomosynthesis

- **(See previous lecture for expert review)**
- **Recently FDA-approved**
- **Multiple studies ongoing**
- **ACRIN is likely to fund clinical trial**

Ultrasound

- **ACRIN 6666 trial (high risk and dense breasts)**
  - physician-performed WBU
  - Increased diagnostic yield from 7.6/1,000 with mammography alone to 11.8/1,000 by adding WBU Substantial number of false positives, PPV = 9%

  Berg et al, JAMA
- **Automated Whole Breast Ultrasound**
  - Increased diagnostic yield from 3.6/1,000 with mammography alone to 7.2/1,000 by adding AWBU
  - PPV = 38%
  - Many images to review

  Kelly et al, Eur Radiol 2010; 20:734-742

Magnetic Resonance Imaging

- In hands of expert readers:
  - Very high sensitivity (approaching 100%)
  - Acceptable specificity
- ACS issued 2007 recommendations
  - Annual screening MRI in women with risk >20%
  - Not enough evidence to recommend for screening in dense breasts
  - ACS recognized that specificity in community practice setting can be ~50%

CA Cancer J Clin 2007;57:75-89.

Nuclear Medicine Imaging of the Breast

- Scintimammography / Breast Scintigraphy
- Breast-Specific Gamma Imaging (BSGI)
- Positron Emission Mammography (PEM)
- Molecular Breast Imaging (MBI)

Scintimammography

- Refers to conventional "scintillating" gamma camera – technology of 1990's
- Bulky camera cannot be positioned close to the breast
- Interference from adjacent tissues (heart, liver)
- Poor sensitivity for lesions < 1 cm

Patient in prone position



Scintimammogram (lateral view)

Courtesy of MK O'Connor, unpublished image

Scintimammography
Effect of Breast Thickness on Lesion Detection



Dedicated Nuclear Medicine Detectors

- Allow positioning in standard mammographic views
- Minimal interference from adjacent tissues
- Better spatial resolution due to:
  - Close contact of breast with detector
  - Pixilated detectors

Dedicated Nuclear Medicine Detectors

BSGI
Dilon Diagnostics
Single Photon Detection
Multicrystal Sodium Iodide (NaI) + PMTs

PEM
Naviscan
Coincidence Detection
Scanning arrays of LYSO crystals

www.dilon.com


www.naviscan.com

Semiconductor Detector Cadmium Zinc Telluride





4 cm x 4 cm

cadmium zinc telluride (CZT) module

Pixel size: 1.6 mm or 2.5 mm

Scintillating vs. Semiconductor Detectors

Scintillator (NaI)

- Converts gamma ray photons to light
- Photomultiplier tubes (PMT) converts light to electrons

Semiconductor (CZT)

- Direct conversion: gamma rays to electrons
- Improved energy and spatial resolution over NaI

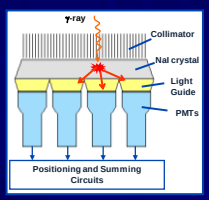

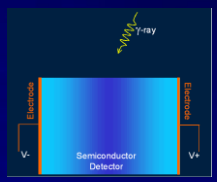

Our first prototype: Molecular Breast Imaging CZT gamma camera

Molecular Breast Imaging Systems

FDA-approved, clinically available
Dual-head CZT detectors

Gamma Medica
LumaGem

GE Healthcare
Discovery NM 750

MBI Procedure

- Tc-99m sestamibi injected IV
- Patient positioned by specially trained technologist
- Imaging begins immediately after injection
- Two views of each breast acquired (CC and MLO)
- Light, pain-free compression

Tc-99m sestamibi

- Developed for cardiac imaging
- FDA-approved for <u>diagnostic</u> breast imaging in 1997
- Exact mechanism of uptake in cancer uncertain
  - Proportional to blood flow and mitotic activity
- Imaging can commence minutes after injection
- Effective half-life = 3 hours
- Uptake not influenced by breast density

Could MBI Find Small Breast Tumors?

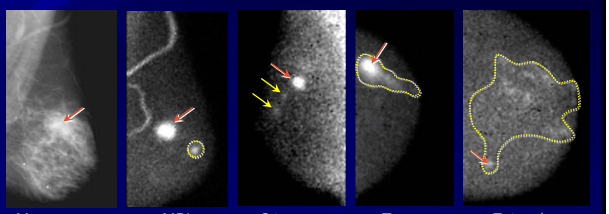

Mammogram 20 mm | MBI 20 mm Additional 10 mm tumor | 3 tumors 17, 6, 3 mm | Tumor extending to nipple | Extensive tumor

Two Heads are Better than One…

Missed cancers occurred more often in women with large compressed breast thickness



Could MBI Find Small Breast Tumors?

Detection of cancer in 88 patients with 128 tumors

Tumor Size	# of tumors	Single head MBI	Dual head MBI	P-value
≤ 10 mm	61	68%	82%	0.004
All	88	80%	90%	<0.0005

Hruska et al, AJR 2008; 191: 1808-1815

Better detection with Dual-head MBI, example 1

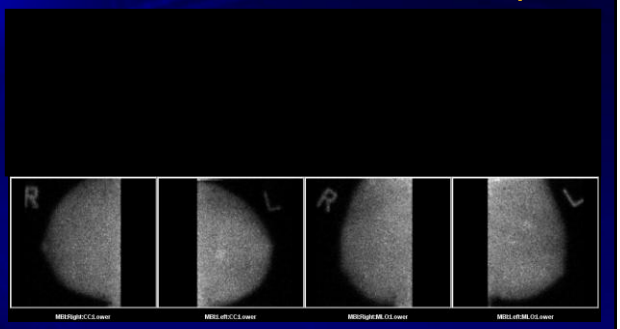

Images courtesy of Dr. Judy Boughey, Mayo Clinic

Better detection with Dual-head MBI, example 1

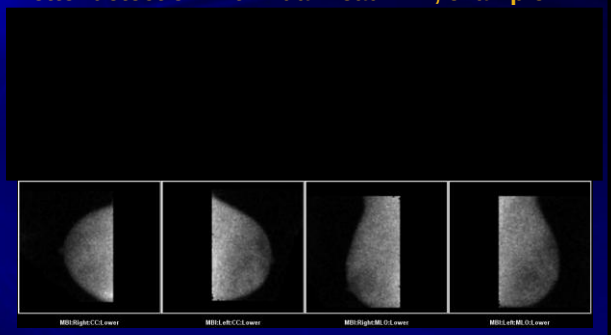

Images courtesy of Dr. Judy Boughey, Mayo Clinic

MBI for Screening in Dense Breasts
Funded by Komen for the Cure

- **Eligible women:**
  - Asymptomatic
  - Presenting for routine screening mammography
  - Heterogeneously or extremely dense breasts based on past prior mammogram


Dedicated Dual-Head Gamma Imaging for Breast Cancer Screening in Women with Mammographically Dense Breasts[1]

Rhodes et al. Radiology, Jan 2011

Results

- **1007 patients enrolled, 936 with known cancer status**
- **Mean age of patients: 55.7**
- **12 cancers diagnosed**
  - **1 by mammography only**
  - **8 by MBI only**
  - **2 by both**
  - **1 by neither (detected at next annual mammogram)**

Examples of Mammographically Occult Cancers Detected on MBI

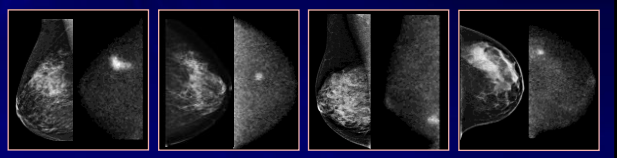

4 mm IDC + 19 mm DCIS | **10 mm tubulolobular** | **12 mm DCIS** | **51 mm ILC**

Rhodes et al. *Radiology* 2011.

Proof of Concept: MBI in Screening Setting

- Diagnostic yield increased detection from 3.2/1,000 for mammography alone to 10.7/1,000 by adding MBI (p=0.016)
- Sensitivity: 3/11 for mammography, 9/11 for MBI
- Specificity: 91% for mammography, 93% for MBI
- PPV of MBI = 12%, four times higher than mammography (3%) (P=0.01)
- Proof of concept: Need to verify findings using low dose (4 mCi) MBI

Radiation Risks of MBI

Modality	Dose to Breast (mGy)	Effective Dose (mSv)	Single exam, age 40: LAR of Fatal Cancer	Annual exams, ages 40-80: LAR of Fatal Cancer
Mammography (2-view bilateral screen)	3.7 (digital) 4.7 (film)	0.44 (digital) 0.56 (film)	1.3 – 1.7	20 – 25
PEM (10 mCi F-18 FDG)	2.5	6.2 – 7.1	31	400†
BSGI/ MBI (20-30 mCi Tc-99m sestamibi)	1.3 – 2	5.9 – 9.4	26 – 39	360 – 540†

Effective Dose accounts for organ-specific doses and weighting factors, and represents the dose to the entire body; LAR = Lifetime Attributable Risk per 100,000 women

Data from: Hendrick RE, Radiology 2010; 257:246-253.
†Data from: O'Connor et al. Medical Physics 2010, 37 (12).

Comparison with Background Radiation

LAR of Fatal Cancer due to Annual Background Radiation per 100,000 women

(birth to 80 years)

U.S. Average (3.1 mSv/year) ~1010

Colorado (~4.5 mSv/year) ~1460

Florida (~2.5 mSv/year) ~ 810

25 mCi MBI screening, age 40-80 (~7.6 mSv/year) ~ 450

Low-dose MBI screening, age 40-80 (~1.2 mSv/year) ~ 108

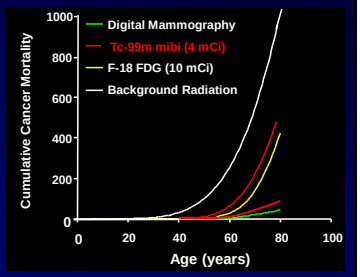

O'Connor et al. Medical Physics 2010, 37 (12).

MBI Dose Reduction

- For annual breast screening, target dose for MBI is 4 mCi Tc-99m sestamibi
  - 1.2 mSv effective dose
  - Equivalent to ~2 screening mammograms
  - Intended screening interval would be 2 years
- MBI dose reduction schemes
  - Optimization of collimator
  - Use of widened energy window
  - Post-acquisition image processing

O'Connor et al. Medical Physics, vol 37 (12), December 2010.

Collimator Optimization

- Hexagonal holes changed to square registered holes
  - Improves active area, count sensitivity
  - Holes closer together, switched from lead to tungsten
- Shorten bore, more count sensitive but give up resolution
- Dual-detector design means only ½ of breast needs adequate resolution for each detector

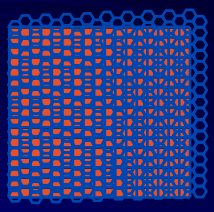



Registered Tungsten Collimator
CREATV MicroTech
Potomac, MD

Weinmann et al. Medical Physics 2009; 36: 845-856.

Collimator Optimization

- MBI performed with conventional and optimized collimators
- ~3 gain in counts

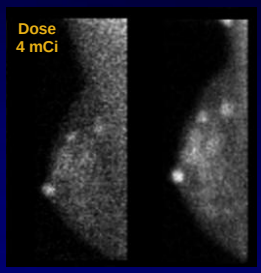

Standard collimator | Optimized collimator

MBI: detected multifocal invasive lobular carcinoma and nipple adenoma.

Digital Mammography: benign stable findings

O'Connor et al. Proceedings of SPIE 2010; vol 7806

MBI Dose Reduction: Wide Energy Acceptance Window

- Tailing Effect in CZT:
  "Good" photopeak events mis-registered at lower energies
  Due to incomplete charge trapping in semiconductor

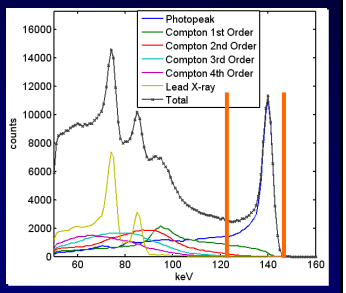

Hruska et al. IEEE Trans Nuc Sci 2008; 55:491-500.
O'Connor et al. Proceedings of SPIE 2010; vol 7806

MBI Dose Reduction: Wide Energy Acceptance Window



O'Connor et al. Proceedings of SPIE 2010; vol 7806

MBI Dose Reduction: Wide Energy Acceptance Window

- **MBI performed with conventional and widened energy window**
- **1.4 – 3.3x gain in counts**
- **Tradeoff: more counts but some scatter at chest wall**

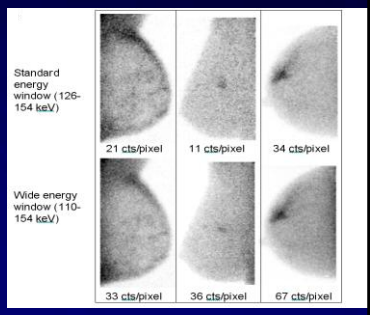

O'Connor et al. Proceedings of SPIE 2010; vol 7806

Low-Dose MBI: New Collimation and Wider Energy Window

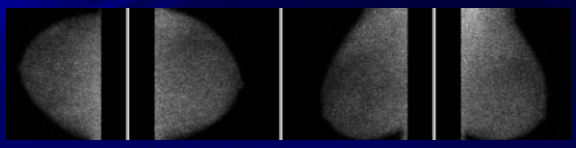

September 2007 – 20 mCi Tc-99m sestamibi

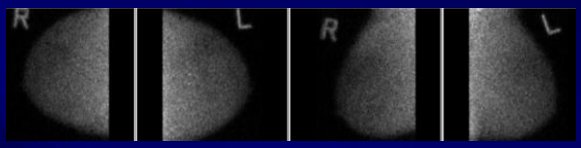

Same patient in December 2010 – 4 mCi Tc-99m sestamibi

Courtesy of Dr. Michael O'Connor, Mayo Clinic

Low-dose screening

Funded by Komen for the Cure

- Target recruitment: 2400
- Accrual to date: 600
- 8 mCi dose
  - Can simulate images at 2,4,and 6 mCi doses
- 9 cancers diagnosed
  - 8 detected by MBI
  - 0 detected by mammography
  - 1 found on prophylactic mastectomy
- PPV = 35%

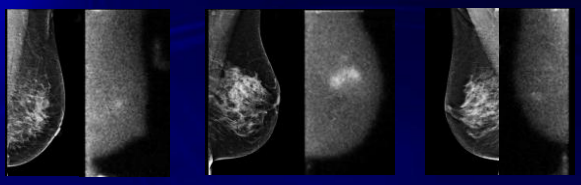

Tubular Carcinoma 0.5 cm

ILC 3.6 cm; LN+

DCIS 0.6 cm

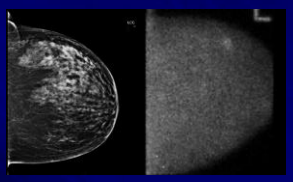

DCIS – final path pending

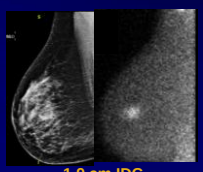

1.9 cm IDC

Mammogram 2010

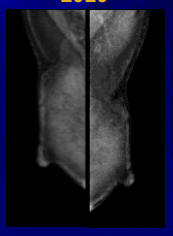

Read as extremely dense; Negative

Mammogram 2011

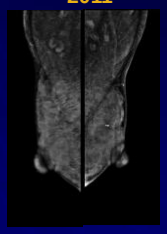

Read as extremely dense; Negative

MBI 2011

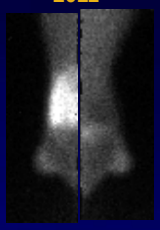

Final path

Right Mastectomy: DCIS

Patient unable to have MRI due to implanted device

Non-screening applications of MBI

MBI in preoperative evaluation

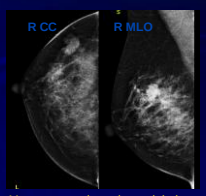

Mammogram: irregular nodule in UOQ at site of palpable abnormality

Ultrasound: 2.3 cm irregular hypoechoic mass

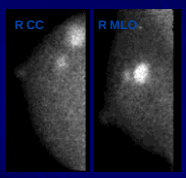

MBI: Uptake in 2 foci, 2.5 cm and 0.9 cm

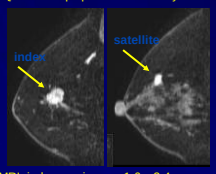

MRI: index carcinoma -1.6 x 2.4 cm irregular enhancing mass; satellite lesion - 0.8 x 1.4 cm

Final Pathology: Infiltrating ductal carcinoma, grade III, forming 2 masses: 2.2 cm, and 0.9 cm

Good correlation between MBI and MRI

9 mm cancer (Ductal Carcinoma In Situ)

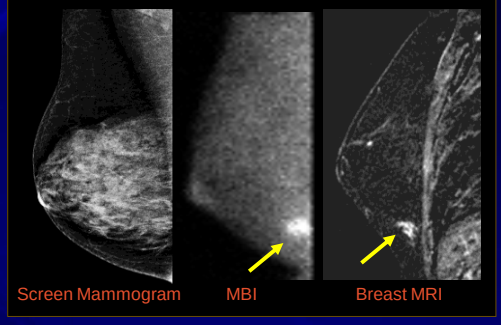

Neoadjuvant Therapy Case #1

Mammogram shows no change

Pre-Therapy

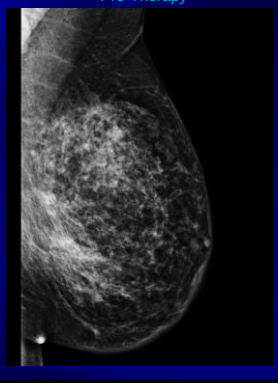

After 3 months of therapy

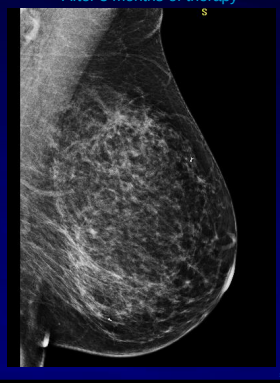

Neoadjuvant Therapy Case #1

MBI demonstrates pathologic complete response

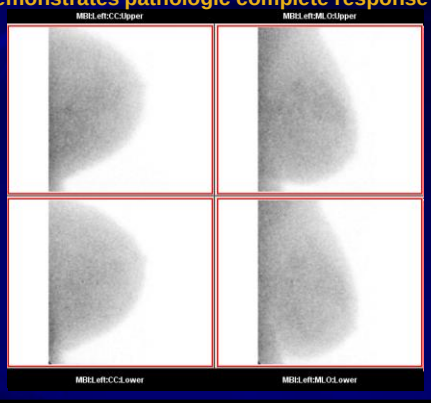

Neoadjuvant Therapy Case #2

MRI and MBI

MRI

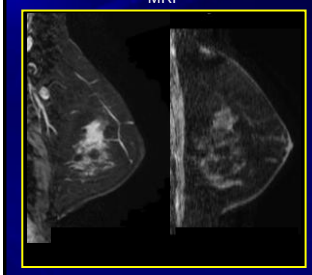

Pre-therapy Post-therapy

Molecular Breast Imaging

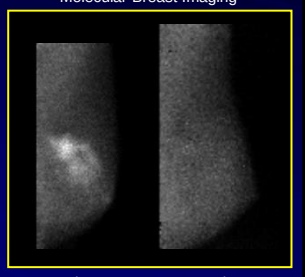

Pre-therapy Post-therapy

Initial diagnosis: IDC with large Area of DCIS
MRI: indicated residual disease
Left Mastectomy: Surgical Pathology indicated no residual viable cancer

MBI - Limitations and Disadvantages

False positive findings in some cases of fibroadenomas, papillomas, fat necrosis.

- Biopsies with benign findings:
  ~3% of screening cases

Fibroadenoma

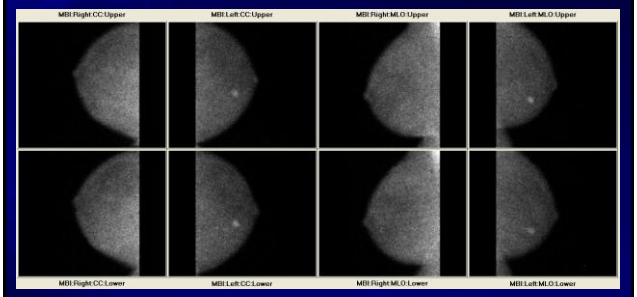

Benign Papilloma

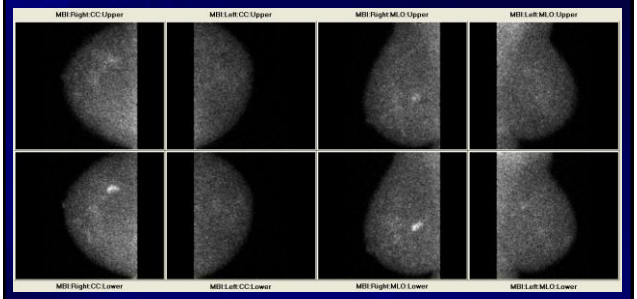

MBI - Limitations and Disadvantages

False positive findings in some cases of fibroadenomas, papillomas, fat necrosis.

Uptake of Sestamibi is influenced by hormonal changes – benign parenchymal uptake

Effect of Menstrual Cycle

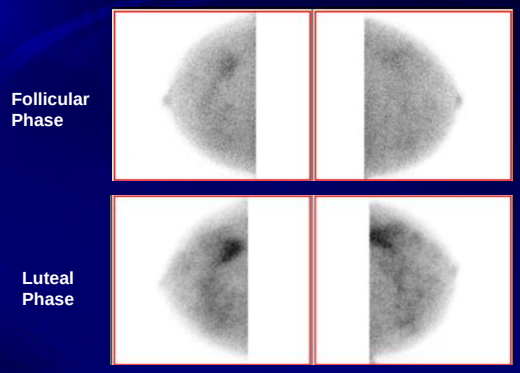

MBI - Limitations and Disadvantages

False positive findings in some cases of fibroadenomas, papillomas, fat necrosis.

Uptake of Sestamibi is influenced by hormonal changes – benign parenchymal uptake

Injection

MBI - Limitations and Disadvantages

False positive findings in some cases of fibroadenomas, papillomas, fat necrosis.

Uptake of Sestamibi is influenced by hormonal changes – benign parenchymal uptake

Injection

Radiation

MBI - Limitations and Disadvantages

False positive findings in some cases of fibroadenomas, papillomas, fat necrosis.

Uptake of Sestamibi is influenced by hormonal changes – benign parenchymal uptake

Injection

Radiation

Time to perform

MBI - Limitations and Disadvantages

False positive findings in some cases of fibroadenomas, papillomas, fat necrosis.

Uptake of Sestamibi is influenced by hormonal changes – benign parenchymal uptake

Injection

Radiation

Time to perform

Biopsy capability – in development

MBI - Limitations and Disadvantages

False positive findings in some cases of fibroadenomas, papillomas, fat necrosis.

Uptake of Sestamibi is influenced by hormonal changes – benign parenchymal uptake

Injection

Radiation

Time to perform

Biopsy capability – in development

Uncertain performance in DCIS

Advantages of MBI

- Compared to mammography:
  - Higher sensitivity in dense breasts
  - Less compression; patient comfort
- Compared to MRI:
  - Option if contraindication to MRI (claustrophobia, pacemaker, clips, impaired renal function)
  - Generalizability
    - Interpretation easy to learn
    - Rapid interpretation
    - Highly reproducible between readers, even those newly trained
  - 5-fold less expensive than MRI, $600 vs $3000 at Mayo

Future Developments in MBI

- Combined MBI / Ultrasound system with real-time MBI-guided biopsy in development
- Investigation of other radiopharmaceuticals

  Improved lesion detection / characterization
- Standardized reporting, terminology, and training course for MBI interpretation

  Collaboration with Dr. Wendie Berg (UPMC)
- Development of standardized QC tests and phantom for dedicated pixilated gamma cameras

Thank you!

This work has been funded in part by the following:
Mayo Foundation
National Institute of Health
Dept. of Defense
Susan G Komen For the Cure Foundation
Friends for an Earlier Breast Cancer Test