Use of CT and PET in Radiation Therapy

Refresher Course

Sasa Mutic

Department of Radiation Oncology
Siteman Cancer Center
Mallinckrodt Institute of Radiology
Washington University School of Medicine
St. Louis, Missouri 63110

Outline

- Multimodality-imaging in RT
- Current status of CT-simulation
- PET/CT incorporation in the treatment planning process
- Influence of PET imaging on RT
- Examples of PET based treatment planning
- Conclusions

Multimodality-imaging in RT

- Patient medical images are an essential tool in conformal radiation therapy
- Computed tomography (CT) is the primary modality for image based treatment planning
- Other imaging modalities can provide unique information which may improve overall patient management
  - Magnetic resonance imaging and spectroscopy
  - Single photon and positron emission computed tomography (SPECT and PET)
  - Ultrasound (US)
  - Molecular Imaging

Multimodality-imaging in RT

- The goal is to accurately delineate and biologically characterize an individual tumor, select an appropriate course of therapy, and to predict the response at the earliest possible time
- Image information can be categorized as:
  - Anatomical
  - Biological
    - » Metabolic
    - » Functional
    - » Physiological
    - » Genotypic
    - » Phenotypic

The potential of multimodality-imaging in RT

- Detection – Possibly better and earlier detection
  - Current imaging of disease is based on anatomic or physiologic changes that are a late manifestation of molecular changes that underlie the disease
- Staging - Improved staging and patient selection
  - Improved staging can define a more appropriate course of therapy

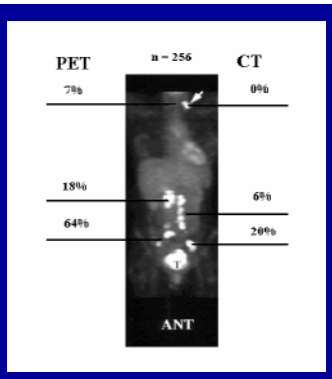

P.W. Grigsby et al, JCO, 2001

Lymph Node Status

n = 256

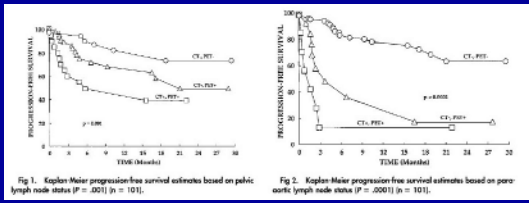

Fig 1. Kaplan-Meier progression-free survival estimates based on pelvic lymph node status (P = .001) (n = 101).

Fig 2. Kaplan-Meier progression-free survival estimates based on para-aortic lymph node status (P = .0001) (n = 101).

P.W. Grigsby et al, JCO, 2001

The potential of multimodality-imaging in RT

- Target definition
  - Improved target identification can significantly alter current treatment volumes
  - The true extent of the disease may extend beyond anatomically defined volumes
  - Anatomically defined volumes may contain regions of increased importance - Biological target volume (BTV)

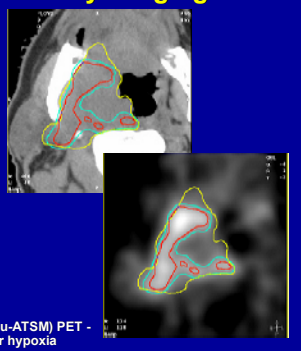

Ling *et al* IJROBP 47:551-560, (2000)

Cu(II)-diacetyl-bis (N^4-methylthiosemicarbazone) (^{60}Cu-ATSM) PET - used to detect regions of tumor hypoxia

The potential of multimodality-imaging in RT

- Target definition – Biological target volume

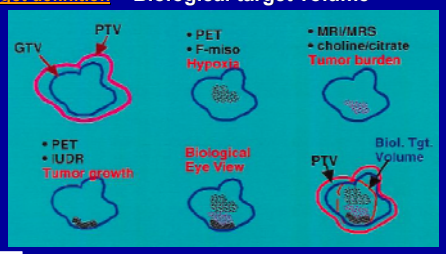

Ling *et al* IJROBP 47:551-560, (2000)

The potential of multimodality-imaging in RT

- Dose distribution
  - Treatment plans can be designed to deliver escalated doses to BTV
  - With IMRT the concept of "dose painting" can be implemented
  - The question becomes how much paint should be used

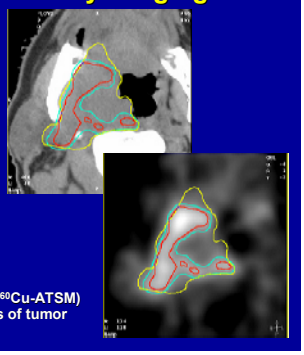

Cu(II)-diacetyl-bis (N^4-methylthiosemicarbazone) (^{60}Cu-ATSM) PET - used to detect regions of tumor hypoxia

Altered/Escalated Dose Distributions

^{60}Cu-ATSM (Hypoxia) - Guided IMRT

- 80 Gy in 35 fractions to the hypoxic tumor sub-volume as judged by Cu-ATSM PET (red)
- GTV (blue) simultaneously receives 70 Gy in 35 fractions
- Clinical target volume (yellow) receives 60 Gy
- More than half of the parotid glands (green) are spared to less than 30 Gy.

Chao *et al.* IJROBP 49:1171-1182, (2001).

^{60}Cu-ATSM-PET

Normoxic

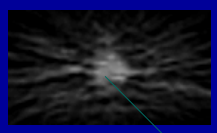

Hypoxic

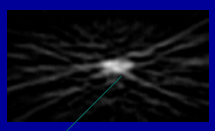

Cervical Cancer – P.W. Grigsby et al

The potential of multimodality-imaging in RT

- Treatment planning- continued
  - Tumor biology (phenotype) and therapy selection –
    - » Intermodality and intramodality changes
    - » Radiation or chemotherapy sensitivity
    - » Incorporate biological response models to maximize the therapeutic ratio
    - » Indicator for more aggressive therapy in certain patients
  - New treatment techniques
    - » Revised target volumes and desired dose distributions will require reevaluation of current treatment techniques

The potential of multimodality-imaging in RT

- Evaluation - Therapy response and follow-up
  - Tumor control
    - » Image at a molecular level
    - » Evaluate response shortly after initiation of therapy
    - » Possibly modify the planned course of therapy based on the initial response
  - Normal tissue function

FDG-PET

IIb Cx Only—Pre & Post RT

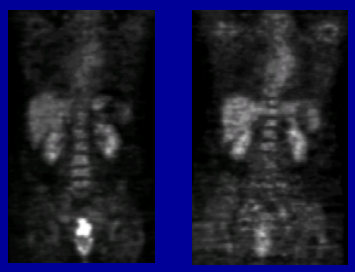

P.W. Grigsby et al

Follow-up FDG-PET

Overall Survival

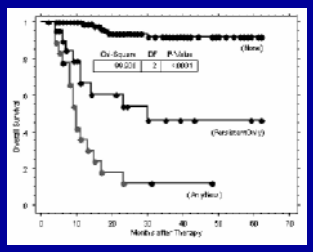

P.W. Grigsby et al

Imaging for RT
Two different concepts

- DIAGNOSTIC SCANS
  - Detection
  - Staging
  - Treatment modality selection
  - Outcome prognosis
  - Therapy evaluation and follow up
  - Scan geometry is less important
  - Fusion or image registration with other imaging modalities desirable
- TREATMENT PLANNING SCANS
  - Used for target definition
  - Guidance for dose distribution and dose escalation
  - Patient positioning, immobilization, and scan geometry are extremely important
  - Fusion and image registration capabilities are mandatory

Clinical imaging

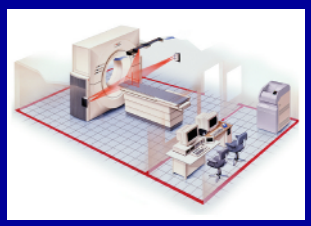

- CT
  - 70 cm single slice
  - 70 cm multi-slice – 16+ slices
  - 85 cm single slice
  - 80 cm multi-slice – 4+ slices
  - Scanned field of view (SFOV)
- PET/CT combined units
- MRI
- MR simulator

CT scanner – x-ray tube

Courtesy Philips Medical Systems, Inc.

- Large number of images per study
  - DRR quality
  - Target delineation
- Rapid study acquisition time
  - Spatial and temporal integrity
  - Motion artifacts
- Large heat anode storage ability (MHU): 5-7 MHU tubes
- Fast anode cooling rate (MHU/min)

CT scanner – Single and multi-slice scanning



Courtesy Philips Medical Systems, Inc.

- Wider collimator widths
- Post patient collimation
- Multiple area detectors
  - 1992 - Elscint CT Twin - first CT scanner capable of simultaneously acquiring more than one transaxial slice
  - 1998 – Four major manufacturers introduce scanners capable of scanning 4 slices simultaneously
  - 16+ slice scanners available

Multi-slice CT scanner benefits in RT

- Faster scan times
  - multi: 0.5 sec/rotation and 16 slices/rotation
  - single: 1 sec/rotation and 1 slice/rotation
- Lower tube heat loading
  - Longer volume covered per rotation
- Reduced slice thickness
- Improved temporal resolution - faster scan times
- Improved spatial resolution – thinner slices
- Decreased image noise – more mA available



Courtesy Philips Medical Systems, Inc.

DRR Image Quality

- Everything else being equal, thinner slices produce better images
- Balance between large amounts of data and image quality

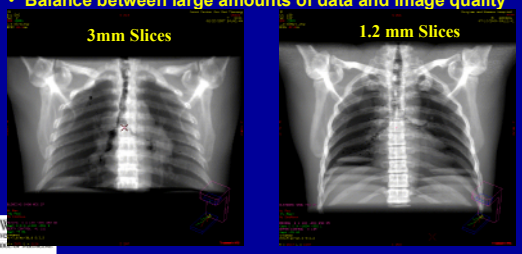

Courtesy Varian Medical Systems, Palo Alto, CA

Multi-slice scanning

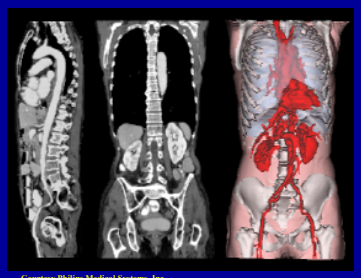

Courtesy Philips Medical Systems, Inc.

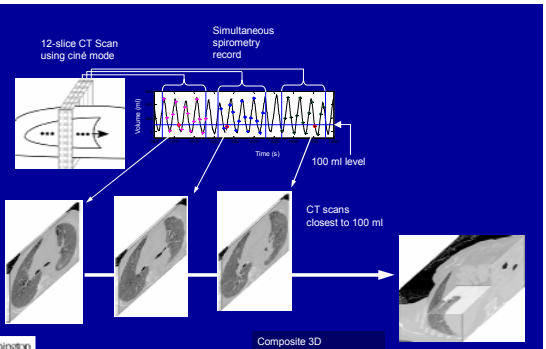

D. A. Low, *et al.*

Composite 3D
CT scan reconstructed
at 100 ml free breathing
tidal volume

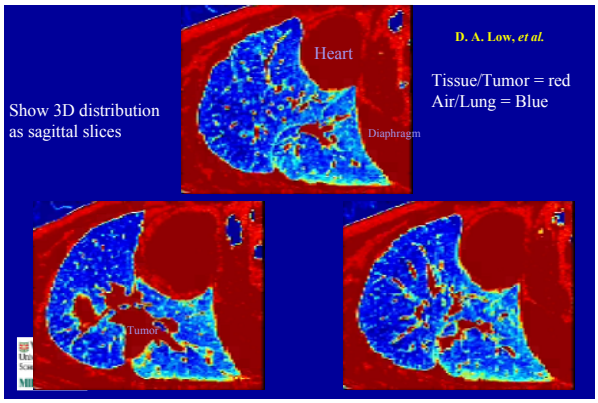

4D CT

Male Patient | Female Patient

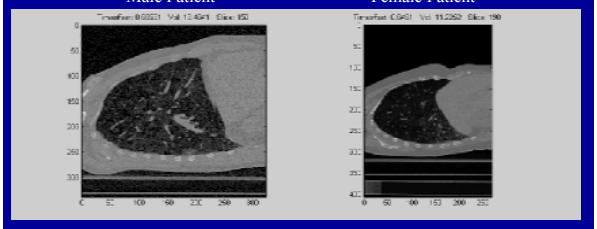

CT scanner – Bore size

85 cm Bore Opening | **70 cm Bore Opening**

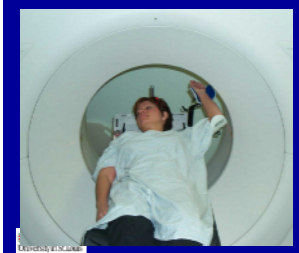

CT scanner – Bore size

Bilateral Breast

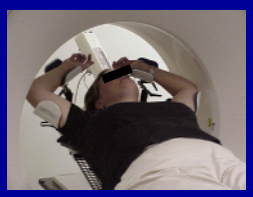

CT scanner – Bore size

Upper Thigh Sarcoma

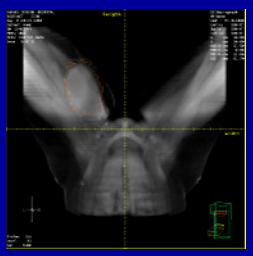

SOMATOM Sensation Open 16 Slice Scanner

GE LightSpeed_RT

- 80 cm bore size
- 4 slice scanner

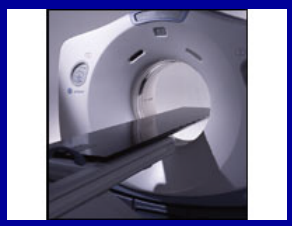

Philips AcQSim2

- 85 cm scanner
- 16 Slices

CT Scanner Selection

- Small Bore vs. Large Bore
  - Patient population
  - Conventional simulator availability
  - The question will become:
    - » How large? (80, 82, or 85 cm)
- Single Slice vs. Multi Slice
  - DRR quality
  - Image quality
  - 4D CT
  - The question will become:
    - » How many? (2, 4, 6, 10, 16, 40, … cone beam)
- Reincarnation of Sim-CT (conventional sim with CT option)

CT simulation process

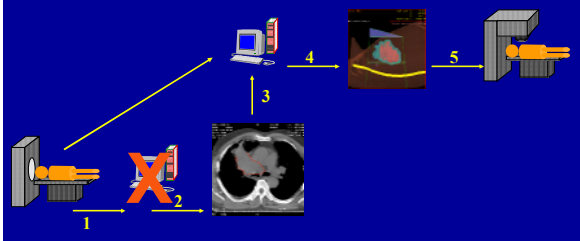

Localization on CT Console

- SIMULATION functions directly on the CT console
- Intended to mark a patient in the shortest possible time
- Segmentation and localization
  - Create structures
  - Define target volume
  - Mark isocenter
- DICOM RT Export
  - RT Structure Set
  - RT plan

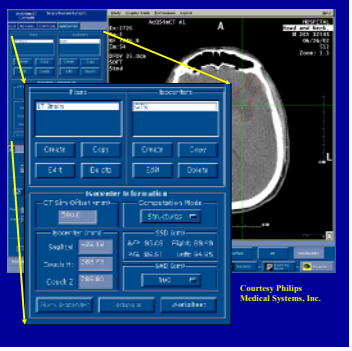

Courtesy Philips Medical Systems, Inc.

PET Imaging for RT

- Provides information about physiology rather than anatomy
  - Tumor metabolism
  - Differentiation between tumor recurrence and radiation necrosis
  - Regional lung function

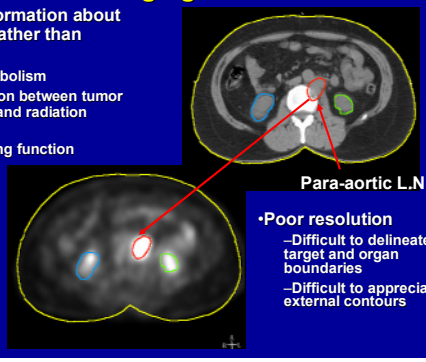

- Poor resolution
  - Difficult to delineate target and organ boundaries
  - Difficult to appreciate external contours

PET imaging for RT

- ^{18}F-fluorodeoxyglucose (^{18}F-FDG) is the primary imaging agent used for oncology imaging
  - Lung
  - Breast
  - Colorectal
  - Melanoma
  - Head and neck
  - Pancreas
  - Brain
  - Thyroid
  - Sarcoma
  - GYN
  - Lymphoma
- Other imaging agents can provide unique information
  - Slow growing tumors
  - Hypoxic regions

PET imaging for RT

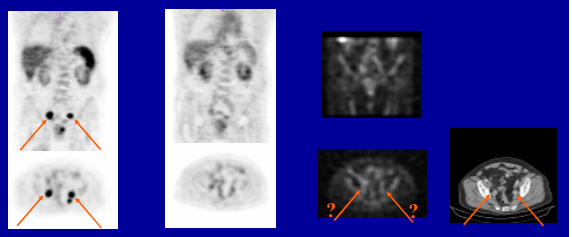

C-11 acetate | F-18 FDG | Prostascint | CT

Oyama *et al.* J Nuc Med 44, 549-555, 2003

RT Treatment Planning with PET

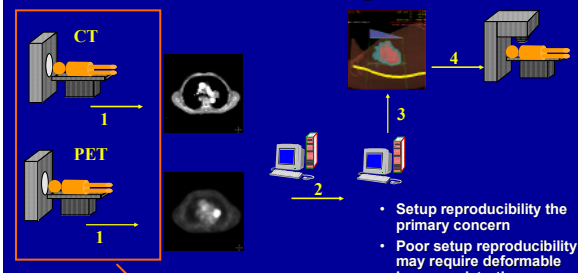

These can be separate units or a combined CT/PET machine

- Setup reproducibility the primary concern
- Poor setup reproducibility may require deformable image registration

Fusion/Image Registration

- Lack of anatomical definition makes a registration with CT image a necessity
- Due to the same lack of anatomical definition, CT and PET study registration is somewhat challenging
- Combined PET/CT scanners can simplify the process

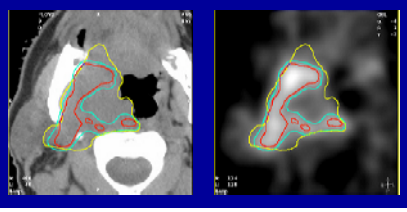

Multimodality Image Registration

- Registration Techniques:
  - Software Registration
  - Hardware Registration

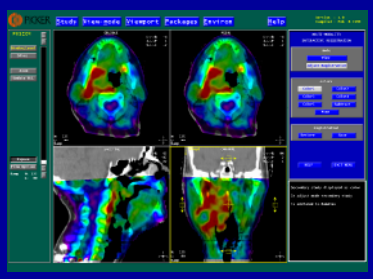

Fiducial Markers

- 0.5 cm diameter, 3.5 cm long, 0.25 ml, plastic, disposable microcentrifuge tubes
- VWRbrand Disposable Microcentrifuge Tubes, VWR Scientific Products, West Chester, PA
- CT, MR, and PET compatible
  - CT - Aluminum
  - MR - 4 mM $CuNO_3$
  - PET - ^{18}F-deoxyglucose

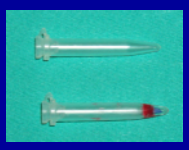

Fiducial Markers

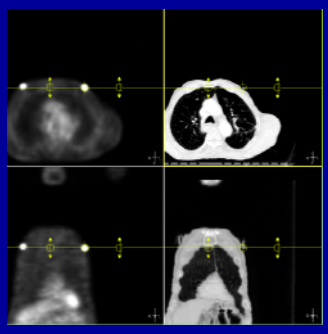

Patient positioning and immobilization
Registration Device

- Gantry opening on stand-alone PET scanners is small (~55 to 60 cm)
- Scan times are relatively long
  - Emission scan
  - Transmission scan

PET/CT scanner combined unit

- Multislice CT scanner mated to a PET scanner
  - Faster scan times
  - Improved image data quality
  - Images registered in hardware
- Three scans acquired during procedure
  - Attenuation correction CT
  - PET
  - Treatment planning CT, with contrast if necessary

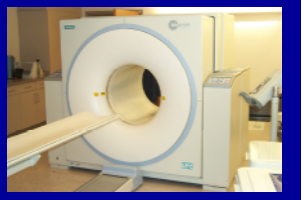

Bore Size is not the same for CT and PET on all scanners

PET/CT scanner combined unit
Patient Motion

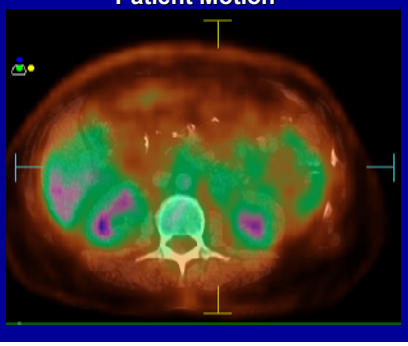

Patient Motion



Staging with PET for RT

- Locoregional disease progression or symptomatic distant metastasis soon after therapy are indicators that the true extent of the disease was not appreciated
- Conventional staging commonly underestimates the true extent of NSCLC, for example
- Tumor stage is often the strongest prognostic factor and the most important parameter that guides treatment decision making
- PET imaging has been shown to be superior to conventional imaging in staging of several tumors (NSCLC, GYN, colorectal, etc.)
- Accurate staging will help render treatment appropriate for that stage
- Differentiate between tumor and other abnormalities (e.g. atelectasis)

Detection and Staging with PET
NSCLC EXAMPLE

- Mac Manus MP, et al. *Cancer, 92:886-895, 2001*
  - Prospective, n=153, unresectable NSCLC
  - "before PET" and "after PET" staging
  - subsequent management and survival recorded
  - "after PET" stage strongly assoc w/ survival (p=.0041) 2 yr
  - detected unsuspected metastases in 20% - upstaged
  - downstaged 5 pts. - went on to potential curative Sx
  - 22/102 (RT) pts. significant increase in target volume
  - 16/102 (RT) pts. significant reduction in target volume

Detection and Staging with PET
NSCLC EXAMPLE

- Mah K, et al. *IJROBP, '02*
  - Prospective, n=30, unresectable NSCLC
  - Multiple observers used for target volume delineation
  - detected unsuspected metastases in 7 of 30 (22%) patients - upstaged
  - 30-76% pts. increase in target volume
  - 24-70% pts. reduction in target volume

Staging and Patient Management with PET
OVERALL IMPACT

- Dizendorf *et al.* J Nuc Med 44:24-29, 2003

Diagnosis	Patients (n)	Patients with therapy changes	
		n	%
Head and Neck Tumor	55	18	33
GYN Tumor	28	9	32
Breast Cancer	28	7	25
Lung Cancer	26	8	31
Malignant lymphoma	24	5	21
Gastrointestinal tract tumor	18	4	22
Unknown primary tumor	4	3	75
Malignant Melanoma	2	1	50
Other tumors	17	0	0
Total	202	55	27

Changes in management of radiation therapy relating to volumes, dose, or intent

Staging with PET for RT
IMPACT AND ITS VALIDATION

- Hicks and Mac Manus, J Nuc Med 44:30-32, 2003
  - » False positive PET findings may deny patients potentially curative treatment
  - » Histopathological validation of PET findings for RT patients
  - » Impact on the outcomes
  - » Impact on the quality of life

RT Treatment Planning with PET
TARGET DEFINITION

- Depending on image window and level setting, target volume can easily change by 50%

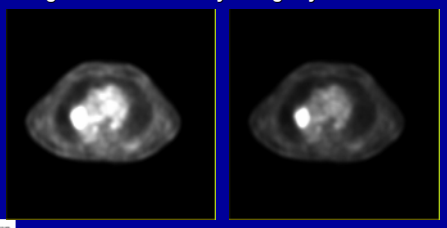

•SUV data is not part of DICOM

RT Treatment Planning with PET
TARGET DEFINITION

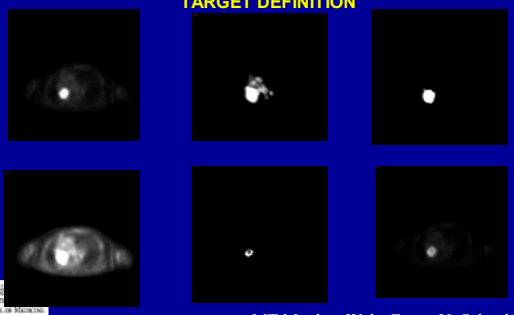

MT Munley, Wake Forest U. School Med.

RT Treatment Planning with PET
TARGET DEFINITION

- Setting the PET image parameters so the tumor volume corresponds to CT image
- Erdi *et al. Cancer 1997*
  - Segmentation by CT-guided adaptive thresholding method
  - Phantom data used for determination of fixed threshold value for sphere volumes larger than 4 mL (from 36% to 44%)
  - CT used for estimation of lesion size and PET for estimation of signal to background ratio
  - 10 patients with 17 metastatic lung lesions
  - PET volumes compared with CT volumes
  - PET provides accurate volume estimations for lesions larger than 4 mL with a single threshold

RT Treatment Planning with PET
TARGET DEFINITON

- Respiratory Gating - Nehmeh *et al.* Med Phys 29:366-371, 2002
  - Respiratory motion during PET imaging degrades image quality and affects quantitative PET information
  - Motion reduces ability to detect small lesions
  - Reduction in measured standard uptake values (SUV)
  - Target volumes overestimated
  - PET images acquired in synchronization with the respiratory motion
  - Acquired images resulted in reduction of target volumes and increase of SUV

RT Treatment Planning with PET
TARGET DEFINITON

- Caldwell *et al.* IJROBP 55:1381-1393, 2003
  - Internal target volume (ITV) definition based on motion during PET imaging
  - Effect on definition of planning target volumes (PTVs)
  - Phantom study
  - Comparison of CT-based PTVs, PET –based PTVs, and ideal (calculated) PTVs
  - Fast CT-imaging of a moving target results in distorted target volumes
  - PET can provide a more accurate definition of time averaged position of target volumes

Altered/Escalated Dose Distributions
PET Guided GYN Brachytherapy Implants

- Mutic *et al.* IJROBP 52: 1104-1110, (2002).
- PET images may allow more accurate delineation of three-dimensional treatment planning (3DTP) target volumes of brachytherapy gynecologic (GYN) implants
- This study evaluated the feasibility of using PET images as the sole source of target and normal structure geometries for intracavitary brachytherapy GYN implant treatment planning using a commercial treatment planning system

Mutic *et al.* IJROBP 52: 1104-1110, (2002).

Altered/Escalated Dose Distributions
PET Guided GYN Brachytherapy Implants

- Tandem and colpostat applicator inserted in the OR
  - Applicator design and mode of delivery (HDR or LDR) not important
- Foley catheter placed in the urinary bladder
- Patient taken to the PET scanner where 555 MBq (15 mCi) ^{18}F-FDG (^{18}F-fluorodeoxyglucose) is intravenously administered
- Three small tubes containing ^{18}F-FDG inserted into the applicator
- Whole pelvis scan obtained and images transferred to the treatment planning system (FOCUS, CMS, St. Louis, MO)
- 3D treatment plan created with target and normal structure DVHs

Anatomy
PET Guided GYN Brachytherapy Implants

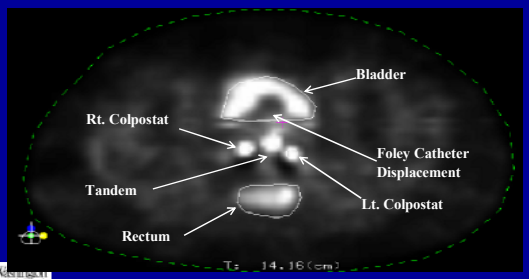

Treatment planning

PET Guided GYN Brachytherapy Implants

- Applicators, critical structures and tumor contoured
- Software places sources at predefined positions with respect to applicator tips
- Source strengths and treatments times optimized
- Alternatively, deliver conventional dose distributions

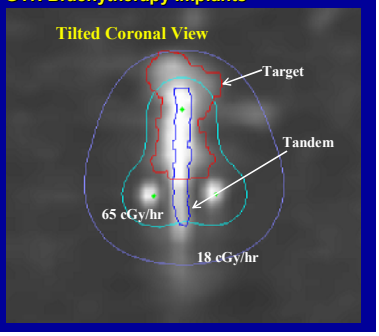

Conventional Dose Distributions

PET Guided GYN Brachytherapy Implants

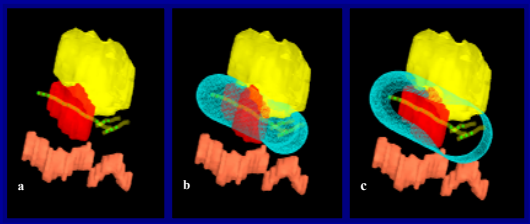

Optimized Dose Distributions
PET Guided GYN Brachytherapy Implants

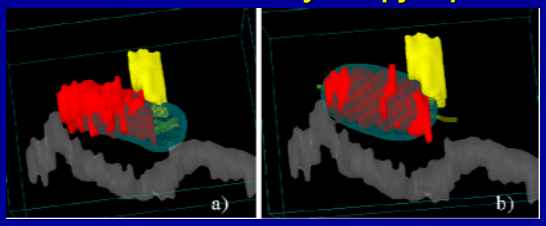

- Same Integrated Reference Air Kerma (IRAK) strength used for both plans
- Dwell positions rearranged to conform dose distribution

FDG-PET Guided IMRT
Dose escalation to PALN

Mutic *et al, Int J Radiat Oncol Biol Phys* 55:1 28-35 (2003)

- Rationale
  - The survival of cervical cancer patients with para-aortic lymph node (PALN) metastasis is poor
  - Results of RTOG-7920 suggest 45 Gy para-aortic lymph node irradiation (PALNI) is associated with better survival - *Rotman et al JAMA 274:387-393 (1995)*
  - PALN dose is limited by bladder, rectum, colon, kidney, small intestine, and spinal cord radiation tolerances
- Objective
  - Dose escalation to PALN while maintaining or even reducing dose to the surrounding critical organs using IMRT
  - Use of PET to delineate target volume

Conventional Treatment Technique For Pelvic And Para-Aortic irradiation

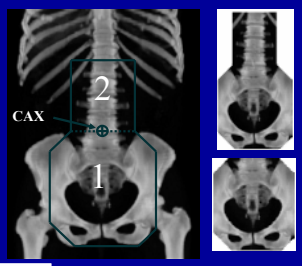

- Volumes 1 & 2 treated in one field AP/PA to 45 Gy
- Volume 1 then treated to additional 5.4 Gy and intracavitary boost

IMRT Treatment Technique For Pelvic And Para-Aortic irradiation

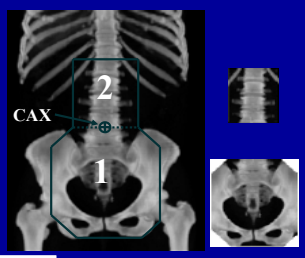

- Volume 2 treated with IMRT
  - Positive PALN as identified by PET treated to 60 Gy
  - PALN Bed treated to 50.4 Gy
- Volume 1 treated using conventional techniques

FDG-PET Guided IMRT Process

- PET and CT scans are acquired in treatment position with PET/CT scanner
- Positive PALN are identified on PET and contours are related to CT

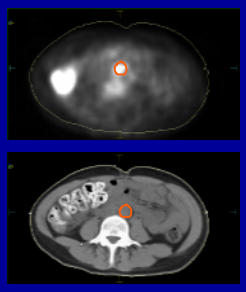

Dose Distribution

First protocol patient - treated 11-3-2003

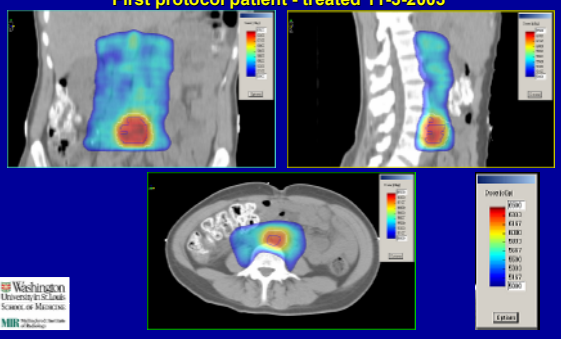

Conclusions

- Biological imaging offers possibilities to individualize patient treatments
- CT will remain the primary imaging modality
- The current practice of radiation therapy will be changed due to biological information
  - Reevaluation of the past clinical trials
  - Development of new techniques