Image Fusion in Nuclear Medicine PET/CT

AAPM 2001
Continuing Education

James A. Patton, Ph.D.
Vanderbilt University Medical Center
Nashville, Tennessee

VUMC

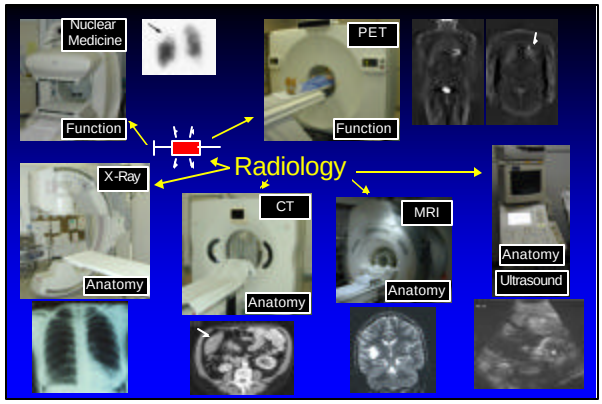

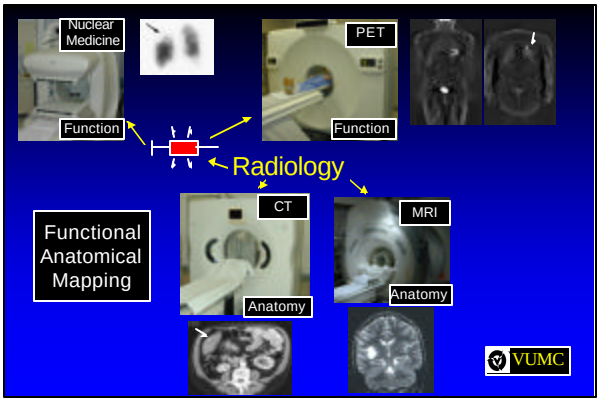

VUMC

Functional Imaging with Radiopharmaceuticals

- Conventional Nuclear Medicine
  - Bone Scans
  - Lung Scans
  - Cardiac Evaluations
  - Tumor and Infection Imaging
- Positron Emission Tomography (PET)
  - Brain Metabolism
  - Cardiac Metabolism and Ischemia
  - Tumor Metabolism

VUMC

Fluorodeoxyglucose (FDG)

- A very special radiopharmaceutical
- Labeled with F-18
  - Positron Emitter (511 keV photons)
- Glucose analog
  - Excellent metabolic imaging agent

VUMC

HCFA Approval for ^{18}FDG

- 1998
  - Solitary pulmonary nodules
  - Staging of non-small cell lung cancer
- 1999
  - Recurrent colorectal cancer
  - Lymphoma
  - Metastatic melanoma
- 2000
  - Non-small cell lung cancer
  - Colorectal cancer
  - Lymphoma
  - Melanoma
  - Head and neck cancer
  - Esophageal cancer
  - Epilepsy
  - Myocardial viability
  - (Therapy monitoring excluded)

VUMC

Annihilation Radiation

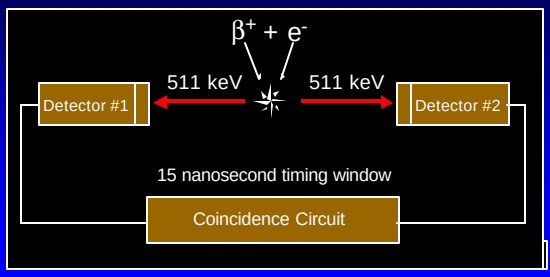

PET Scanner

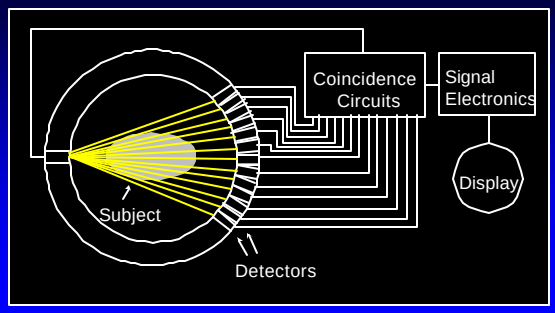

PET Scanner

- 18 rings of detectors
- 35 imaging planes
- 15 cm axial field-of-view



Dedicated PET Scanner

VUMC

Brain Tumor

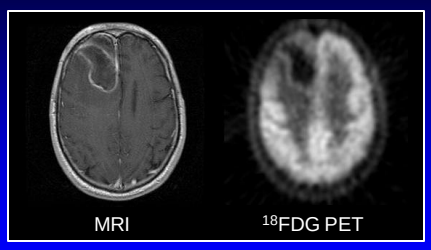

VUMC

PET scans are acquired as a series of transverse slices with a spatial resolution of approximately 5 mm.
Each slice is 7 -8 mm thick.



VUMC

Whole Body FDG PET No Attenuation Correction

Images are created by acquiring data from multiple bed positions.

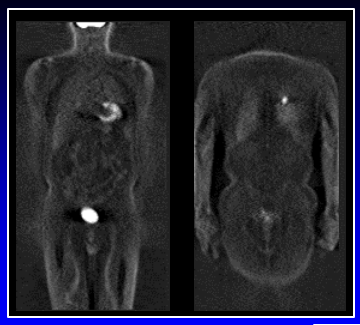

VUMC



VUMC

Attenuation Correction

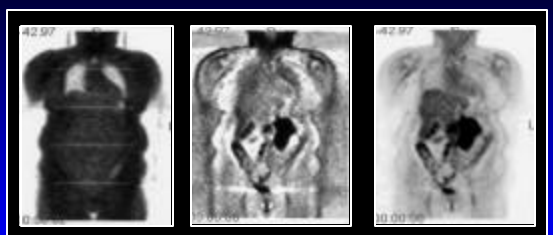

Transmission Scan | Emission Scan w/o AC | Emission Scan with AC

VUMC

Problems with Dedicated PET Scanners

- Expensive to purchase
- Expensive to service
- Can only perform PET procedures
- Reimbursement has been a problem (but is now improving)

VUMC

Hybrid Cameras

- Multi -Head Scintillation Camera
  - Routine nuclear medicine procedures
  - Collimated high energy imaging
  - Coincidence imaging (PET)

VUMC

Dual-Head Scintillation Camera

VUMC

Coincidence Counting with a Dual-Head Scintillation Camera

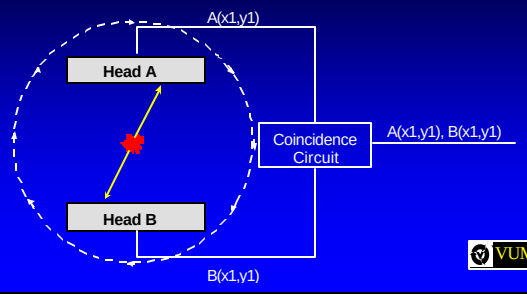

VUMC

Metastatic Lung Cancer

Without Attenuation Correction

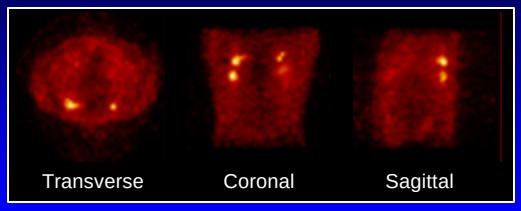

VUMC

Attenuation Correction

- Generally performed with a transmission scan obtained using a radioactive source as in PET scanning.

VUMC

Dilemma in Nuclear Medicine

- Referring physicians ask "You have identified an area of increased uptake. Where is the abnormality located?"
- Nuclear medicine images must then be compared with images from CT or MRI.
  - Physiology - domain of nuclear medicine
  - Anatomy - domain of CT and MRI

VUMC

Image Fusion

↓

Molecular Function + Anatomical Detail
(Nuclear Medicine) (CT or MRI)

↓

Functional and Anatomical Imaging

VUMC

Overlay Images for Comparison

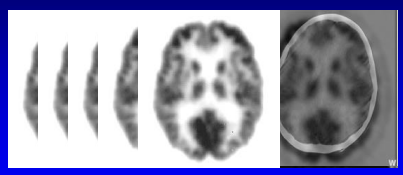

VUMC

Traditional Methods

- Software Registration/Fusion
  - Rigid Body Transformations
    - Head
  - Non-rigid Body Transformations
    - Body

VUMC

Traditional Methods

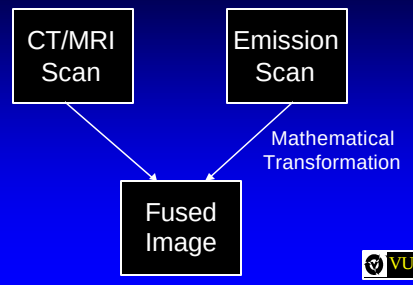

VUMC

Rigid Body Transformations
PET → MRI

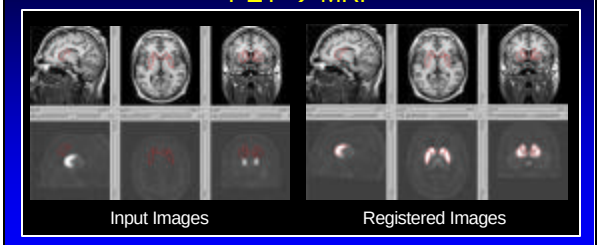

Benoit Dawant, Ph.D., Vanderbilt University

VUMC

Stereotactic Head Frame

VUMC

Problems

- Images are acquired:
  - With different modalities
  - With different spatial resolutions
  - At different times
  - With patient in different positions
  - With different pixel sizes
  - With different array sizes
- And organs move
  - Cardiac/Respiratory/GI

VUMC

GE Millennium with "Hawkeye"

CT Acquisition
10 mm slice
13.6 sec/slice
40 slices

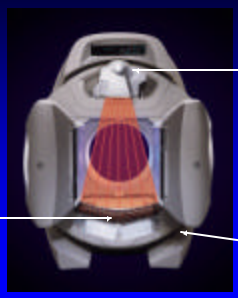

X-Ray Tube
140 kVp max.
2.5 mA max.

Linear Array of Detectors

Slip ring gantry

VUMC

Transmission Maps for Attenuation Correction and Image Fusion

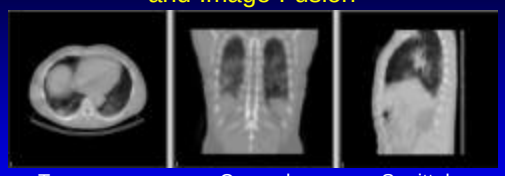

Transverse Coronal Sagittal

Attenuation maps are displayed in Hounsfield Units and measured attenuation coefficients are scaled to 511 keV for attenuation correction.

VUMC

Functional Anatomical Mapping

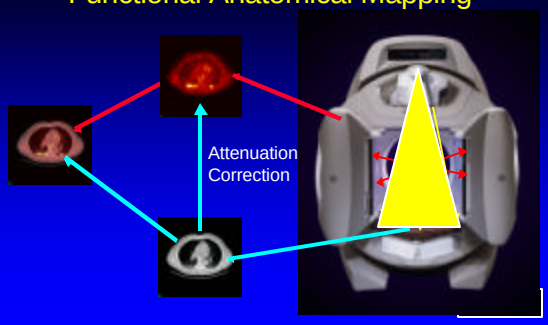

Testicular Cancer

Elevated tumor markers

^{18}FDG

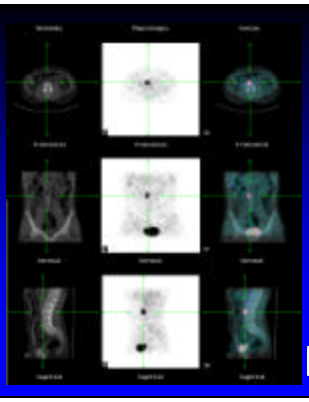

VUMC

Metastatic Liver Cancer

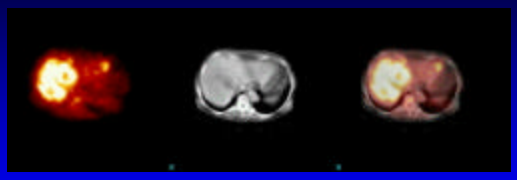

Emission Transmission Fusion

VUMC

SPECT of Chest with ^{99m}Tc Sestamibi in Patient with Parathyroid Adenoma

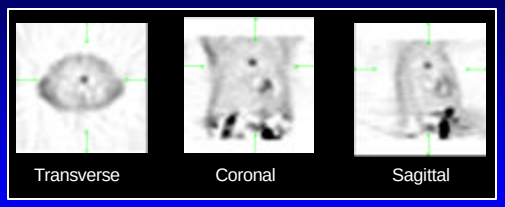

Transverse Coronal Sagittal

VUMC

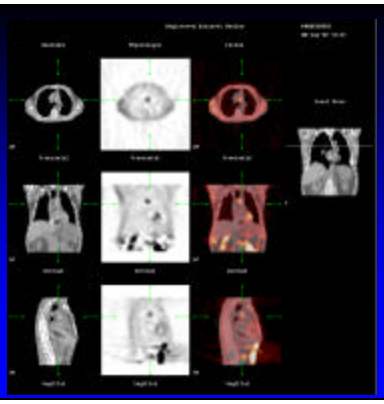

VUMC

Results

- In a limited series of patients, image fusion provided added clinical value in 35% of the studies.

VUMC

Hybrid Camera/CT

- Advantages
  - Relatively low cost
  - Multiple functions
- Disadvantages
  - Lesion detectibility problems for lesions < 1.5 cm
  - CT images are not diagnostic CT quality

VUMC

PET

CT

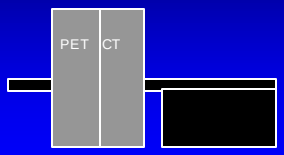

Integrated System
David Townsend, Ph.D., University of Pittsburgh

VUMC

Breast Cancer

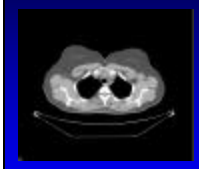

CT

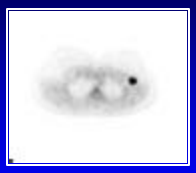

PET

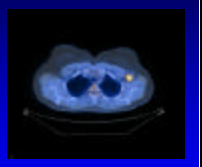

Fused Image

VUMC

PET/CT

PET Scanner

+

Multi-Slice
CT Scanner

=

PET/CT
Scanner

VUMC

Lung Cancer

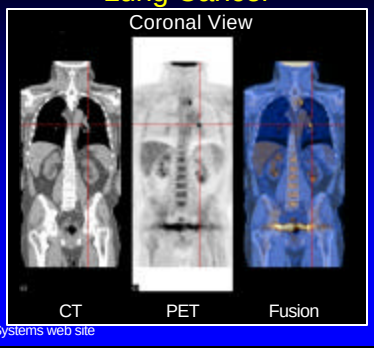

GE Medical Systems web site

VUMC

PET/CT

- Advantages
  - Improved lesion detectibility
  - High quality anatomical information
  - Increased speed → Improved throughput
  - High quality fusion images
- Disadvantage
  - Cost

VUMC

Image Fusion Applications

- Radiation therapy treatment planning
  - Conformal Therapy uses multi-leaf collimators to shape the radiation beam
  - Intensity Modulated Radiation Therapy (IMRT) permits the altering of the intensity of the radiation beam
- Use fused images as input for therapy treatment planning
  - to increase accuracy of radiation field mapping for therapy
  - Evaluate response to therapy

VUMC

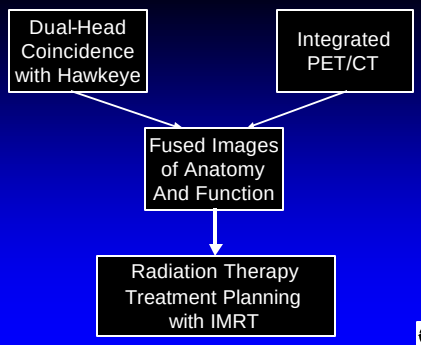

VUMC

Advantage of Nuclear Medicine



Nuclear medicine provides information on regional biological activity that anatomical images alone cannot provide. This is useful for treatment planning and monitoring therapeutic response.

VUMC

Plan Variation

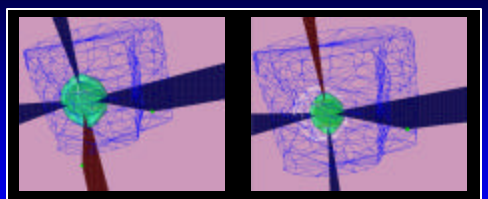

CT Isocenter | Nuclear Medicine Isocenter

VUMC

^{18}FDG Lung Cancer

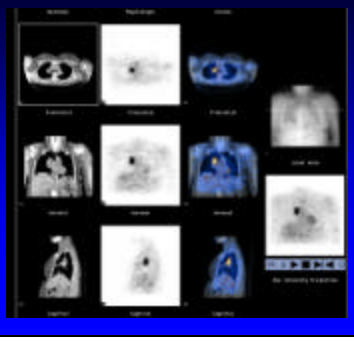

VUMC

^{18}FDG Lung Cancer
Coronal View

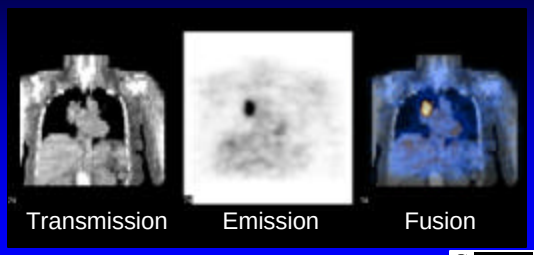

VUMC

^{18}FDG Lung Cancer
Sagittal View



VUMC

Tumor at Base of Tongue

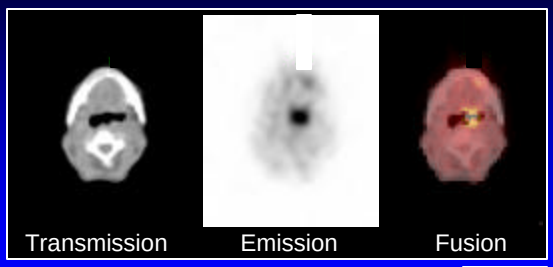

VUMC

Varian See and Treat™ Cancer Care
Data input from GE VG with Hawkeye

Hawkeye CT

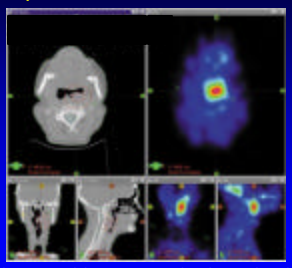

VG Coincidence ^{18}FDG

Varian SomaVision treatment planning workstation

VUMC

Varian Helios IMRT Treatment Plan
Using co-registered VG Coincidence and Hawkeye CT data sets



VUMC

Acceptance Testing and Q.A.

- Perform routine CT procedures
- Perform routine PET/Camera procedures
- Verify accuracy of registration
  - Phantom measurements
  - Remember data are three dimensional
  - Watch for flexing of imaging table

VUMC

Conclusions

- Image fusion appears to be a valuable tool to:
- Precisely locate and identify lesions
- Refine radiation therapy treatment plans
- Follow course/effects of therapy

VUMC