Patient Setup Uncertainties (inter-fraction)

Emilie Soisson, PhD

McGill University Health Centre

AAPM Summer School 2011

Centre universitaire de santé McGill
McGill University Health Centre

Inter-fraction Setup Uncertainty

- Unknown/undetected differences between a patient's position and location at treatment compared to that at treatment simulation
- Difference between fractions, does not include motion within the fraction
- Large setup uncertainties can result in a geographic miss that can compromise tumor control

Time Frames to Consider

Daily Variation

Differences in patient setup
Daily anatomical variation

Simulation to Treatment

Swelling
Disease progression

Gradual Changes Throughout Treatment

Weight loss/gain
Tumor shrinkage/diseases progression

Setup Uncertainty-Interfraction

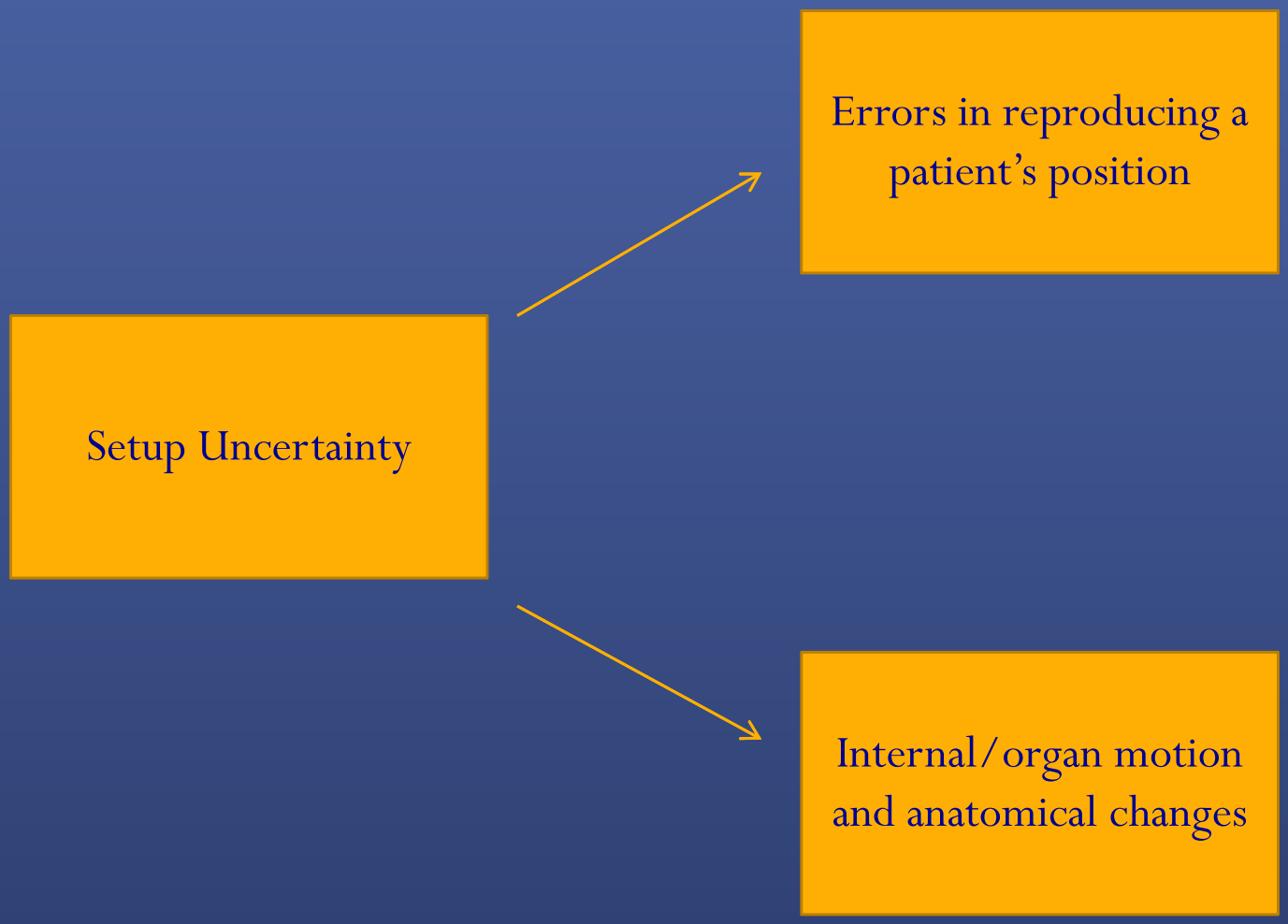

Mitigation Strategies

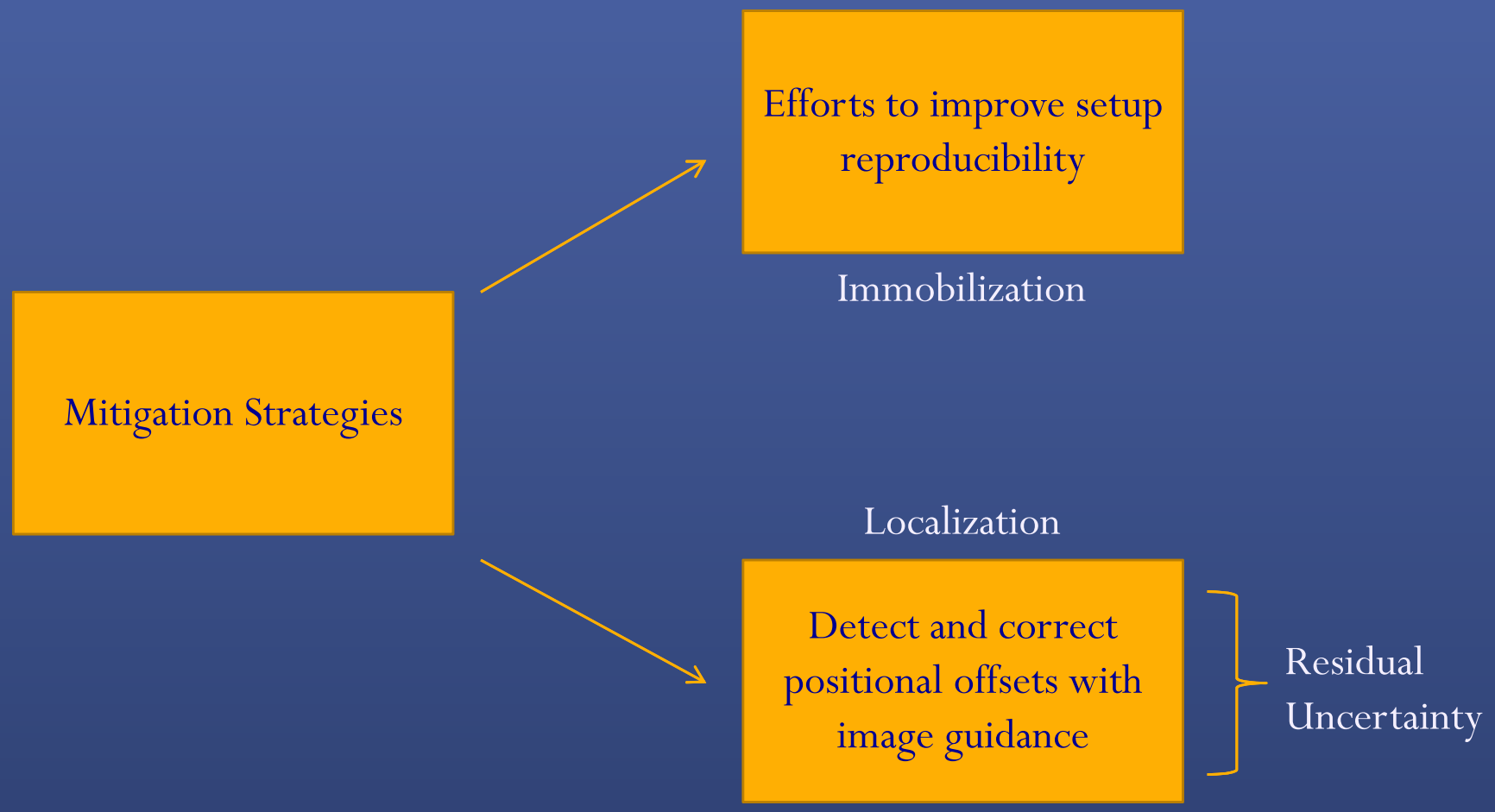

Jatinder's Table

Cause of Uncertainty	Magnitude of Uncertainty	Mitigation Strategy	Magnitude of Uncertainty After Implementing Mitigation Strategy
Lots	?	Lots	?

Magnitude of Setup Uncertainty?

- Patient specific
- Site specific
- Institution specific
  - Immobilization devices
  - Therapist training
  - Simulation techniques
  - Imaging devices
- Changes with medical practices (chemotherapy, nutritional intervention)
- Varies in importance with selected margins and treatment techniques

How to fill out the table?

- Give up and spend the first week of August at my cottage instead
- Extensive literature search
  - Many studies and approaches
  - Results may or may not apply to you
  - Attempted in the chapter (85 references)
- Collect all my data and talk about my setup errors at McGill
  - You do not work at McGill
- Suggest an approach to determine where these uncertainties might exist and how to reduce them

Main Points for Today

- Patient setup is a process that involves many steps
- As a physicist, you may be able to mitigate uncertainty by getting more involved
- Go to the clinic and observe, be proactive
- Get involved in training and policy making
- Review images
  - Know how to produce the best images with your imaging devices
  - Know when you can see and when you can't see
- Determine your setup accuracy internally and evaluate the effect of changes

Patient Setup

Reduce Uncertainties Associated with Setting up to Lasers

- Routine QA and calibration (systematic error that can easily be avoided!)
- Install good laser systems
- Document shifts from planning
  - QA documentation
  - Mark shifts appropriately

Improving Simulation Technique

- Policies, procedures and checklists
- Set up training/refreshers– Ensure proper training for everybody, avoid hand offs
- Ensure compliance manufacturers instructions for IDs
- Standardized marking procedures
- Take time to ensure the patient is straight, relaxed and comfortable
- Purchase adequate IDs (type and number) and know where they are and who it belongs to (RFID)
- Ensure consistent/complete/available documentation

Improving Documentation

- Electronic charting
- Documentation protocols
  - Determine what should be documented
  - Create forms
  - Include enough details to avoid losing information at handoff
  - Standard language
- Chart QA to check for completeness
- Include pictures

TREATMENT SITE	LARYNX	NUMBER OF SCANS	1

CT SIMULATOR SETUP

PATIENT POSITION

☒SUPINE
☐PRONE
☒HEAD FIRST
☐FEET FIRST
☐ARMS UP
☒ARMS BY SIDE
☐ARMS AKIMBO
☐HANDS ON CHEST
☐HANDS ON ABDO
☐HANDS ON SHOULDERS

☐LEGS FROG
☒KNEE/ANKLE SPONGE
HEEL SPACER 12☐ 18☐ 22☐
☐DENTURES OUT

REFERENCE LANDMARKS

TABLE TO CT MARKER CM

2 TATTOO ON CHEST
ANT TATTOO IS 7.0 CM INF OF XYPHOID AND SECOND ANT TATTOO IS 14 CM SUP OF XYPHOID

PATIENT PARAMETERS – SIMULATOR ONLY

DEPTH @ ISOCENTER CM

OTHER INFORMATION

CONTRAST AGENT
☐OMNIPAQUE 300
☐GASTROGRAFIN
☐ESOPHO-CAT PASTE
☐IV
☐URETHROGRAM
☐ORAL
QUANTITY/GIVEN BY

GATING SCANS
☐FREE BREATHE
STUDY#
☐4DCT
☐BELLOWS
☐RPM

SPECIAL ACCESSORIES

☐MEDTEC BREAST BOARD
☐VACLOC ☐BODYFIX
☒U-FRAME
☒ INCLINE ORFIT, ANGLE5
☐HEAD ORFIT
☐ HEAD + SHOULDER ORFIT
☐BLUE MATRESS
☐FACE REST
SUP HT cm INF HT cm
☐BRAINLAB MASK
☐FRAMELESS STEREO HEAD MASK
☐FRAMELESS STEREO ENT MASK
SPACER MM

☐WING BOARD DIST HT

HEADREST

☐A ☐B ☐C ☐D ☐E ☒F☐G ☐CUSTOM

☐REVERSED ☐ +2CM STYROFOAM

SPECIAL SETUP FORM

☐MEDTEC
☐BODY FIX
☐CONTRAST
☐BRAINLAB
☐MRI

NUMBER OF CT SLICES 131	ACQSIM STUDY #13452	REFERENCE MARKER Z	-48.60

SETUP PICTURE OR NOTES ☐SEE DIGITAL PHOTO ☐ PROSTATE ULTRASOUND

AL PRESENT AT SET UP CALL ALEKSANDRA ON ISO SHIFT DAY
POSITION APPROVED BY DR :

Encourage pictures and make them available at treatment

Training Examples

- BodyFix
  - Even distribution of vacuum
  - No holes
  - No excess clothing
  - Proper placement of cushions
- Masks
  - Water bath appropriate temperature
  - Allow adequate time for cooling (opaque)
  - Define nose and chin well
  - Lots of hands in molding
  - Consider claustrophobia, cut eyes if necessary to relax patient

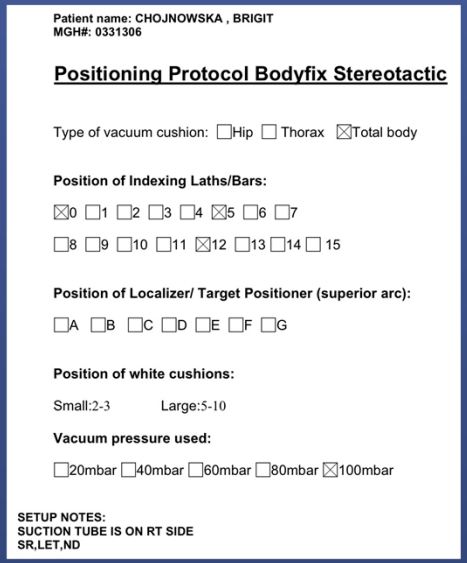

Patient name: CHOJNOWSKA , BRIGIT
MGH#: 0331306

Positioning Protocol Bodyfix Stereotactic

Type of vacuum cushion: ☐Hip ☐ Thorax ☒Total body

Position of Indexing Laths/Bars:

☒0 ☐1 ☐2 ☐3 ☐4 ☒5 ☐6 ☐7

☐8 ☐9 ☐10 ☐11 ☒12 ☐13 ☐14 ☐ 15

Position of Localizer/ Target Positioner (superior arc):

☐A ☐B ☐C ☐D ☐E ☐F ☐G

Position of white cushions:

Small:2-3 Large:5-10

Vacuum pressure used:

☐20mbar ☐40mbar ☐60mbar ☐80mbar ☒100mbar

SETUP NOTES:
SUCTION TUBE IS ON RT SIDE
SR,LET,ND

Brain and Ocular

- Minimize movement with respect to mask
  - Head and shoulder mask
  - Bite block
  - Reinforcements
  - Custom head rest
- Reduce voluntary eye movement
  - Suction contact lens
  - Visulization of a light

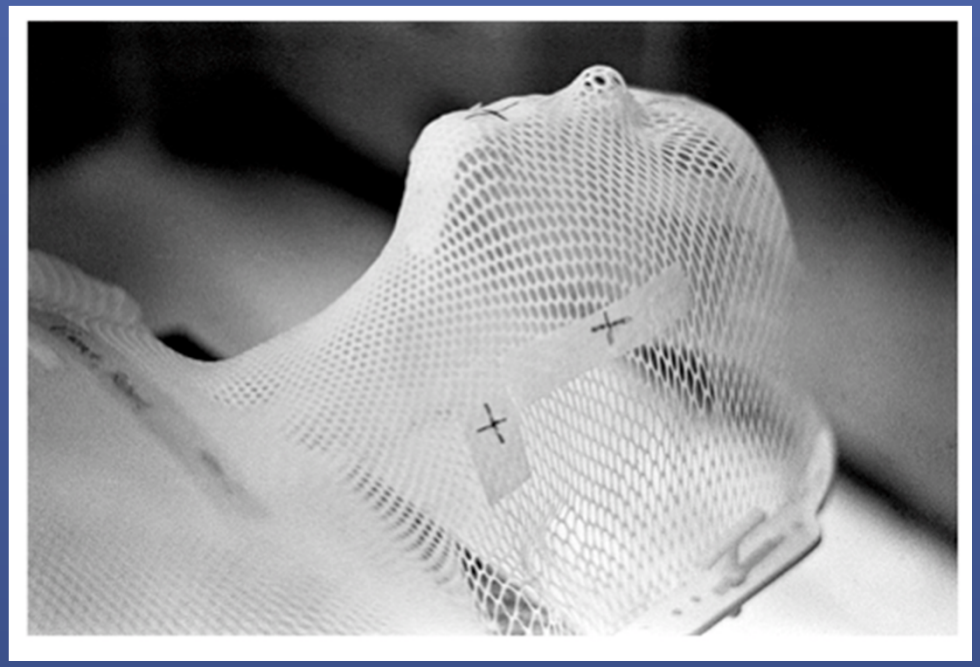

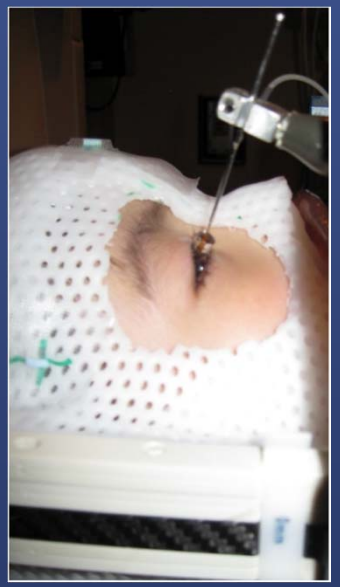

Head and Neck

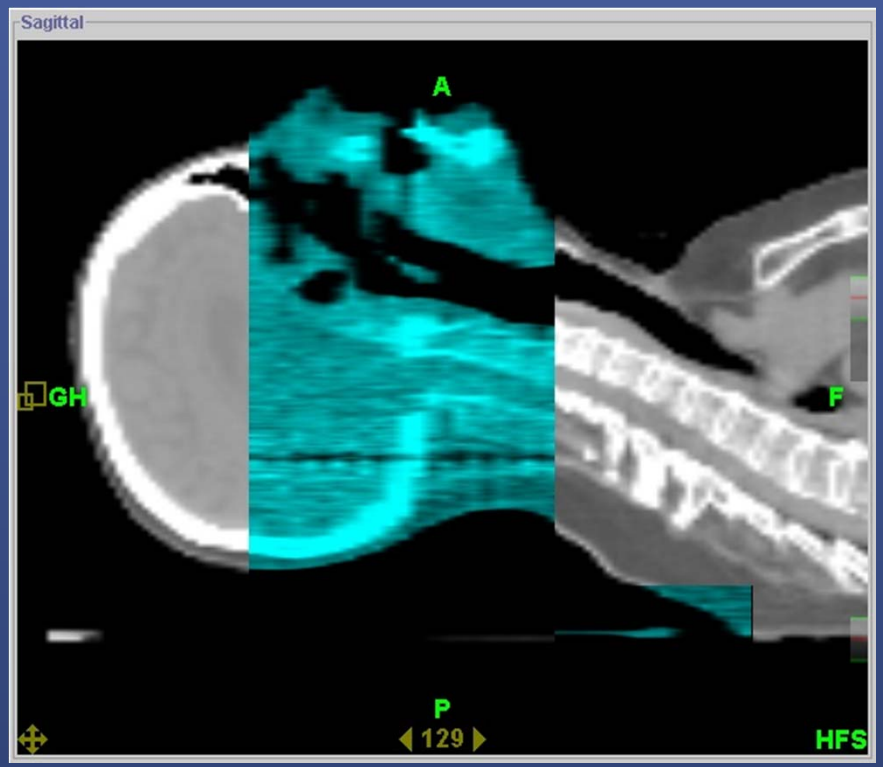

- Improve mask making
  - Custom head rest
  - Add shoulders
  - Indexing
- Manage weight loss
  - Dietary intervention
  - Evaluate and replan

Ok but with image guidance as long as we immobilize the target, shouldn’t we should be able to mitigate these uncertainties through image guidance?

Image Guidance

Uncertainty Associated with Image Guidance

Imaging System and Image Quality

- Misalignment of imaging and machine isos
- Poor resolution
- Poor image quality
- Artifacts
- System position accuracy

Image fusion

- DRR image quality
- Differences in modality
- Poor manual fusion technique
- Incorrect autofusion
- Poor soft tissue contrast
- Improper surrogate
- Migration of surrogate
- Artifacts
- Movement between images
- Incorrect reference image
- Incorrect planning image
- Anatomical deformation between images
- Software bugs

Follow AAPM Guidelines TG142

TABLE VI. Imaging.

Procedure	Application-type tolerance: non-SRS/SBRT	Application-type tolerance: SRS/SBRT
Daily[a]		
Planar kV and MV (EPID) imaging		
Collision interlocks	Functional	Functional
Positioning/repositioning	≤2 mm	≤1 mm
Imaging and treatment coordinate coincidence (single gantry angle)	≤2 mm	≤1 mm
Cone-beam CT (kV and MV)		
Collision interlocks	Functional	Functional
Imaging and treatment coordinate coincidence	≤2 mm	≤1 mm
Positioning/repositioning	≤1 mm	≤1 mm
Monthly		
Planar MV imaging (EPID)		
Imaging and treatment coordinate coincidence (four cardinal angles)	≤2 mm	≤1 mm
Scaling[b]	≤2 mm	≤2 mm
Spatial resolution	Baseline[c]	Baseline
Contrast	Baseline	Baseline
Uniformity and noise	Baseline	Baseline
Planar kV imaging[d]		
Imaging and treatment coordinate coincidence (four cardinal angles)	≤2 mm	≤1 mm
Scaling	≤2 mm	≤1 mm
Spatial resolution	Baseline	Baseline
Contrast	Baseline	Baseline
Uniformity and noise	Baseline	Baseline
Cone-beam CT (kV and MV)		
Geometric distortion	≤2 mm	≤1 mm
Spatial resolution	Baseline	Baseline
Contrast	Baseline	Baseline
HU constancy	Baseline	Baseline
Uniformity and noise	Baseline	Baseline
Annual (A)		
Planar MV imaging (EPID)		
Full range of travel SDD	±5 mm	±5 mm
Imaging dose[e]	Baseline	Baseline
Planar kV imaging		
Beam quality/energy	Baseline	Baseline
Imaging dose	Baseline	Baseline
Cone-beam CT (kV and MV)		
Imaging dose	Baseline	Baseline

Imaging and Treatment Coordinate Coincidence



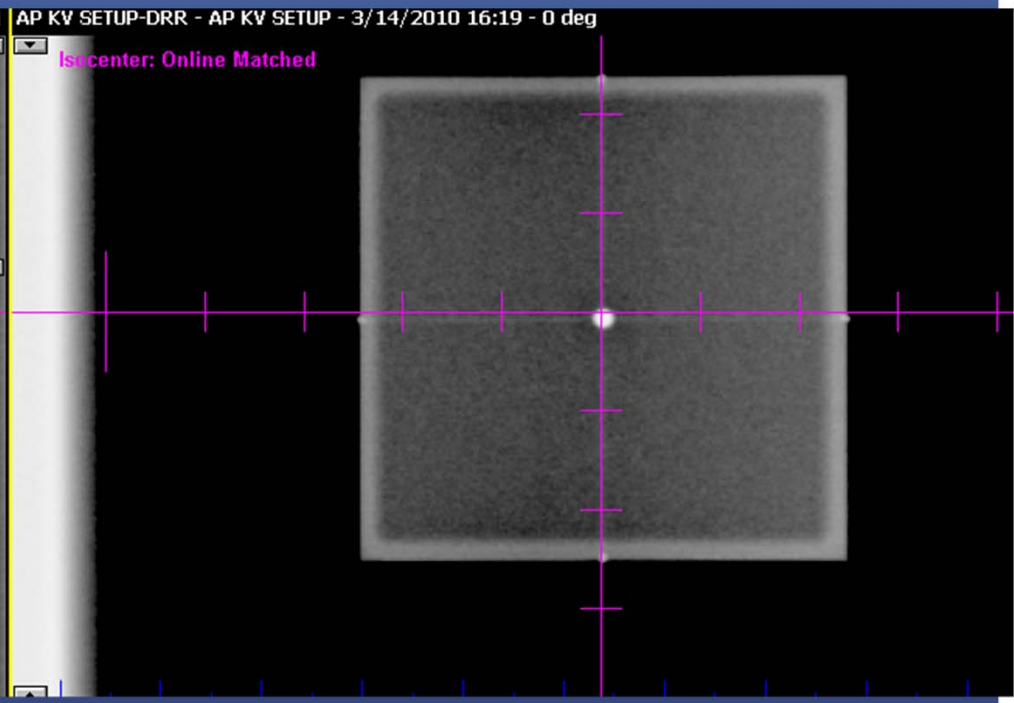

Verify agreement between image and radiation isocenter (line block up to room lasers)

Center of image varies with gantry angle

Diameter of sphere is 2mm. Graticule <2mm away from center

Best to correct in reconstruction if available

OBI – Positioning/Repositioning Test

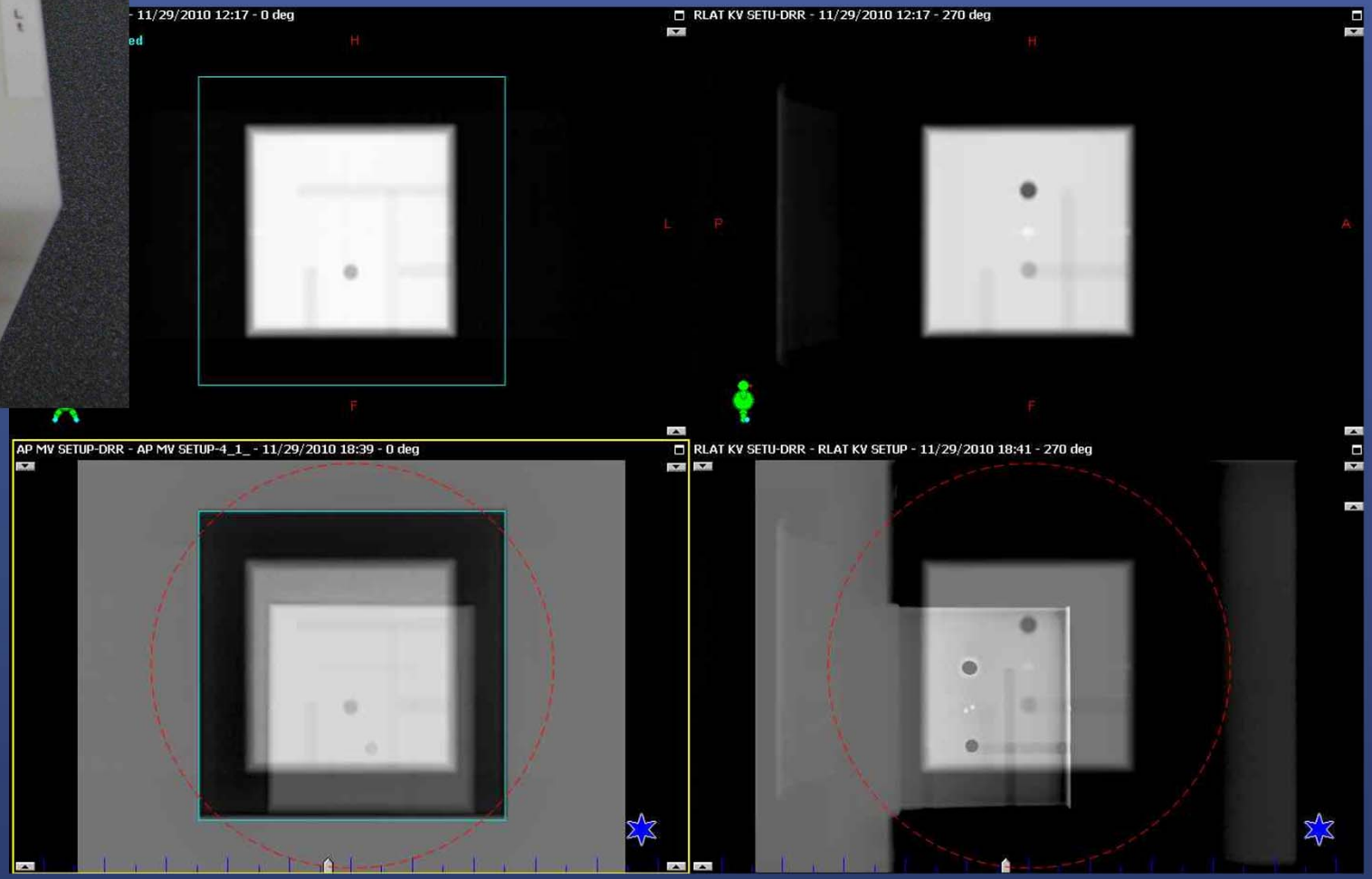

CBCT – Repositioning Test

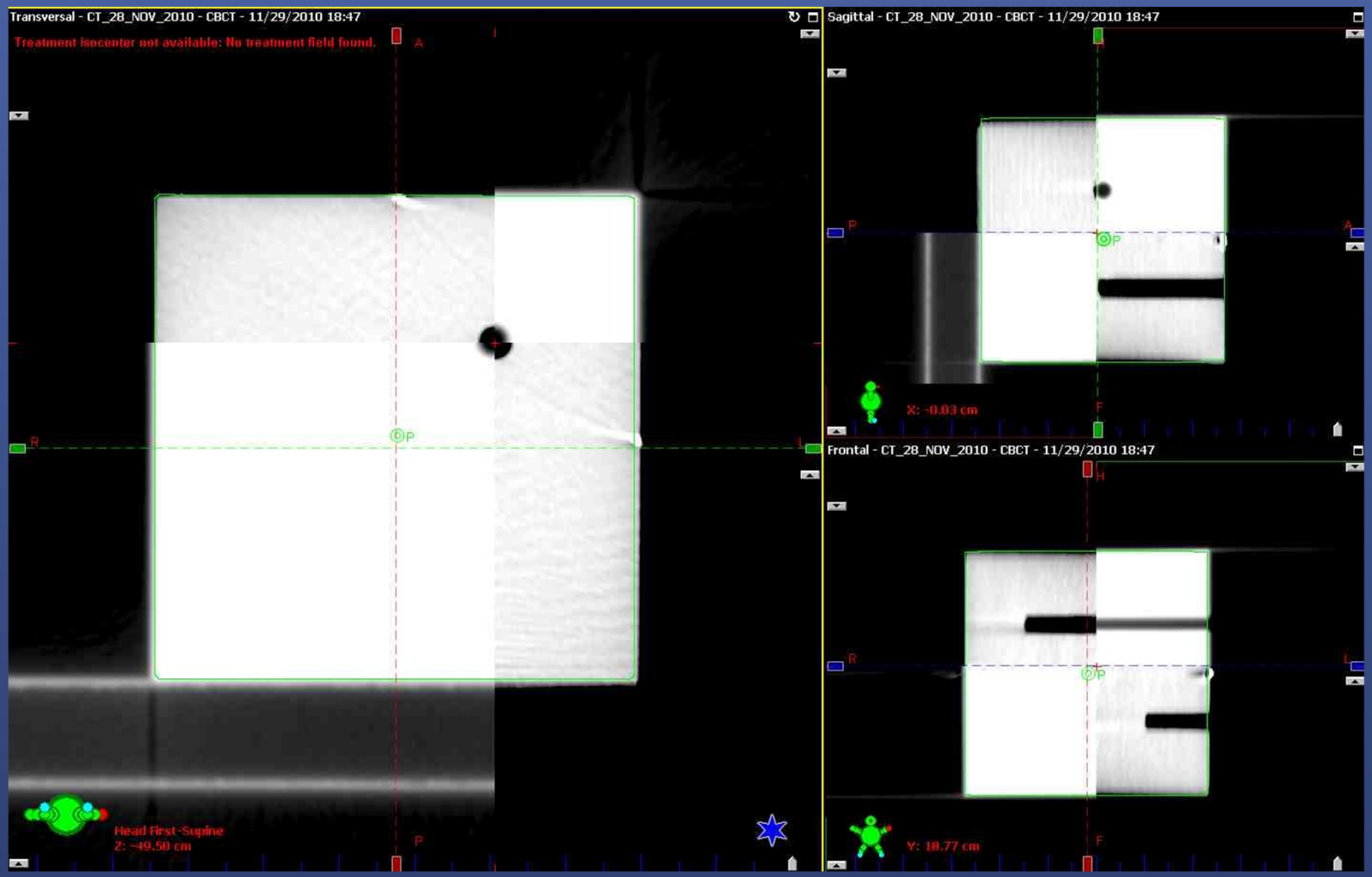

Shifts must be <2mm from expected

Ensure Consistent Image Quality



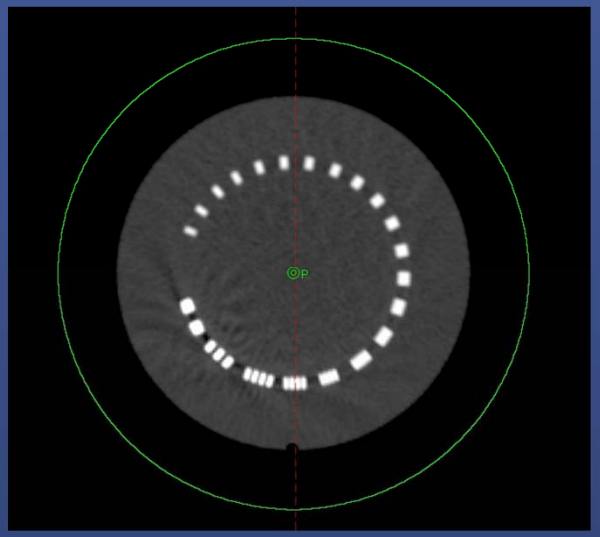

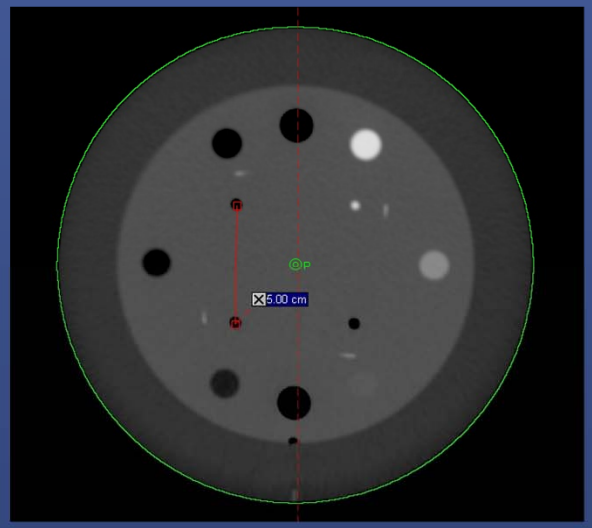

Calibration of Independent Imaging Systems (US, Cameras, etc)

- Many dependent on room lasers
- Must establish relationship between lasers and radiation isocenter
- Daily QA procedure

Novalis TX example: Check Lasers Point to Machine Isocenter



Define Camera Isocenter



Define X Ray Isocenter





Some Causes of Uncertainties in Image Fusion

#1 Poor visualization of the target

Poor Low Contrast Resolution in CBCT

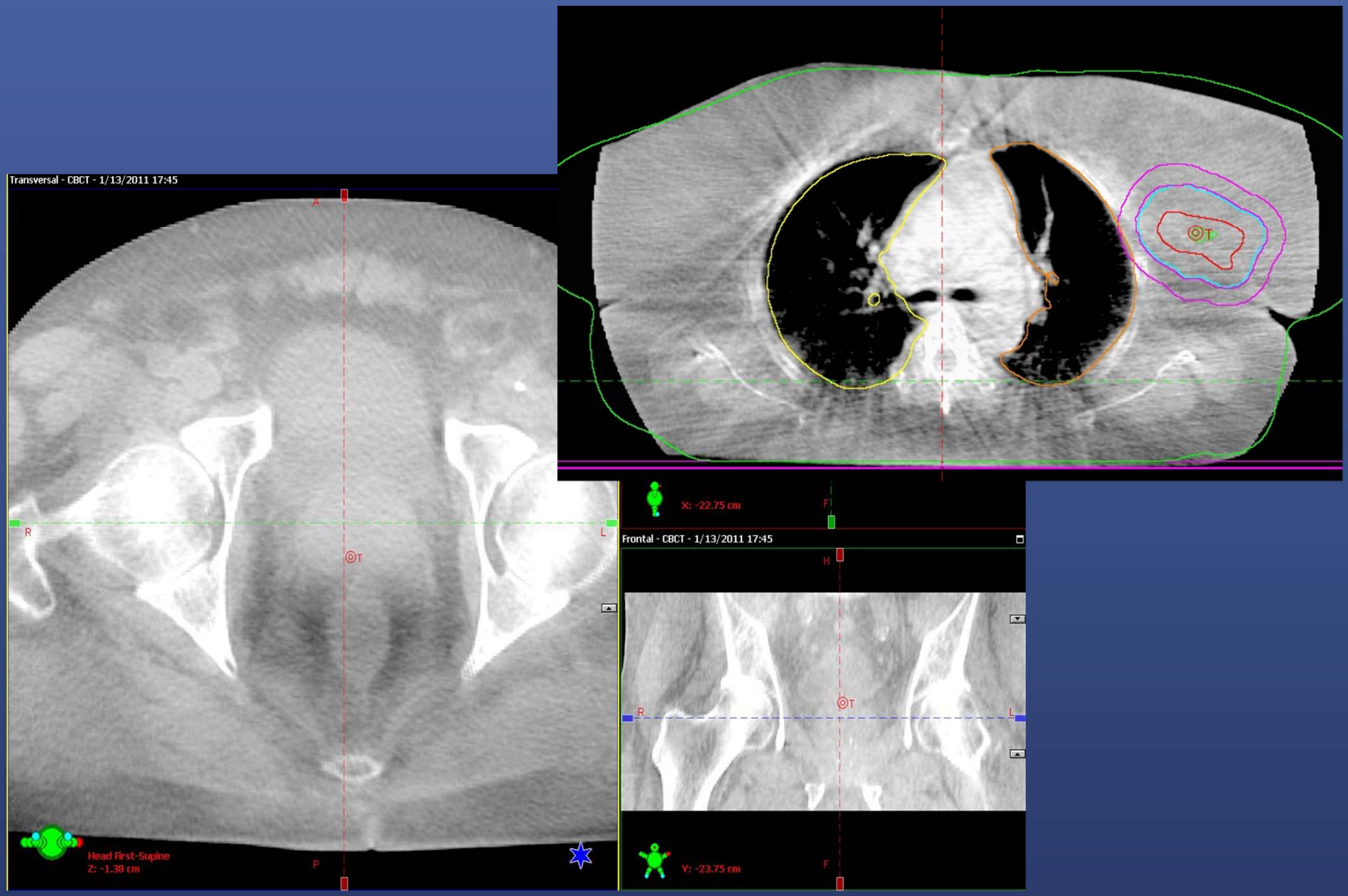

Image Artifacts

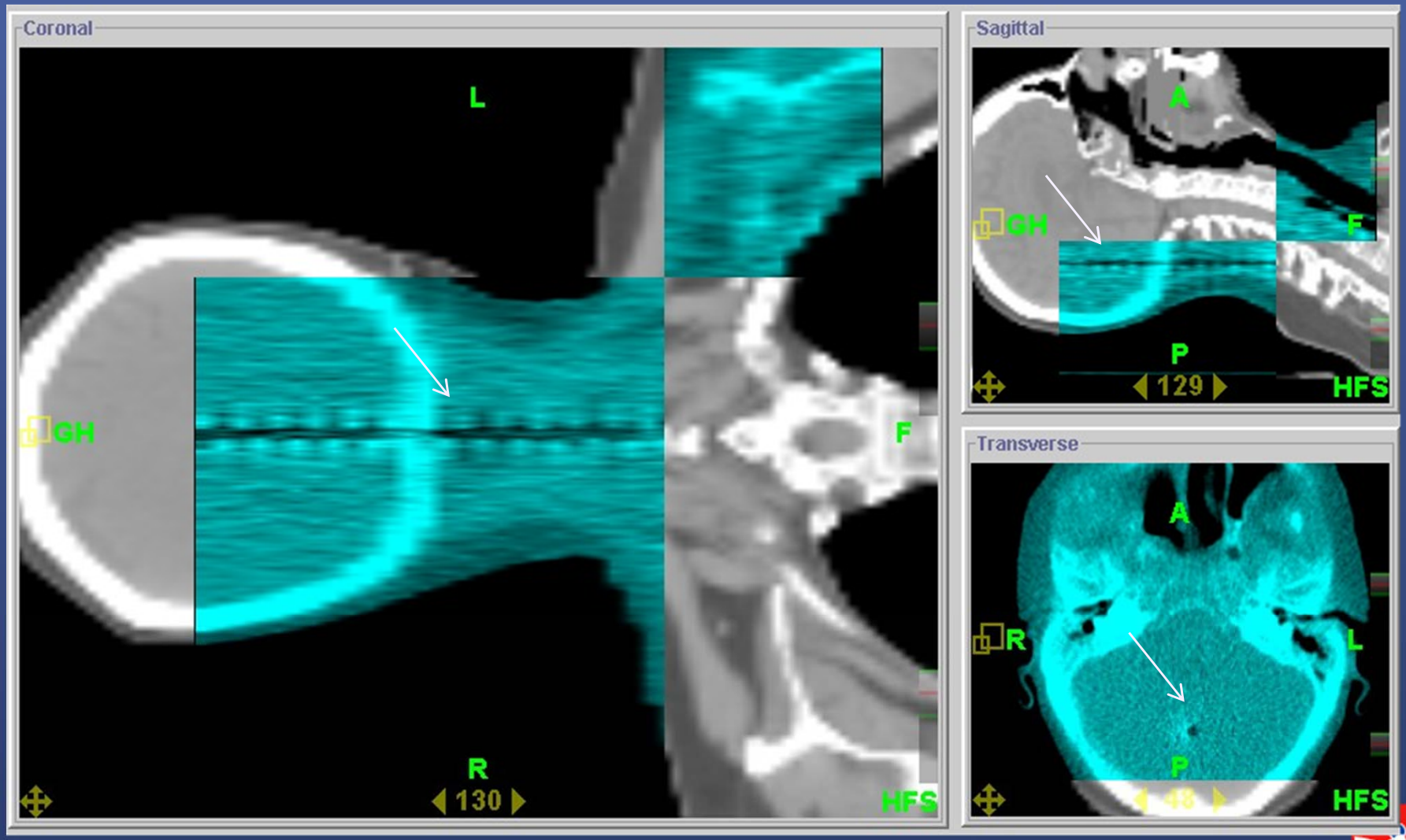

Old Portal Imaging Devices

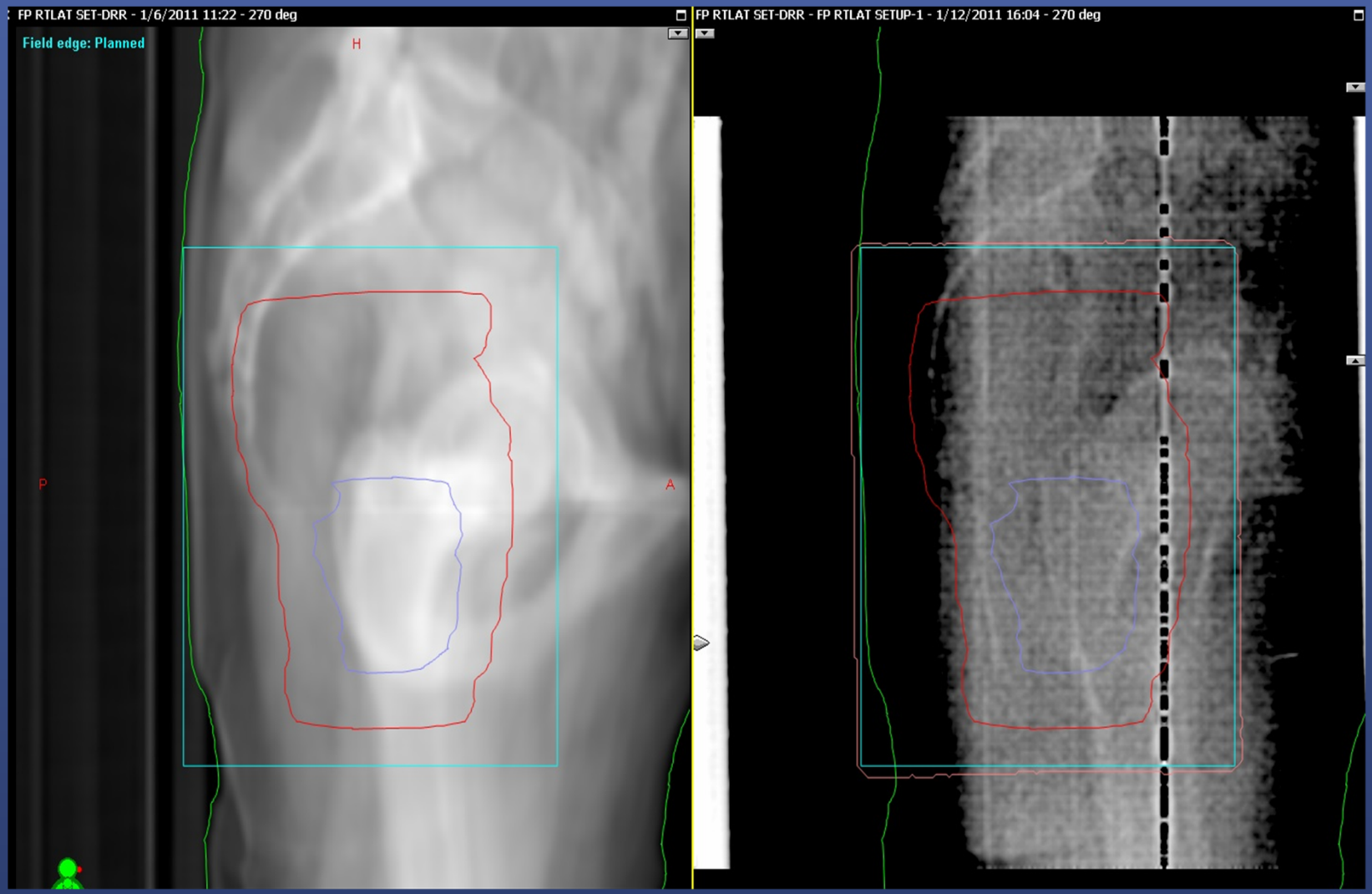

CBCT User Error

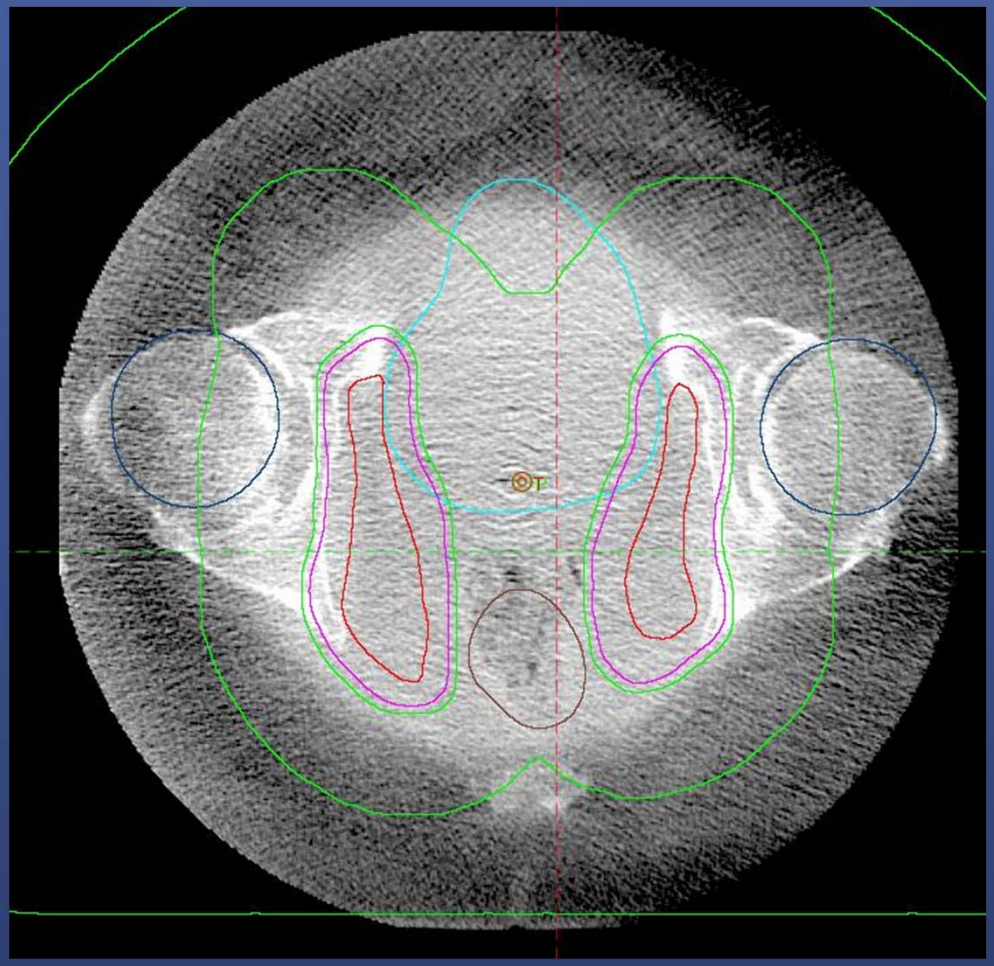

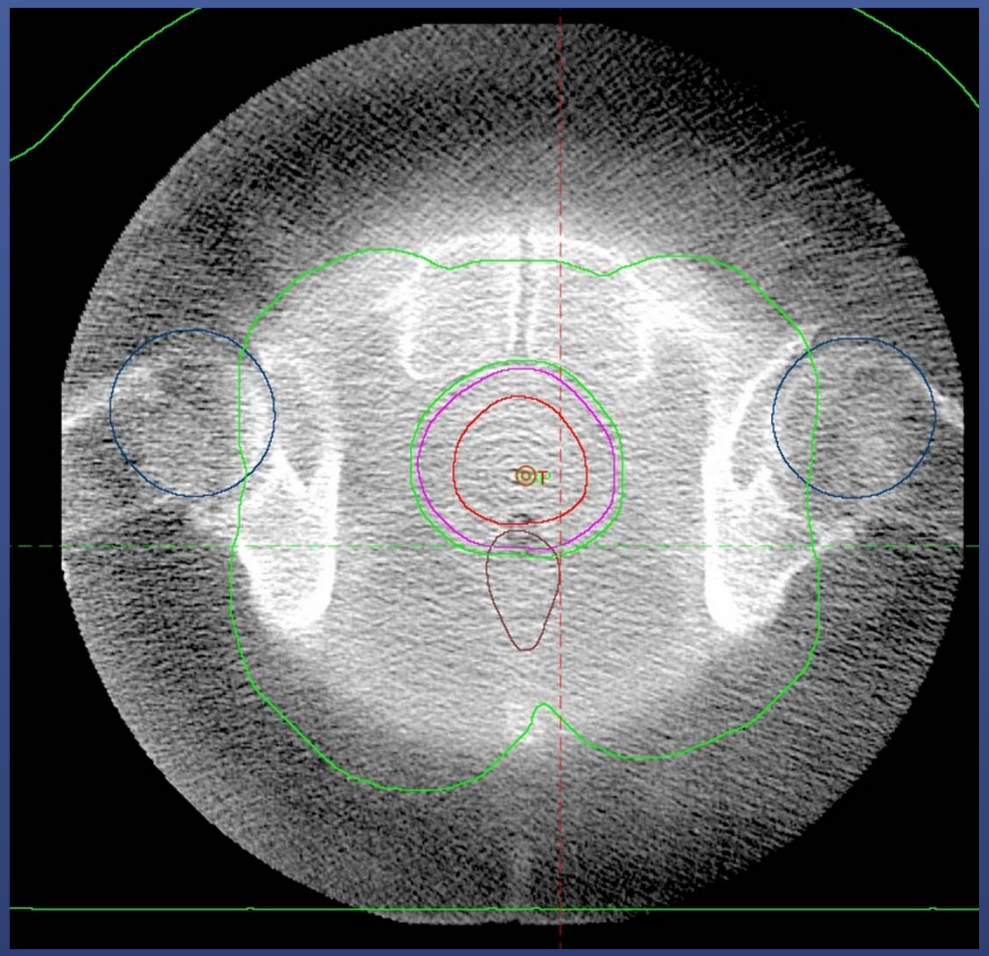

Artifact and Poor Visualization of the Target

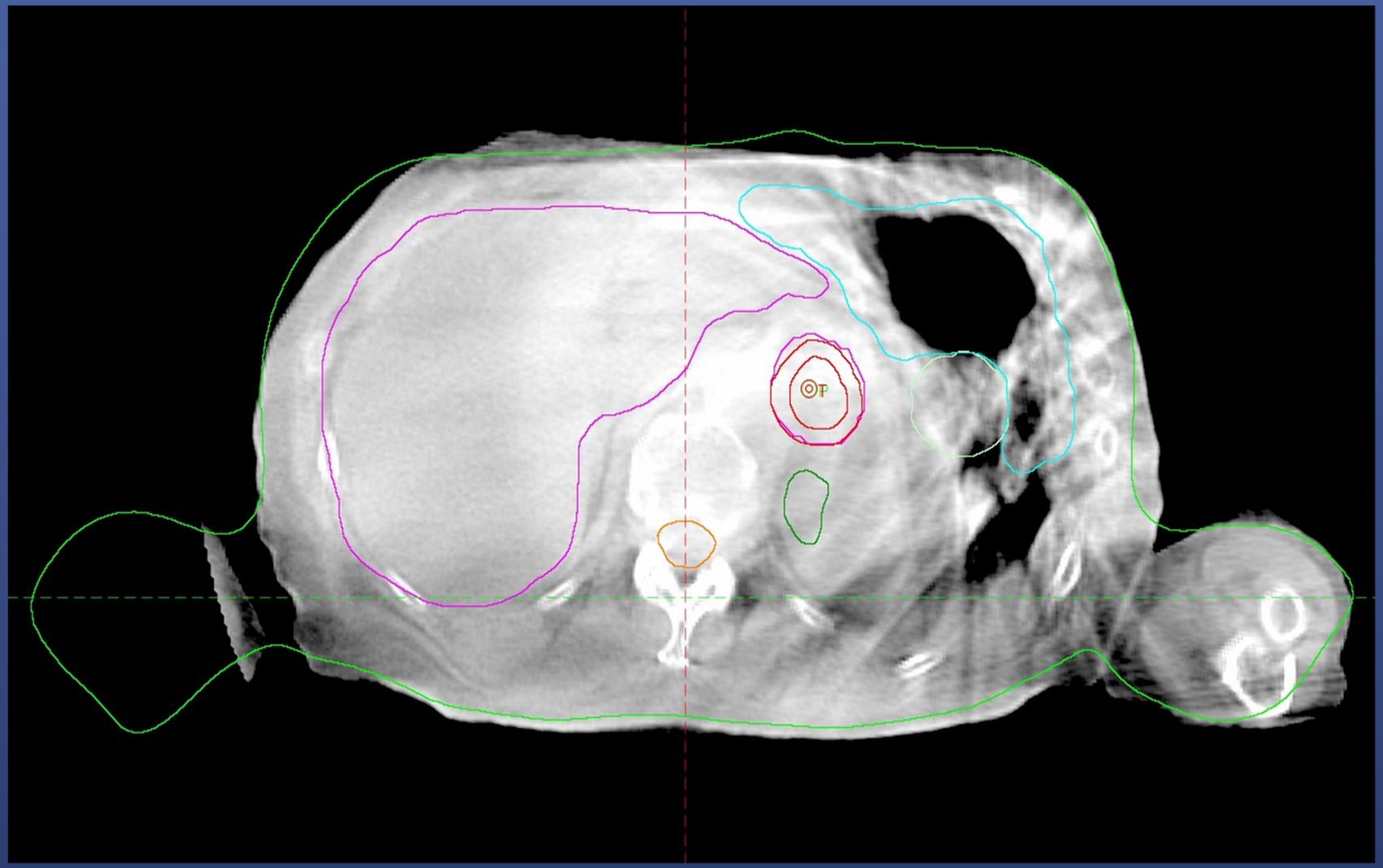

Ultrasound....

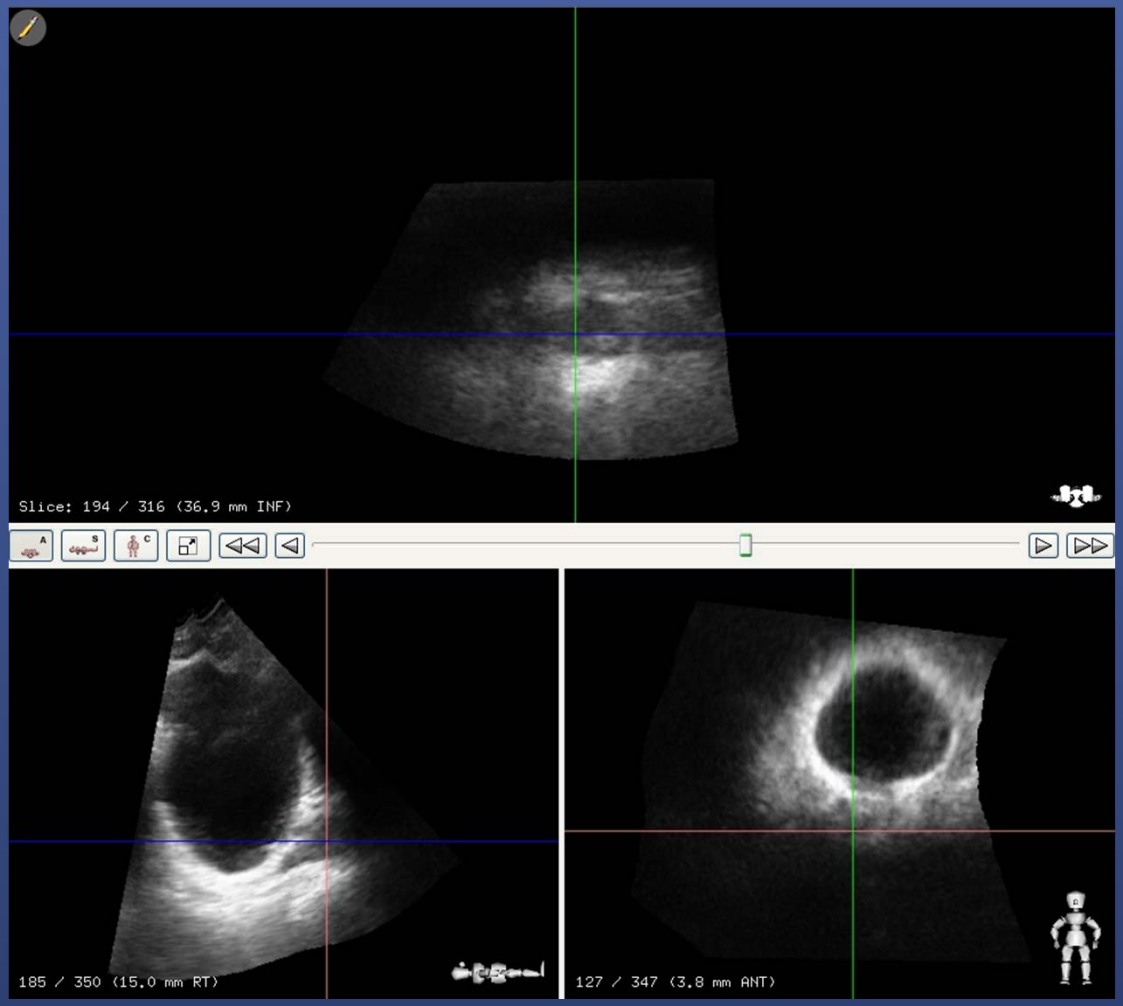

- Patient size dependent
- Interuser variability

Improving Imaging Techniques

- Setup imaging protocols
- Use image presets with caution
  - Consider size of patient along with the anatomy
  - "Lateral Pelvis" assumes an average size patient
- Training
  - Know how to use the equipment
  - Know how to adjust imaging techniques to get the best image
  - Know when an imaging mistake has occurred

Improve kV Imaging Techniques

Grainy Dark

Increase KV
Brighter/Grainy

Increase KV and mA
Brighter/ Less Grainy

Example provided on www.myvarian.com

Bands of Vertical Stripes

- Problem:
  - Image is saturated
  - X-Ray intensity is too high
- Solution:
  - Decrease kV

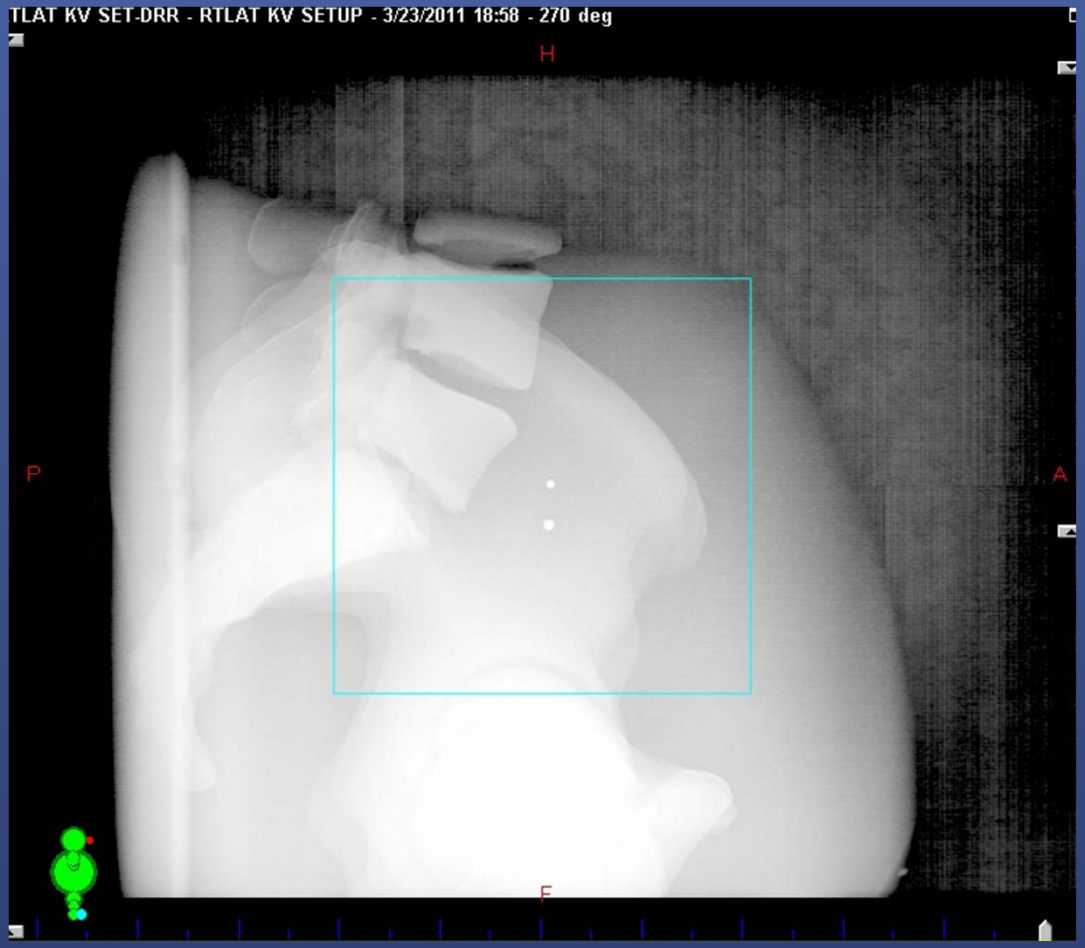

150 kV
3000mAs
Pelvis Lat Technique: 105 kV, 800ms

Grainy Images

- Problem:
  - X-Ray intensity is too low
- Solution:
  - Increase mAs or kV
  - Increase mAs only if contrast is already good

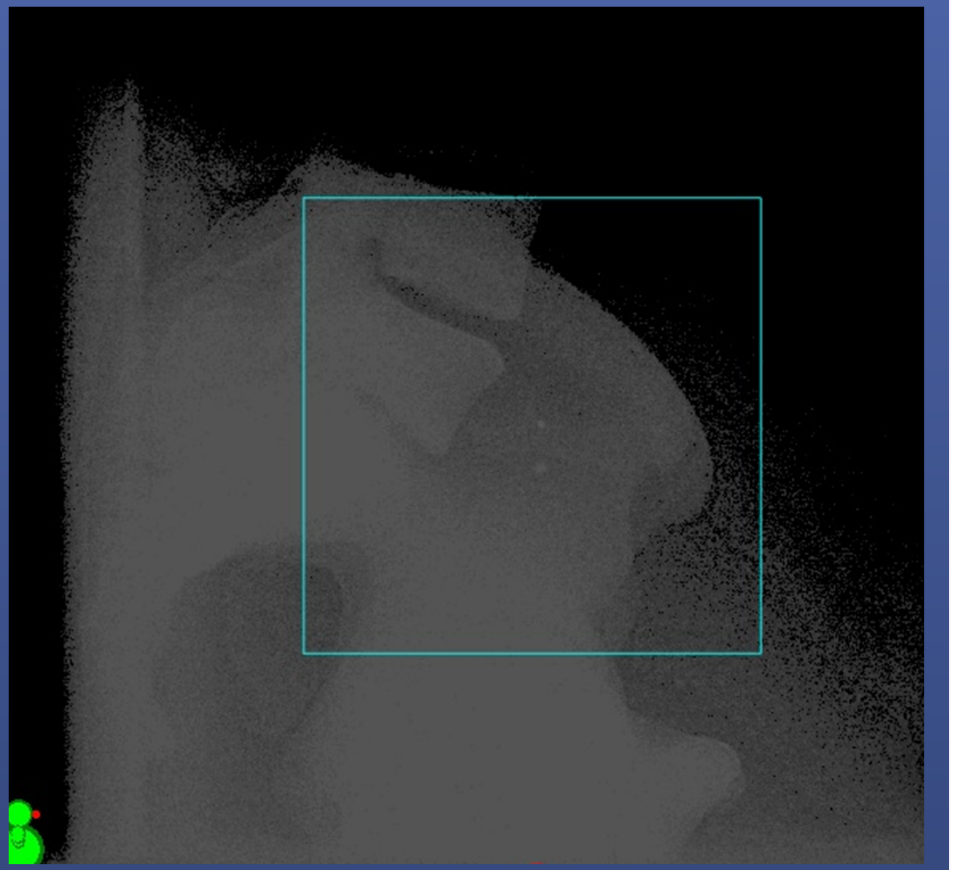

Head Lat Technique: 70 kV
50ms
Pelvis Lat Technique: 105 kV, 800ms

Improve kV Imaging

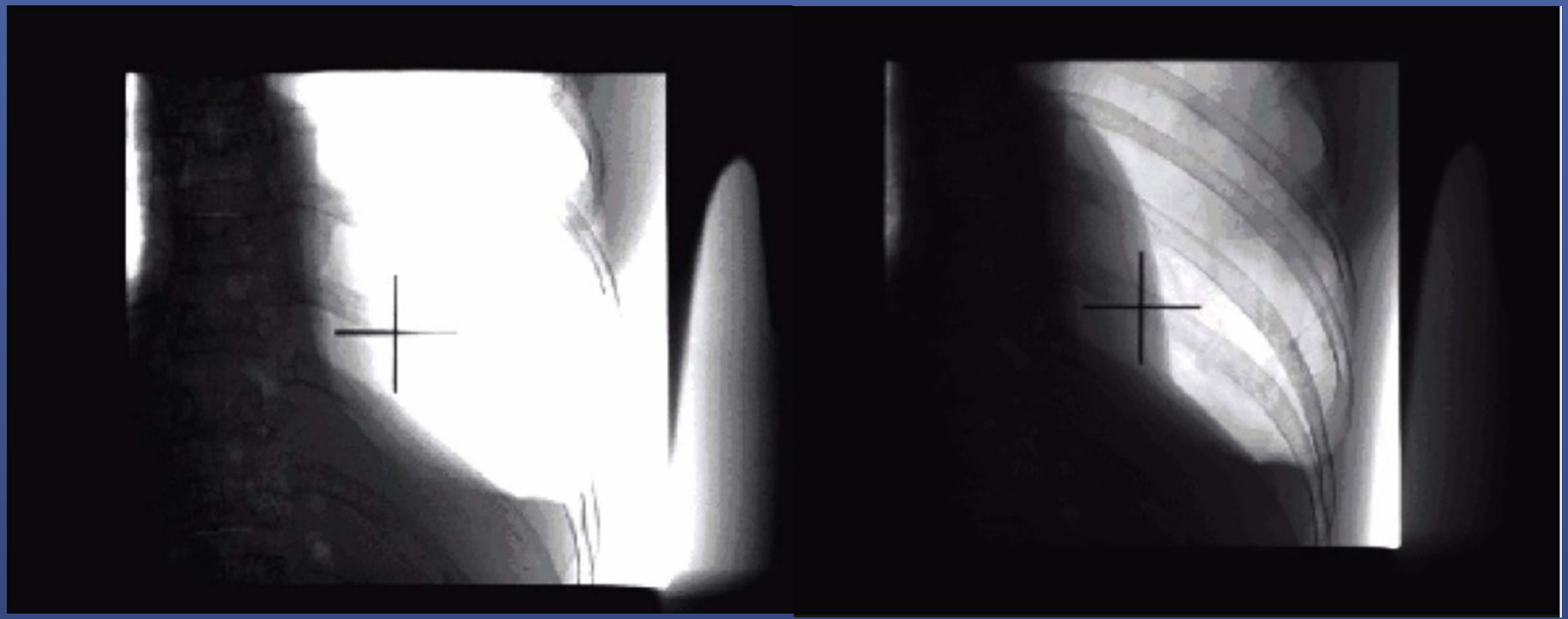

- Reduce flaring by adding a bowtie filter
- Collimate to field size

Example provided on www.myvarian.com

Use of Collimation and Filters

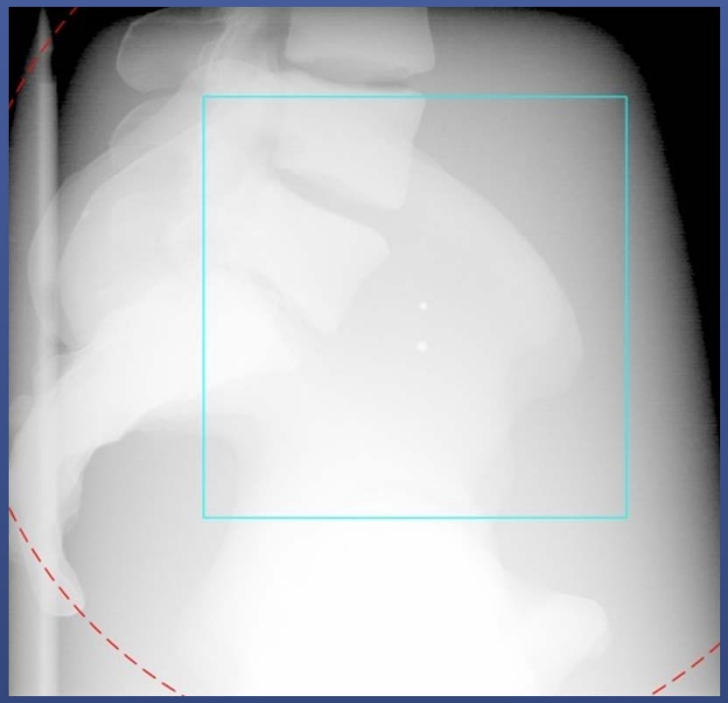

Blades Open/No Filter

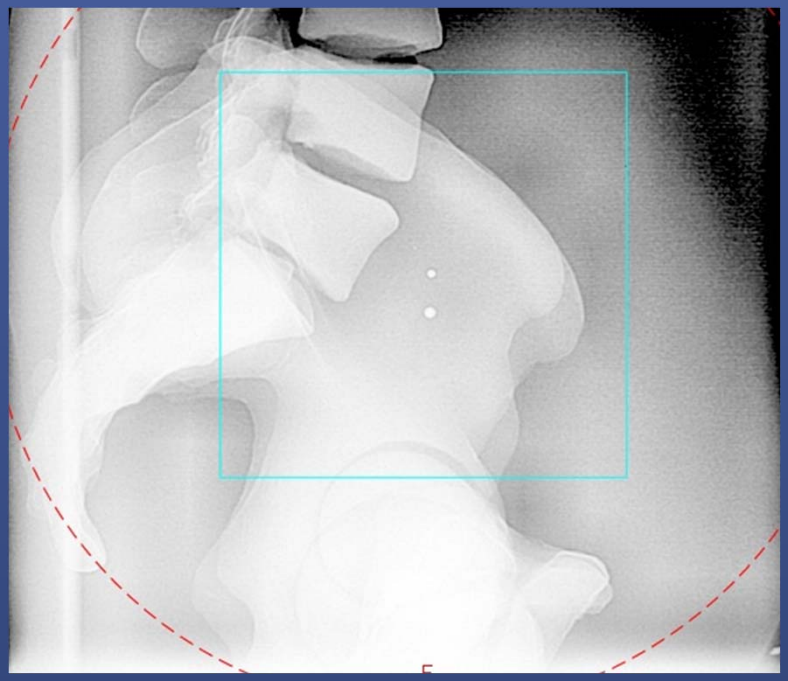

Dynamic Filter

Avoid Imaging Mistakes

Three consecutive days of imaging

Prostate

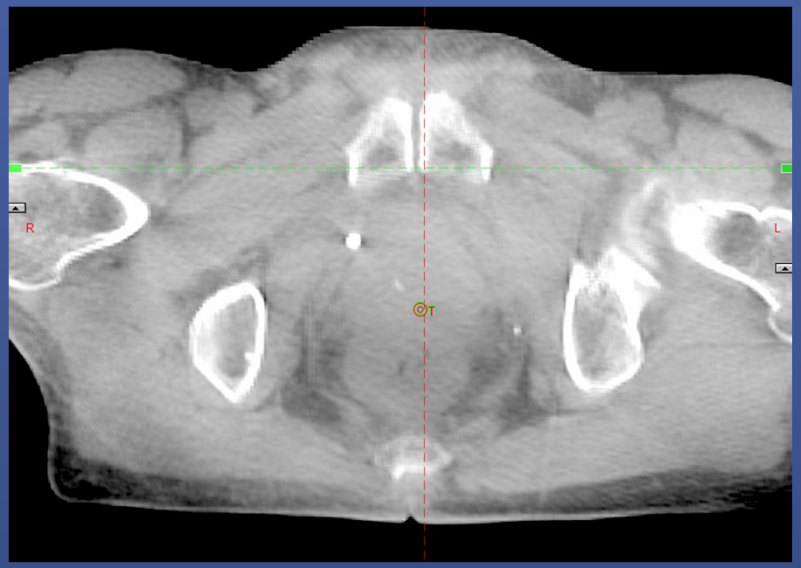

Head with Half Fan

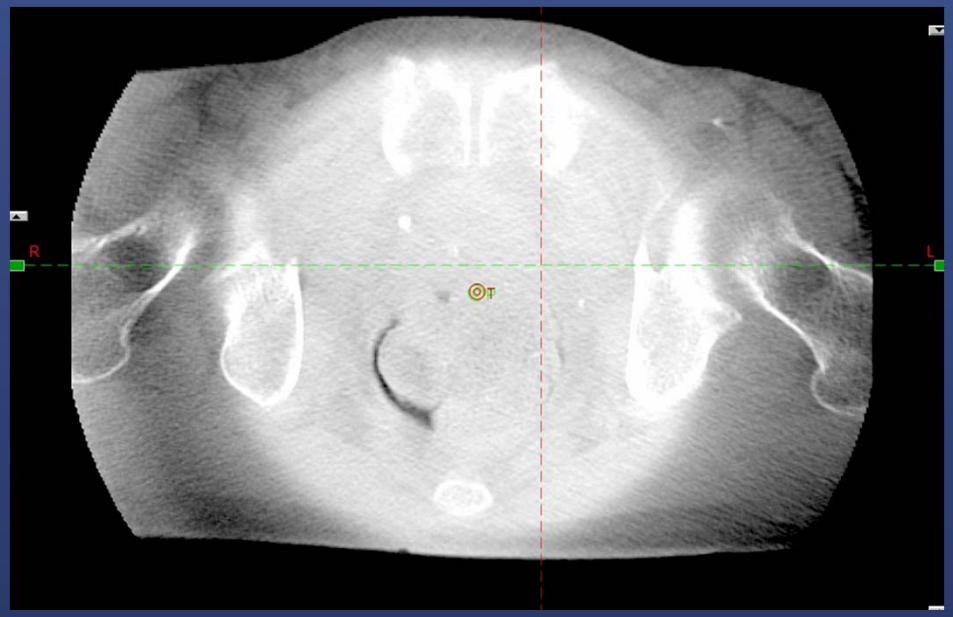

Pelvis with Full Fan

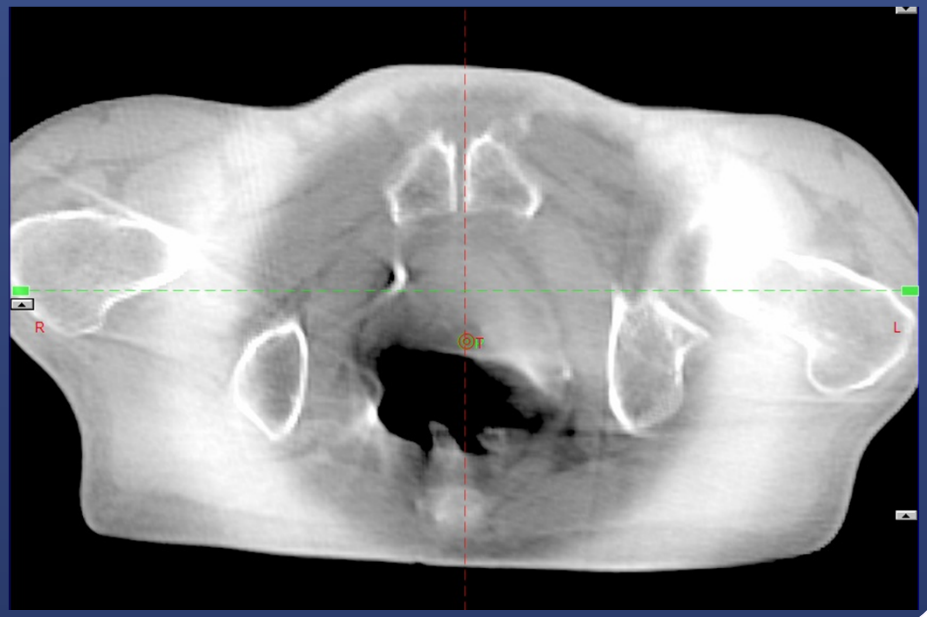

Correct and Incorrect Filter – Half Fan

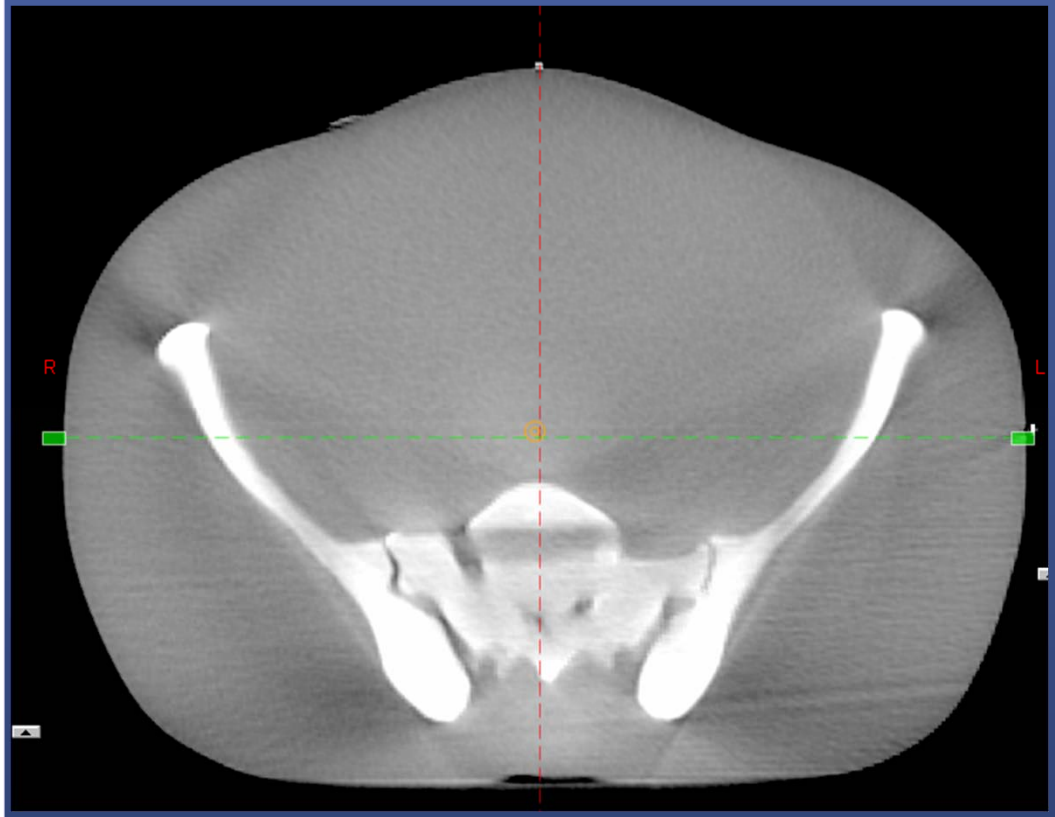

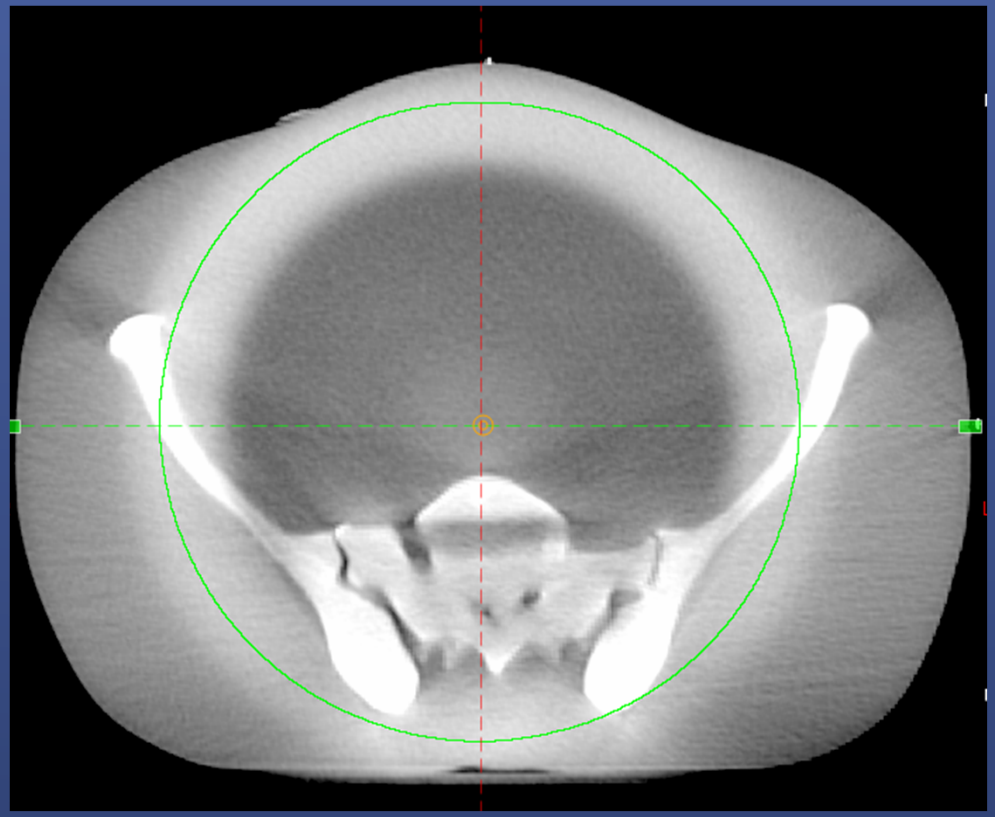

With and Without Filter

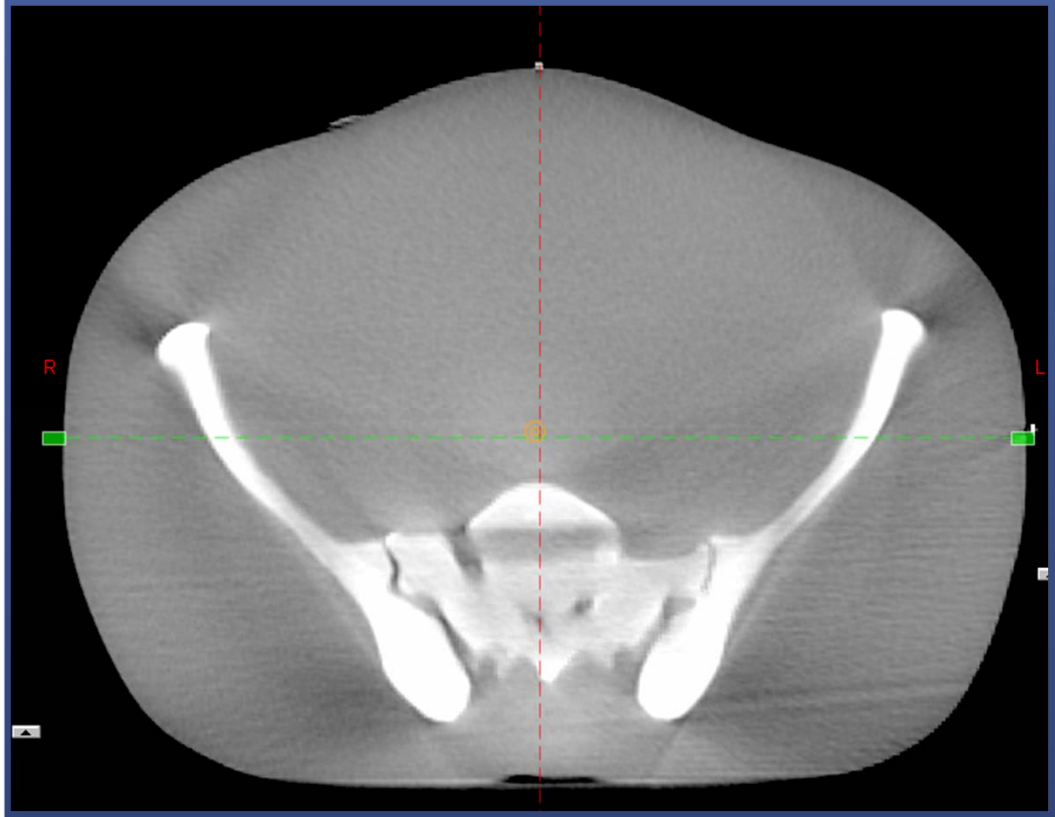

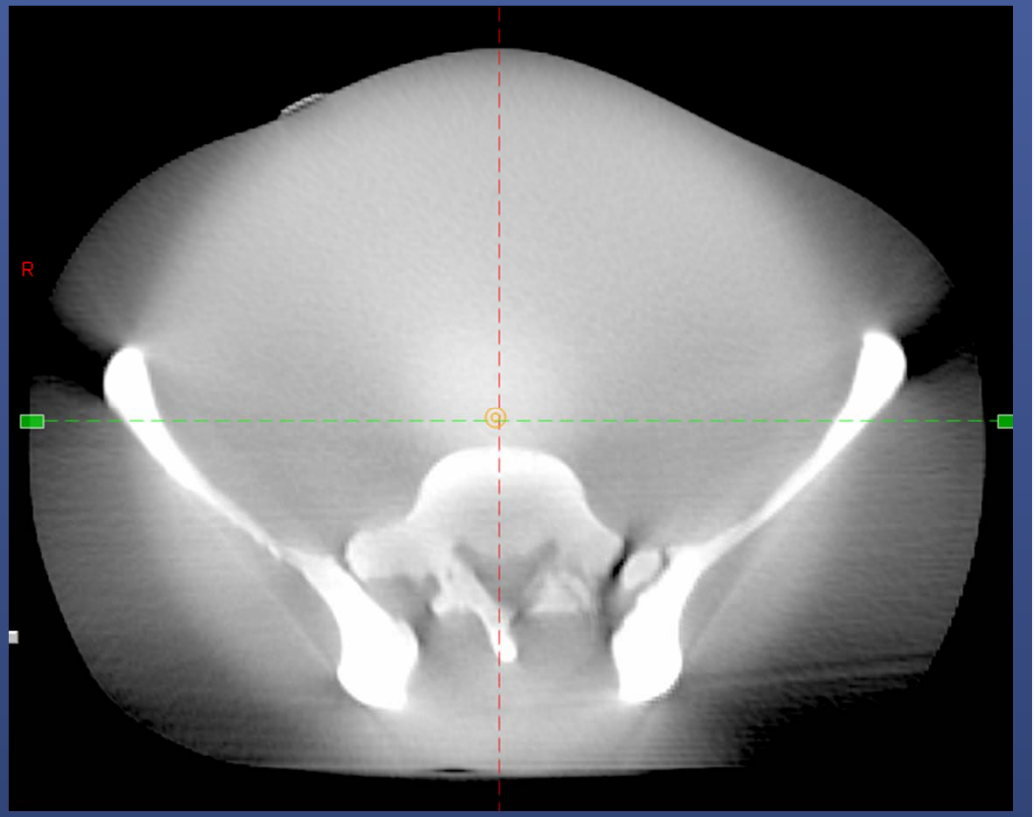

Correct and Incorrect Filter – Full Fan

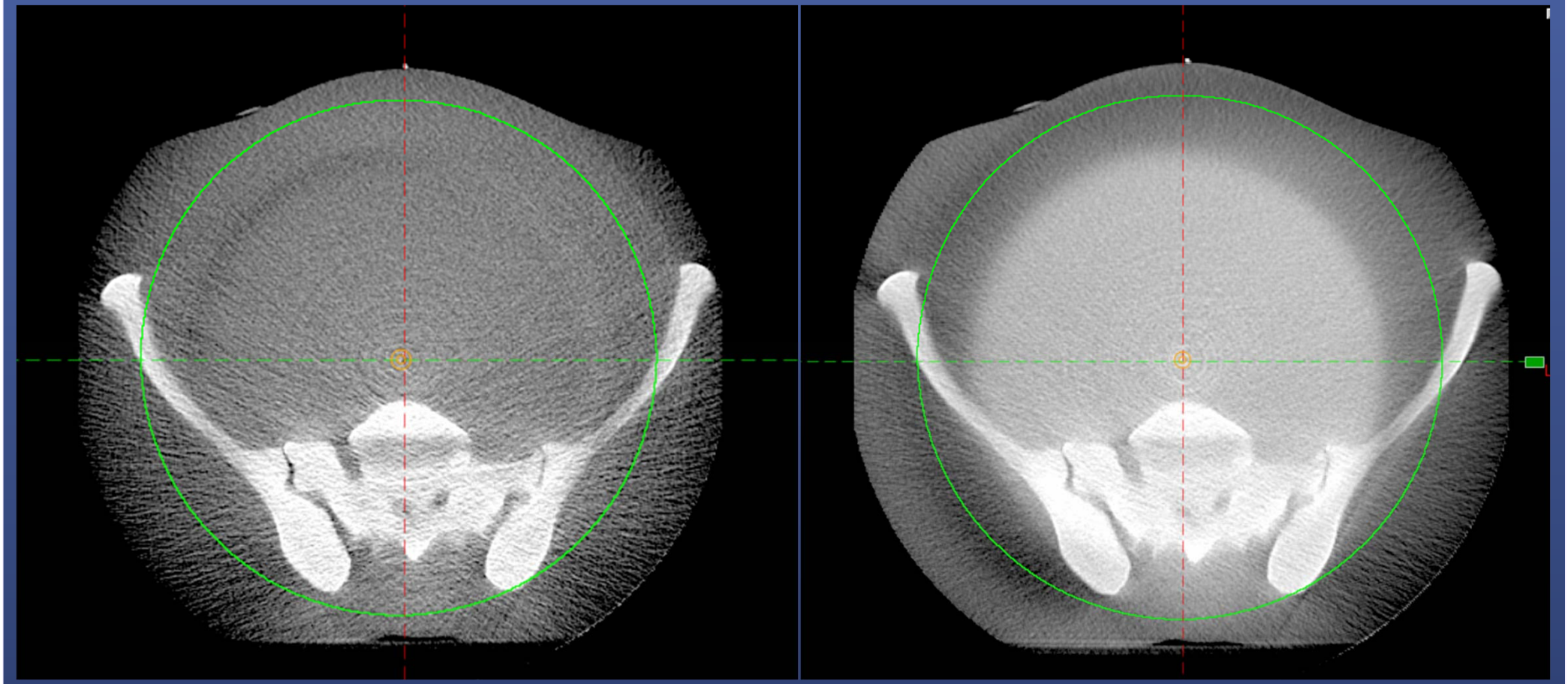

Correct and Incorrect Energy

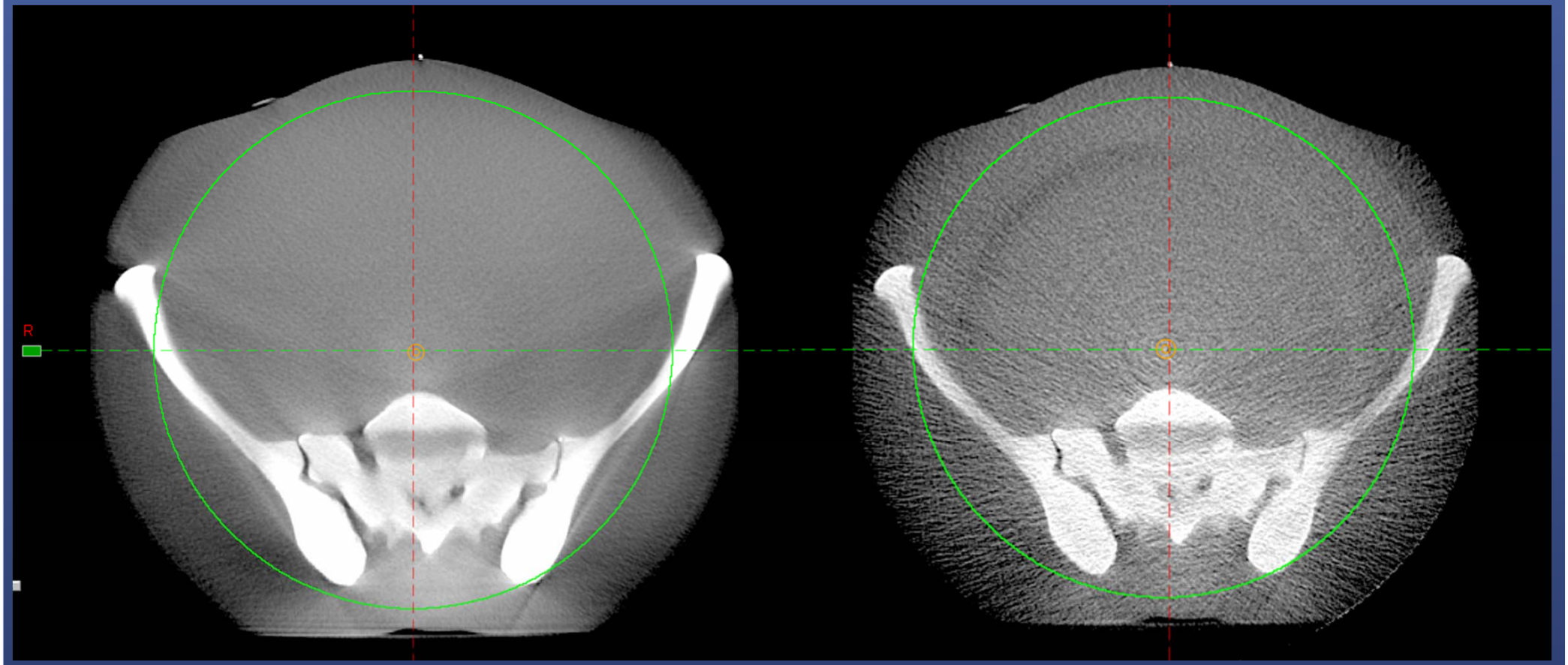

Quick Scan

- Selects same parameters that were used for the previous CBCT for THAT patient
- Quick Scan (Parameter Display) shows what is being automatically selected
- Ensure that all therapists check scan parameters before scanning

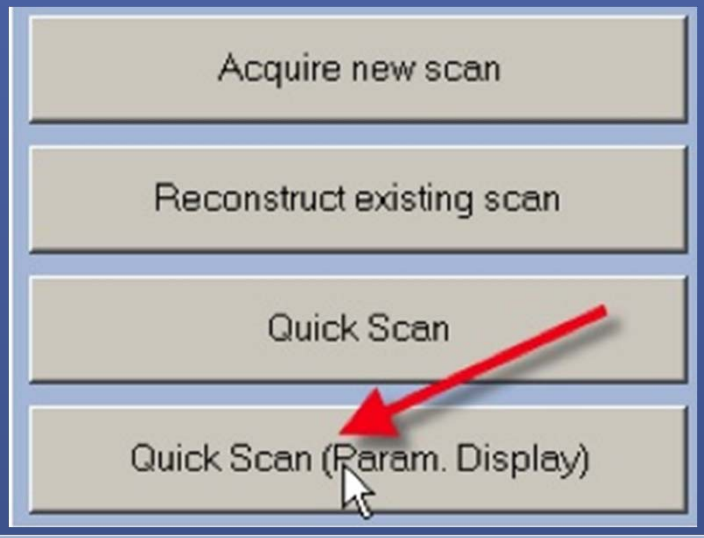

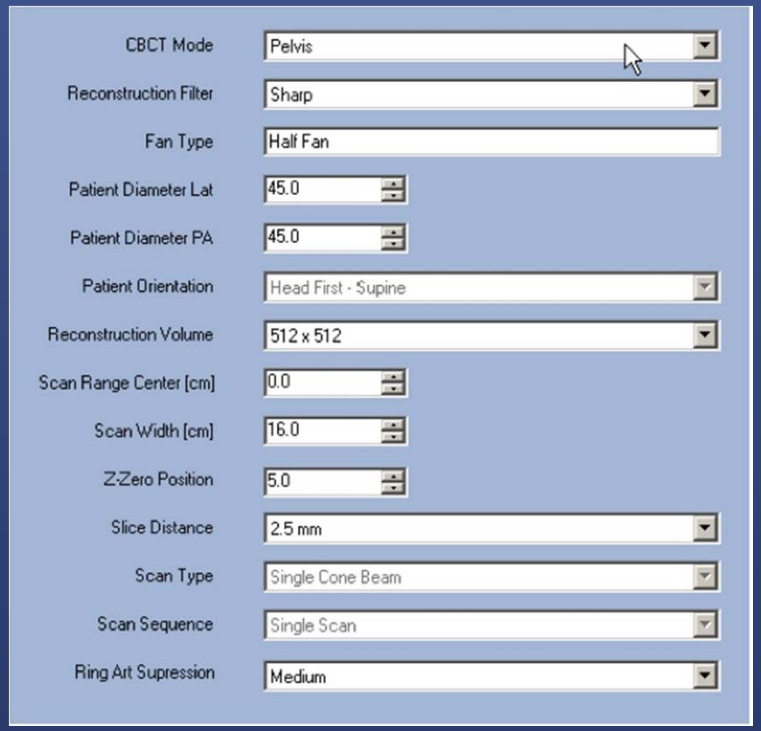

Improving Ultrasound Imaging

- Intact prostate
- Full bladder (aids in image quality, appears dark)
- Empty rectum (appears bright)
- Thin patient (improves image quality and belly stable)
- Relaxed patient (not pushing against the probe)
- Prostate not under the pubis
- Lasers aligned properly (CT/Vault) and daily QA performed
- Constant pace and pressure used by therapists in imaging
- Reduced intrafraction motion (short time between CT and ultrasound at simulation)

Better Visualization of Target

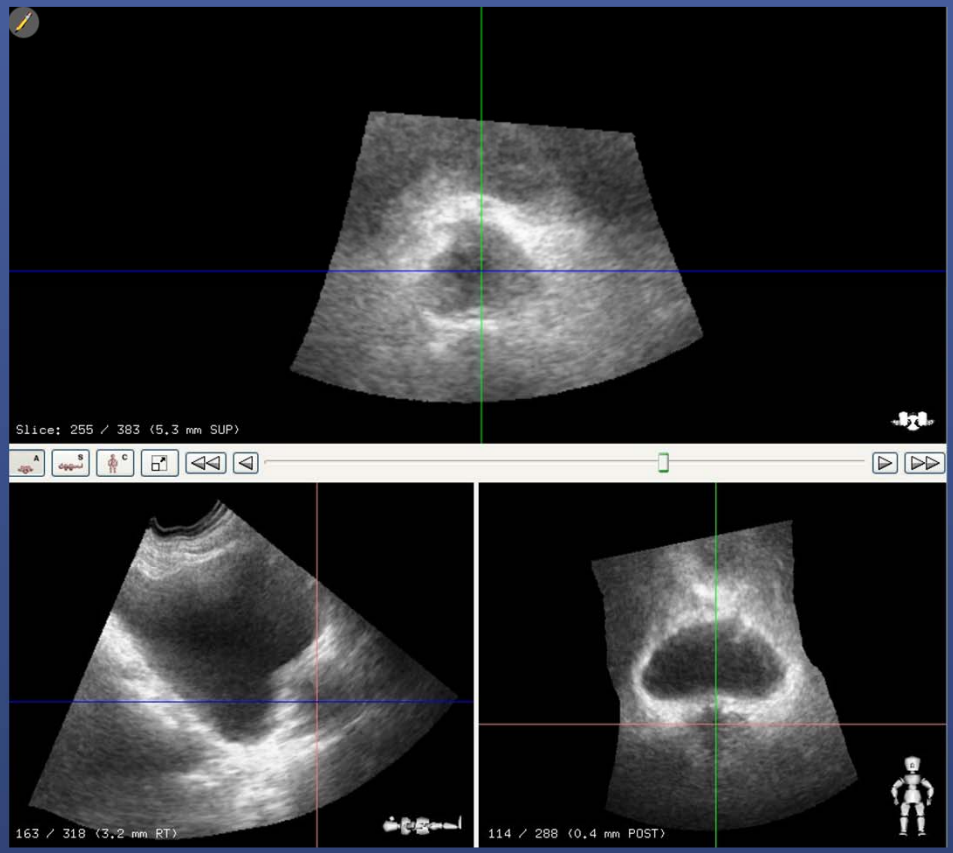

Better

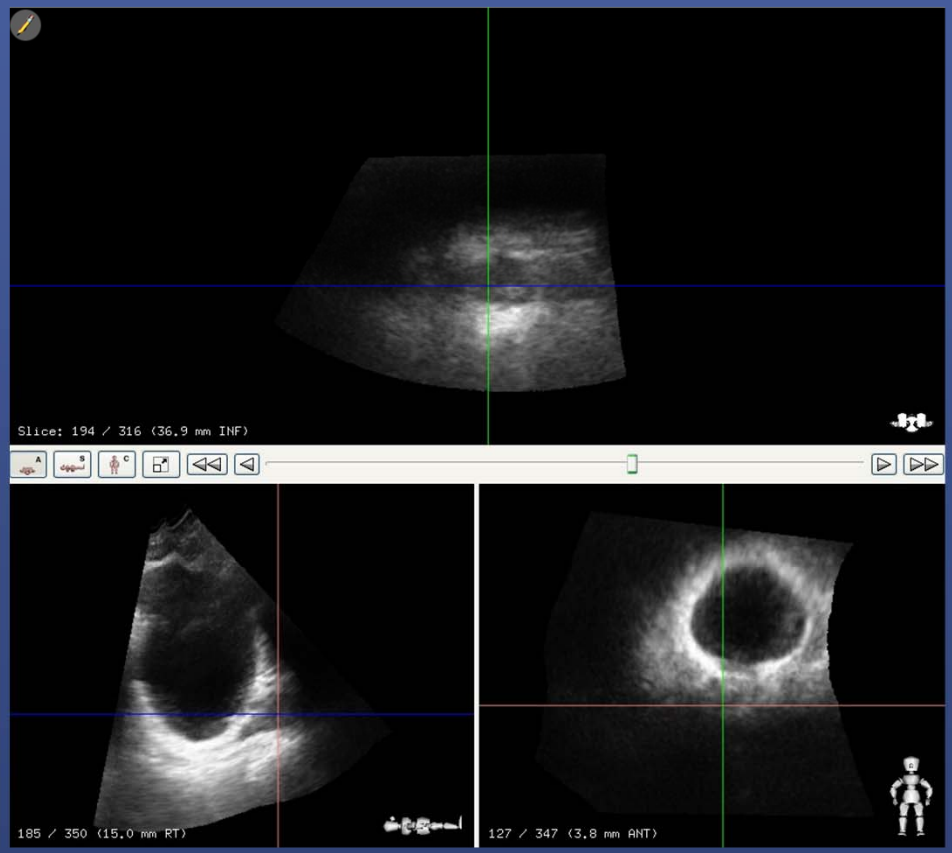

Worse

Change Imaging Modalities

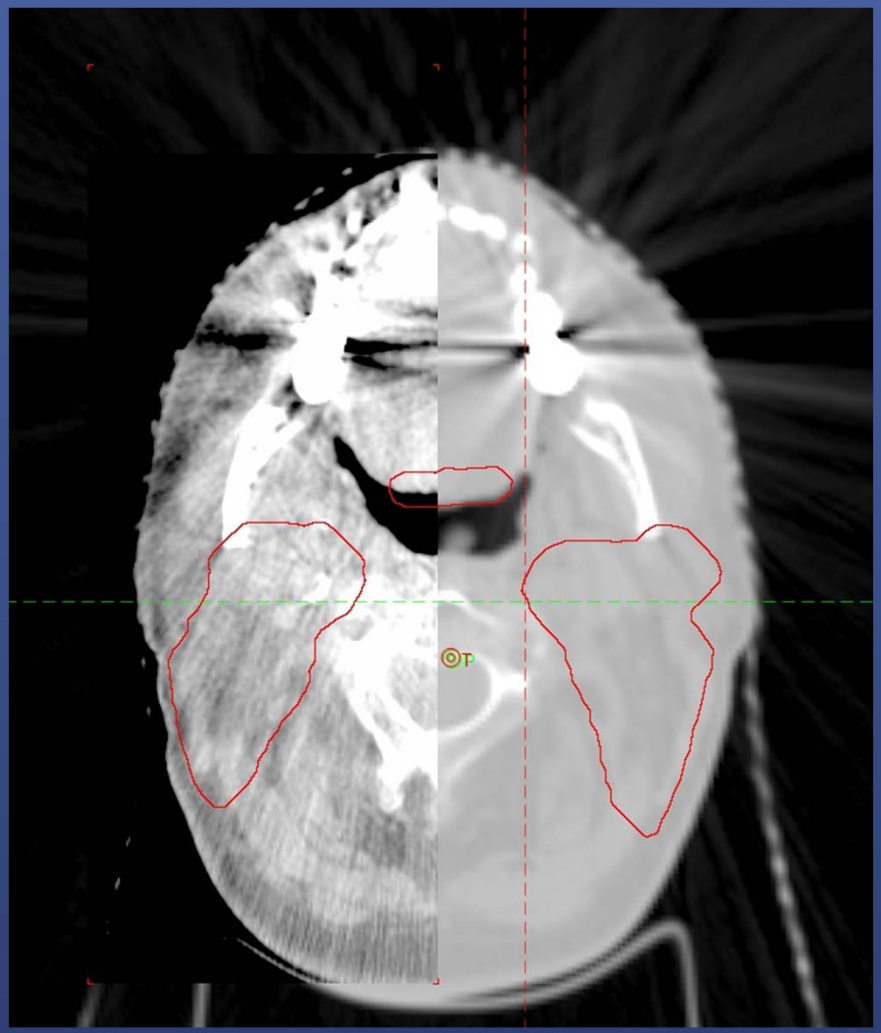

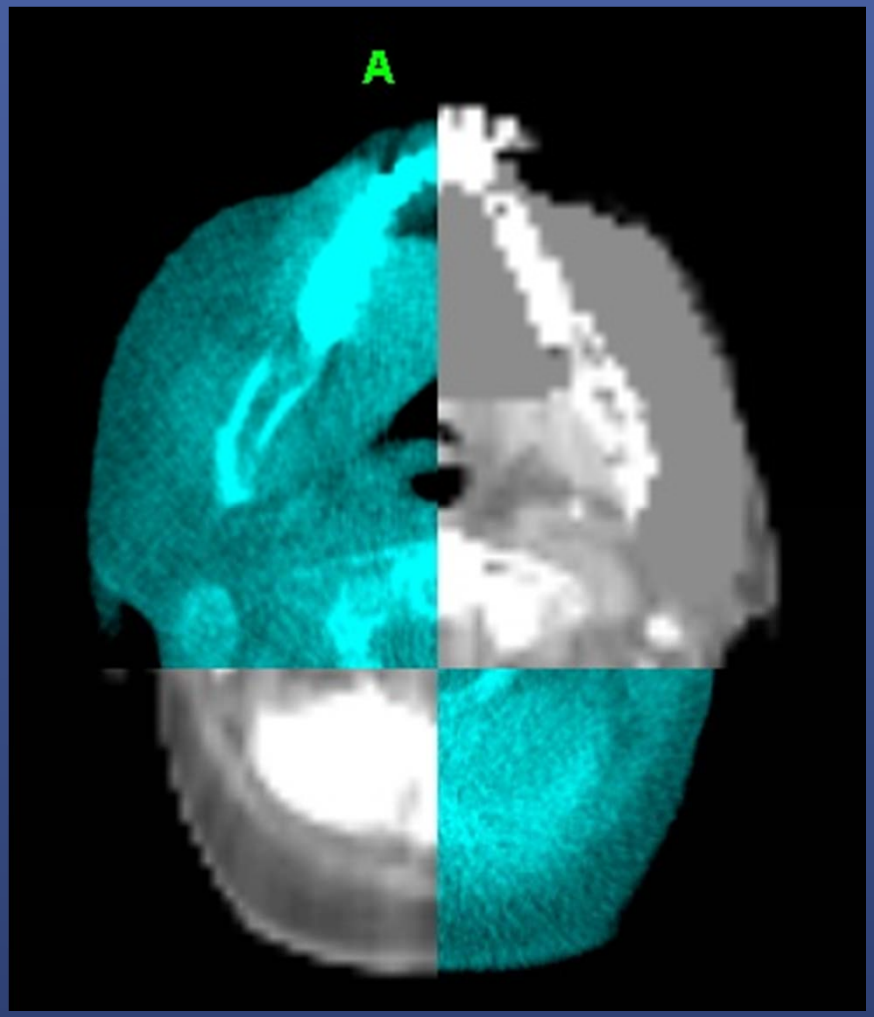

#2 Quality of the Reference Image

Improve DRR Quality

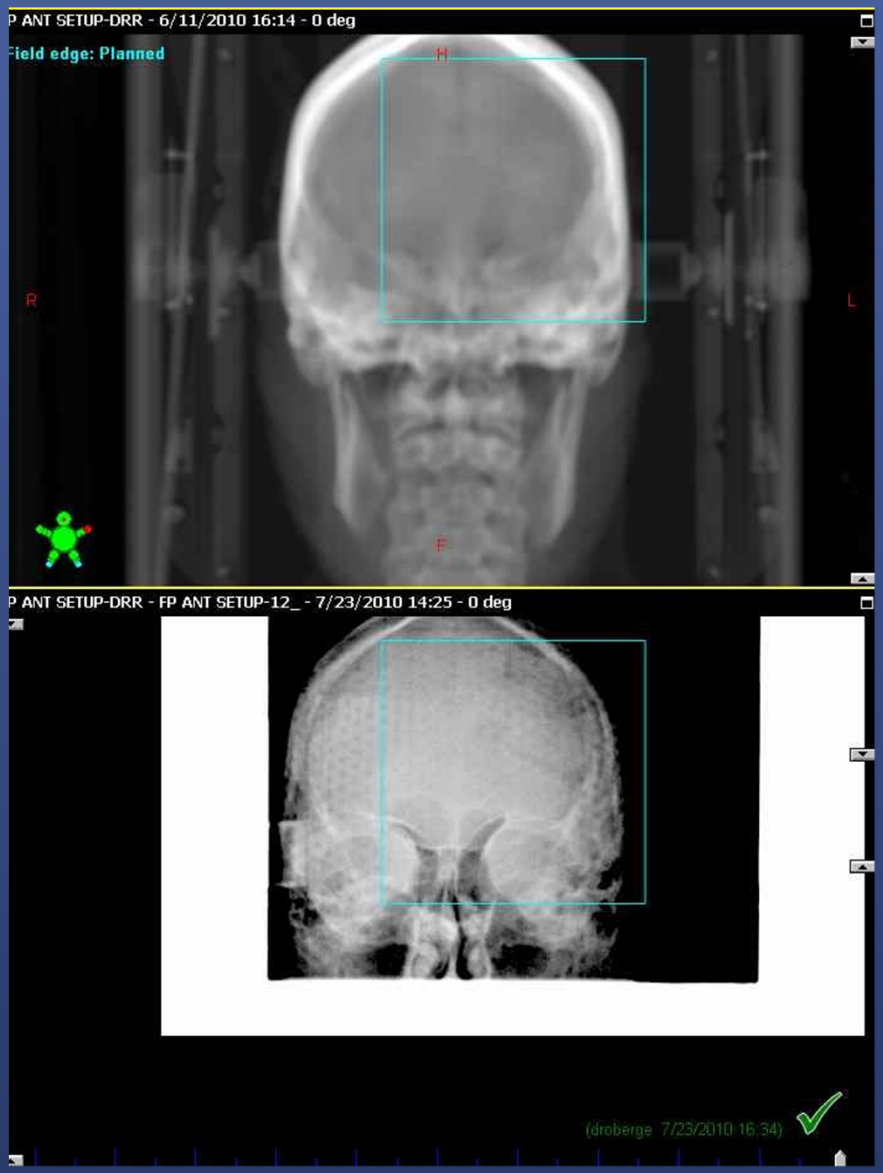

- QA to review DRR before treatment
- Small CT slice width
- Good image resolution
- Apply appropriate filter
- Ensure CORRECT DRR if manually imported

Mach Reference and Localization Image Modality

US to US Registration

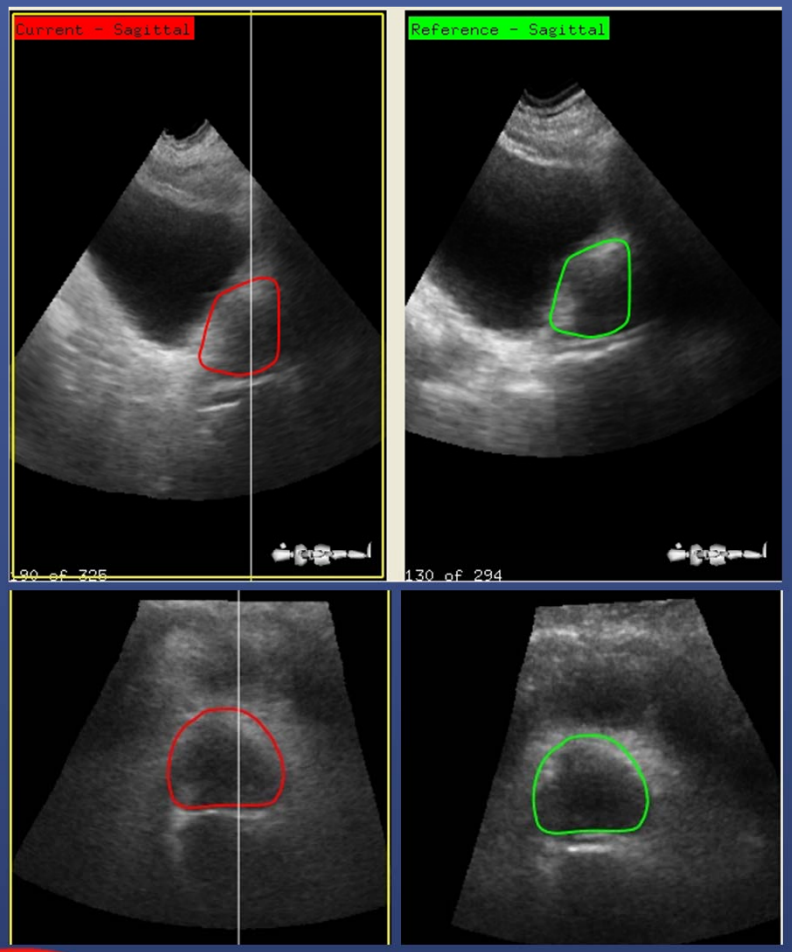

CT-US Fusion

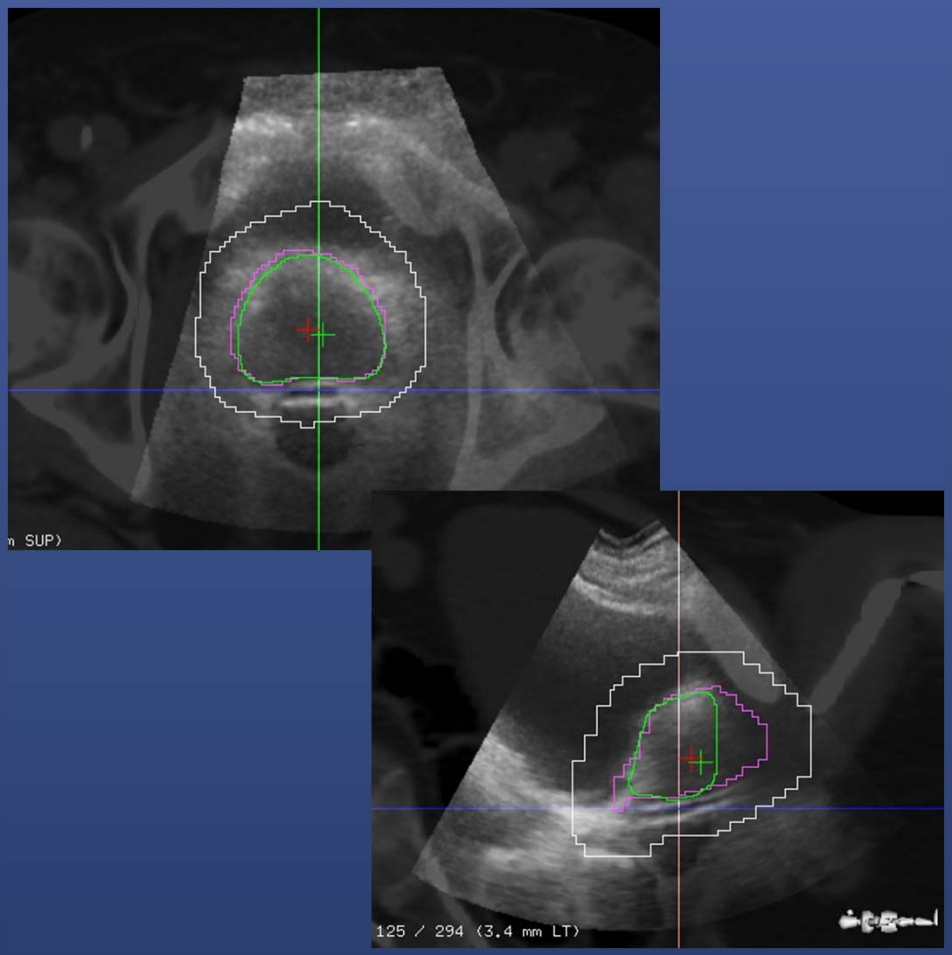

Match Reference Image Quality

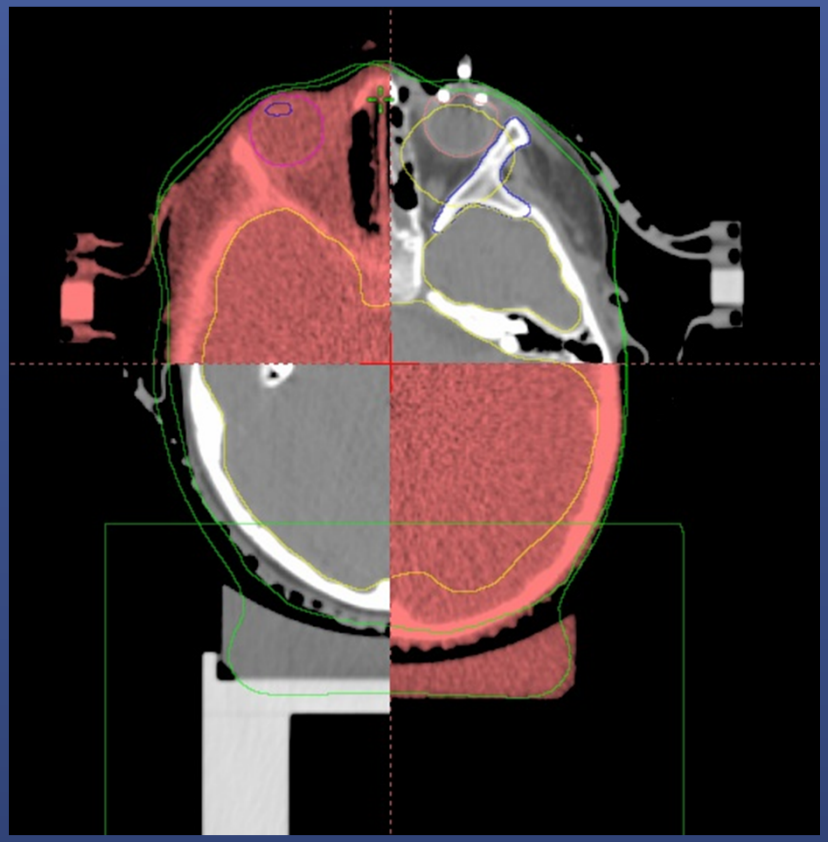

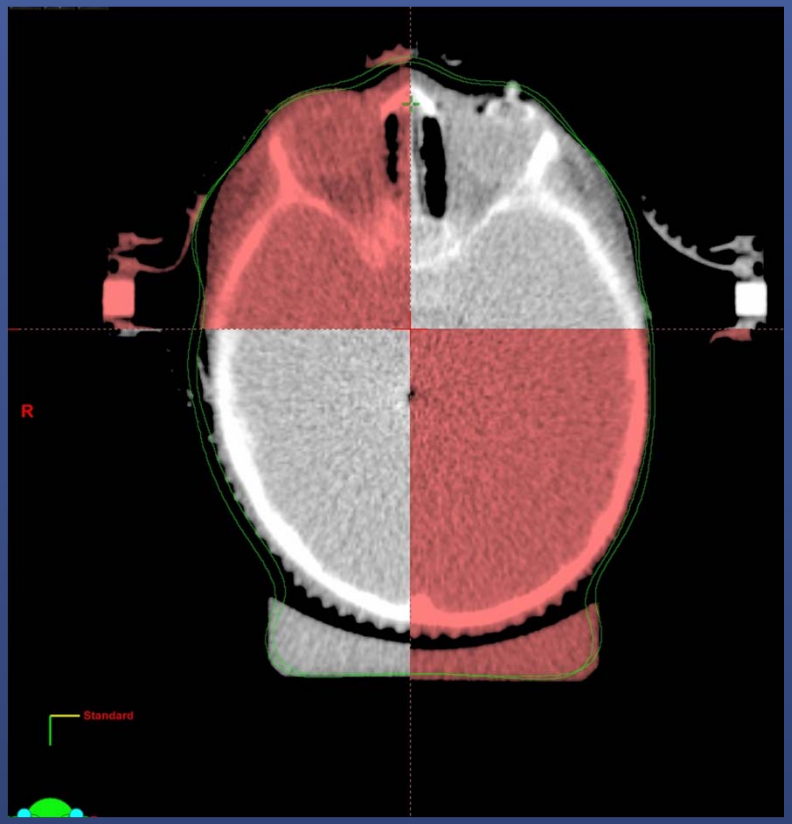

#3 Motion between images that must be analyzed together

Mitigation Strategy: Manage intrafraction motion, reduce time between images

Time delay between images that must be analyzed together

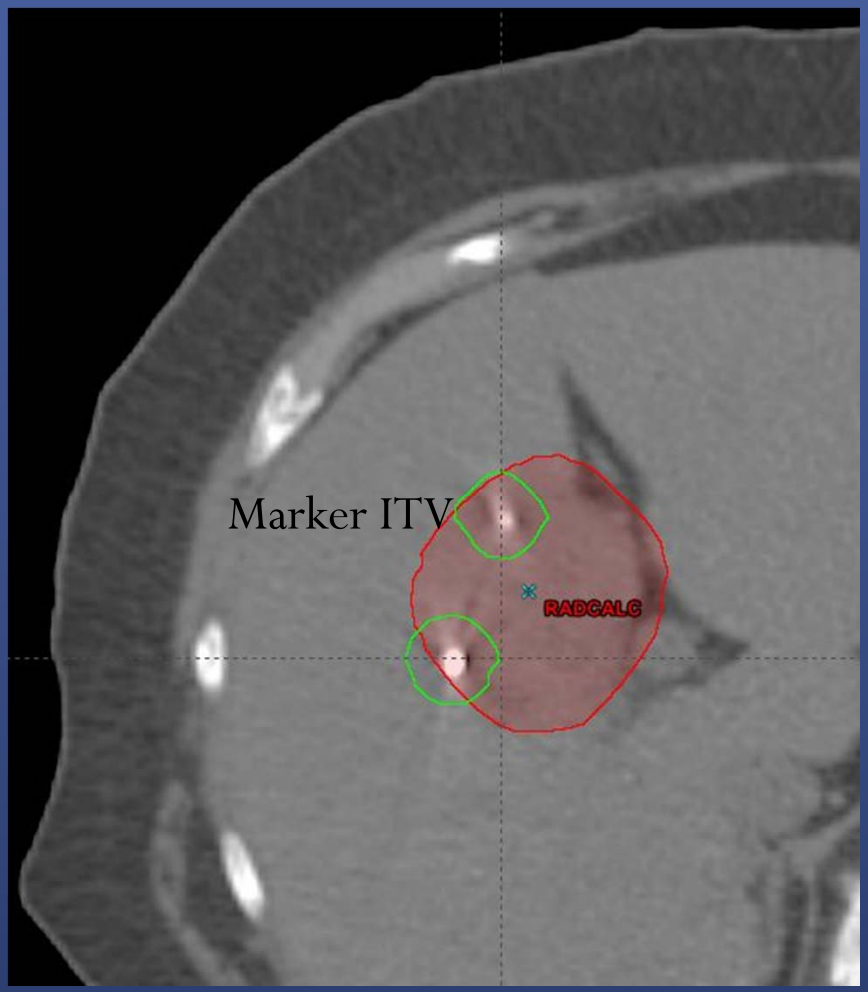

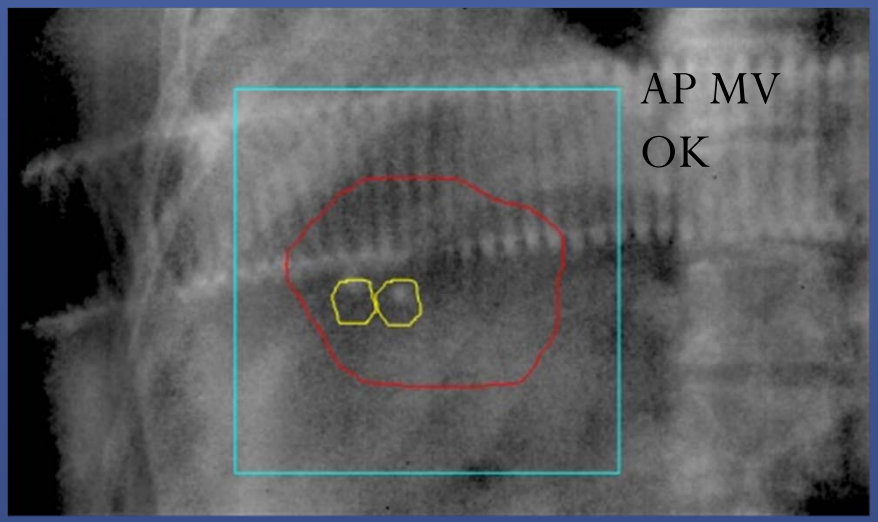



MV/kV pair to localize a liver target

#4 Reliance on Automatic Image Registration Algorithms

Suboptimal Image for Automatic Fusion in SRS

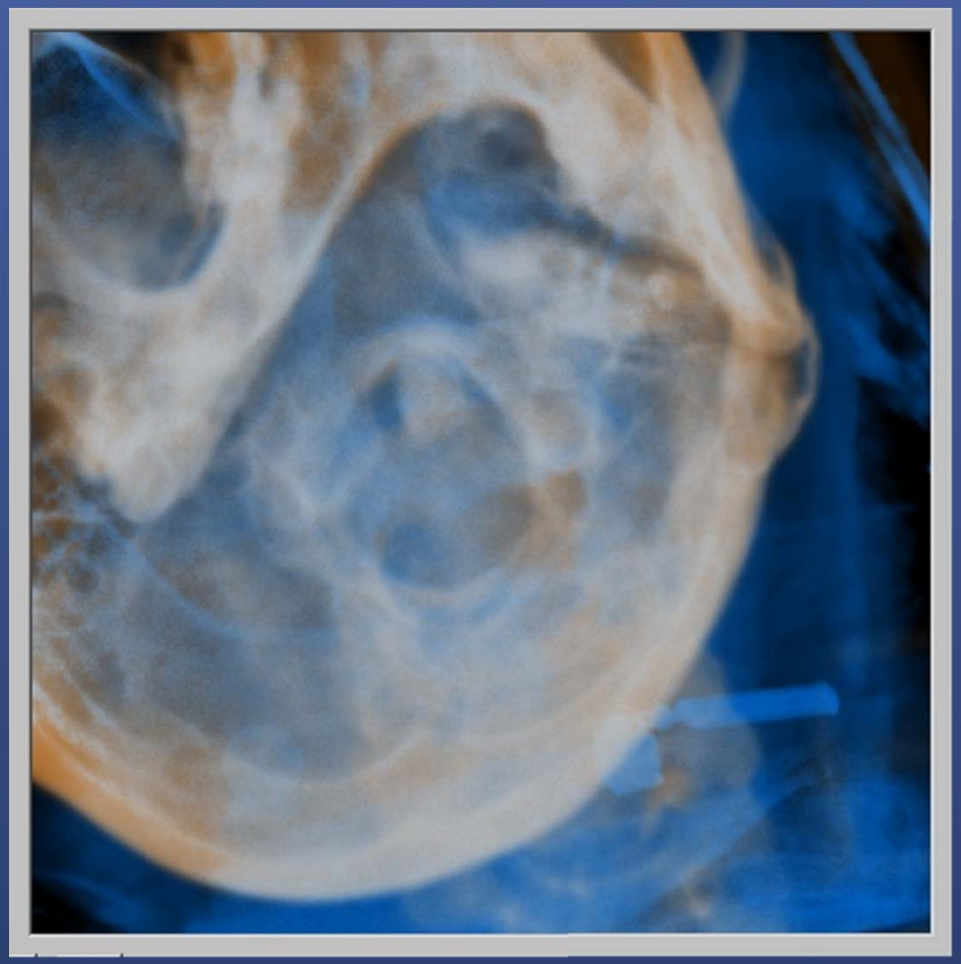

Jaw and neck are not rigid with respect to intracranial targets

Improving Automatic Fusion

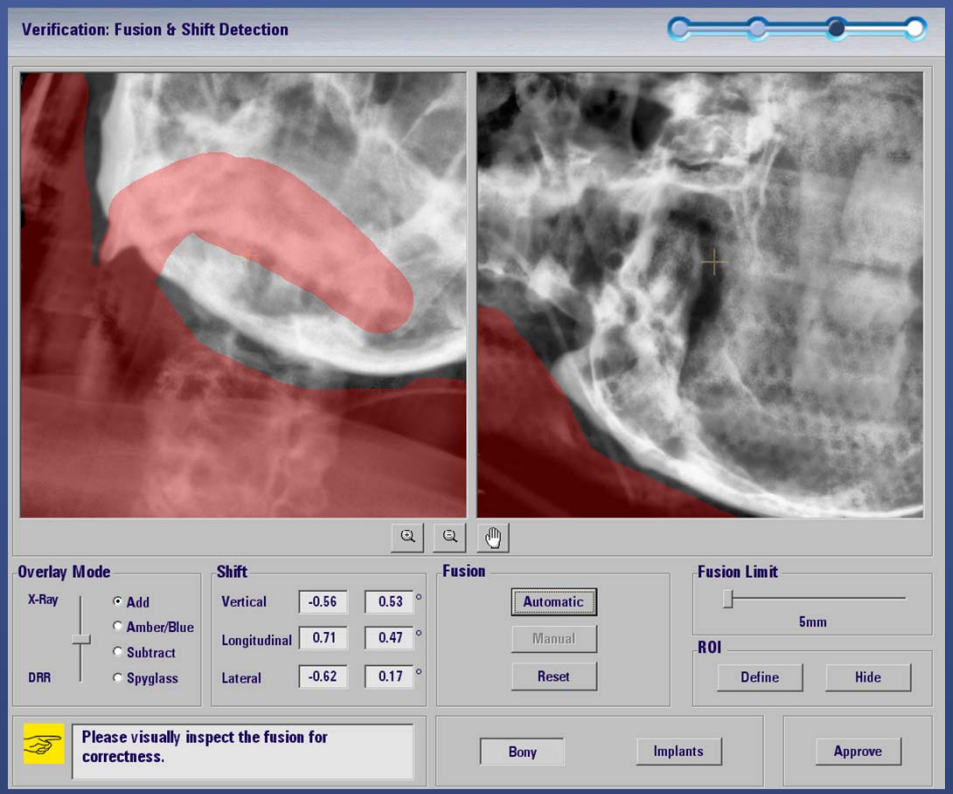

- Exclude areas of the image that are not useful
- Manual adjust fusion or position patient as well as possible before fusion
- Reduce region of interest (if possible)
- REVIEW FUSION RESULTS
- Use alternate imaging method

Automatic Fusion to Incorrect Vertebral Body

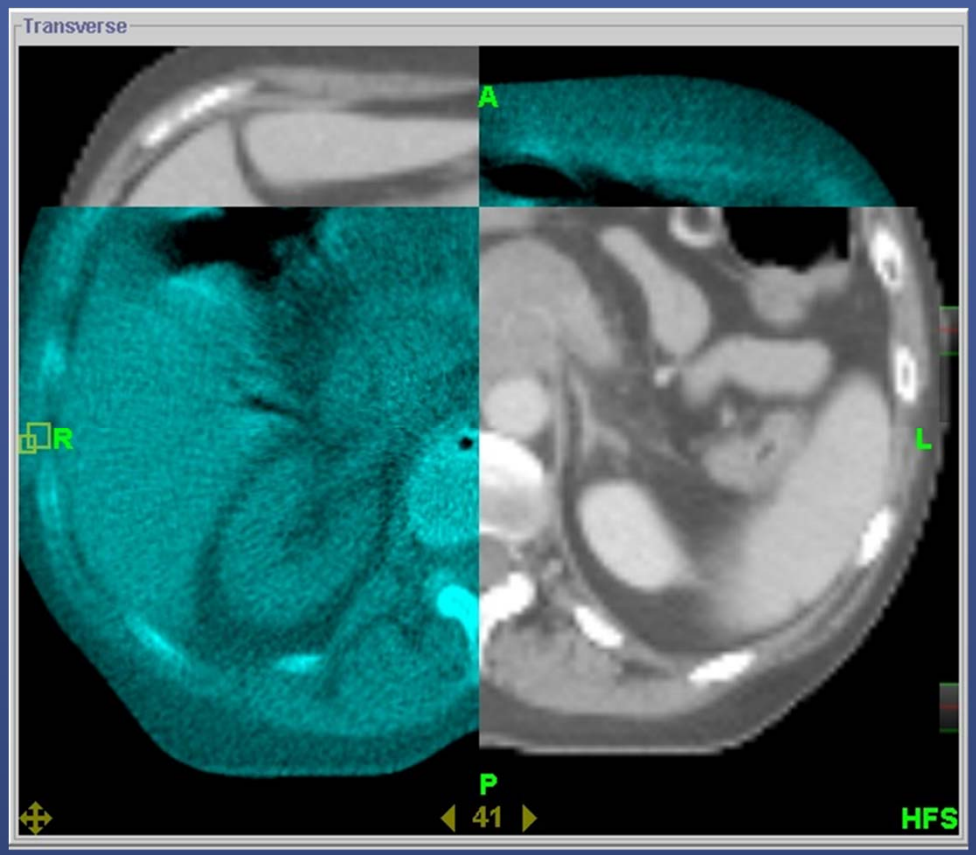

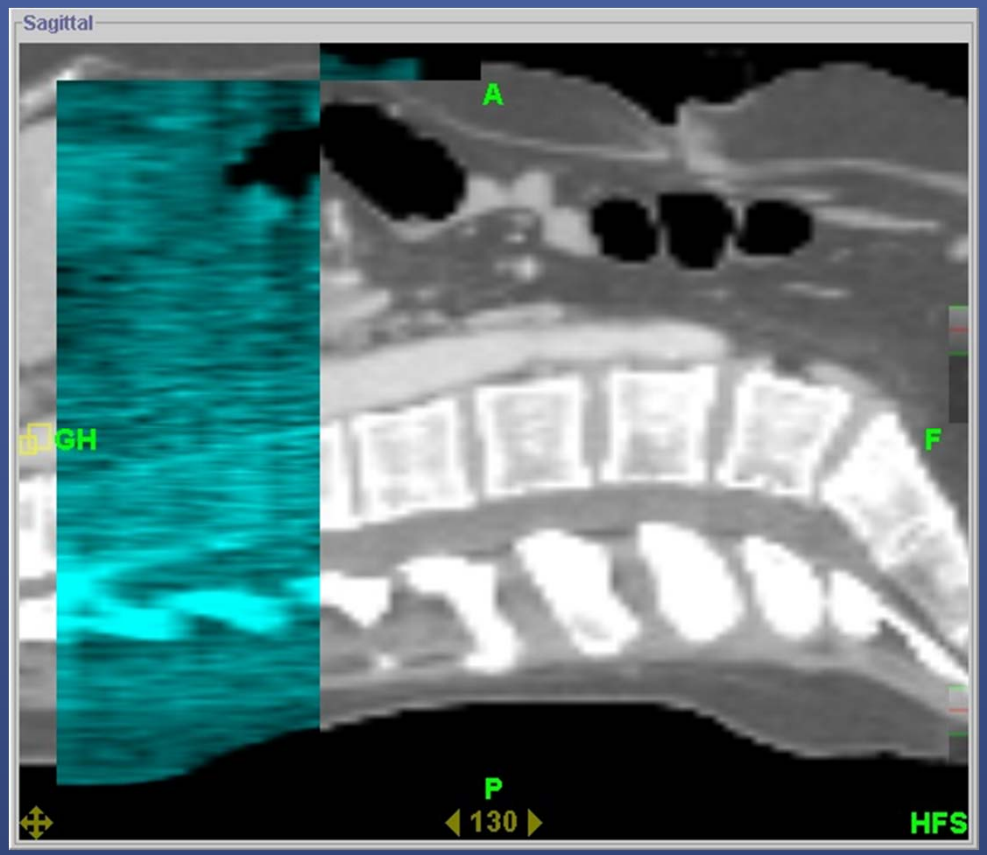

Investigate Large Shifts

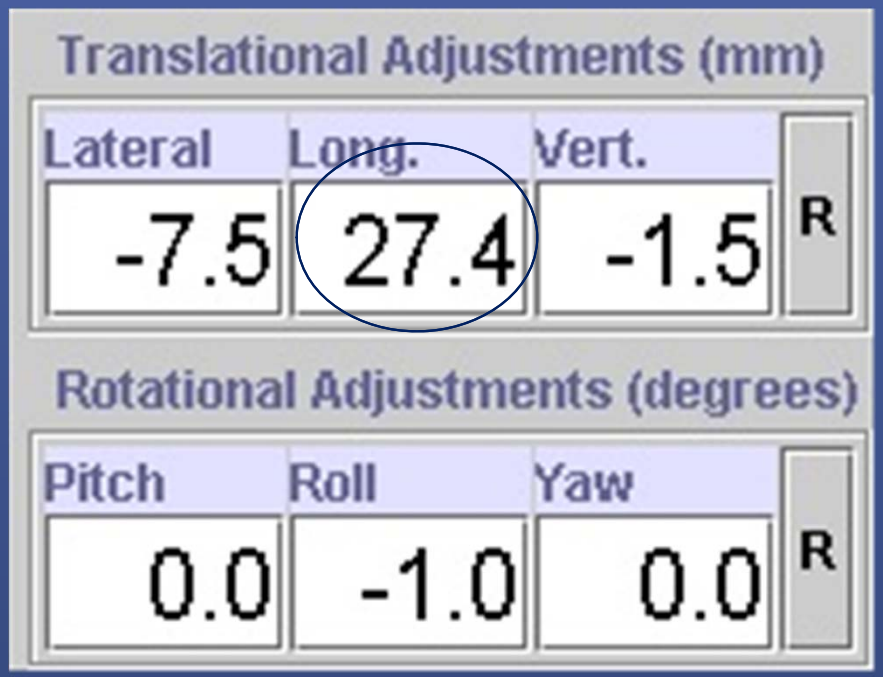

- Be skeptical of large shifts
- Set a threshold for physician intervention
- Use other anatomical features in fusion
- Add an artificial marker on patient
- Ensure scan length is long enough
- Ensure accurate setup prior to imaging

ROI Overlay to Detect Fusion Errors

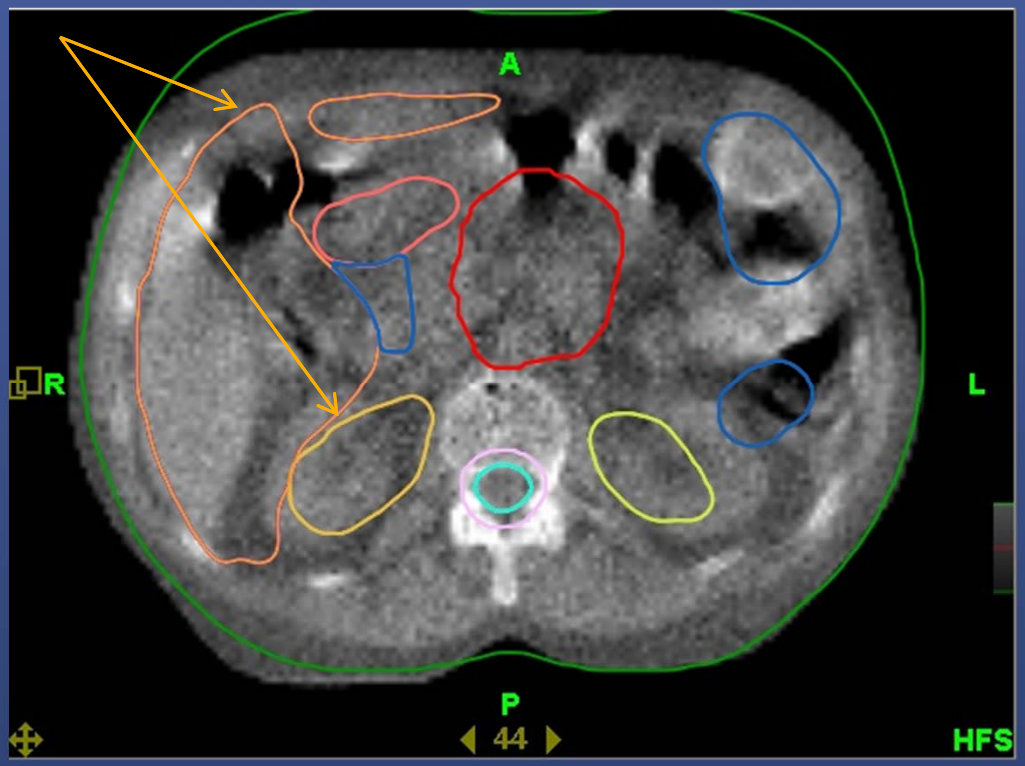

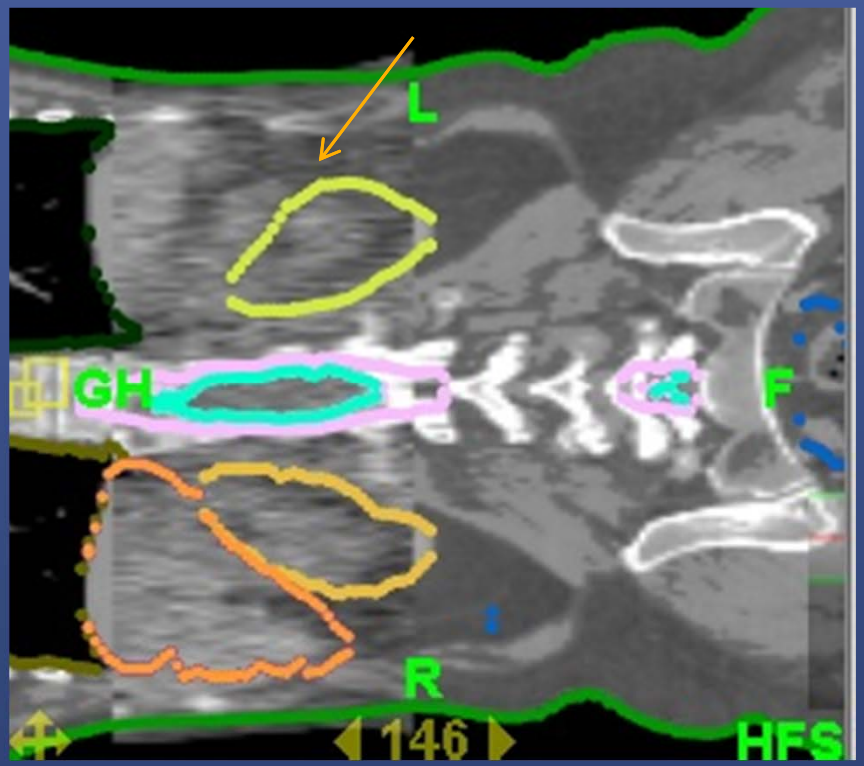

#5 Manual Image Registration

Manual Registration

- Have physicians clearly indicate where the target is and how to register the images (make a space in the electronic chart)
- Ensure that the scan region is optimal for fusion
- Use appropriate window and level, or presets
- Ensure images are reviewed by a physician
- Notify physicians of target deformations prior to treatment
- Designate a tolerance for physician intervention
- Set up site specific strategies and protocols
- Ensure consistent training of those performing the fusion

Physician Designate Fusion Order

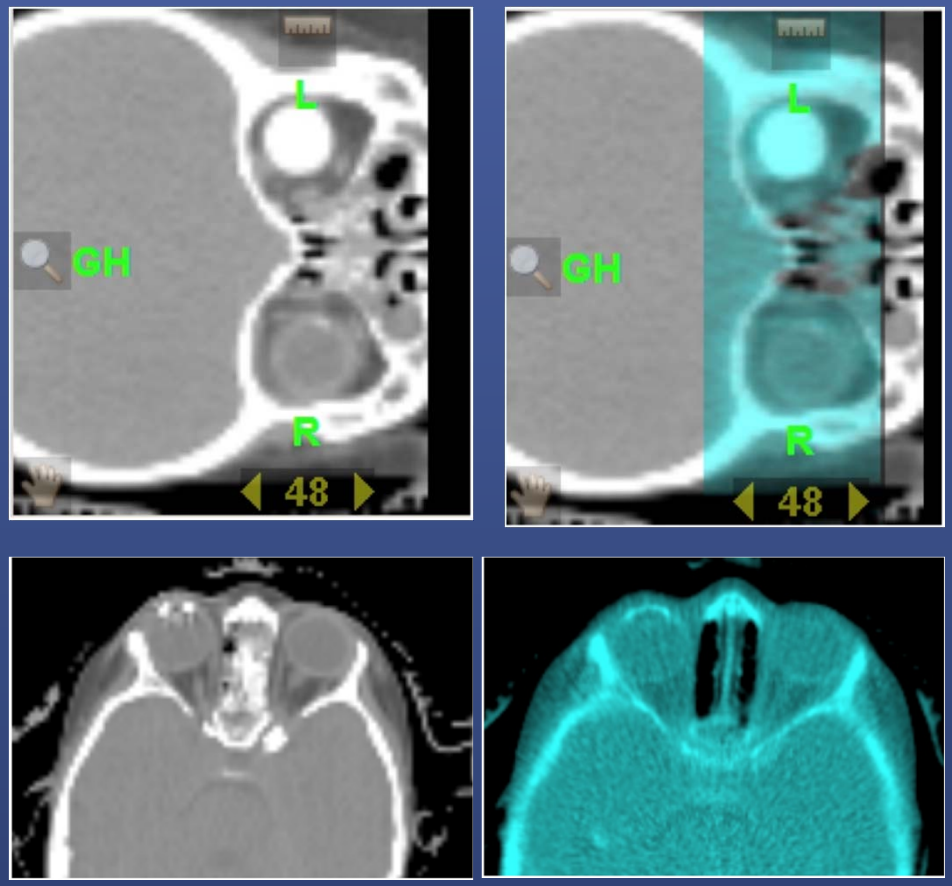

1. Tumor
2. Lens
3. Optic Nerve
4. Calcification
5. Entire Globe

Designate a tolerance for physician intervention

Santa Cruz Prostate Scanning Protocol

Prostate	
Matching Instructions 21) Begin with grey auto match 22) Zero rotations 23) Manually adjust to match seeds if available. If not, match prostate 24) Double check rectum interface.	**Clipbox** 
Structures to be sent Prostate Seminal Vesicles PTV Markers Bladder Rectum	**Scanning Presets** Prostate only ..... Prostate M10 F1 Prostate and nodes .... Prostate M15F1 **Scanning Limits** -180 deg – 180 deg
Frequency Daily for the first 10 fractions, then continue as directed.	

Courtesy of Wes Culberson

Santa Cruz Head Scanning Protocol

Head	
Matching Instructions 1) Begin with bone auto match 2) Zero rotations 3) Manually adjust to line up bony anatomy in the region being treated 4) Double check the cord and brain stem match.	**Clipbox** 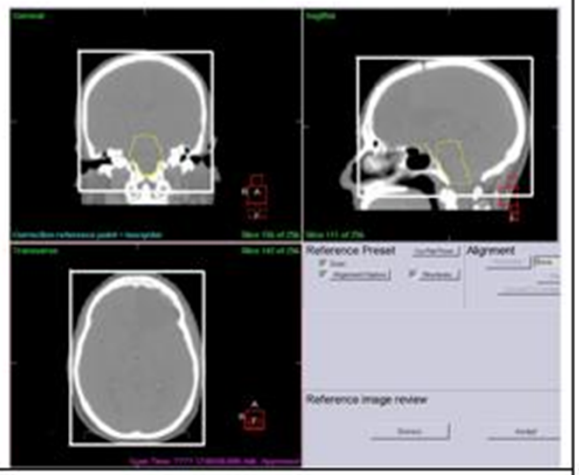
Structures to be sent Target (GTV, CTV, PTV) Spinal cord Brainstem parotids	**Scanning Presets** Head and Neck **Scanning Limits** 255 deg – 100 deg
Frequency Daily for first five fractions, then continue as directed	

Courtesy of Wes Culberson

Notify Physician of Anatomical Changes

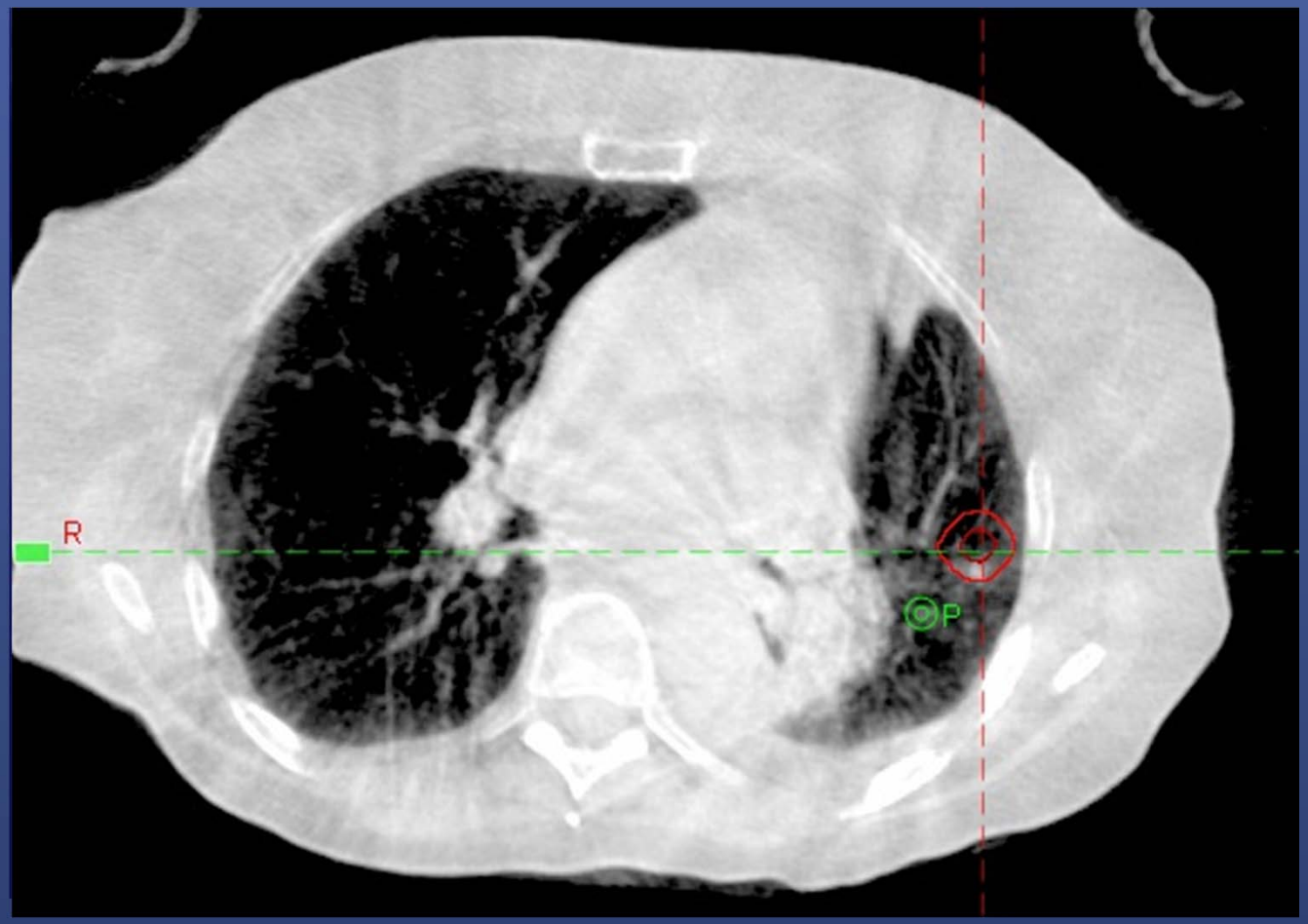

#6 Use of Surrogates

Choice of Surrogate

- Use surrogates when cannot see the target but can see something else
- Examples:
  - Boney Landmark
  - Neighboring structure
  - Implanted fiducial
  - Surgical clips
  - Calcification
- Best Features:
  - Visible
  - Rigid wrt target
  - Close to or within target
  - Should not cause excessive artifact
  - Should be identified by physician prior to image fusion

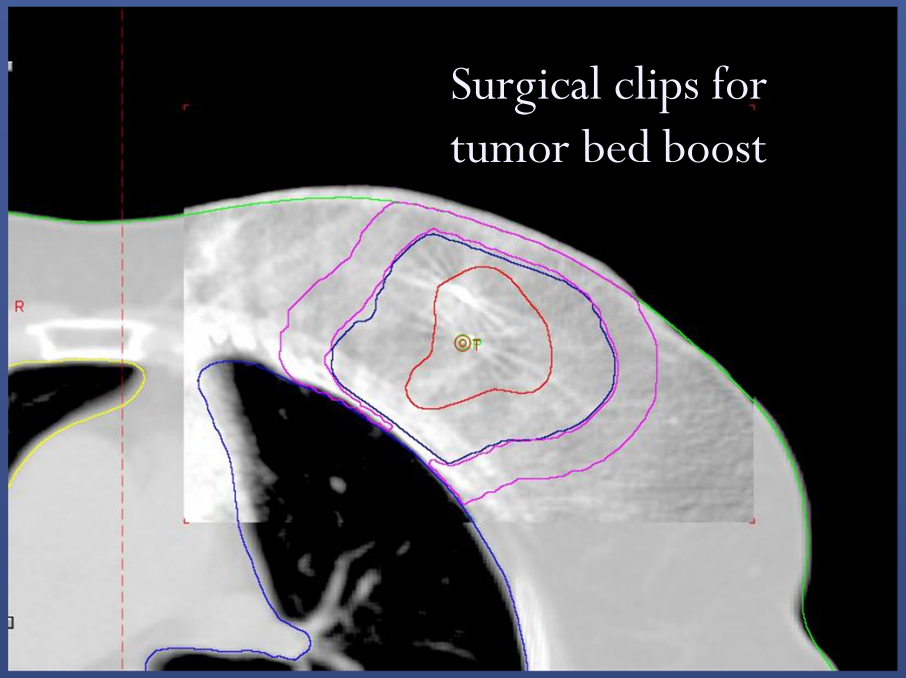

Artifact from Implanted Fiducial

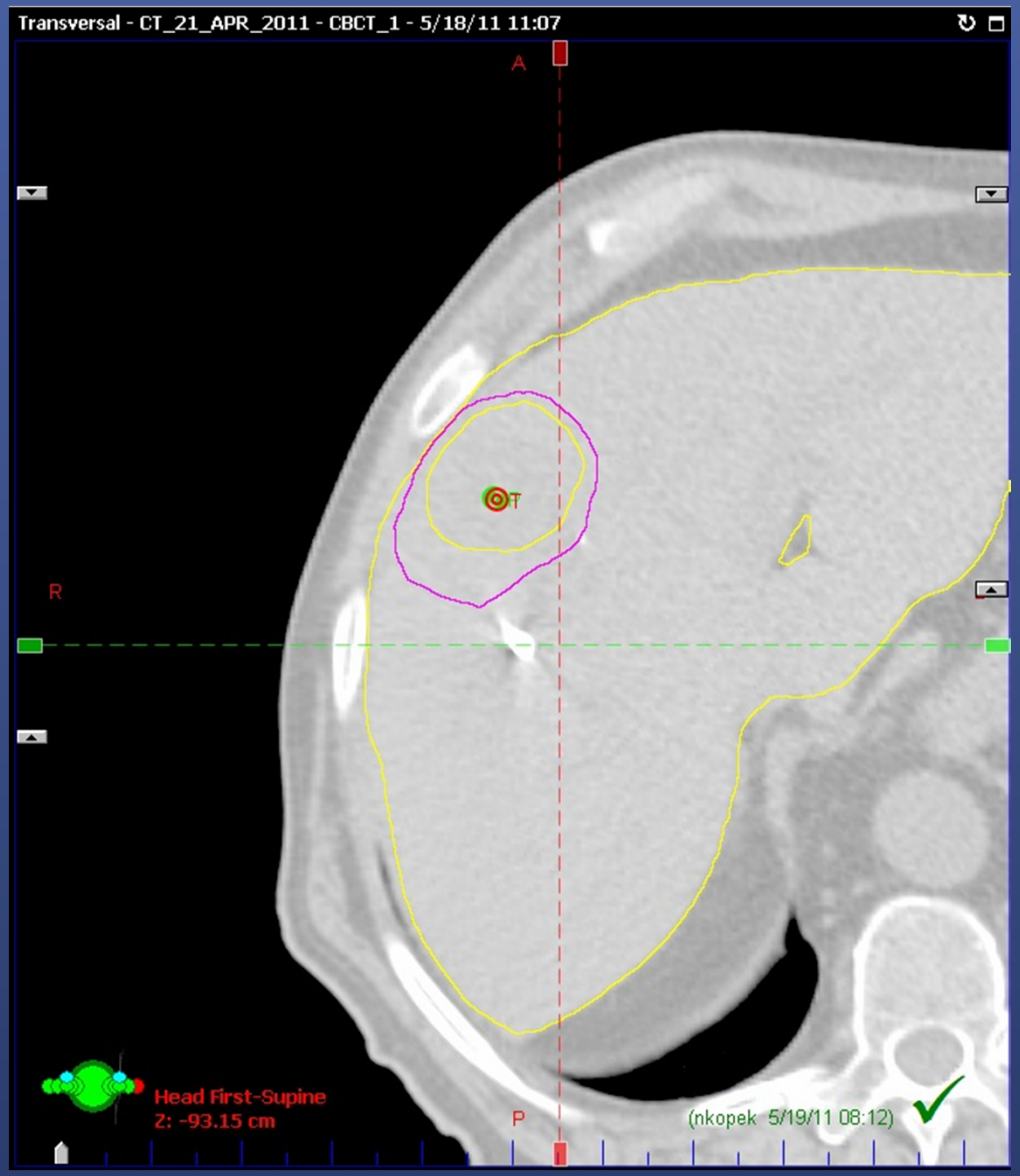

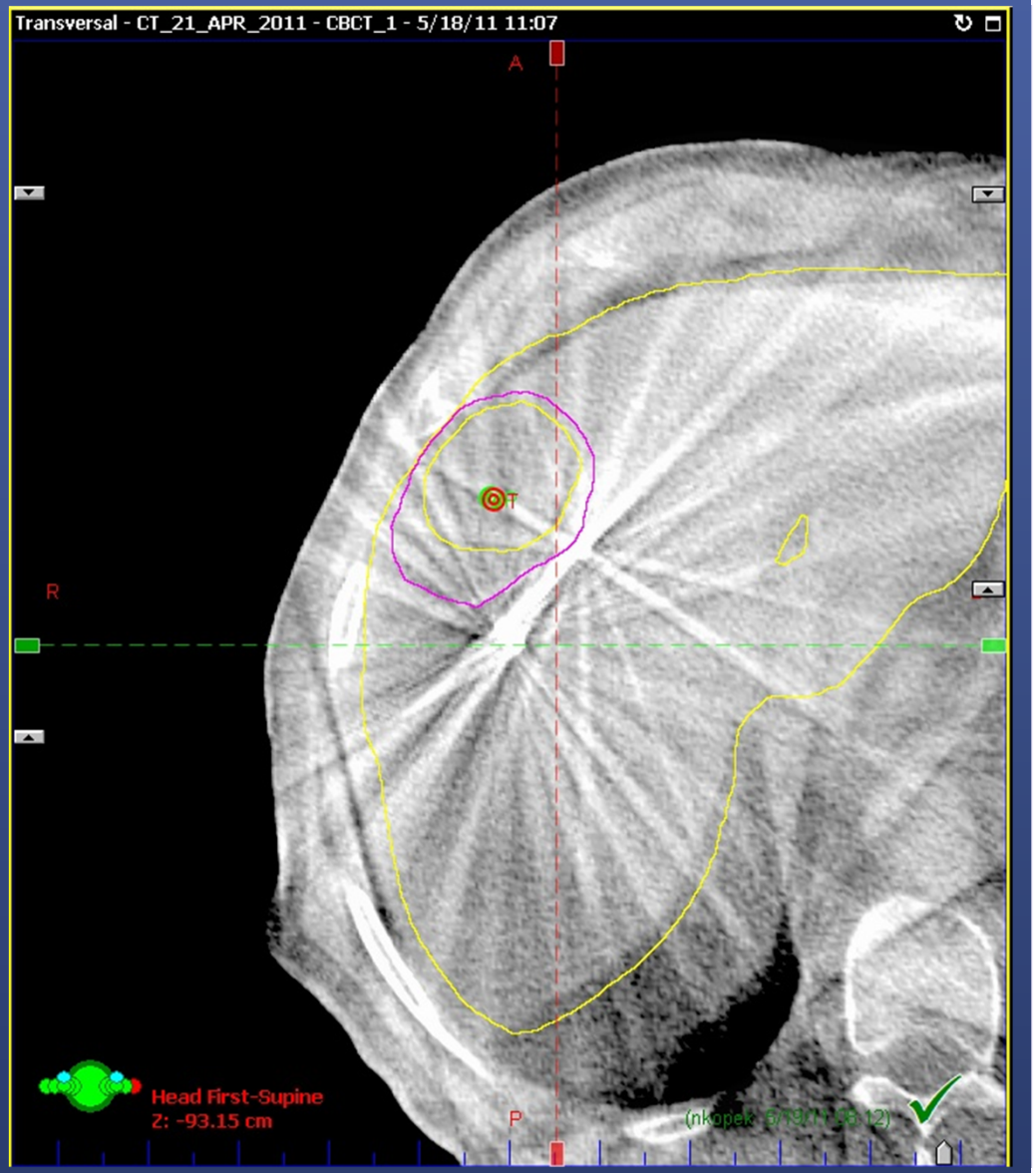

Surrogate Must be Visualized

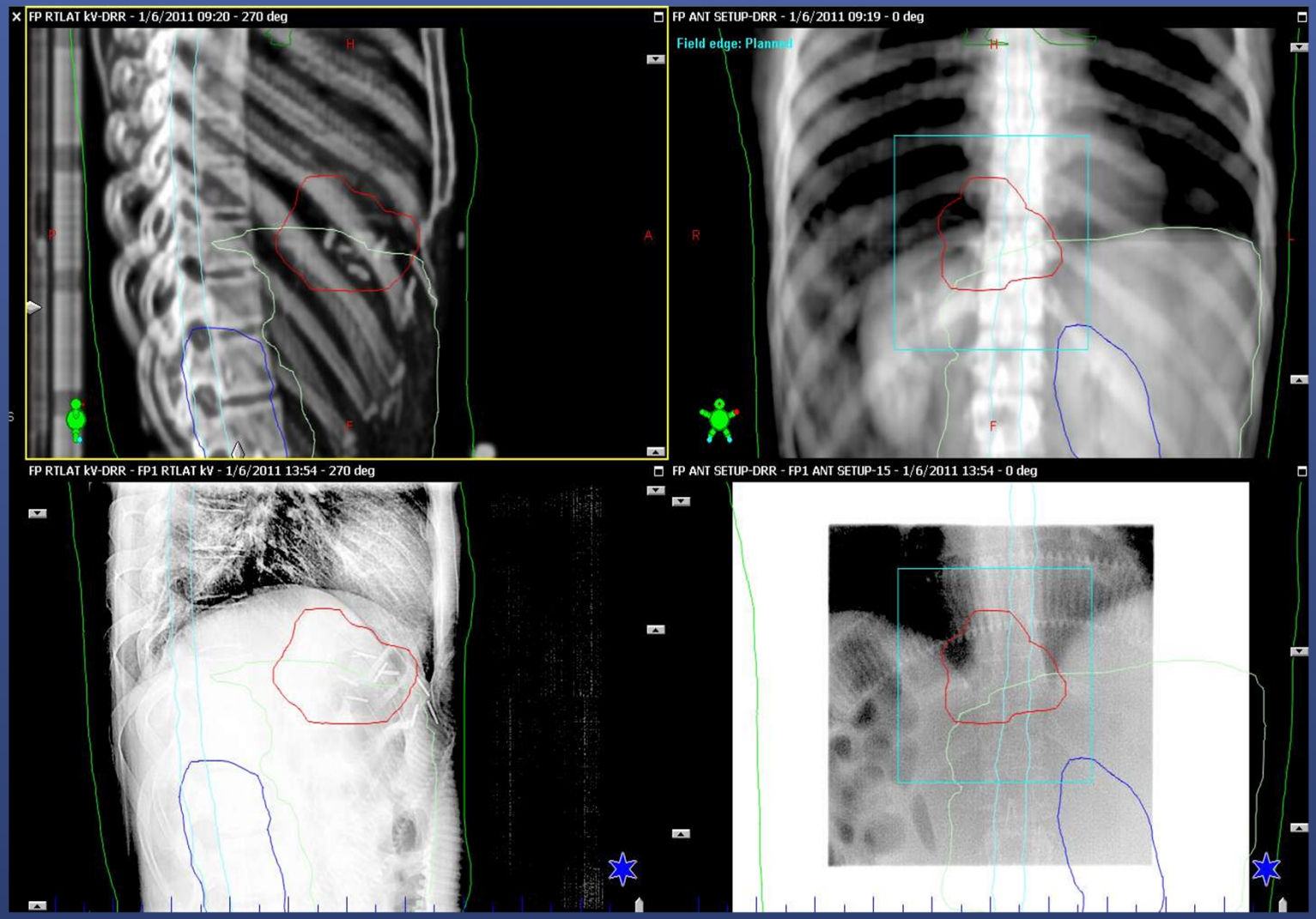

Surrogate Should Not Migrate

- Time from marker placement to CT important
- Marker matching will not work if markers move

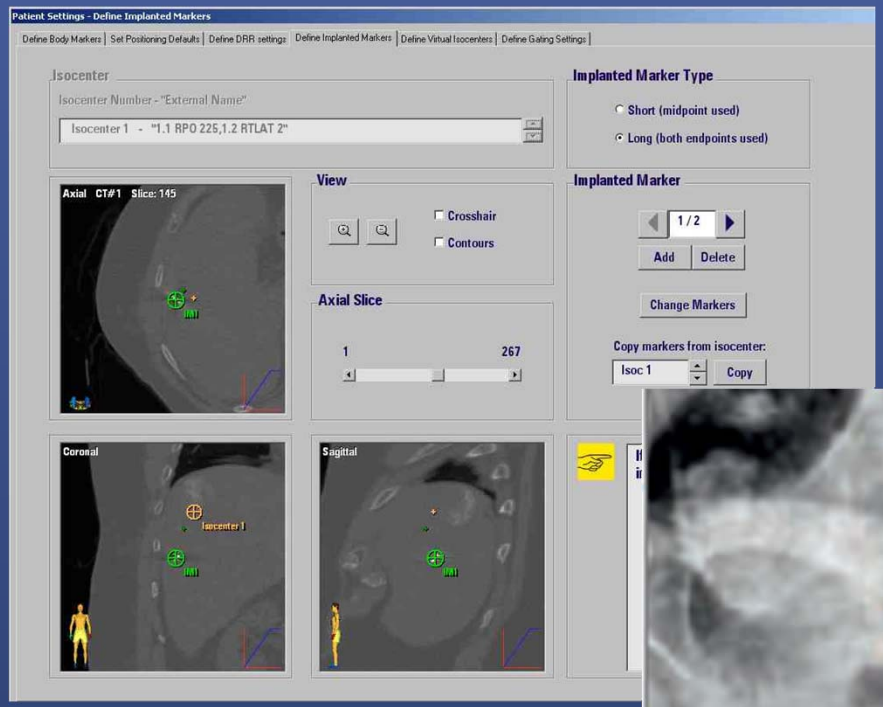

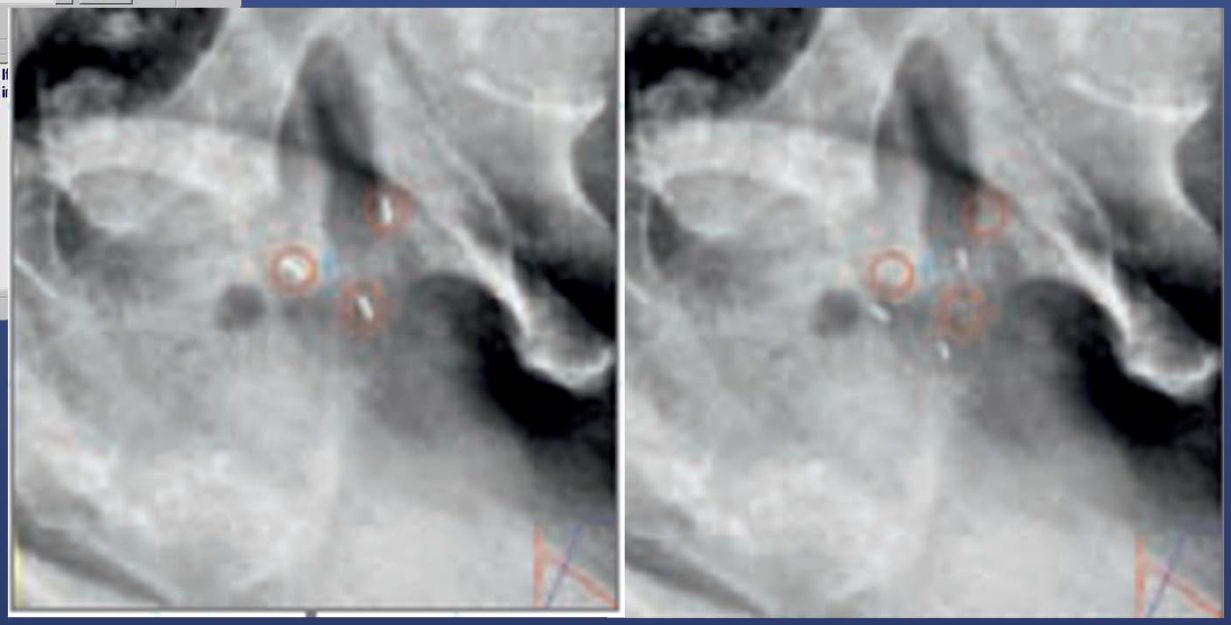

#7 Software Errors

Mitigation Strategy: Know then exist and create proper QA steps to catch them (specific to your systems)

Uncertainty with Image Centering

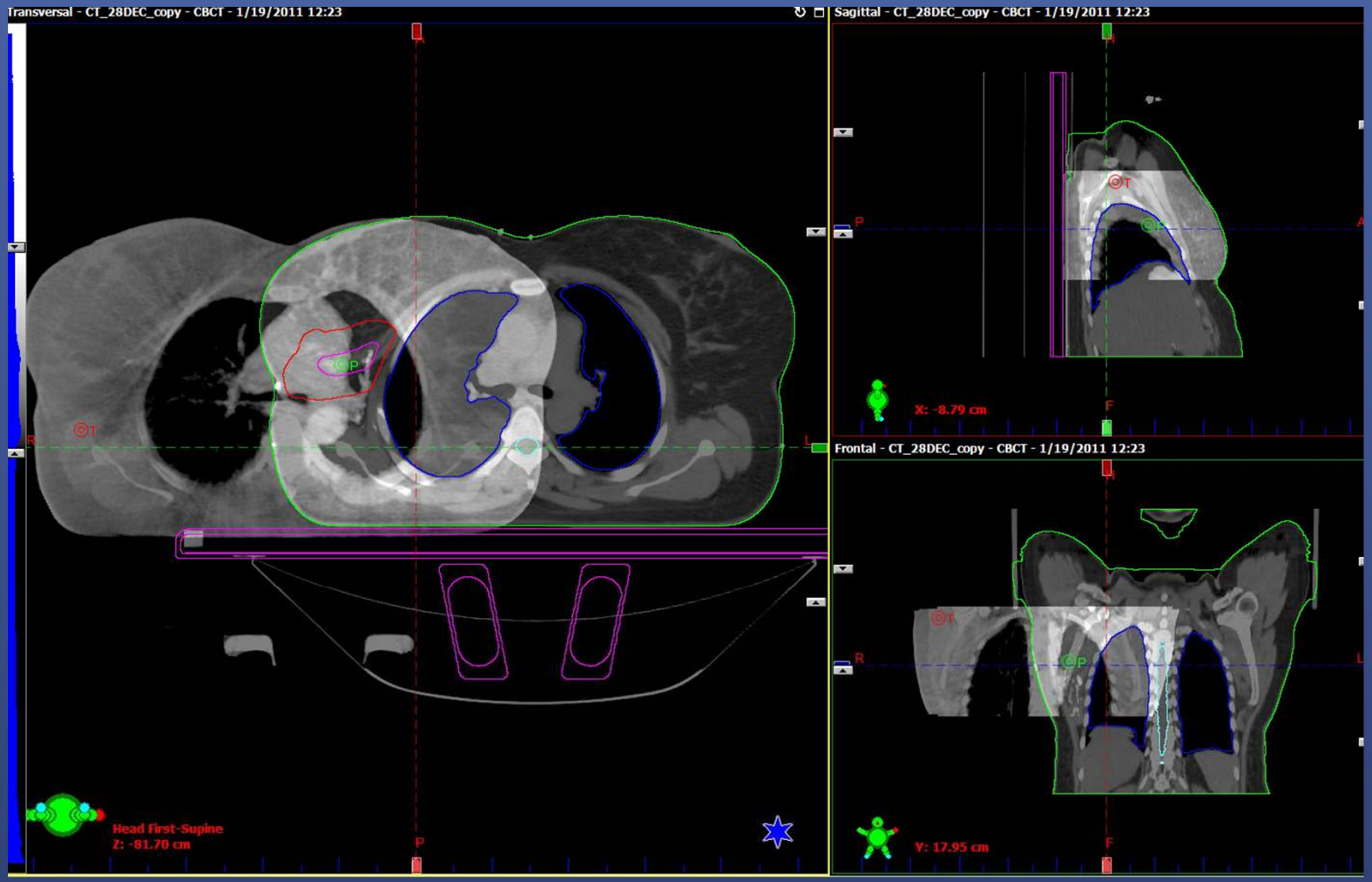

Patient actually in the correct position but software thinks the patient has not been recentered

Erroneous Shift

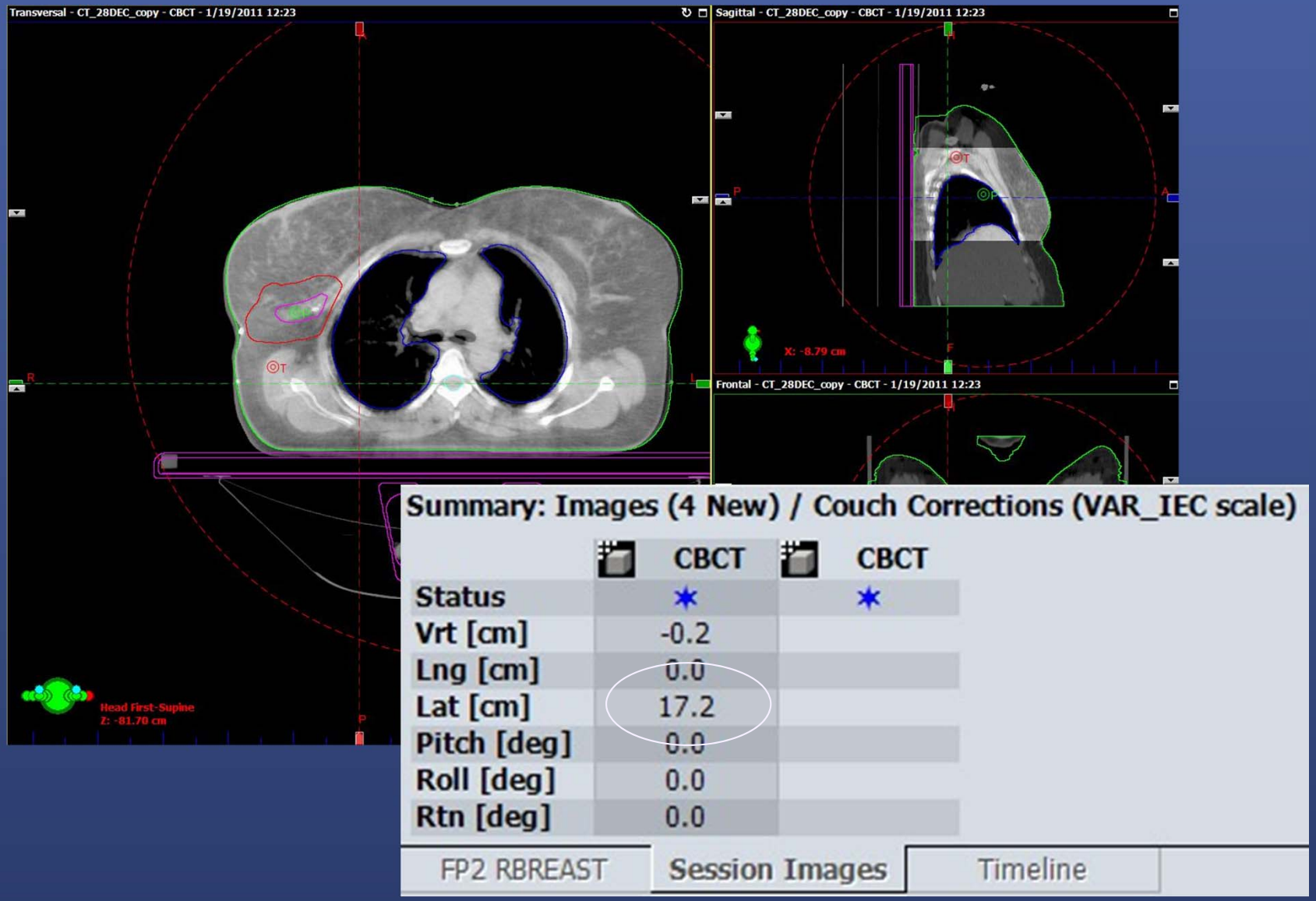

Errors in Images Presented for Physician Review

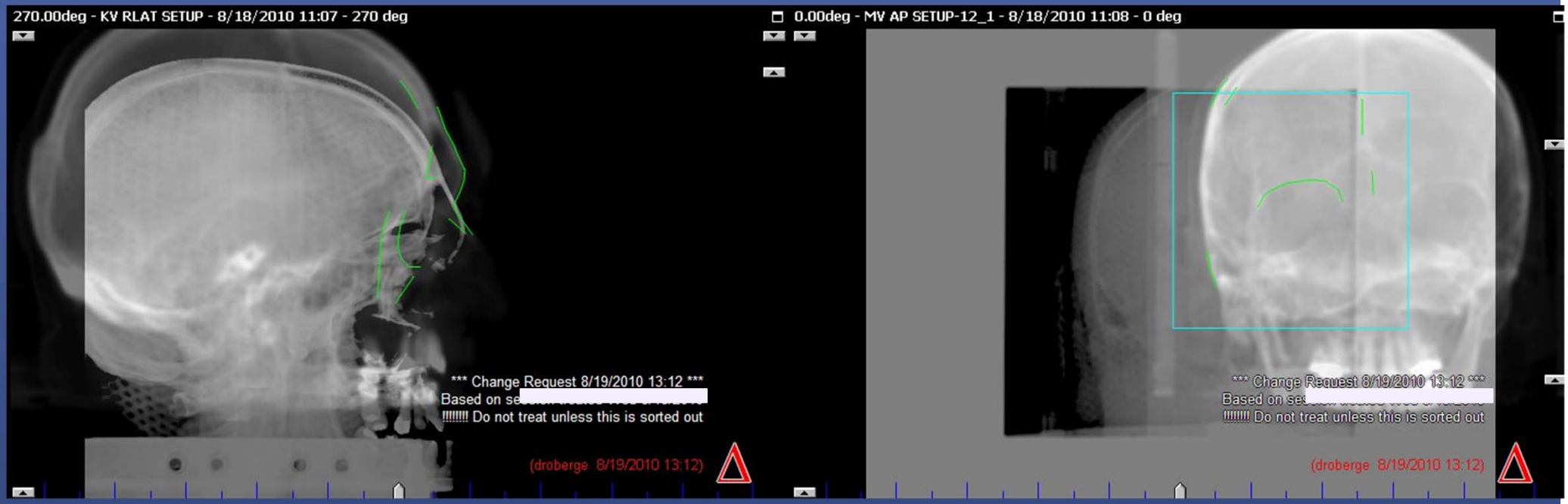

Image shifted for first treatment field in software before export. Patient in correct position.

Wrong CT Used for Localization

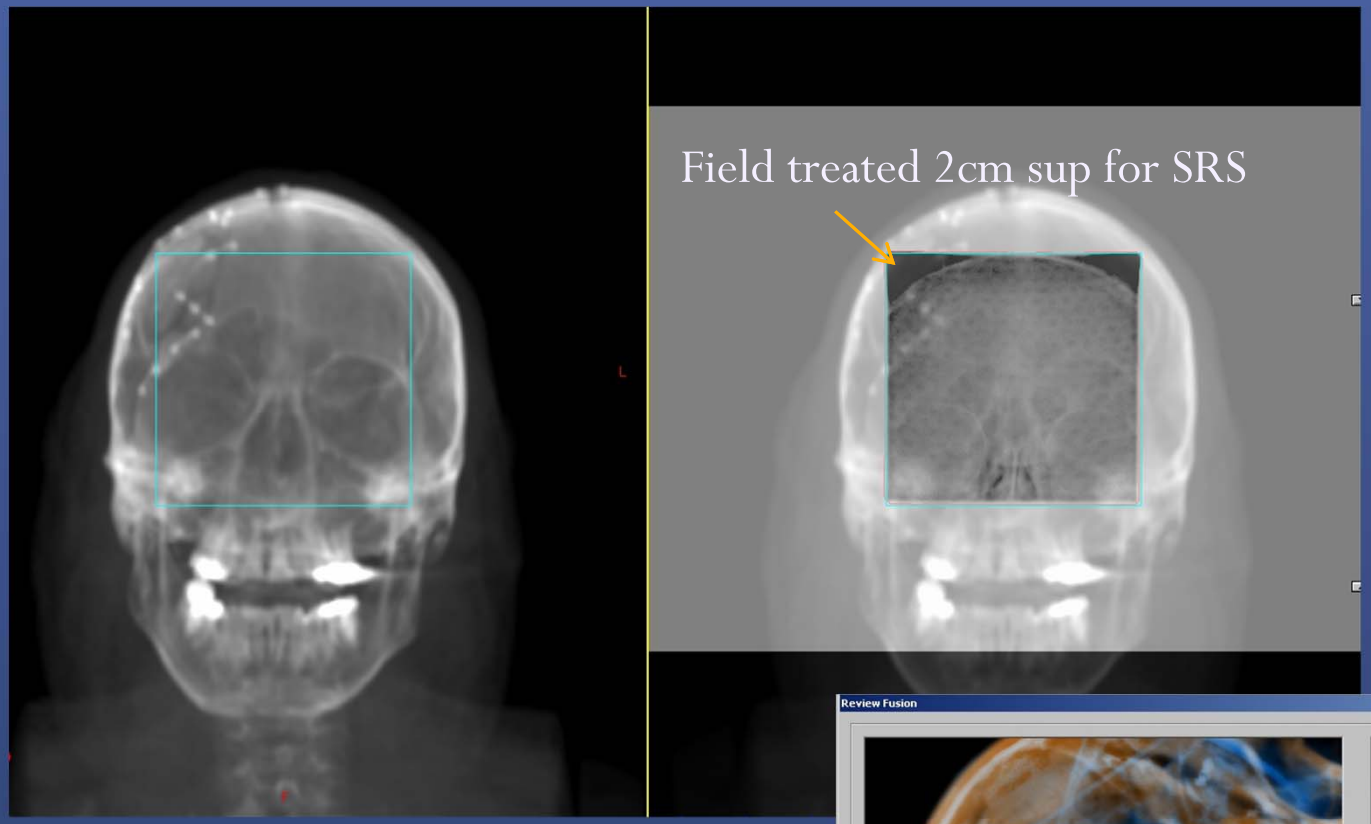

Image with a second modality

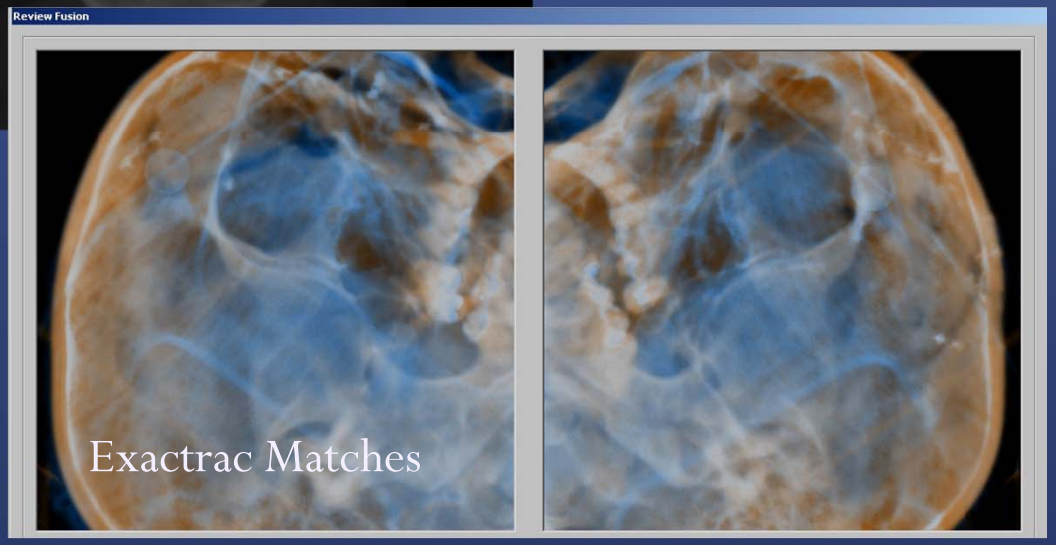

Studying Interfraction Setup Uncertainty Internally

- Use image guidance to determine setup error
- Tabulate daily shifts for a large number of patients
- Determine if PTV margins are appropriate
- Determine if image guidance is necessary (and frequency)
- Determine if adaptive replanning strategies should be adopted

Daily imaging for Breast Boosts

- Purpose: To determine if daily image guidance is necessary for patients receiving RapidArc plans for breast boosts
- Shift data collected for the first 20 patients (translations)
- Conclusions:
  - Average shifts are small in all direction (Average 0mm, Range (-8mm-+7mm), SD 3mm)
  - With daily guidance PTV margins are too large
  - Without daily guidance PTV are more than adequate (2SD (6mm) <margin (10mm))
  - Shifts greater for larger patients

average		
VERT	LONG	LAT
0.0	-0.4	-0.2
0.1	0.5	-0.2
-0.1	0.1	0.2
-0.7	0.0	0.3
0.0	0.3	-0.2
0.1	0.7	0.5
0.1	0.0	0.1
-0.1	-0.4	0.2
-0.3	0.0	-0.4
0.6	-0.1	-0.3
0.1	-0.2	0.3
-0.2	-0.4	0.5
-0.1	-0.5	0.4
0.2	-0.2	0.0
-0.8	-0.3	0.0
0.0	0.2	0.2
		0.3
		0.2
		0.0
		-0.1

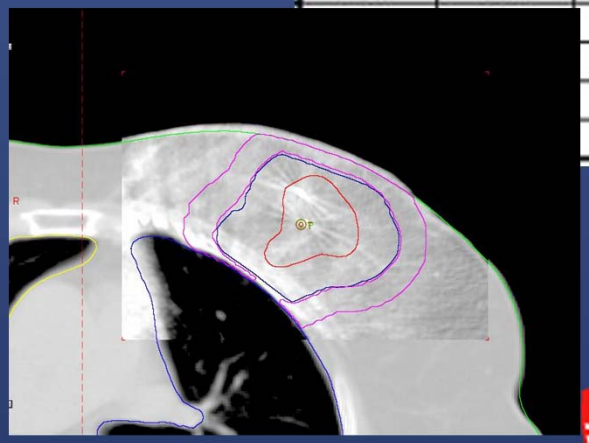

Results courtesy of Aleksandra Lazicic, RTT

Tumor Kinetics in Sarcoma Patients

- 10 patients with Myxoid Liposarcoma treated on Tomotherapy
- Shifts data collected for all treatment fractions
- Results
  - Tumors enlarge from simulations to treatment (11-27 days, mean 8%, max 25%)
  - Tumor size stable for two weeks and then decrease steadily for the remaining fractions(36% average, 8%-61% range)
  - Average rate of shrinkage $6cm^3$/day
  - 4 of 10 patients required replanning
- Conclusions:
  - Myxoid Liposarcoma patients should receive daily image guidance
  - Should be re-assessed for replanning at week 3 of treatment
  - Interval from simulation to treatment should be reduced

Early results courtesy of Dr. Siavosh Vakilian

Tumor Progression: Sim to 1st Fx

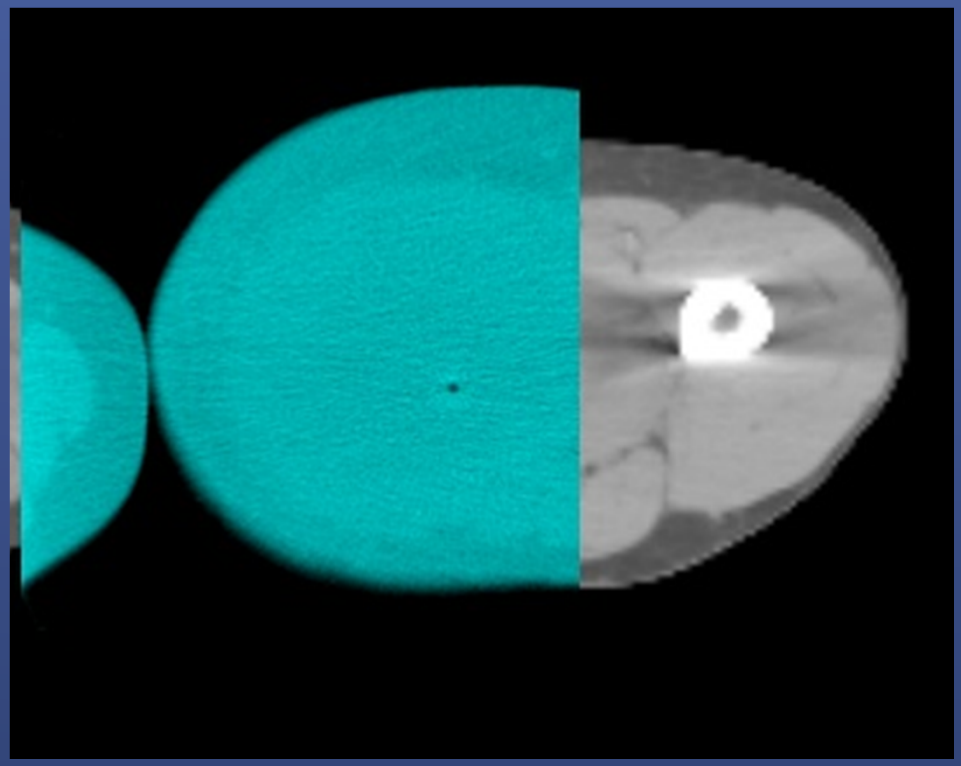

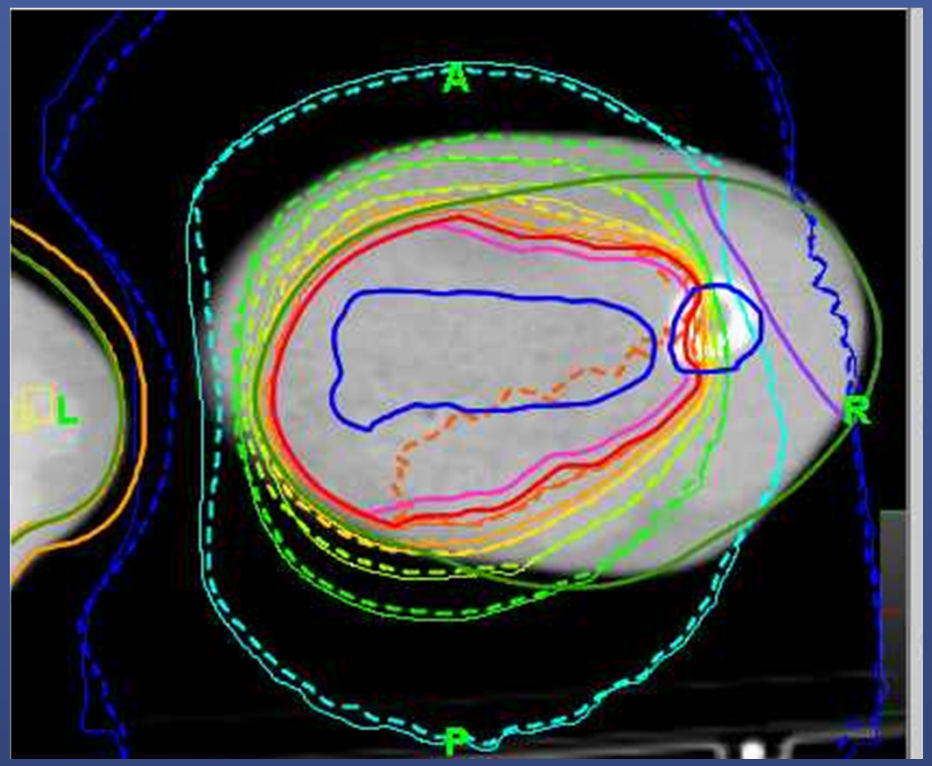

Determine Imaging Frequency

IGRT Review Statistical Analysis

Patient:
ID:
Physician:
Date of Review: 11/12/2010

	Sup (cm)	Lat (cm)	Ant (cm)
1	1.1	0.3	0.4
2	0.9	0.7	-0.1
3	0.4	0.9	0.2
4	-0.3	-0.8	0.0
5			
6			
7			
8			
9			
10			

Average Shifts	**0.5**	**0.3**	**0.1**
1σ	0.6	0.8	0.2
2σ	1.2	1.5	0.4

(if these values are less than planning margin, consider reducing imaging frequency)

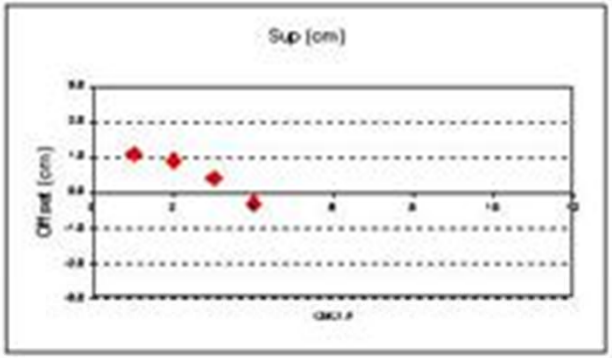

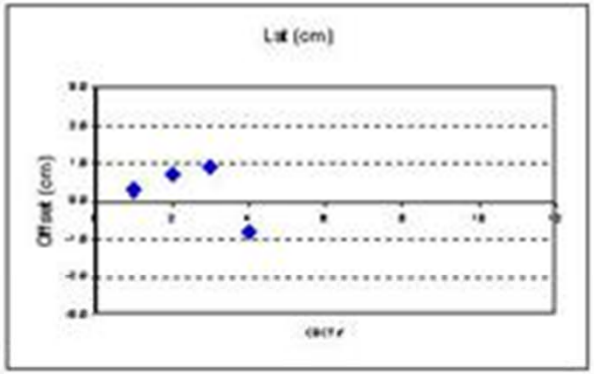



Courtesy of Wes Culberson

Conclusions

- Physicists can play a role in mitigating interfraction setup uncertainty
  - Help to optimize image quality
  - Review simulation procedures
  - Implement electronic charting/forms
  - Use image guidance to study interfraction motion internally
- Imaging does not solve everything
  - Setup precision prior to imaging is still important
  - Sometimes you can't see and your setup is no more certain with imaging than without

Thank you for your attention!

Anatomical Variation

Uncertainties Due to Anatomical Variations

- Pelvis
  - Bladder/rectal filling
  - Diarrhea
- Abdomen
  - Digestion
  - Respiration
- Thorax and Breast
  - Flaccid/pendulous breasts
  - Atelectasis
- Head and Neck
  - Extreme weight loss
- Brain and Ocular
  - Motion with respect to mask
  - Voluntary motion

Weight loss
Obesity

Disease Progression
Tumor Response

Reducing Interfraction Pelvis Motion

- Constant bladder filling
  - Drink 2 glasses of water
  - Void before treatment
  - Avoid unexpected wait times
- Empty rectum
- Rectal Balloon
  - Immobilizes prostate
  - Constant rectal volume
- Dietary Intervention
  - No fiber to reduce gas
  - Manage diarrhea
- Body mold
  - Less variation than lying on the table

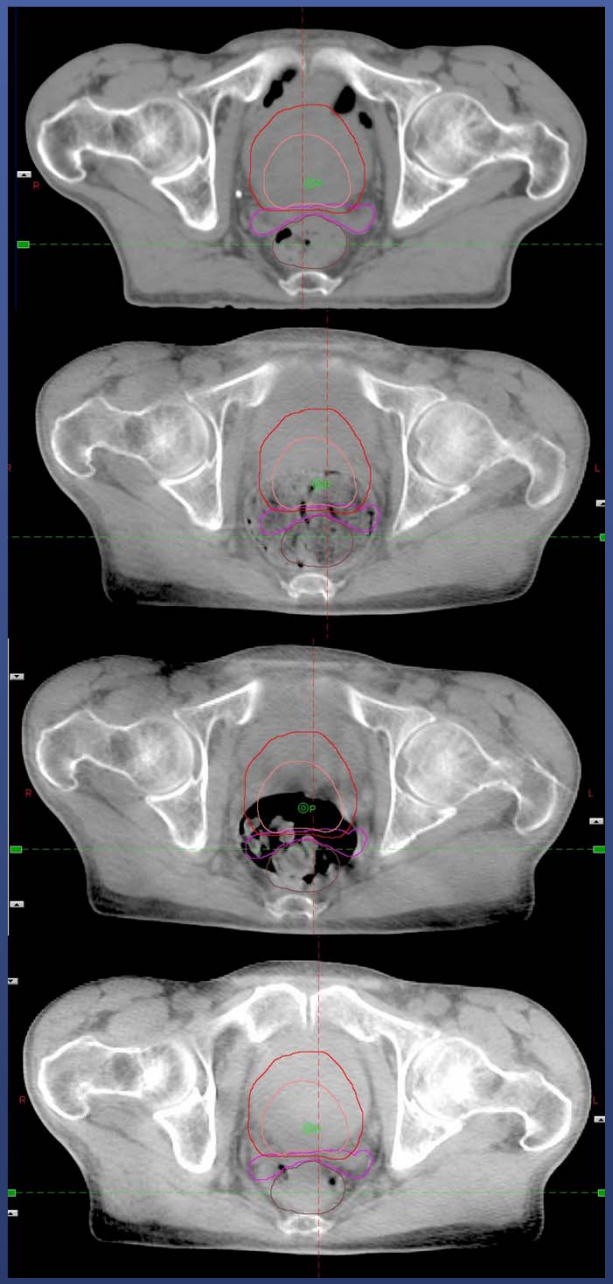

Reducing Breast Positioning Uncertainty

- Index Breast Board
  - Small to medium breasts
- Body mold
- Tolerable/reproducible arm position
- Prone Position
- Custom bra-type devices or thermoplastic

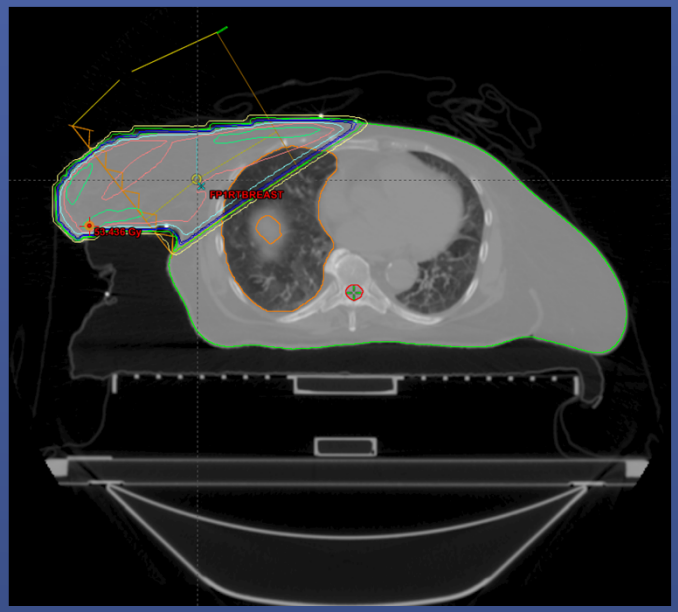

Reducing Thoracic Motion

- Control respiratory motion AMPLITUDE
  - Gating
  - Vaccuum mold (abdominal compression)
- Reproducible arm position
- Body mold (indexing)
- Image to note anatomical changes (atelectasis, pleural edema)

Anatomical Changes Noticed with Image Guidance