The Challenges Associated with Differential Dose Delivery using IMRT

Helical Tomotherapy Experience

Chester Ramsey, Ph.D.
Director of Medical Physics
Thompson Cancer Center
Knoxville, Tennessee, U.S.A

Collaborators
Chester Ramsey, Ph.D. (TCSC)
Ben Robison, M.S. (TCSC)
J. Wesley Hines, Ph.D. (Univ. of TN)
Dustin Garvey, Ph.D. (Univ. of TN)
Scott Outten, M.S. (TCSC)



Helical Tomotherapy Experience

- TomoTherapy
- Whole Brain
- Head & Neck
- Prostate
- Lung
- Summary

HI-ART TomoTherapy System



- Helical tomotherapy is the fusion of a Radiation Therapy Linear Accelerator and a Helical CT Scanner
- Patients are treated with an intensity modulated fan-beam
- The linac is mounted on a slip-ring that allows continuous rotation around the patient
- The system rotates once every 15 to 60 seconds depending on the dose and the degree of intensity modulation

HI-ART TomoTherapy System

Siemens 6 MV Linac

- Treatment Nominal Acceleration Potential: 3.6 MV (6 MV Max)
- MVCT Nominal Acceleration Potential: 2.6 MV (6 MV Max)

Primary Collimator



- Independent Primary Jaws in the Superior - Inferior Direction
- Symmetric or Asymmetric Slice Thicknesses of 5-mm, 10-mm, 25-mm and 50-mm

HI-ART TomoTherapy System

MLC Characteristics

- The binary MLC has 64 leaves that are either open or closed
- The MLC is pneumatically driven, and the leaves have a 5-20 msec transit time (depending on the field size)
- For clinical cases, there are 51 projections (i.e. segments) per gantry rotation
- MLC controller files can be created manually or automatically during the inverse planning process

HI-ART TomoTherapy System

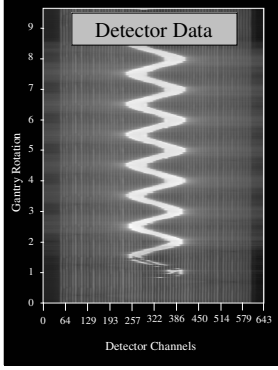

Detector Characteristics

- The detector used in the tomotherapy system is an arc-shaped CT detector array
- The detector array consists of 738 cells with a 0.73 mm width at isocenter
- Each cell is comprised of two gas cavities that are divided by thin tungsten septal plates 2.54 cm long in the beam direction
- The gas cavities are filled with xenon gas under high pressure
- Every odd plate has a high-voltage of 1300 V applied, and the even plates act as charge collecting electrodes for the charge produced in the gas cavities

Helical Tomotherapy Experience

- TomoTherapy
- Whole Brain
- Head & Neck
- Prostate
- Lung
- Summary

Case Study: Whole Brain / Boost

- The most common intracranial tumors in adults are Brain Metastases
- Whole-brain radiotherapy and steroids represent the mainstay of management for patients with a diagnosis of brain metastases
- In this case study, helical tomotherapy was used to deliver 32.3 Gy (*2.2 Gy/fx*) to the whole brain and 63 Gy (*4.2 Gy/fx*) to the visible metastasis*

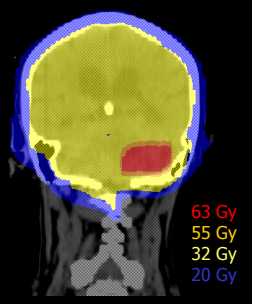

** Ghia et al. IJROBP (In-Press)*

Case Study: Whole Brain / Boost

- The brain was automatically contoured using Pinnacles Model Based Segmentation
- The solitary metastasis was contoured on MR images that were fused with the planning CT dataset
- The orbits, optic nerves, optic chiasm, and scalp were also contoured

MBS Brain Auto-Contouring

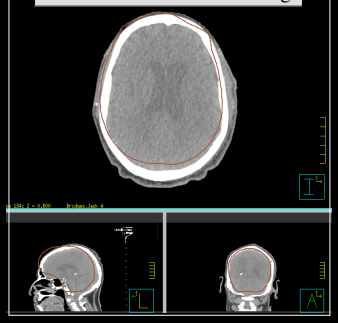

Case Study: Whole Brain / Boost

Pre-Treatment CT Images
Reference CT Images

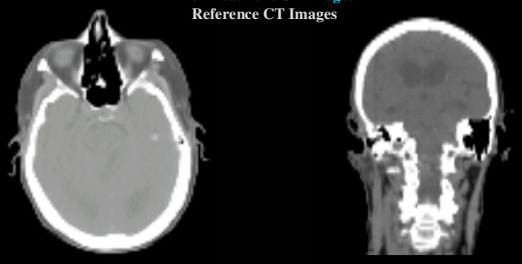

- The patient was MVCT imaged prior to each treatment fraction and repositioned for treatment

Case Study: Whole Brain / Boost

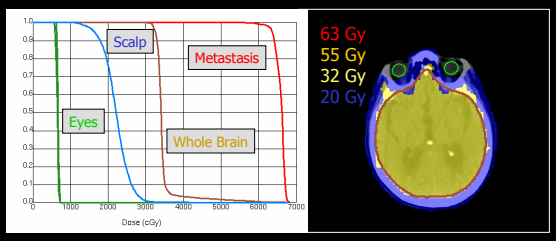

- There is no need for an additional radiosurgery boost with this type of treatment
- In addition, the scalp can be added as an objective during optimization to help reduce hair loss

Case Study: Whole Brain / Boost

- Ghia *et al* have proposed using this technique to preserve neurocognitive function by conformal avoidance of the hippocampus
- The vast majority of brain metastases occur >5 mm from the hippocampus (*96.7%*)
- The reported hippocampal mean dose was 8.3 Gy (0.55 Gy/fx)

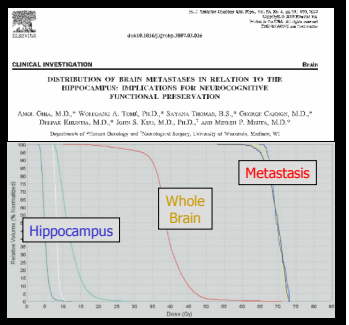
CLINICAL INVESTIGATION

DISTRIBUTION OF BRAIN METASTASES IN RELATION TO THE HIPPOCAMPUS: IMPLICATIONS FOR NEUROCOGNITIVE FUNCTIONAL PRESERVATION

Helical Tomotherapy Experience

- TomoTherapy
- Whole Brain
- Head & Neck
- Prostate
- Lung
- Summary

Case Study: Head & Neck

- In this example, a Epiglotis patient presented with bulky disease in the left neck
- Helical tomotherapy was used to deliver a concurrent boost
  - *50.4 Gy (1.8 Gy/fx) to the Secondary PTV*
  - *64.4 Gy (2.3 Gy/fx) to the Primary PTV*
- The patient was also treated with Concurrent Chemotherapy

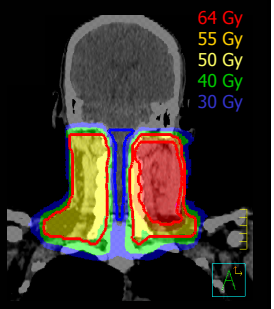

Case Study: Head & Neck

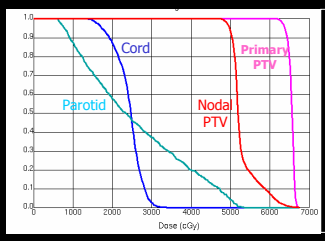

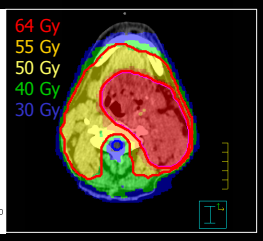

- The minimum dose to the Primary PTV was 63 Gy, and the maximum dose was 67 Gy
- Maximum dose to the spinal cord was 32 Gy, and the mean dose to the Right Parotid was 22 Gy

Case Study: Head & Neck

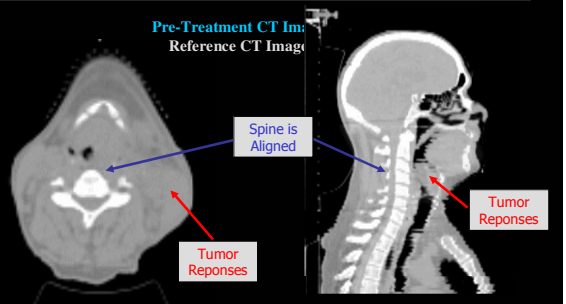

- The patient was MVCT imaged prior to each treatment fraction and repositioned for treatment

Case Study: Head & Neck

- Patient had substantial tumor reduction during treatment
- Allowed head to roll clockwise inside the mask
- Without daily imaging, part of the tumor would have been outside the treatment field
- >7-mm Lateral Systematic Error and 5º Roll

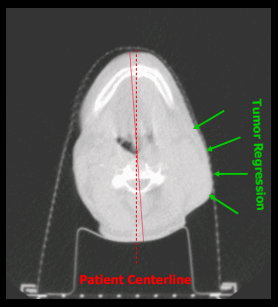

Helical Tomotherapy Experience

- TomoTherapy
- Whole Brain
- Head & Neck
- Prostate
- Lung
- Summary

Case Study: Whole Pelvis Prostate

- The use of hypofraction in the treatment of localized prostate cancer has received increased attention in recent years
- In addition, prostate patients with intermediate-to high-risk disease appear to experience disease-progression benefits from use of pelvic nodal irradiation
- In this example, helical tomo-therapy was used to deliver 50.4 Gy (*1.8 Gy/fx*) to the whole pelvis and 70 Gy (*2.5 Gy/fx*) to the prostate

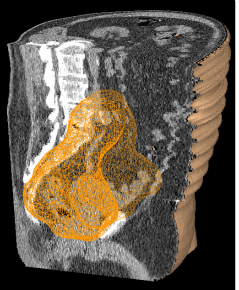

[2/3 PSA + (Gleason Score – 6) x 10]
Roach et al. IJROBP 66: 647–653

Case Study: Whole Pelvis Prostate

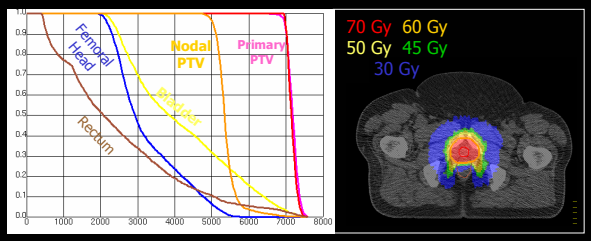

- Assuming a prostate α/β of 1.5, the total equivalent dose of 70 Gy delivered at 2.5 Gy/fx would be 85 Gy delivered at 1.8 Gy/fx
- Helical tomotherapy is capable of differential dose delivery that can meet both the Kupelian and Roach dose criteria

Case Study: Whole Pelvis Prostate

Pre-Treatment CT Images
Reference CT Images

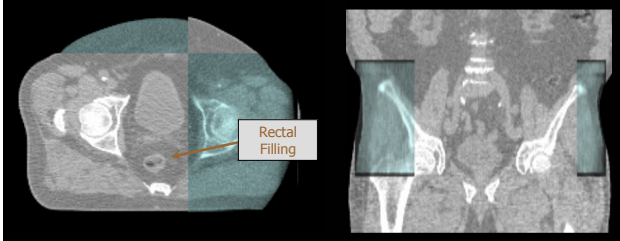

- The patient was MVCT imaged prior to each treatment fraction and repositioned for treatment

Case Study: Whole Pelvis Prostate

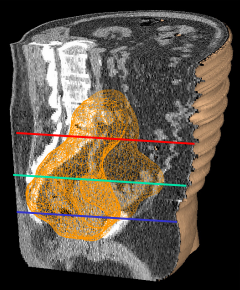

Without Daily CT-based IGRT Soft-Tissue Deformation is Hidden

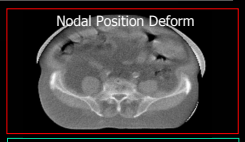

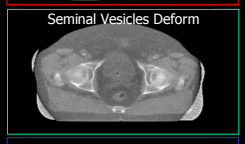

Helical Tomotherapy Experience

- TomoTherapy
- Whole Brain
- Head & Neck
- Prostate
- Lung
- Summary

Case Study: Lung

- Recent studies have shown that non-small cell lung tumors can change in volume over the course of treatment
- In this example, the predicted change in GTV volume is used to create an integrated boost to the site most at risk for local failure

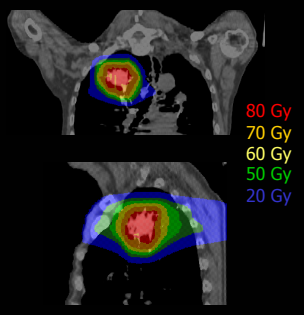

Case Study: Lung

Pre-Treatment CT Images
Reference CT Images

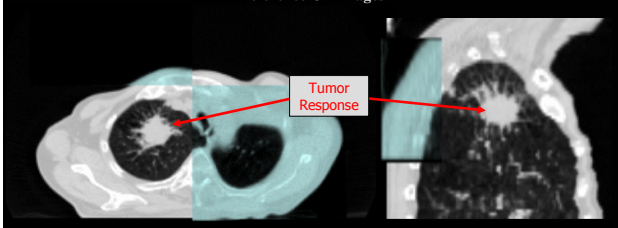

- The patient was MVCT imaged prior to each treatment fraction and tumor volumes were calculated automatically after each fraction using model based segmentation

Case Study: Lung

- The Patient's measured Tumor Response was measured for the first three fractions
- A a nonparametric model was used with a memory vector containing 563 MVCT imaging sessions of other patients
- This model was used to predict GTV's behavior

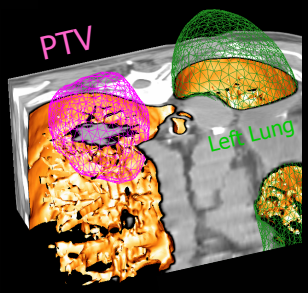

Case Study: Lung

Predicted Tumor Response to Treatment

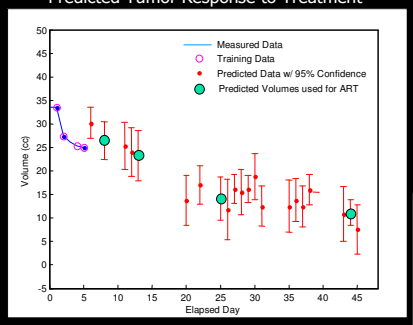

MVCT Image Sessions

Residual Tumor Volume Probability Map

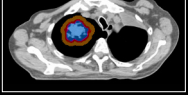

Case Study: Lung

Predicted Tumor Response to Treatment

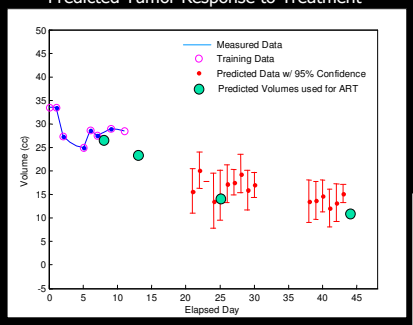

MVCT Image Sessions

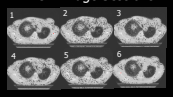

Residual Tumor Volume Probability Map

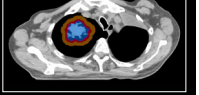

Case Study: Lung

Predicted Tumor Response to Treatment

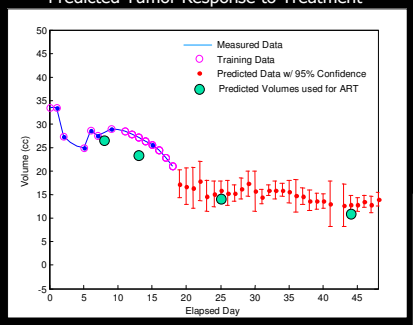

MVCT Image Sessions

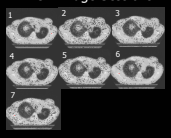

Residual Tumor Volume Probability Map

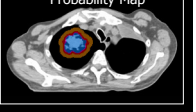

Case Study: Lung

Predicted Tumor Response to Treatment

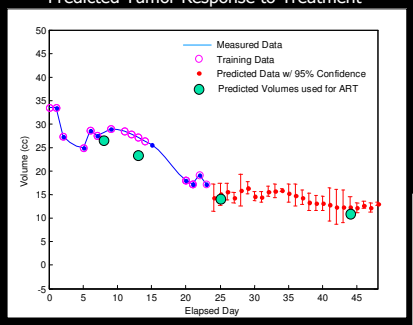

MVCT Image Sessions

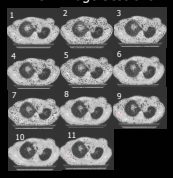

Residual Tumor Volume Probability Map

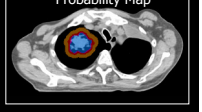

Case Study: Lung

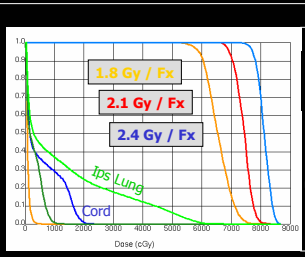

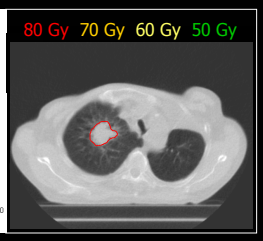

- The predictive model accurately identified the location of the residual tumor mass during the first week of treatment
- An integrated boost to this mass can allow dose escalation with increasing the dose to the surrounding normal tissues

Helical Tomotherapy Experience

- TomoTherapy
- Whole Brain
- Head & Neck
- Prostate
- Lung
- Summary



Helical Tomotherapy Experience

- Helical tomotherapy is well-suited for Differential Dose Delivery
- When combine with pre-treatment MVCT imaging, clinicians have the ability to compensate for changes in soft tissue anatomy