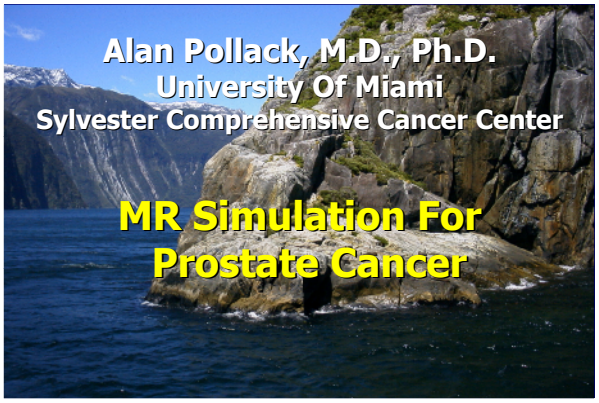

MR Simulation

- Prostate Anatomy
- MR-CT Fusion
- Functional Imaging
- Therapeutic Implications

2

The Benefit Of MRI

- Prostate Apex
  - Prostate-rectal interface
- Penile Bulb
- Tumor Location/Extent
- Bladder-Prostate Interface
- Seminal vesicles
- Pelvic vessels
- Lymph nodes

3

Prostate Anatomy
McLaughlin et al, IJROBP 2005

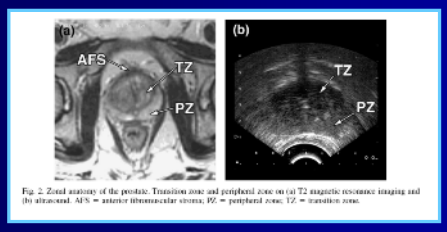

Fig. 2. Zonal anatomy of the prostate. Transition zone and peripheral zone on (a) T2 magnetic resonance imaging and (b) ultrasound. AFS = anterior fibromuscular stroma; PZ = peripheral zone; TZ = transition zone.

4

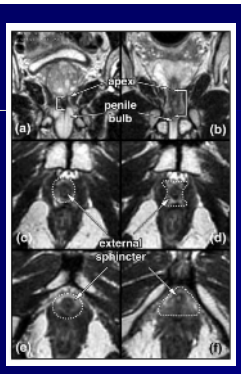

Prostate Anatomy
McLaughlin et al, IJROBP 2005

5

Case 3 High Risk CT-Sag Apex Not Well-Visualized

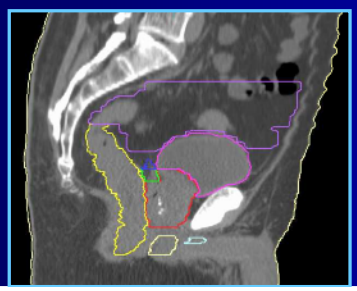

6

Case 3 High Risk MRI-Sag Apex Better Visualized

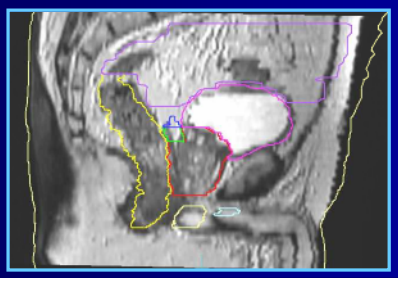

7

Case 3 High Risk Coronal CT

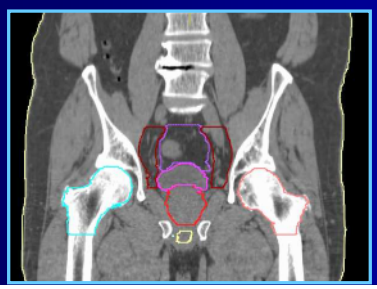

8

Case 3 High Risk Coronal MRI

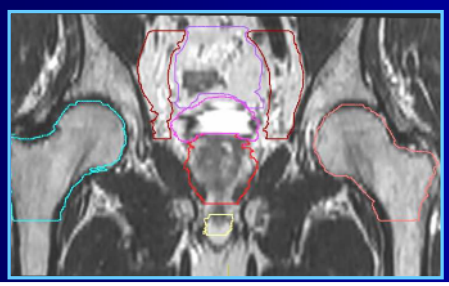

9

CT Overestimates Prostate Volume

- Roach et al, IJROBP 1996:
  - "The mean prostate volume was 32% larger…" by CT
- Rasch et al, IJROBP 1999:
  - The "average ratio between the CT and MR volumes was 1.4"
  - "CT-derived prostate volumes are larger than MR derived volumes, especially toward the seminal vesicles and the apex of the prostate."

10

Retrograde Urethrogram vs MRI For Defining The Prostate Apex

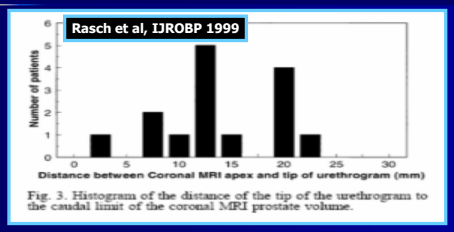

Fig. 3. Histogram of the distance of the tip of the urethrogram to the caudal limit of the coronal MRI prostate volume.

- Milosevic et al 1998 Radioth Oncol: ~80% agreement between CT urethrogram and MR.

11

MRI vs CT: GTV Delineation

MR CT

12

Case 3 High Risk: Slice 89

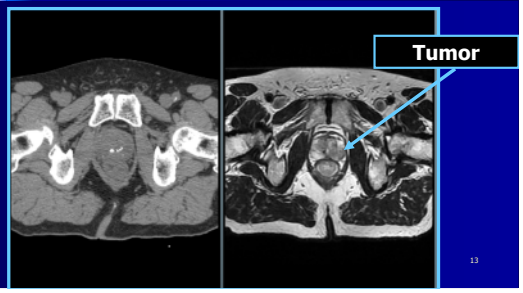

13

Penile Bulb/Cavernosal Bodies

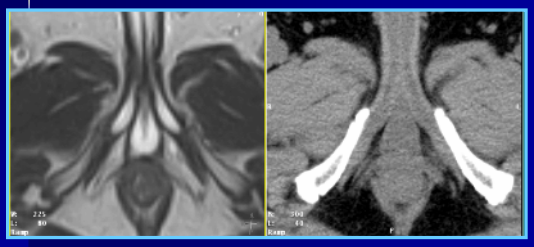

14

MRI vs. CT: Hip Replacement

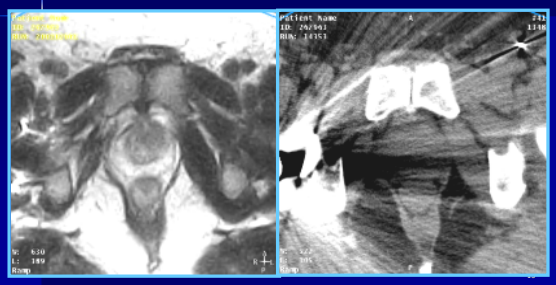

MR Simulation

- Prostate Anatomy
- MR-CT Fusion
- Functional Imaging
- Therapeutic Implications

16

MR Simulation

- No fiducials or Gold fiducials :
  - CT Sim First
- Calypso Beacons
  - MR Sim first
- Fusion based on bone and soft tissue.

1.5 T, 60 cm bore

Courtesy of Bob Price

- Retrograde urethrograms are *not* performed.

MR-CT fusion based on boney anatomy

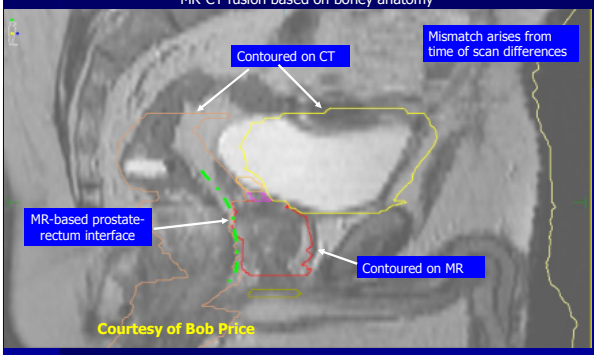

Courtesy of Bob Price

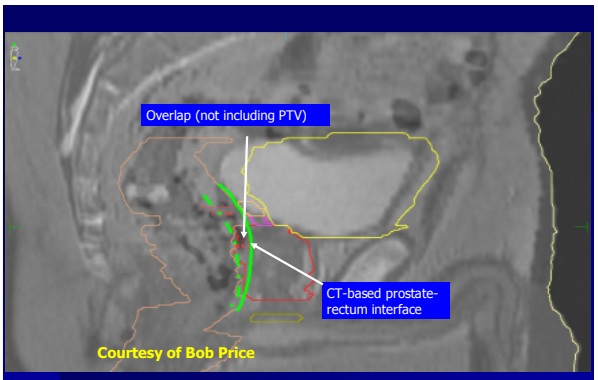

Courtesy of Bob Price

MR And CT With Gold Fiducials

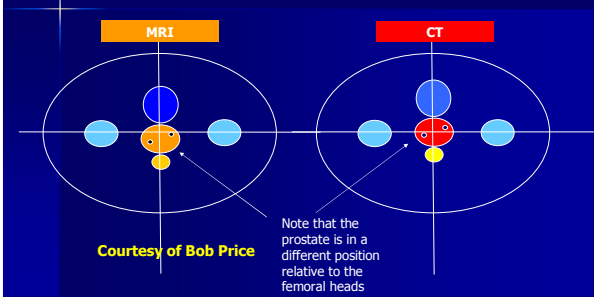

Courtesy of Bob Price

CT With Calypso Beacons

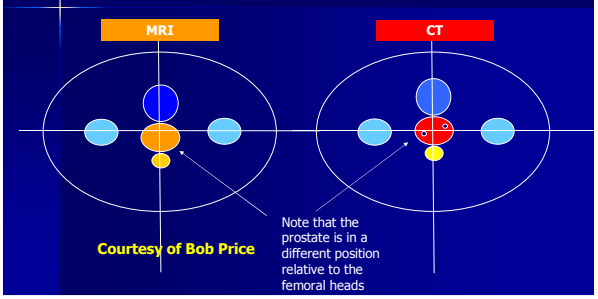

ELSEVIER

doi:10.1016/j.ijrobp.2004.05.068

PHYSICS CONTRIBUTION

MRI-BASED TREATMENT PLANNING FOR RADIOTHERAPY: DOSIMETRIC VERIFICATION FOR PROSTATE IMRT

Lili Chen, Ph.D., Robert A. Price, Jr., Ph.D., Lu Wang, Ph.D., Jinsheng Li, Ph.D., Lisiong Qin, Ph.D., Shawn McNeeley, M.S., C-M Charlie Ma, Ph.D., Gary M. Freedman, M.D., and Alan Pollack, Ph.D., M.D.

Department of Radiation Oncology, Fox Chase Cancer Center, Philadelphia, PA

ELSEVIER

doi:10.1016/j.ijrobp.2007.02.033

PHYSICS CONTRIBUTION

MAGNETIC RESONANCE–BASED TREATMENT PLANNING FOR PROSTATE INTENSITY-MODULATED RADIOTHERAPY: CREATION OF DIGITALLY RECONSTRUCTED RADIOGRAPHS

Lili Chen, Ph.D., Thai-Binh Nguyen, M.S., Elan Jones, Zoqun Chen, Ph.D., Wei Luo, Ph.D., Li Wang, Ph.D., Robert A. Price, Jr., Ph.D., Alan Pollack, Ph.D., M.D., and C.-M. Charlie Ma, Ph.D.

Department of Radiation Oncology, Fox Chase Cancer Center, Philadelphia, PA

MR-CT Fusion

- Don't outline from MR for soft tissue if there is discrepancy in the soft tissue
  - Fusion should be based on both soft tissue and bony anatomy
- Gold markers on MR and CT can aid in soft tissue fusion
- Calypso beacons are on CT only and MR should only be used as a reference (all outlining from CT)

23

MR Simulation

- Prostate Anatomy
- MR-CT Fusion
- Functional Imaging
- Therapeutic Implications

24

How Can Bulky-Hypoxic-Microvessel Dense Areas Be Identified And Better Targeted?

- **MR**
  - **MRS, Bold, DCE, DW**
- **PET**
  - **11C-Choline, 11C-Acetate**
- **Spect**
  - **PSMA**

Testa et al, Radiology 2007

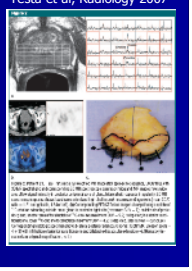

Imaging To Identify Bulky Tumor Regions

- **Pretreatment**
  - **Target with EBRT boost, EBRT+Brachy boost, EBRT+Cryosurgery boost, EBRT+FUS boost**
    - MR-Guided FUS
  - **Reduce incidence of Bx+ at 2-3 yr**
- **Post-treatment**
  - **Biopsy at 2-3 years**
    - Decision to Bx based on imaging?
    - Target residual tumor before PSA rise
      - Treatment of residual tumor cells only

26

Is Failure Related To High Volume Areas?

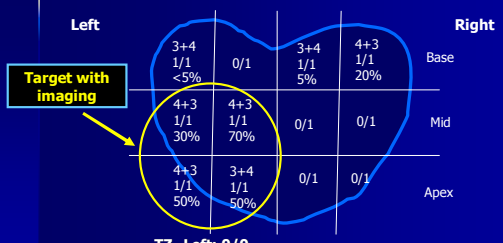

- **TZ- Left: 0/0**
- **TZ-Right: 0/0**

27

Post-Treatment Biopsy Results

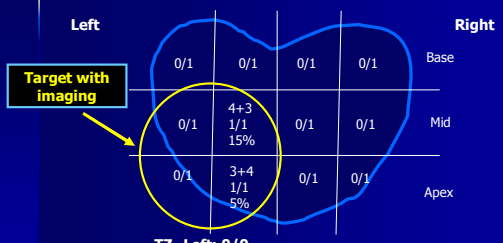

- **TZ- Left: 0/0**
- **TZ-Right: 0/0**

28

ASTRO Online CME

CLINICAL INVESTIGATION — Prostate

CLINICALLY SIGNIFICANT PROSTATE CANCER LOCAL RECURRENCE AFTER RADIATION THERAPY OCCURS AT THE SITE OF PRIMARY TUMOR: MAGNETIC RESONANCE IMAGING AND STEP-SECTION PATHOLOGY EVIDENCE

Darko Pucar, M.D., Ph.D.,* Hedvig Hricak, M.D., Ph.D.,* Ameta Shukla-Dave, Ph.D.,*† Kentaro Kuroiwa, M.D.,†¶ Marija Drobniak, M.D.,‡ James Eastham, M.D.,§ Peter T. Scardino, M.D.,§ and Michael J. Zelefsky, M.D.‖

- 9 Patients
- Pre-RT and Post-RT MRI
- Salvage Prostatectomy

29

Pucar et al, IJROBP 2007

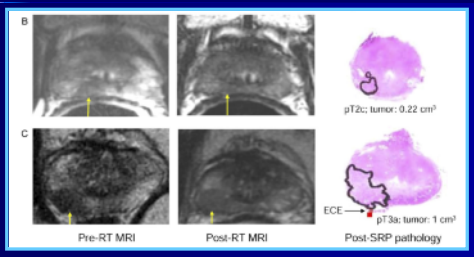

30

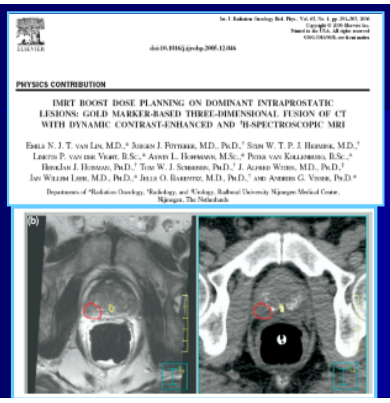

PHYSICS CONTRIBUTION

IMRT BOOST DOSE PLANNING ON DOMINANT INTRAPROSTATIC LESIONS: GOLD MARKER-BASED THREE-DIMENSIONAL FUSION OF CT WITH DYNAMIC CONTRAST-ENHANCED AND ^{19}F-SPECTROSCOPIC MRI

31

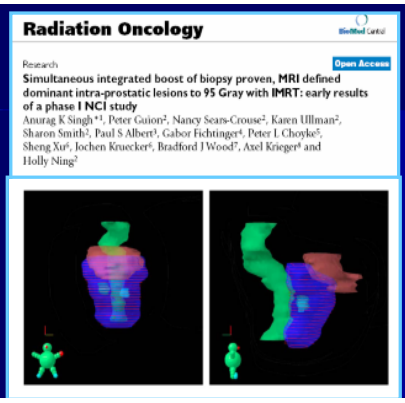

Radiation Oncology — BioMed Central

Research — Open Access

Simultaneous integrated boost of biopsy proven, MRI defined dominant intra-prostatic lesions to 95 Gray with IMRT: early results of a phase I NCI study

Anurag K Singh*[1], Peter Guion[2], Nancy Sears-Crouse[2], Karen Ullman[2], Sharon Smith[2], Paul S Albert[3], Gabor Fichtinger[4], Peter L Choyke[5], Sheng Xu[6], Jochen Kruecker[6], Bradford J Wood[7], Axel Krieger[8] and Holly Ning[2]

32

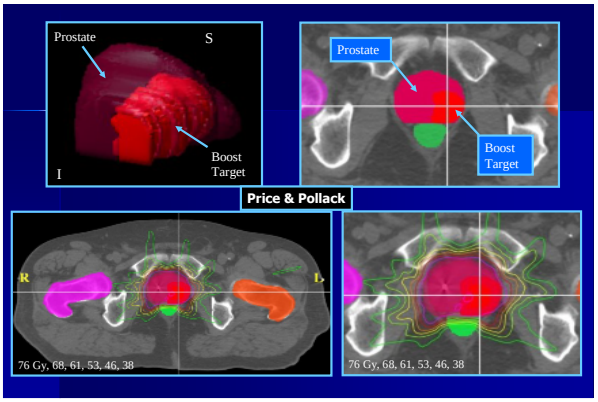

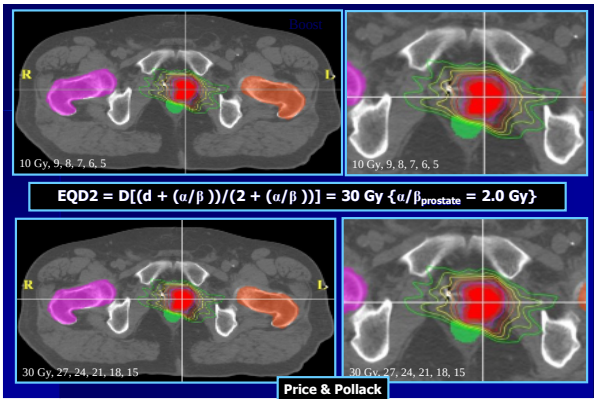

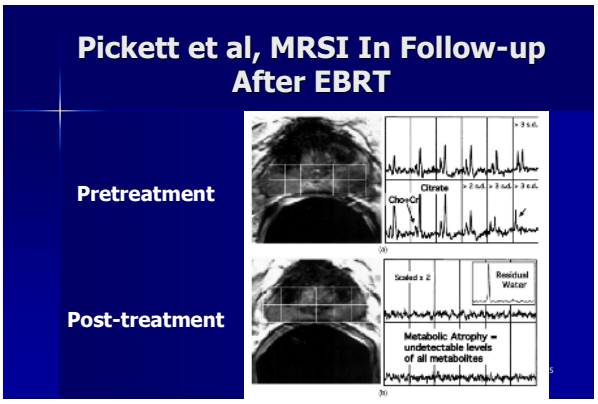



Int. J. Radiation Oncology Biol. Phys., Vol. 70, No. 3, pp. 425–430, 2008.
Copyright © 2008 Elsevier Inc.
Printed in the U.S.A. All rights reserved.
0360-3016/$ - see front matter

ELSEVIER

doi:10.1016/j.ijrobp.2007.06.029

CLINICAL INVESTIGATION — Prostate

DYNAMIC CONTRAST-ENHANCED MAGNETIC RESONANCE IMAGING FOR LOCALIZATION OF RECURRENT PROSTATE CANCER AFTER EXTERNAL BEAM RADIOTHERAPY

Table 1. Performance of DCE MRI vs. T2w imaging

	By patient					By sextant				
	T2w	95% CI	DCE MRI	95% CI	p	T2w	95% CI	DCE MRI	95% CI	p
Sensitivity	58 (7/12)	28–85	100 (12/12)	74–100	0.06	38 (11/29)	20–60	72 (21/29)	56–84	0.005*
Specificity	52 (11/21)	30–75	71 (15/21)	48–89	0.29	80 (135/169)	66–88	85 (144/169)	74–92	0.4
PPV	41 (7/17)	18–67	67 (12/18)	41–87	†	24 (11/45)	11–45	46 (21/46)	27–65	0.02*
NPV	69 (11/16)	41–89	100 (15/15)	78–100	†	88 (135/153)	80–94	95 (144/152)	89–97	0.002*
Accuracy	55 (18/33)	36–72	82 (27/33)	65–93	0.02*	74 (146/198)	64–82	83 (165/198)	74–90	0.07

Abbreviations: DCE MRI = dynamic contrast-enhanced magnetic resonance imaging; T2w = T2-weighted imaging; CI = confidence interval; PPV = positive predictive value; NPV = negative predictive value.
Values are percentages.
* Significant difference ($p < 0.05$).
† Statistical assumptions do not allow for analysis with the given number of events.

Int. J. Radiation Oncology Biol. Phys., Vol. 71, No. 1, Supplement, pp. S43–S47, 2008

0360-3016/$–see front matter

doi:10.1016/j.ijrobp.2007.06.079

QA FOR RT SUPPLEMENT

NEWER IMAGING MODALITIES TO ASSIST WITH TARGET LOCALIZATION IN THE RADIATION TREATMENT OF PROSTATE CANCER AND POSSIBLE LYMPH NODE METASTASES

Subhash S. John, M.D.,* Anthony L. Zietman, M.D.,* William U. Shipley, M.D.,* and Mukesh G. Harisinghani, M.D.†

Departments of *Radiation Oncology and †Radiology, Massachusetts General Hospital and Harvard Medical School, Boston, MA

Lymphotropic Superparamagnetic Nanoparticle lymph node imaging agents (Combidex)

37

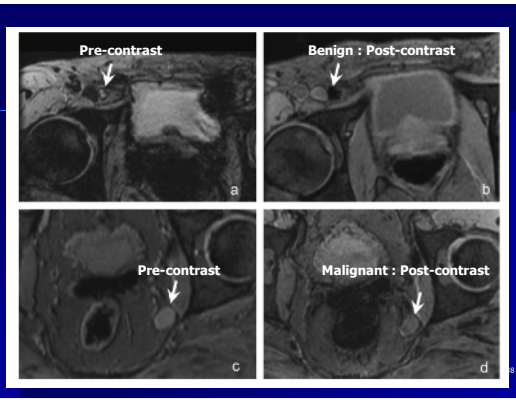

38

MR Imaging For Prostate Cancer

- There are gains in the use of MR imaging in RT planning and delivery, and in follow-up.
- Need to test and incorporate better imaging methods for identifying bulky-hypoxic-microvessel dense disease

39