Imaging for Treatment Planning

Kristy K. Brock, Ph.D.
Radiation Medicine Program
Princess Margaret Hospital/Ontario Cancer Institute
Department of Radiation Oncology, University of Toronto

Princess Margaret Hospital
University Health Network

Disclosure

- Industry Grant Funding:
  - Philips Medical Systems
  - Elekta Oncology Systems
  - RaySearch Laboratories
- Physics Advisory Board: IMPAC

Acknowledgements

- Laura Dawson
- Barbara Wysocka
- Cynthia Ecceles
- Douglas Moseley
- Tom Purdie
- Andrea Bezjak
- Harry Keller
- M Ghilezan – Beaumont Hospital
- D Litzenberg – University of Michigan

Imaging for Treatment Planning

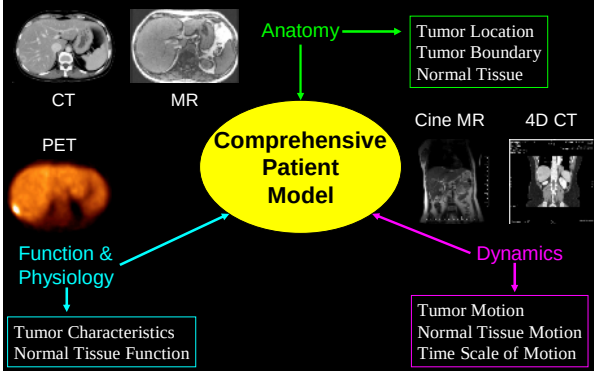

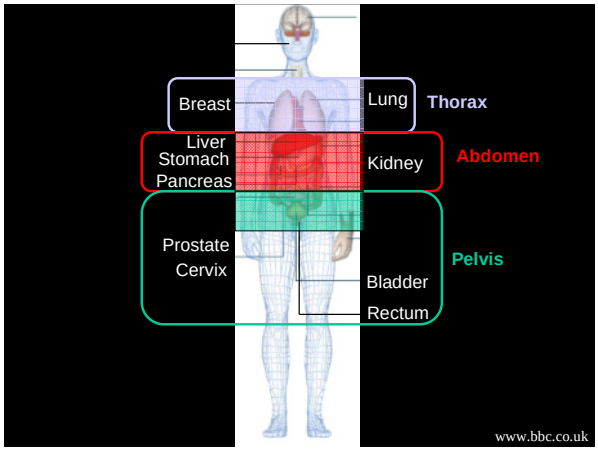

Anatomy

- Multi-modality imaging
  - Reproduce patient set-up
  - Integration: Image Registration
- Reduce/eliminate motion
- Contrast enhancement
- Optimize image resolution & timing

Multi-modality Imaging Prostate

*Courtesy Cynthia Ménard

Multi-modality Imaging Prostate

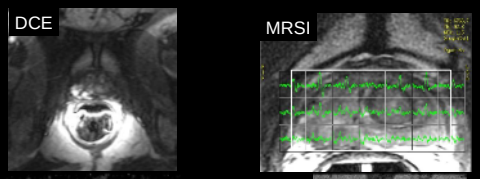

*Courtesy Cynthia Ménard

Multi-modality Imaging Cervix

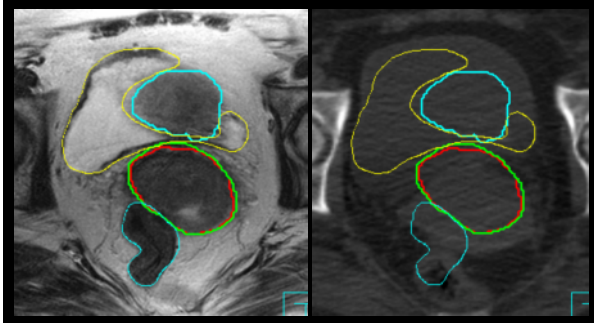

*Courtesy Mike Milosevic

Multi-modality Imaging Liver

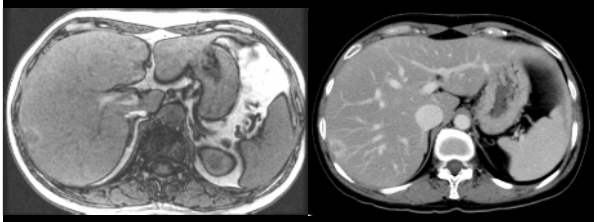

*Courtesy Laura Dawson

Patient Set-up

- Reproduce the patient set-up between imaging modalities
- Match the set-up at the treatment unit

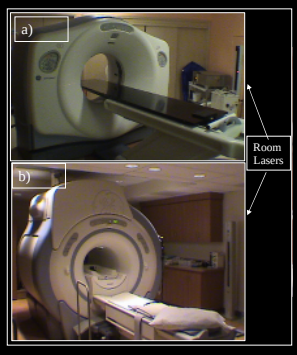

Integration: Image Registration

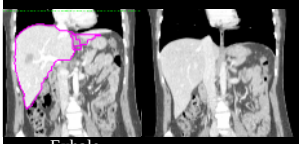

- Rigid registration has limitation
- Limit the field of view
  - Contour driven
  - Clip box
- Beware of errors outside of your field of view

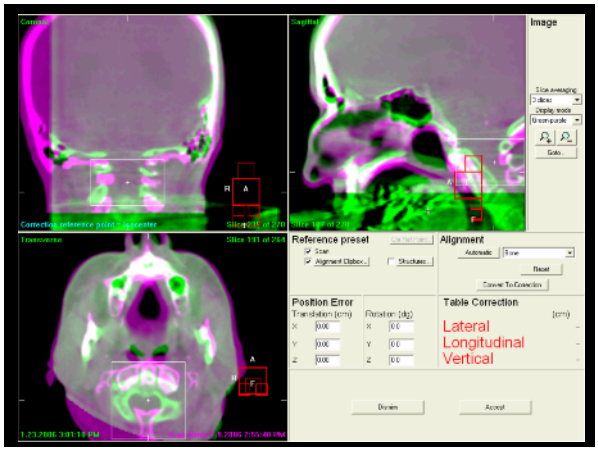

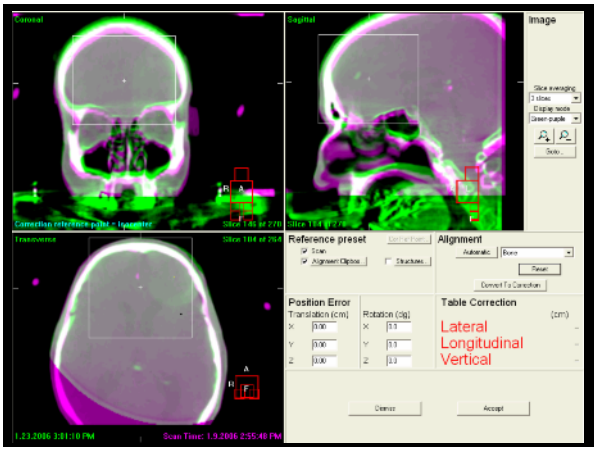

Reducing Motion Artifacts

- Abdominal Motion
  - Heart beat
  - Breathing
  - Peristalsis

Reducing Motion: Breathing

- Respiration correlation
  - '4D' Imaging
- Breath hold
- Abdominal Compression

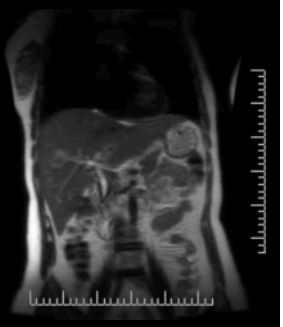

Respiration Correlated

- Surrogate of breathing motion
  - External (RPM)
  - Internal (image-based aperture)
  - Physical (flow sensor)
- Over-sampling of image space
  - Repeat acquisition of anatomy over the course of breathing period



Breath Hold

- Voluntary
- Assisted
  - Monitor breathing cycle
  - Forced breath hold at pre-determined position

- Intra-fx reproducibility of diaphragm
  - End-inh 4.0 mm +/- 3.5 mm
  - End-exh 2.2 mm +/- 2.0 mm
- Mean organ movement relative to bones as studied with repeat nephrograms in 32 patients

Structure	CC
Kidney-inh	7.7 mm
Kidney-exh	4.9 mm

Kim, IJROBP 49, 2001
Kimura T et al. , IJROBP, 1307, 2004
Kuhns, J of Comp Ass Tomography 3(5), 1979

Breath Hold

- Voluntary
- Assisted
  - Monitor breathing cycle
  - Forced breath hold at pre-determined position

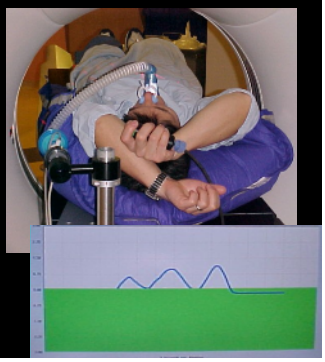

Breath Hold

- Voluntary
- Assisted
  - Monitor breathing cycle
  - Forced breath hold at pre-determined position

	No. Images	Reprod. (σ) Inter-fx Intra-fx
Michigan[1]	262	4.4 mm 2.5 mm
Toronto[2]	257	3.4 mm 1.5 mm

- IGRT required for maximal PTV reduction

1) Dawson LA. IJROBP 2001
2) Eccles, C, IJROBP, 2005

Abdominal Compression

- Mean organ movement as studied with serial CT scans

Structure	CC Motion	
	no comp.	comp.
Kidney	4 mm	2 mm
Liver	10 mm	6 mm
Pancreas	4 mm	1 mm

Suramo, Acta Radiologica Diagnosis 25, 1984

Reducing Motion: Peristalsis

- Peristalsis may decrease with fasting
  - Fasting
  - 15 min after eating

Barbara Wysocka, Princess Margaret Hospital

Reducing Motion: Peristalsis

- Peristalsis may decrease with fasting
  - Fasting
  - 15 min after eating

Barbara Wysocka, Princess Margaret Hospital

Reducing Motion: Rectal Motion

- Full Bladder Prep
  - One hour before the appointment, empty the bladder
  - Drink 500mls of water and do not void until after the appointment
- Empty Rectum Prep
  - Take 2 tablespoons of Milk of Magnesia every night, starting 2-3 days before the appointment

Tumor Definition

- Multi-modality imaging
- Contrast Enhancement
- Optimal Imaging parameters

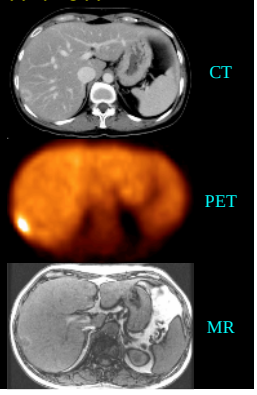

CT: Importance of Contrast

Non-contrast, exhale breath hold

Arterial phase contrast contrast, exhale breath hold

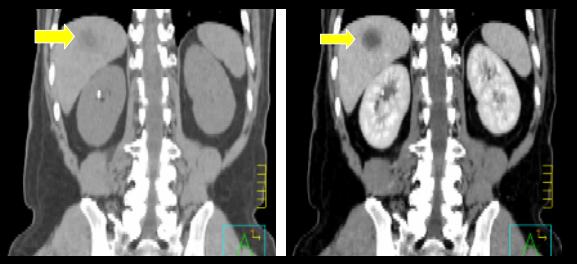

Courtesy of LA Dawson

CT: Importance of Contrast

- Triphasic liver CT in treatment position
  - Omnipaque 300 2cc/kg to a maximum of 200cc
  - Injected 5 cc/sec
  - Arterial Delay (best for hepatoma) 30 sec
  - Venous Delay (best fo metastases) 60 sec

Arterial phase contrast contrast, exhale breath hold

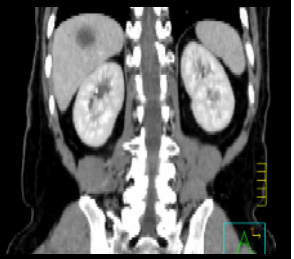

Courtesy of LA Dawson

Importance of Contrast

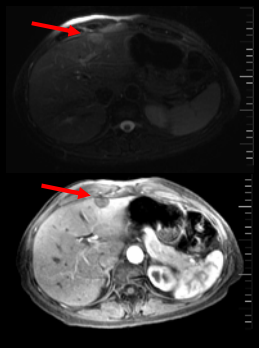

T2w – no contrast

T1w - gadolinium

Optimizing Imaging Time

- Obtain the entire imaging FOV in 1 Breath hold
  - Reduces repeat breath hold artifacts
  - ~15-30 s imaging time
- 320 Slice CT
- ✓ MR w/ Parallel Imaging

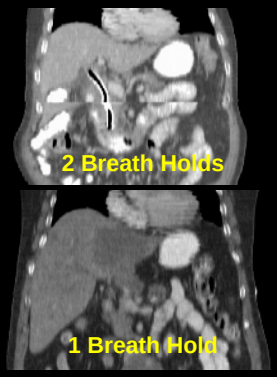

Parallel Imaging

- Reduce K space data obtained
  - Interpolate remaining
- Faster imaging time
- Small reduction in image quality
- Beneficial for cine and volumetric (breath hold) imaging

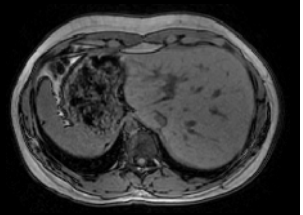

Axial Fast-Spin Gradient Recovery (FSPGR)
(TE/TR 1.6/325 ms, 1 NEX, FOV 34 – 44 cm)
Array Spatial Sensitivity Encoding Techniques (ASSET™)
GE 1.5T MR unit (Excite, 4 channel, GE Medical Systems)
256 x 256 x 34 (0.14 x 0.14 x 0.4 cm resolution), ~30 sec

Dynamics

- Measure motion
  - Periodic motion (breathing)
  - Random motion (bladder/bowel/stomach filling)
- Reduce artifacts

Quantifying Motion

- Fluoroscopy
  - 2D Imaging
  - Limited to high contrast
  - 'Real-Time'
- 4D CT
- Breath hold CT
- Breath hold MR
- Cine MR

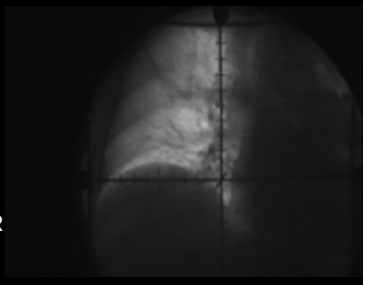

Quantifying Motion

- Fluoroscopy
- 4D CT
  - Multiple 3D datasets
  - Soft tissue contrast
  - May have artifacts due to respiration correlation
- Breath hold CT
- Breath hold MR
- Cine MR

GTV motion in esophageal cancer

- 17 esophageal patients
- 4D CT during normal breathing
- Manual tumor delineation at 0 and 50,60%

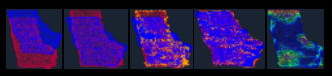

KL Wiltshire, R Wong, H Alasti, A Abbas, F Cheung, K Brock, J Ringash & J Brierley CARO 2005

Esophageal movement
Max motion – population AVG, SD [cm]

	Sup	Inf	Right	Left	Ant	Post
Upper (n=2)	0.5 (0.0)	0.5 (0.1)	0.3 (0.1)	0.2 (0.0)	0.4 (0.0)	0.4 (0.1)
Mid (n=4)	0.8 (0.3)	0.8 (0.4)	0.4 (0.2)	0.4 (0.1)	0.5 (0.1)	0.3 (0.1)
Lower (n= 12)	0.9 (0.7)	1.0 (0.6)	0.5 (0.2)	0.6 (0.2)	0.7 (0.3)	0.6 (0.4)

Quantifying Motion

- Fluoroscopy
- 4D CT
- Breath hold CT
  - Normal Inhale BH
  - Normal Exhale BH
- Breath hold MR
- Cine MR

5 mm/2.5 mm reconstruction
Pitch 0.75:1
120 kV, 200+ mA

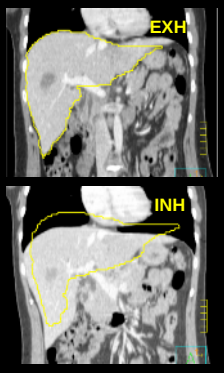

Quantifying Motion

- Fluoroscopy
- 4D CT
- Breath hold CT
- Breath hold MR
  - Normal Inhale BH
  - Normal Exhale BH
- Cine MR

axial Fast-Spin Gradient Recovery (FSPGR)
(TE/TR 1.6/325 ms, 1 NEX, FOV 34 – 44 cm)
Array Spatial Sensitivity Encoding Techniques (ASSET™)
scanning time ~30 s, 256 x 256 x N (5 mm slice)

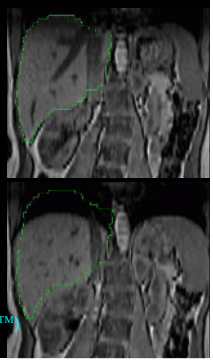

Quantifying Motion

- Fluoroscopy
- 4D CT
- Breath hold CT
- Breath hold MR
- Cine MR
  - 2D planar
  - Flexibility in optimizing imaging plane
  - Soft tissue contrast
  - Close to 'real-time'

(1.5 Tesla GE)
–SSFSE ≈ 1 frame/sec. ≈ 30 sec.
–1 cm slice

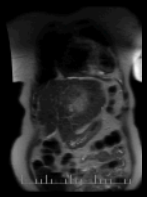

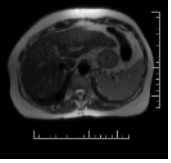

Breathing Motion – Liver Cancer

MR liver tumor motion due to breathing (mm)

	CC	>	AP	>	ML
Ave.	16.1		10.2		7.6
St Dev.	7.4		4.4		2.9
Min.	7.3		3.7		3.8
Max.	35.4		20.6		16.3

Dawson, et al., ESTRO 2004

Differences in Quantified Motion

Difference between Fluoro and MR tumor CC motion

	All n = 32	Fluoro > MR 48 %	Fluoro < MR 52 %
Ave	7 mm	6 mm	8 mm
Max	21 mm	18 mm	21 mm
> 5 mm	48 %	43 %	55 %

Dawson, et al., ESTRO 2004

Cine MR: Non-Periodic Motion

Cervical Cancer

- Single Shot FSE images displayed with cine loop.
  - TR/TE=1400-1600/90. FOV 30, Matrix 256x192, NEX 0.5, BW 31.2kHz, slice thick/gap=5/7mm.
  - Acquiring 3 sagittal slices along axis of uterus and cervix at 3 seconds (1s/slice) interval for 1 min with 4 minute rest for a total of 30 min.
  - 20 images/slice/min totaling
  - 360 images over 30 min.

P. Chan, PMH

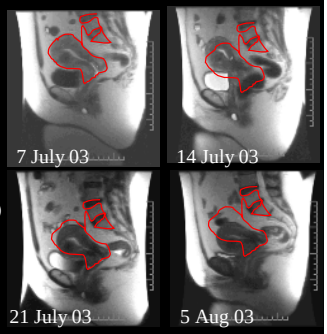

Inter- and Intra-fraction Displacement

Time Frame		Fundus Pt.		Cervical Os		Bladder Pt.	
		Y	Z	Y	Z	Y	Z
Inter- (week-week)	1 S.D.	2.5	21.6	10.1	5.0	6.8	11.9
	Range	4.6	51.3	23.4	11.7	13.3	28.3
Intra- (within a 30 minute interval)	1 S.D.	1.8	3.7	0.9	1.0	1.5	2.8

(All results in mm, exclude setup errors)

Organ Motion – Prostate Cancer

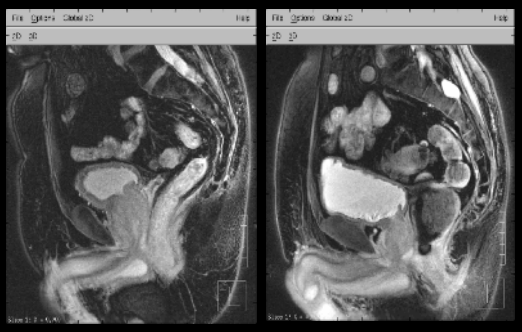

Probability of Prostate Motion with Time

- Increases with full rectum

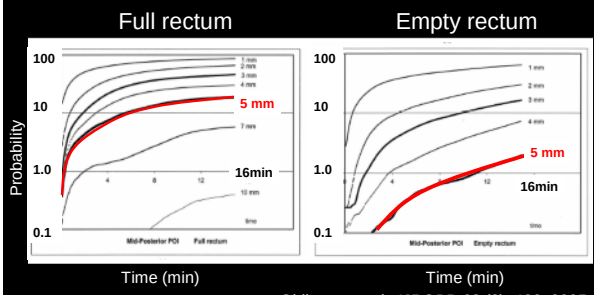

Ghilezan, et al. IJROBP 62 (2), 406, 2005

Prostate Motion – Bowel Routine

	No laxative	Laxative used	
	MR 1	MR 2 - CT	MR 3 - RT
Maximum	16.6 mm	6.9 mm	10.7 mm
Probability of > 3 mm displacement	9.8%	5.7% (p = 0.30)	5.0% (p = 0.13)

* Previous investigation report probabilities of 20%.

Nicol, et al. ASTRO 2004

Prostate and Pelvic Skeletal Breathing Motion

Prone	CC (marker)	AP (skeleton)
Free breathing	1.0 - 5.1 mm	1.0 - 3.5 mm
Deep breathing	3.8 - 10.5 mm	2.7 - 13.1 mm
Supine		
Free breathing	< 1.0 mm	< 1.0 mm
Deep breathing	0.5 - 7.3 mm	< 1.0 mm

Dawson, et al. IJROBP. 2000
Malone et al Rad Onc 2000

Technical Developments

- Contrast agents/timing
- Respiration correlation
  - more than CT
- Parallel imaging
  - Faster and Faster Imaging @ 'no' expense
- Multiple slices
  - Faster and Faster Imaging
- Functional imaging
- Correlating Multi-Modality Imaging

Function & Physiology

- Measure metabolic activity
- Improve target definition
- Provide response assessment

The new roles of PET

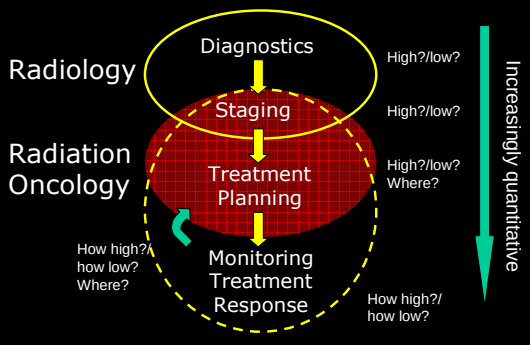

ELSEVIER
Radiotherapy and Oncology 62 (2001) 51–60
RADIOTHERAPY & ONCOLOGY
www.elsevier.com/locate/radiotherapy

Radiotherapy treatment planning for patients with non-small cell lung cancer using positron emission tomography (PET)

Yusuf E. Erdi[a,*], Kenneth Rosenzweig[b], Alev K. Erdi[a], Homer A. Macapinlac[c], Yu-Chi Hu[a], Louise E. Braban[a], John L. Humm[a], Olivia D. Squire[d], Chen-Shou Chui[a], Steven M. Larson[d], Ellen D. Yorke[a]

[a]Department of Medical Physics, Memorial Sloan-Kettering Cancer Center, 1275 York Avenue, New York, NY, 10021, USA
[b]Department of Radiation Oncology, Memorial Sloan-Kettering Cancer Center, 1275 York Avenue, New York, NY, 10021, USA
[c]Department of Nuclear Medicine, MD Anderson Cancer Center, Houston, TX, 77035, USA
[d]Department of Radiology, Nuclear Medicine Service, Memorial Sloan-Kettering Cancer Center, 1275 York Avenue, New York, NY, 10021, USA

Received 28 March 2001; received in revised form 1 September 2001; accepted 15 October 2001

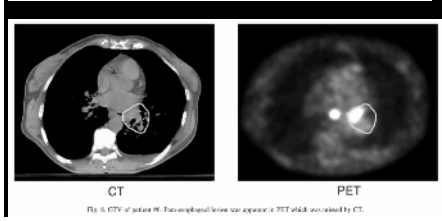

Fig. 8. GTV of patient #6. Post-esophageal lesion was apparent in PET which was missed by CT.

- 11 Patients
- PET + CT
- CT: GTV + PTV
- CT+PET: PTV
- 7/11 – increase in PTV with PET

Simulation Imaging Modality

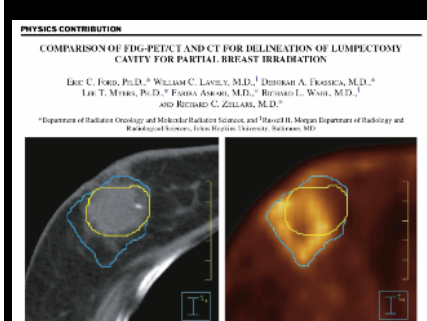
PHYSICS CONTRIBUTION

COMPARISON OF FDG-PET/CT AND CT FOR DELINEATION OF LUMPECTOMY CAVITY FOR PARTIAL BREAST IRRADIATION

Eric C. Ford, Ph.D.,[a] William C. Lavely, M.D.,[1] Deborah A. Frassica, M.D.,[a] Lee T. Myers, Ph.D.,[a] Fabiola Asikari, M.D.,[a] Richard L. Wahl, M.D.,[1] and Richard C. Zellars, M.D.[a]

[a]Department of Radiation Oncology and Molecular Radiation Sciences, and [1]Russell H. Morgan Department of Radiology and Radiological Sciences, Johns Hopkins University, Baltimore, MD

Ford, IJROBP, 71, 595-602, 2008.

12 patients

Inflammation used to ID lumpectomy cavity

Cavity volume ratio (PET CT)/CT = 1.68
Range = 1.24 – 2.45

PTV volume ratio (PET CT)/CT = 1.16
Range = 1.08 – 1.64

PET CT largely encompassed CT

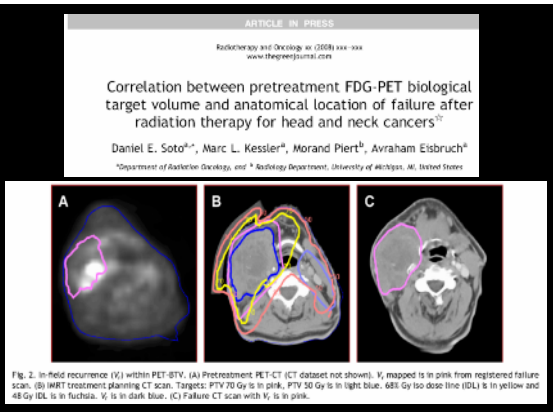

ARTICLE IN PRESS

Radiotherapy and Oncology xx (2008) xxx–xxx
www.thegreenjournal.com

Correlation between pretreatment FDG-PET biological target volume and anatomical location of failure after radiation therapy for head and neck cancers☆

Daniel E. Soto[a,*], Marc L. Kessler[a], Morand Piert[b], Avraham Eisbruch[a]
[a]Department of Radiation Oncology, and [b] Radiology Department, University of Michigan, MI, United States

Fig. 2. In-field recurrence (V_r) within PET-BTV. (A) Pretreatment PET-CT (CT dataset not shown). V_r mapped is in pink from registered failure scan. (B) IMRT treatment planning CT scan. Targets: PTV 70 Gy is in pink, PTV 50 Gy is in light blue. 68% Gy iso dose line (IDL) is in yellow and 48 Gy IDL is in fuchsia. V_r is in dark blue. (C) Failure CT scan with V_r is in pink.

9/16 Pts had LRF, 9/9 LRF inside GTV, 8/9 LRF mapped within the PET-BTV

Summary

- Optimizing Imaging for Treatment Planning
  - ✓Remove motion for tumor definition
  - ✓Quantify physiological motion
  - ✓Acquire data as fast as possible
  - ✓Optimize contrast agents
  - ✓Obtain information on organ function

Summary

- Remove motion for tumor definition
  - Breath hold (voluntary, assisted)
  - Respiration Correlated
  - Compression
  - Dietary guidelines
- Quantify physiological motion
  - 4D Imaging
  - Breath hold at normal inhale/exhale
  - 2D cine data
  - Fluoroscopy

Summary

- Acquire data as fast as possible
  - Multi-slice Acquisition (CT)
  - Parallel Imaging (MR)
- Optimize contrast agents
  - Correlate timing with imaging goals
- Obtain information on organ function
  - PET/SPECT/fCT/fMR