X-ray Imaging Dose to Patients in the Era of Image-Guided Radiation Therapy

George Ding, Ron Price, Charles Coffey
Vanderbilt-Ingram Cancer Center
Vanderbilt University Medical Center, Nashville, TN

Introduction

- Image-guided radiation therapy (IGRT) has dramatically improved the accuracy of radiotherapy
- IGRT has emerged as the new paradigm in radiotherapy.
- X-ray imaging, such as cone-beam CT (CBCT), for patient setup can add radiation dose to patients.
- Additional imaging dose may entail biological risk
- How much are the imaging doses to patients?

Modalities used in imaging guidance

- electronic portal imaging device (EPID)
- kilovoltage digital radiography (kV DR)
- megavoltage cone-beam CT (MV-CBCT)
- kilovoltage cone-beam CT (kV-CBCT)
- CT-on-rails

Electronic portal imaging device (EPID)

MV AP setup field (Head and Neck)

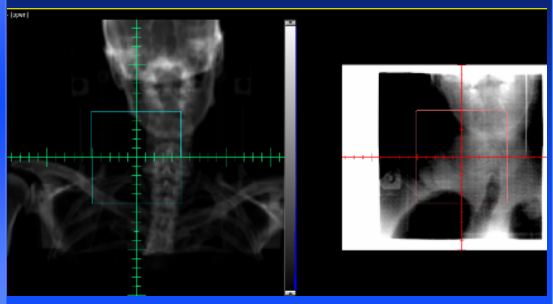

MV AP setup field

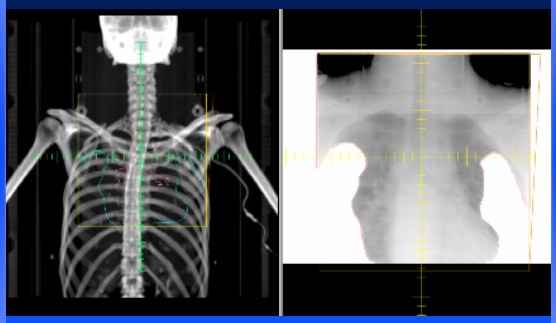

MV AP setup field (double exposure)

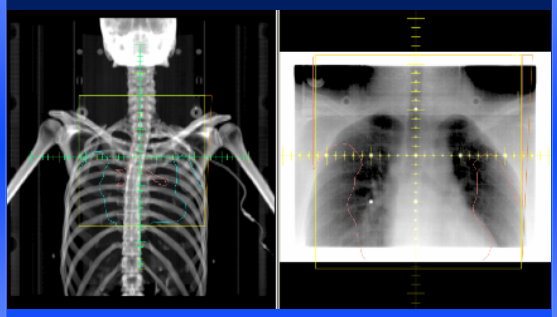

MVCT on Linac unit

Gayou *et al.*: Patient dose and image quality from MV-CBCT Med. Phys. 34 (2), February 2007

FIG. 1. The cylindrical acrylic phantoms measurement setup. A small volume chamber was placed at the isocenter as well as 1 cm below the surface at the 0°, 90°, 180°, and 270° positions.

MVCT images

Gayou *et al.*: Patient dose and image quality from MV-CBCT Medical Physics, Vol. 34, No. 2, February 2007

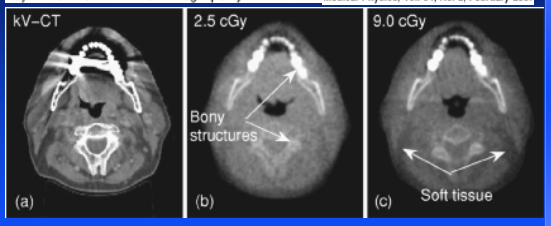

FIG. 8. Transverse slice of a head and neck patient imaged with (a) kV-CT, (b) 2.5 cGy MV-CBCT protocol, (c) 9.0 cGy MV-CBCT protocol. The lower dose is sufficient to show the bony structures on the MV-CBCT image. Soft tissue boundaries are more visible with the higher dose.

Vanderbilt Medical Center School of Medicine

MVCT images

Sillanpaa *et al.*: Gated megavoltage cone beam CT with aS500 EPID Medical Physics, Vol. 32, No. 3, March 2005

FIG. 12. 20 MU large-field scan registered to a diagnostic CT scan of the same phantom, using a CT-to-CT registration tool. Left: axial view; right upper: coronal view; right lower: sagittal view. MV reconstructions are in the lower-right and upper-left quadrants of each image.

Vanderbilt Medical Center School of Medicine

MVCT on Tomotherapy unit

I. J. Radiation Oncology ● Biology ● Physics Volume 56, Number 1, 2003

Image-guided radiotherapy ● T. R. MACKIE *et al.*



Fig. 3. The helical tomotherapy unit installed at the University of Wisconsin. The left panel is with a cover open. The panel on the right is looking along the CT table into the ring gantry bore.

Vanderbilt Medical Center School of Medicine

Images of MVCT Tomotherapy unit

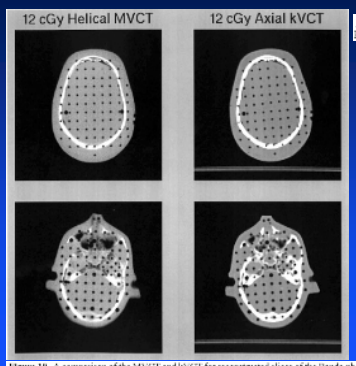

K J Ruchala et al
Phys. Med. Biol. 44 (1999) 2597–2621

Figure 10. A comparison of the MVCT and kVCT for reconstructed slices of the Rando phantom.

Vanderbilt Medical Center School of Medicine

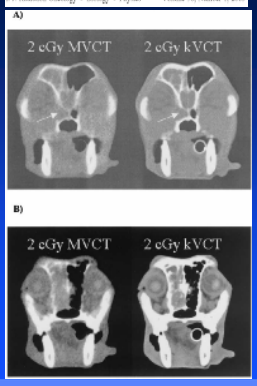

Images of MVCT Tomotherapy unit

Fig. 4. Comparison of MVCT images to kVCT images. Shown are 2 CT slices from a dog with sarcoma of the sinus. (A) Erosion of the bone is shown with the white arrow. (B) The left sinus is filled with tumor. The MVCT image at 2 cGy does not have sufficient contrast for diagnosis but is sufficient for purposes of localization.

CT-on-rail system

Murphy *et al.*: Imaging dose during image-guided radiotherapy
Medical Physics, Vol. 34, No. 10, October 2007

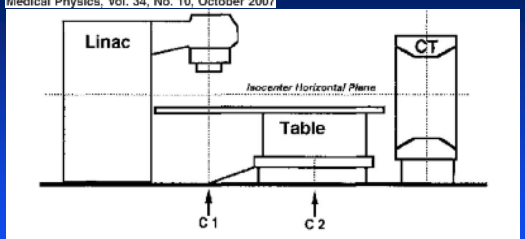

FIG. 3. The schematic geometry for a CT-on-rails system showing the two rotation axes of the couch: C1 being the conventional rotational axis with respect to the Linac isocenter and C2 being the axis to rotate the couch into alignment with the CT scanner, which moves on rails along the scan axis.

kV CBCT system



Islam *et al.* Med. Phys. 33 (6), June 2006

kV CBCT system

G X Ding *et al* Phys. Med. Biol. 52 (2007) 1595–1615

kV Lat setup field

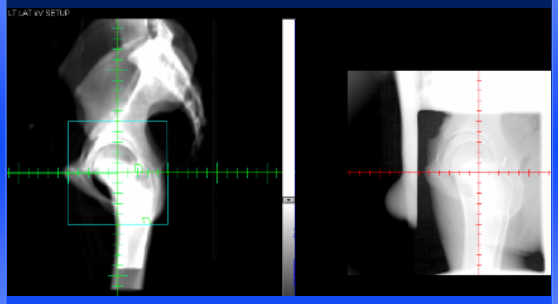

kV CBCT application for SBRT- Lung



kV CBCT application for SBRT- Prostate

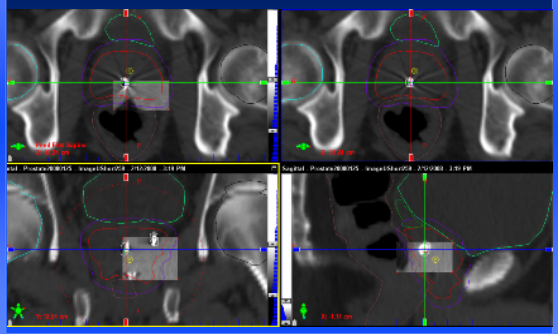

kV CBCT application for SBRT- spine

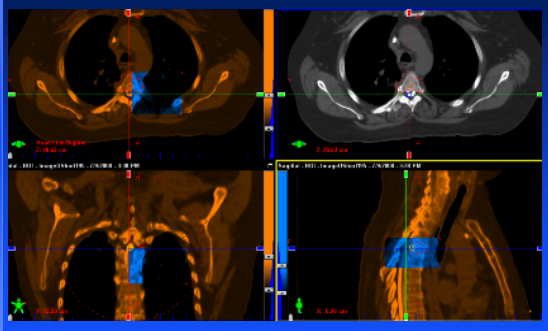

Monitoring treatment progress and ART



Feasibility of kV CBCT for treatment planning

Information from 2D images

- 2D projected verification images:
  - Bony anatomy relative to treatment isocenter
  - Seeds position relative to treatment field
  - Two orthogonal project images for 3D positioning
  - Treatment field shaped by MLC

Information from images

- 3D images from cone-beam CT:
  - Can be viewed in axial, coronal, and saggittal reconstructions from the volumetric images
  - Organ shape and position relative to isocenter
  - Small lung tumor
  - Can be used for monitor treatment progress and adaptive radiotherapy (ART)

Radiation doses

- Detailed list see AAPM TG-75
- 2D projected verification images:
  - MV beams EPID (1-2 MU ~ 1- 2 cGy/field)
    - Setup fields: two orthogonal beams
    - Treatment portal field
      - can be acquired during treatment (no additional dose)
      - Before or after (can be added to total dose)
    - Double exposure (area larger than the treatment field)

Radiation doses cont...

- 2D projected verification images:
  - kV beams from OBI device (~ mGy/field)
    - Setup fields: two orthogonal beams
    - mAs can be automatically adjusted (patient size↑ → dose↑)
    - Dose rapidly decreases as a function of depth in patient

Radiation doses cont...

- CBCT volumetric images:
  - scan area is larger than the treatment field (~cGy/scan)
  - Standard acquisition mode
  - Low-dose acquisition mode
  - For the same scan (patient size ↓ → dose ↑)

Dose dependency on depth

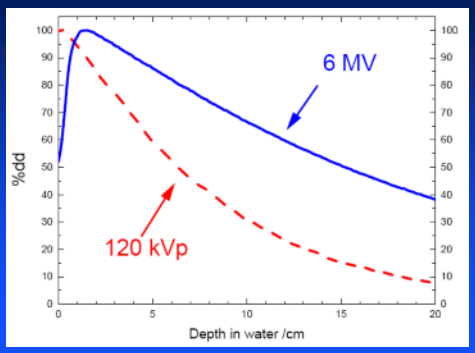

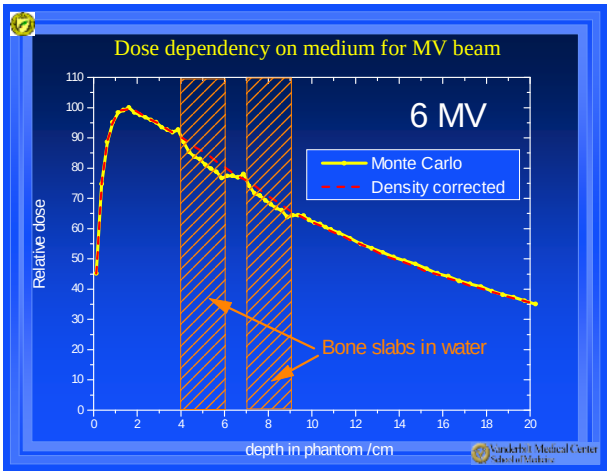
Dose dependency on medium for MV beam
6 MV
Monte Carlo
Density corrected
Bone slabs in water
Relative dose
depth in phantom /cm
Vanderbilt Medical Center
School of Medicine

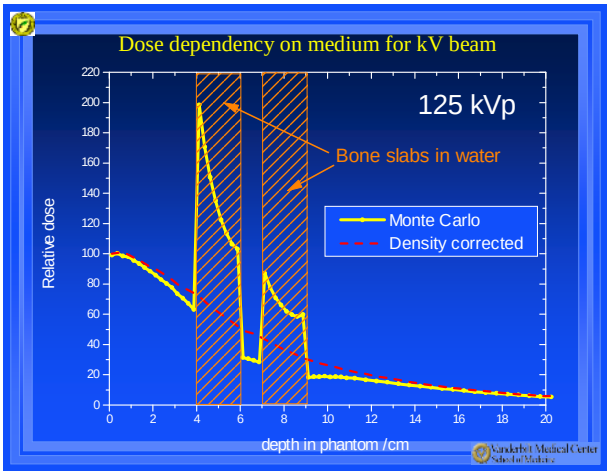
Dose dependency on medium for kV beam
125 kVp
Bone slabs in water
Monte Carlo
Density corrected
Relative dose
depth in phantom /cm
Vanderbilt Medical Center
School of Medicine

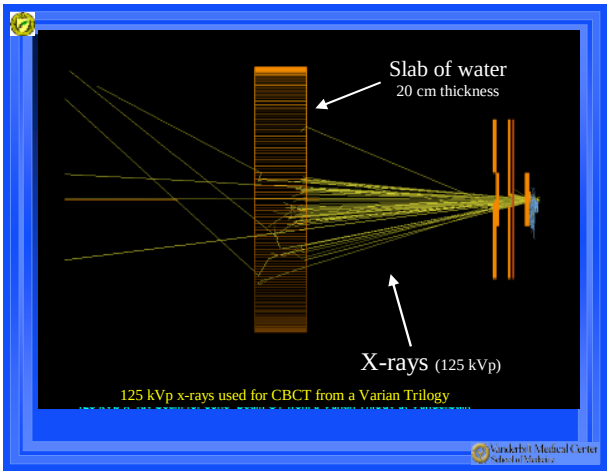
Slab of water
20 cm thickness
X-rays (125 kVp)
125 kVp x-rays used for CBCT from a Varian Trilogy
Vanderbilt Medical Center
School of Medicine

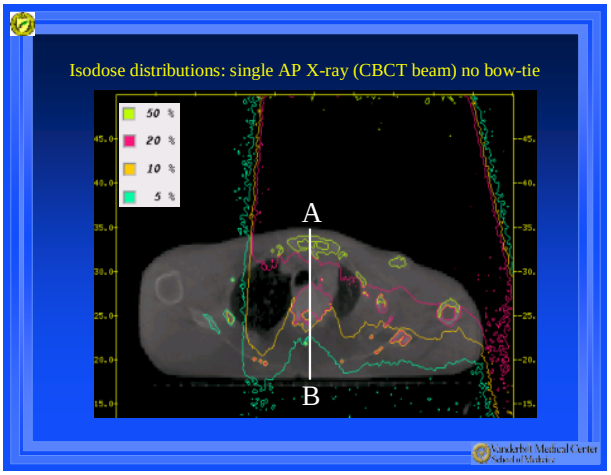
Isodose distributions: single AP X-ray (CBCT beam) no bow-tie
50 %
20 %
10 %
5 %
A
B
Vanderbilt Medical Center
School of Medicine

Isodose distributions: single AP 6 MV beam

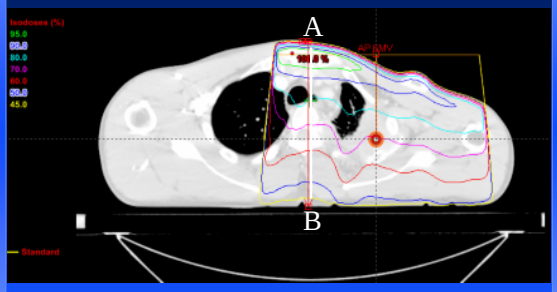

Dose profiles along the **line A-B** on chest CT: kV vs. MV

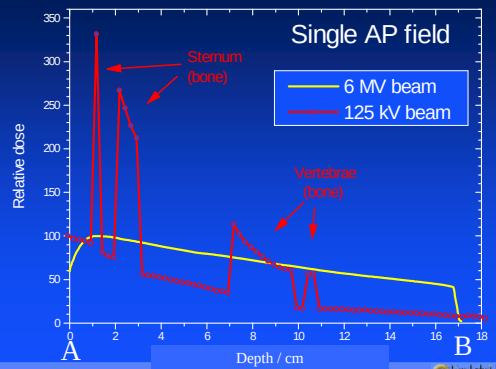

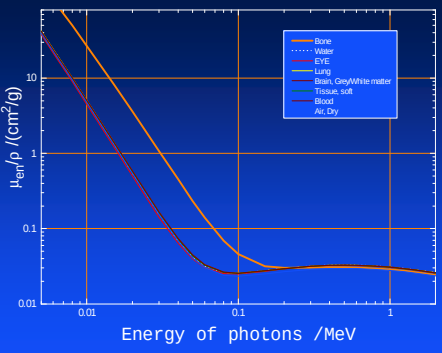

Data are from: J. H. Hubbell and S. M. Seltzer, "Tables of X-Ray Mass Attenuation Coefficients and Mass Energy-Absorption Coefficients," National Institute of Standards and Technology, Gaithersburg, MD NISTIR 5632, 1995.

Dose distributions resulting from a kV CBCT Head and Neck

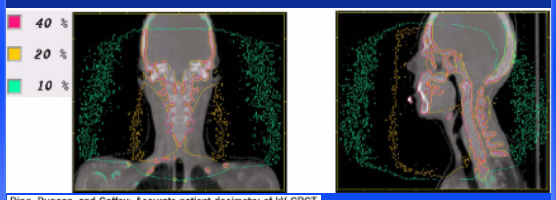

Ding, Duggan, and Coffey: Accurate patient dosimetry of kV CBCT
Medical Physics, Vol. 35, No. 3, March 2008

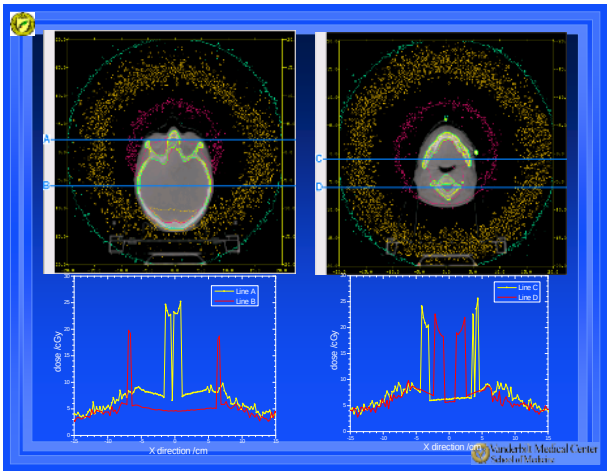
A
B
C
D
Line A
Line B
Line C
Line D
dose /cGy
X direction /cm

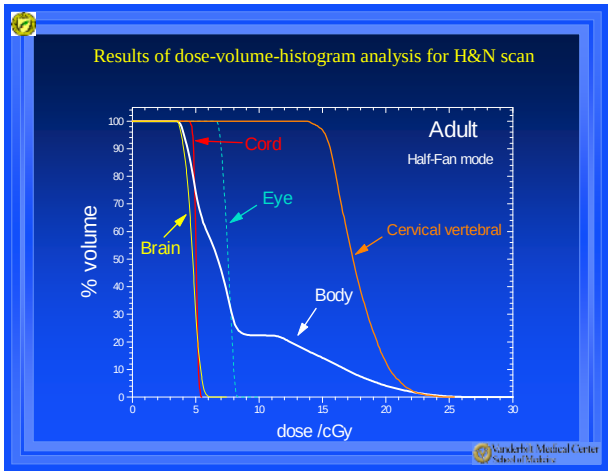
Results of dose-volume-histogram analysis for H&N scan
Adult
Half-Fan mode
Cord
Eye
Brain
Cervical vertebral
Body
% volume
dose /cGy

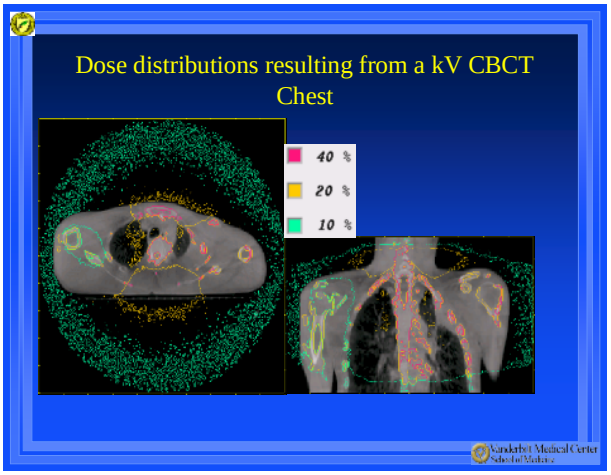
Dose distributions resulting from a kV CBCT Chest
40 %
20 %
10 %

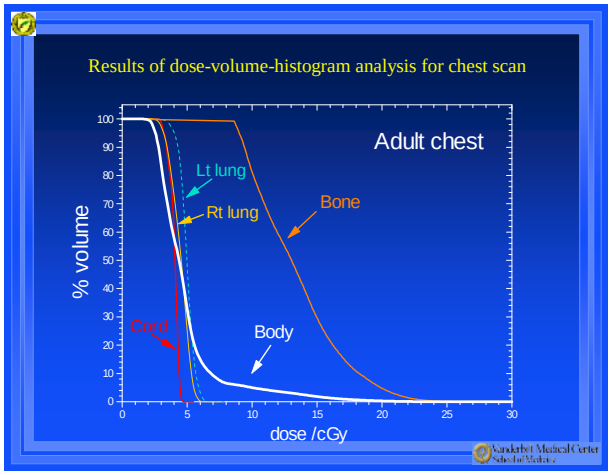
Results of dose-volume-histogram analysis for chest scan
Adult chest
Lt lung
Rt lung
Bone
Cord
Body
% volume
dose /cGy

Results of dose-volume-histogram analysis for a pelvic kV CBCT scan Large Adult

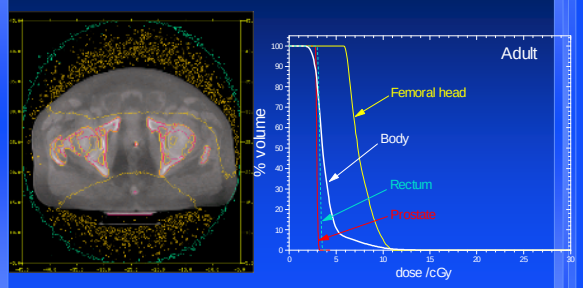

Dose distributions resulting from MV-CBCT: pelvic scan

Mitten *et al.*: IMRT incorporating MV-CBCT dose Medical Physics, Vol. 34, No. 10, October 2007

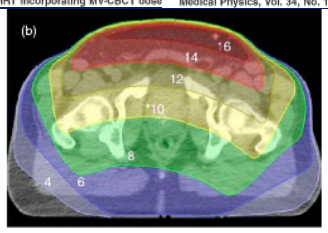

FIG. 1. (a) Examples of transverse images from a MV-CBCT dataset acquired with a dose of 10 cGy at isocenter using the 15 MU protocol. The bony anatomy, and soft tissue such as prostate, seminal vesicles, rectum, and bladder can be identified. (b) Distribution of dose deposited in the pelvis by a single fraction of CB imaging for the same prostate patient, with 10 cGy at isocenter. The isodose lines are labeled in cGy.

Summary

Commonly used image-guided procedures

- MV imaging:
  - megavoltage electronic portal imaging (MV-EPI)
  - megavoltage cone-beam CT (MV-CBCT)
    - On Linac unit
    - On Tomotherapy unit
- kV imaging:
  - kilovoltage digital radiography (kV DR)
  - kilovoltage cone-beam CT (kV-CBCT)
  - CT-on-rail

Summary cont...

Doses from image-guided procedures

- MV imaging:
  - MV-EPI: ~ 1-2 cGy /acquisition
  - megavoltage cone-beam CT (MV-CBCT)
    - Linac unit: ~ 5 – 20 cGy /acquisition
    - Tomotherapy unit: 8-12 cGy
- kV imaging:
  - kV DR: ~ mGy (entrance dose)
  - kV-CBCT
    - Soft tissue: 2 - 8 cGy /acquisition
    - Bone: 8 - 25 cGy /acquisition

Summary cont...

- Imaged area is larger than the treatment field
- Imaging-guidance procedures are more frequent than diagnostic imaging
- Repeated imaging procedures can sum up significant dose to radiosensitive organs
- kV DR imaging: high entrance dose
- exit dose (~ 5% of entrance dose)
- MV EPID imaging: exit dose (~50% of entrance dose)

Summary cont...

- MV beam imaging:
  - Dose resulting from MV-CBCT is comparable to that of multiple portal imaging acquisitions
  - Negligible difference between dose to bone and dose to soft tissues
- kV x-ray imaging:
  - Dose resulting from kV-CBCT is much larger than that of multiple kV DR acquisitions
  - Dose to bone is 2-4 times higher than the dose to soft tissues
  - Dose to bone marrow? (see Kawrakow et al WE-E-332-04)

What to do now?

- Improve imaging technology (manufactures)
  - Increase image quality and decrease the dose to patients
  - Progress is being made
- Use imaging guidance efficiently:
  - Choose the procedure and the frequency that is most suitable for the purpose
  - Develop protocols for using image guidance procedures
  - Pay attention to pediatric patients and imaged volume
- Account imaging guidance dose for radiotherapy patients
  - Calculate organ doses resulting from image guided procedures
  - Account them as part of total dose to patients in radiotherapy treatment planning systems

Acknowledgements

Matthew Deeley,	Vanderbilt University
Kenneth Lewis,	Vanderbilt University
Fitz-William Taylor,	visiting student from USMA at West Point
ACCRE	Vanderbilt Advanced Computing Center for Research and Education