Artifacts in Digital Mammography

W. Geiser, M.S.[1] G. Whitman, M.D.[2], T. Haygood[2], PhD, M.D., T. Stephens, M.D.[2], L. Santiago, M.D.[2], D. Thames, RT(R)(M)

1. M.D. Anderson Cancer Center, Imaging Physics, Houston, Texas, United States
2. M.D. Anderson Cancer Center, Diagnostic Imaging, Houston, Texas, United States

Disclosure of Commercial Interest

None of the authors nor their immediate families have a financial relationship with a commercial organization that may have a direct or indirect interest in this content.

Introduction

Mammography is the gold standard for detection of breast cancer. Early detection of breast cancer is directly related to the mammographer's ability to detect abnormalities visible only on high-quality mammograms.

Artifacts on mammograms reduce image quality and may present clinical and technical difficulties for the mammographer, mammography technologist, medical physicist, and for equipment service personnel.

Recognizing artifacts improves the quality of mammographic interpretation and prevents characterization of artifacts as real breast pathology.

Artifacts in digital mammography

- Detector based artifacts
- Machine based artifacts
- Patient related artifacts
- Processing and storage artifacts

Detector based artifacts

- Dead Pixels
- Dead or unread lines
- Non-uniformities
- Ghosting

- Dead pixel group projecting over an implant.

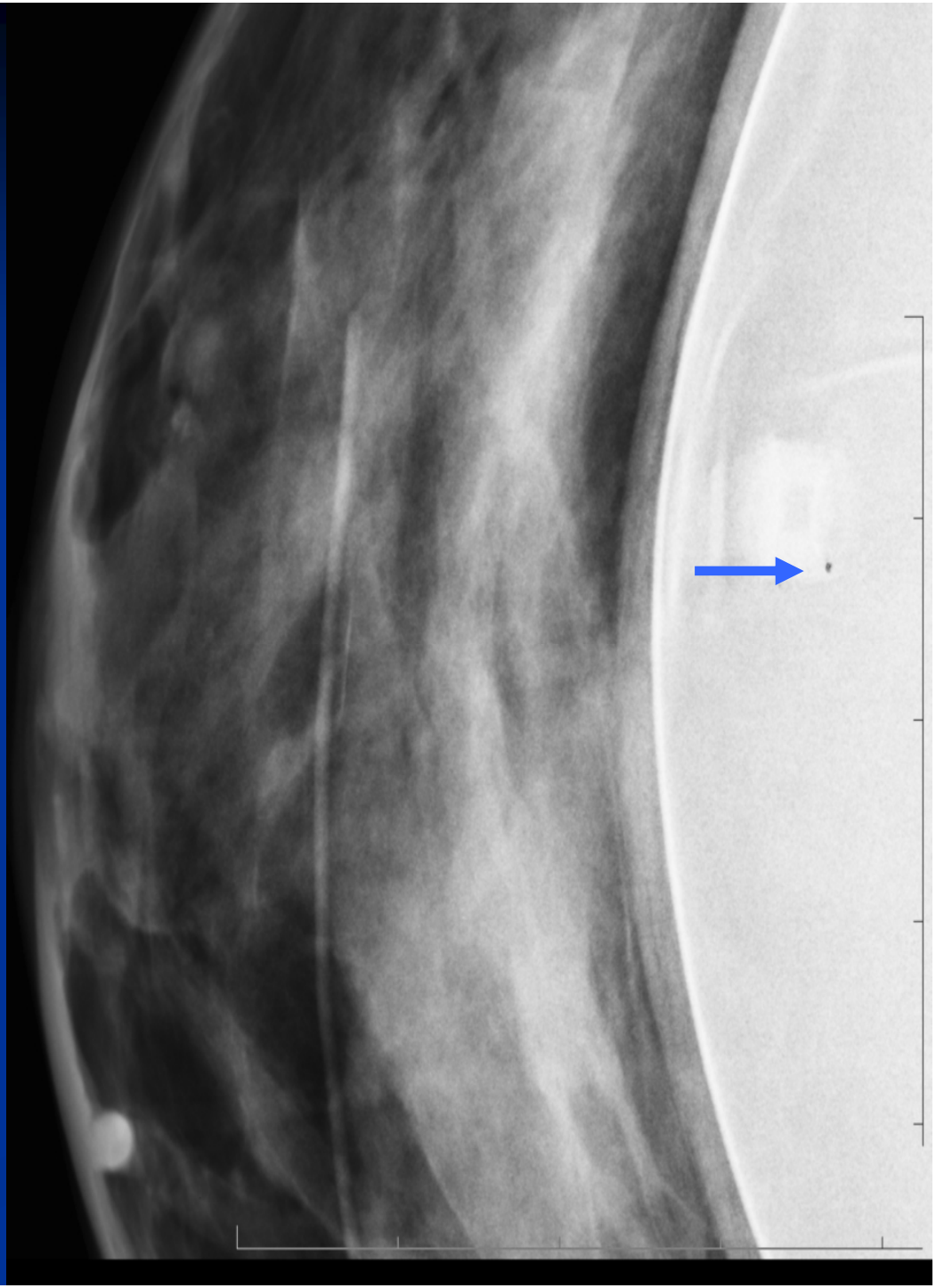

- The same dead pixel group seen in a standard LCC view.
- Individual dead pixels are mapped out by the service engineer.

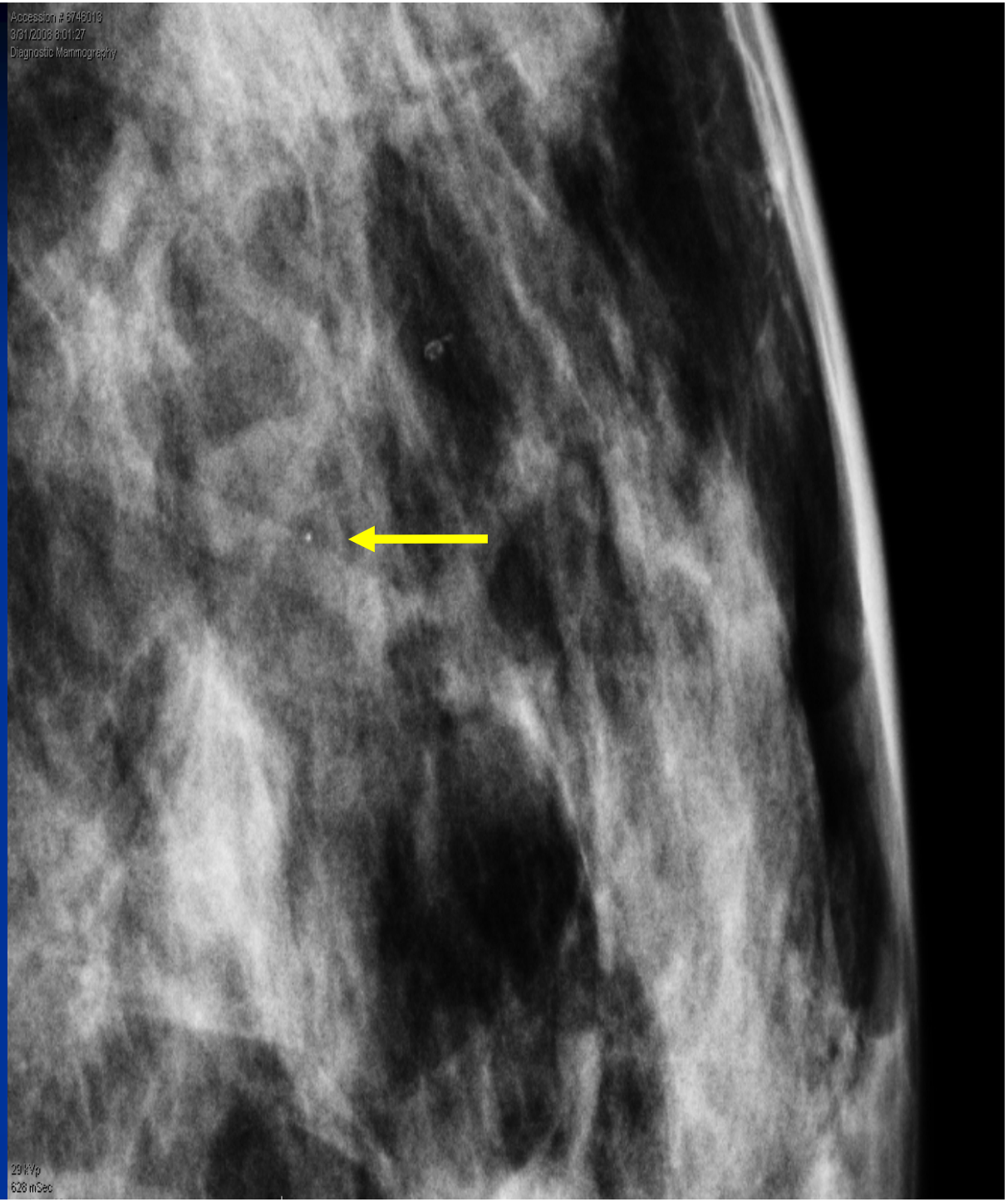

Detector failure

- As a detector gets damaged by exposure to radiation, pixels begin to be damaged and no longer operate properly. The following images show a detector at the end of its useful life. Note the many dead pixels and how they look like small scattered calcifications. Subsequent testing using a flat field phantom and the ACR accreditation phantom showed the damage to the detector. This detector was replaced.

- FFDM detector failure showing large numbers of misread or dead pixels. These can look like clusters of micro-calcifications

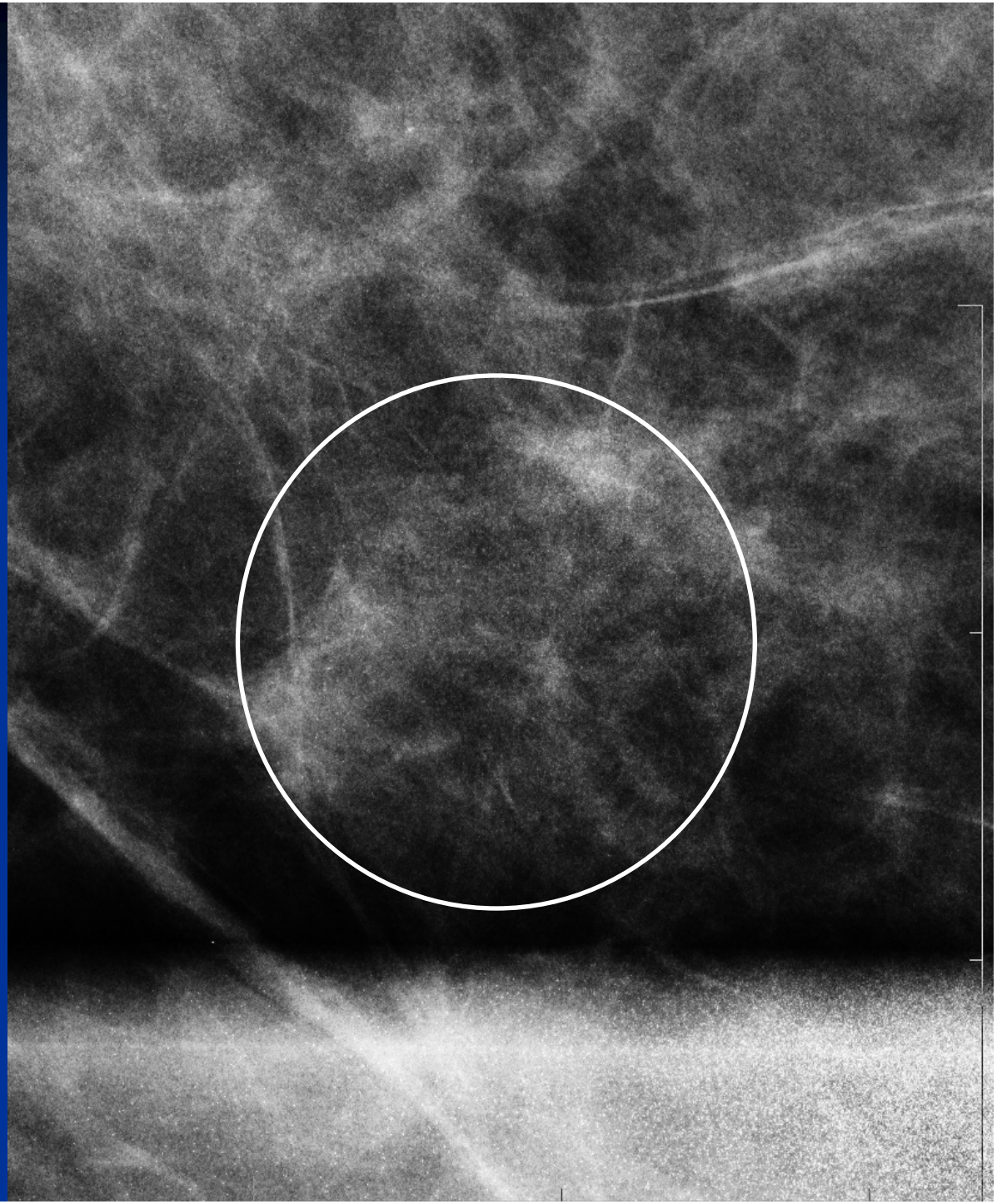

- Flat field image of a detector as it starts to fail. Note the white band of dead pixels.



- Magnification image of the ACR Accreditation phantom on a detector as it starts to fail. Note the white band of dead pixels.
- This room was taken out of service immediately and the detector replaced within a couple of days



Dead lines or misread lines

- Technologist took image and noted an artifact
- Continued with exam
- Artifact disappeared on next image
- Retake of same projection was satisfactory
- Determined that gate line did not turn on

- Failure of a line to read out during read out of the detector.
- System corrected itself on repeat exposure.

Other Detector Artifacts

- Small dark spot
- Determined to be from detector
- Cannot be calibrated out
- Detector was replaced

Ghost Image

- Selenium detector technology had ghosting problems
- Temperature of detector plays large part
- Ensure that detector is at proper temperature to prevent ghosting

Ghost of the previous MLO image is visible on this RLM.

This ghost image was cause by incorrect detector temperature. Allowing the detector to warm up properly cleared the problem.

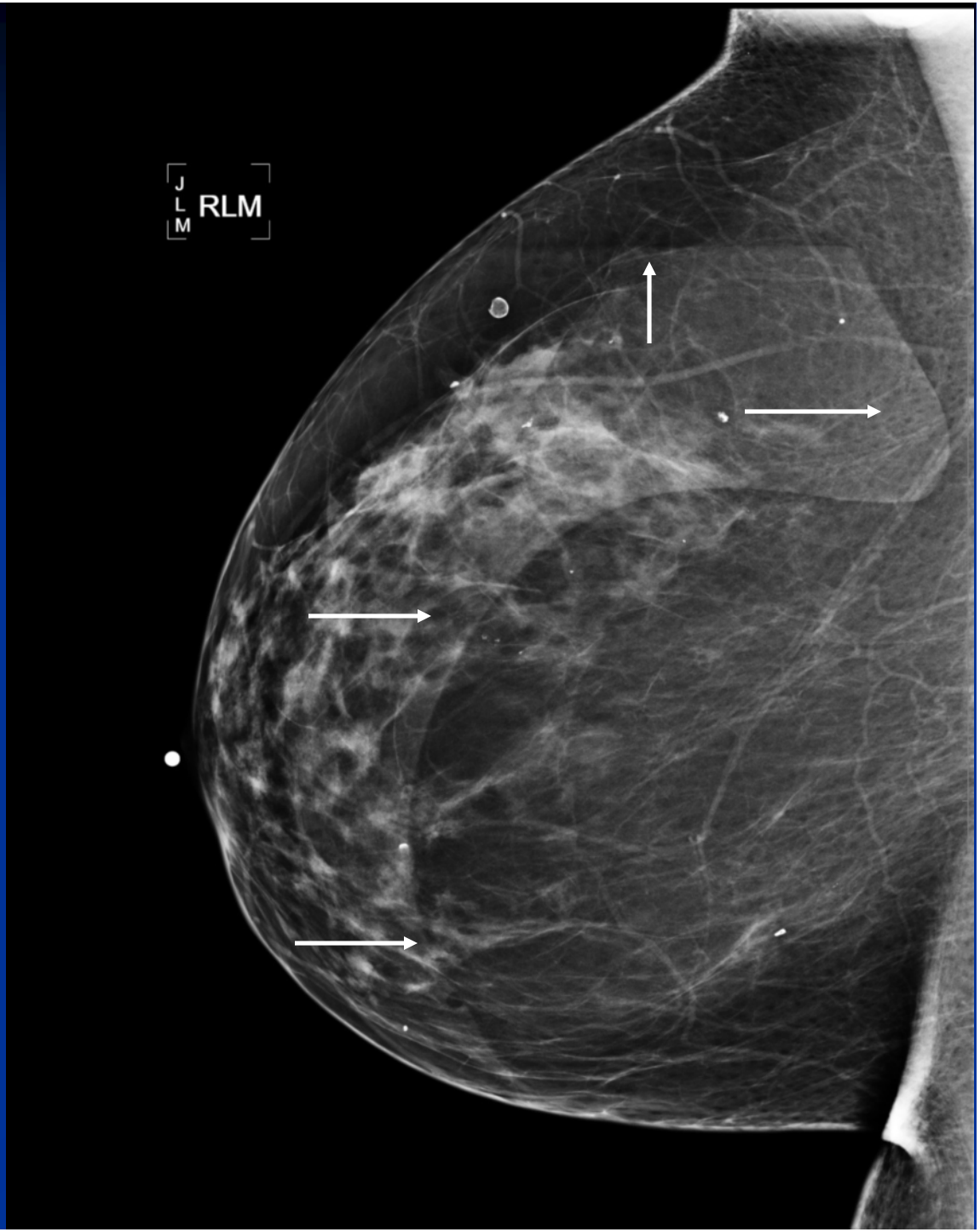

Machine Based Artifacts

Machine based artifacts are those artifacts that are related to components on the gantry but not part of the detector. Most of these artifacts come from dirt or dust on the compression paddle or problems with the tube filtration and the grid.

With digital systems, technique can also play a role in the look of the image. The image may process well and have the correct contrast and grey scale. But improper technique may cause high noise which may obscure small objects that need to be seen.

Dust or Dirt on Compression Paddle

- Dust or dirt on the compression paddle may mimic calcifications or masses. Look for an artifact that is seen on two different images but in the same area of the detector (flipped and rotated). Through cleaning of the compression paddles at least weekly will prevent this type of artifact

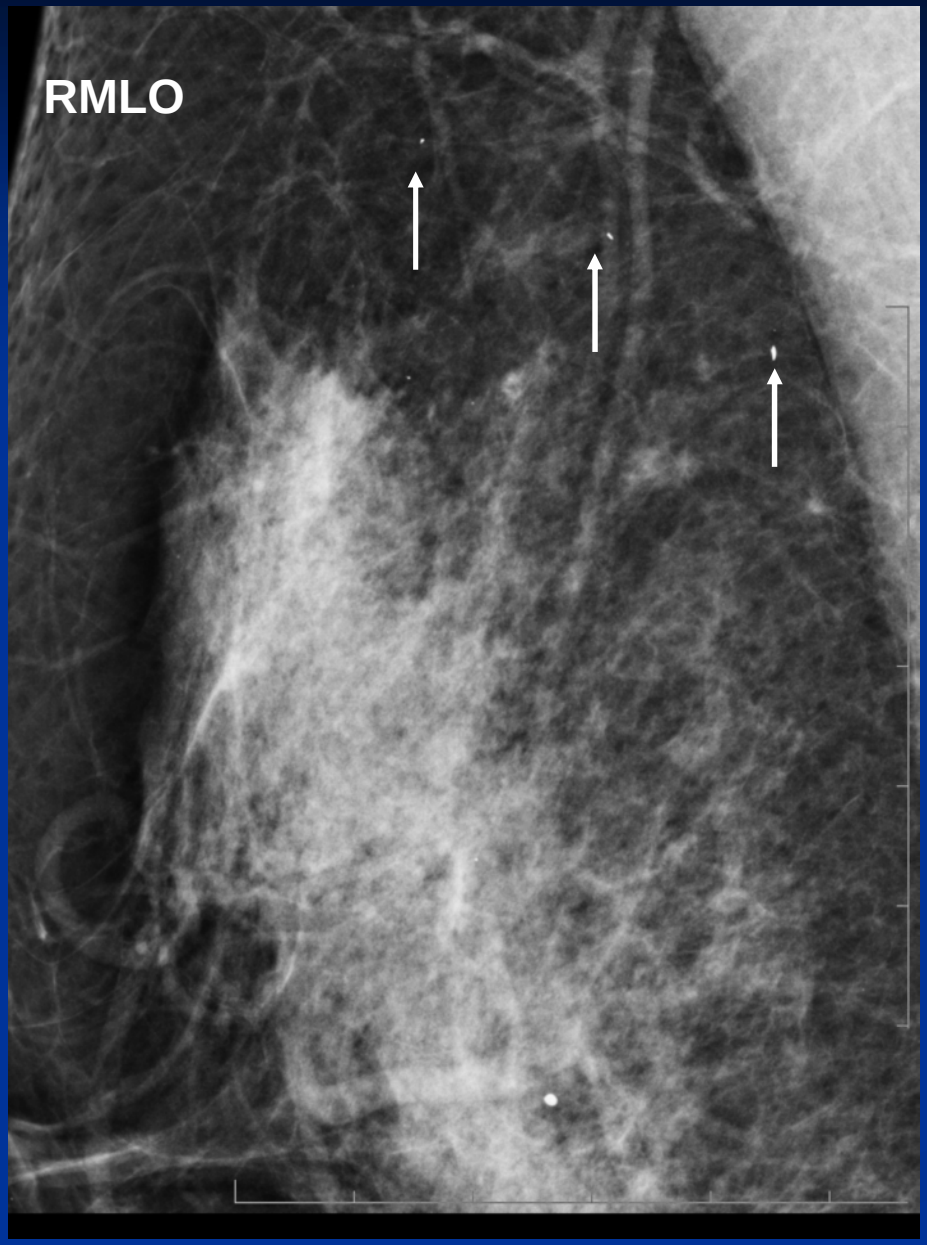
RMLO

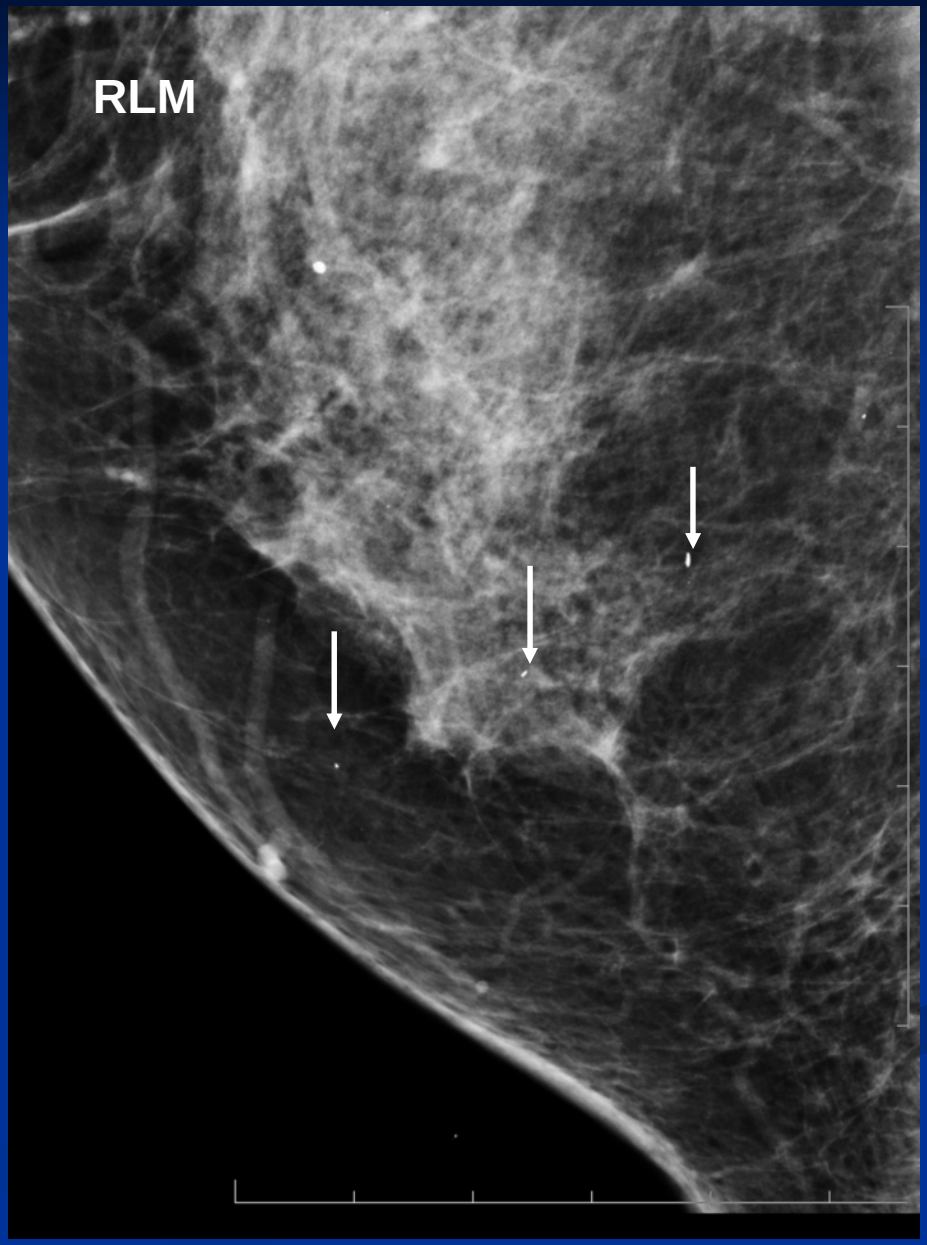
RLM

- Edge of the compression paddle seen on the image.
- The compression paddle needed to be realigned so that its shadow was not longer visible along the chest wall edge of the image
- Check all paddles on during annual testing

Technique Problems

- Clearly visible calcification seen through a hematoma on a standard LCC
- Noise on the LMCC image obscures the calcification. This image should be repeated at a higher kVp and with an exposure compensation of at least 2.

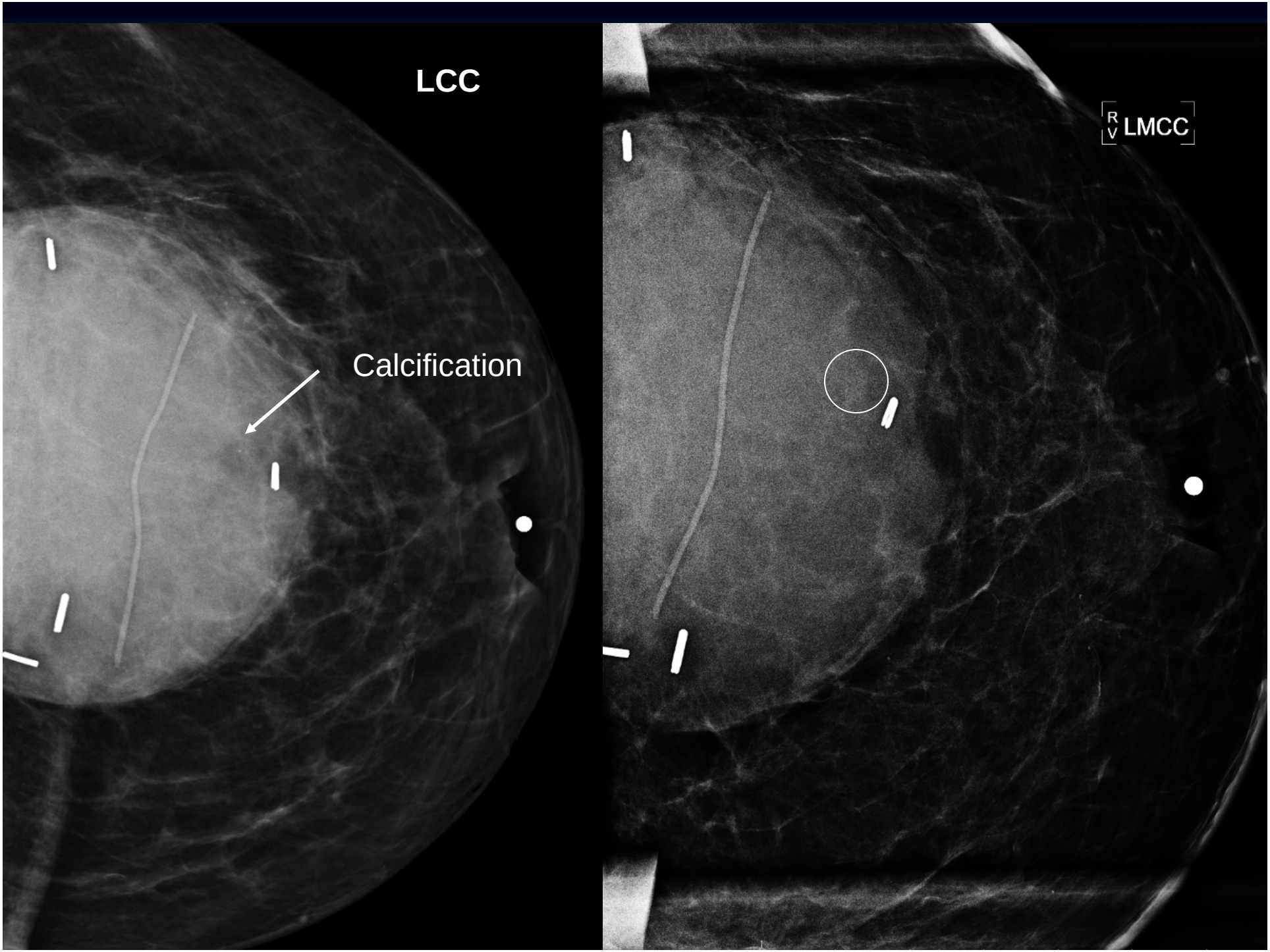
LCC
Calcification
R
V
LMCC

- Gridlines on image. These gridlines were caused by having the grid speed set incorrectly. This caused the grid to be stopped during the exposure, leaving the grid shadow on the image (cross hatch pattern in the region of the clip marker).

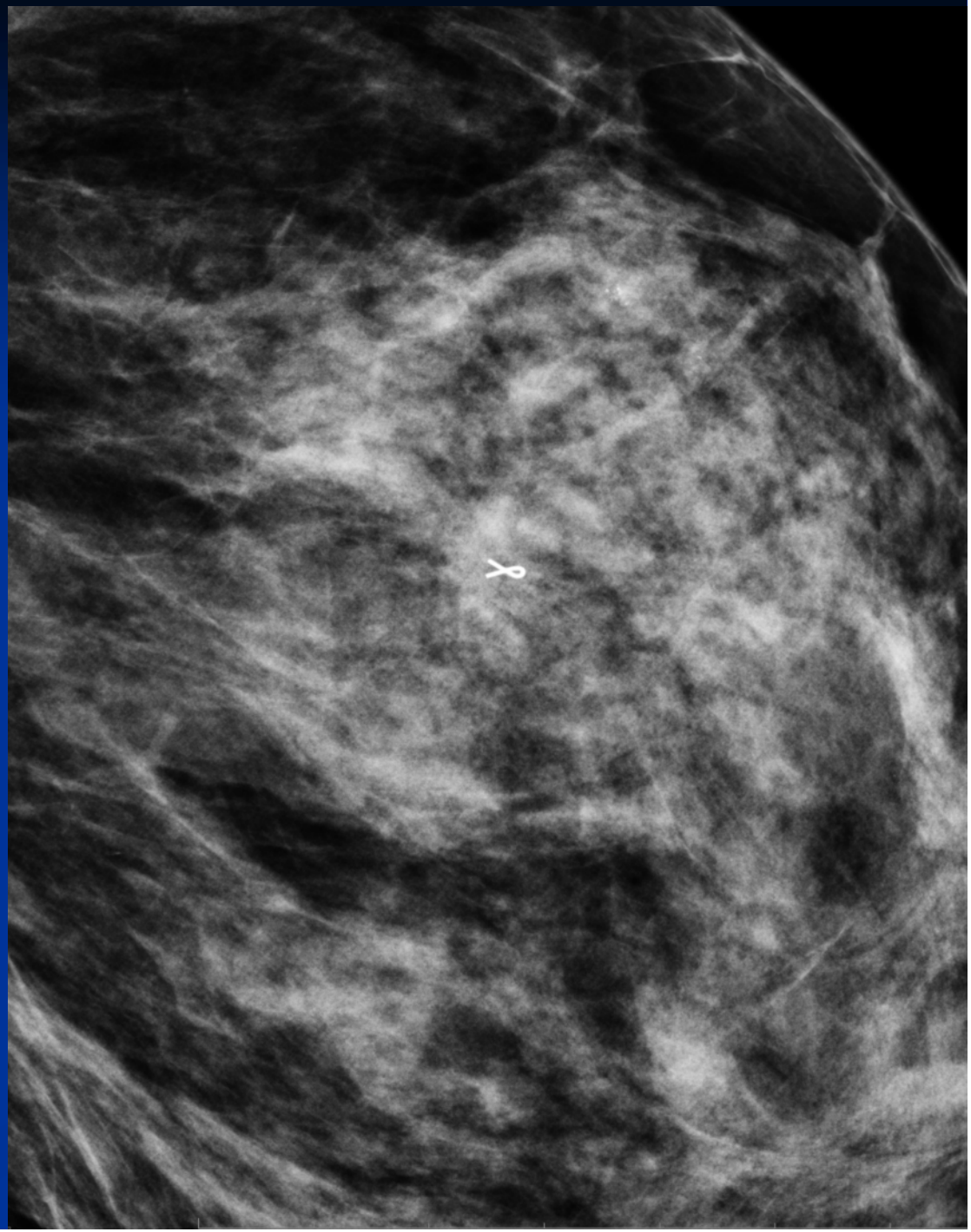

Patient Related Artifacts

- There are many different types of patient related artifacts. The most common artifact is patient motion. Other types of artifacts include hair, gowns or other foreign objects laid over the breast during imaging. At other times the technologist may not notice that the patient has placed a hand on the breast support plate or compression paddle or that there are other foreign objects in the image field.

- Blurring of the image due to patient motion. The edge of the clips have a definite shadow
- Repeat of the image without patient motion shows the clips in focus

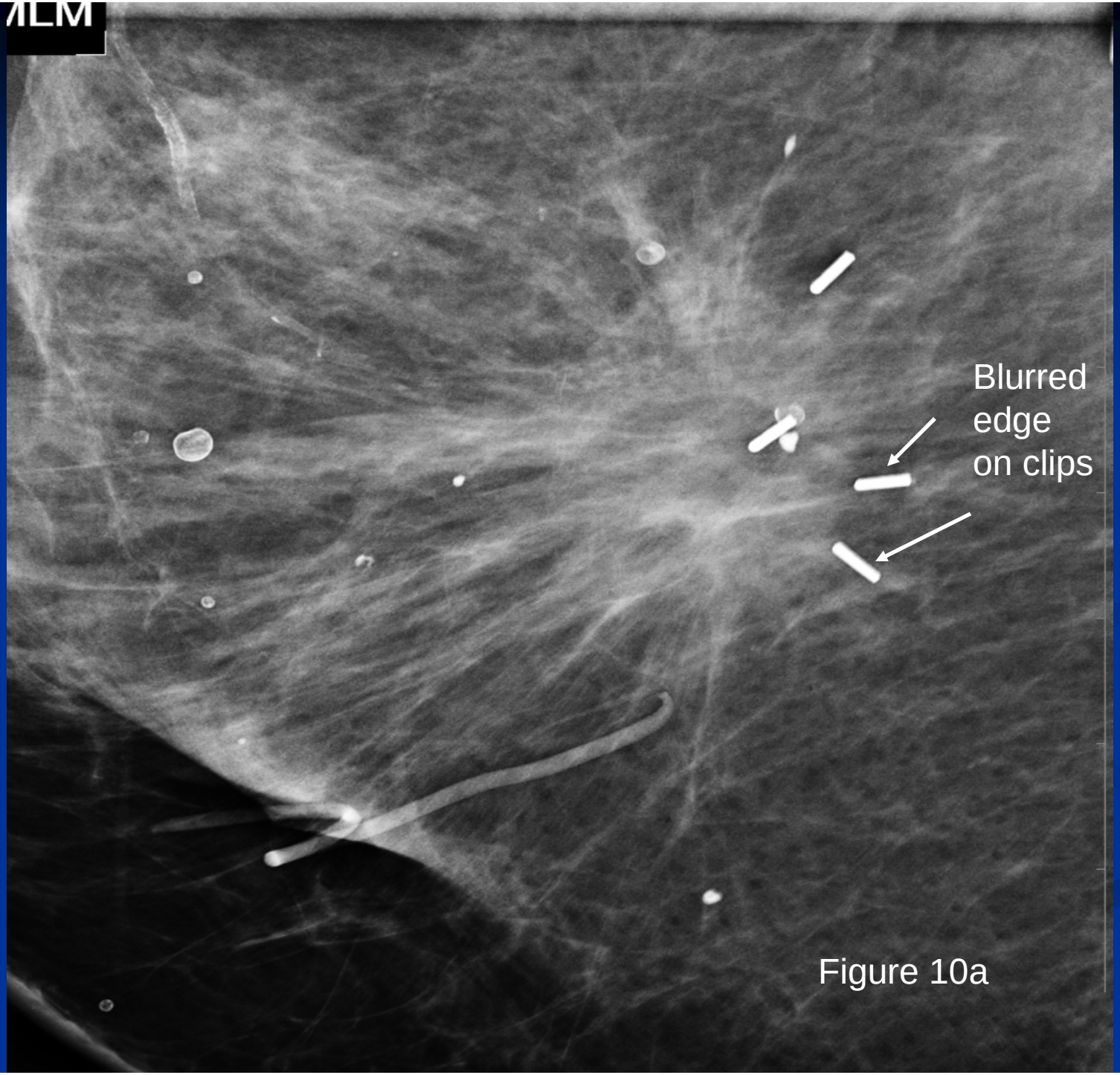

Figure 10a

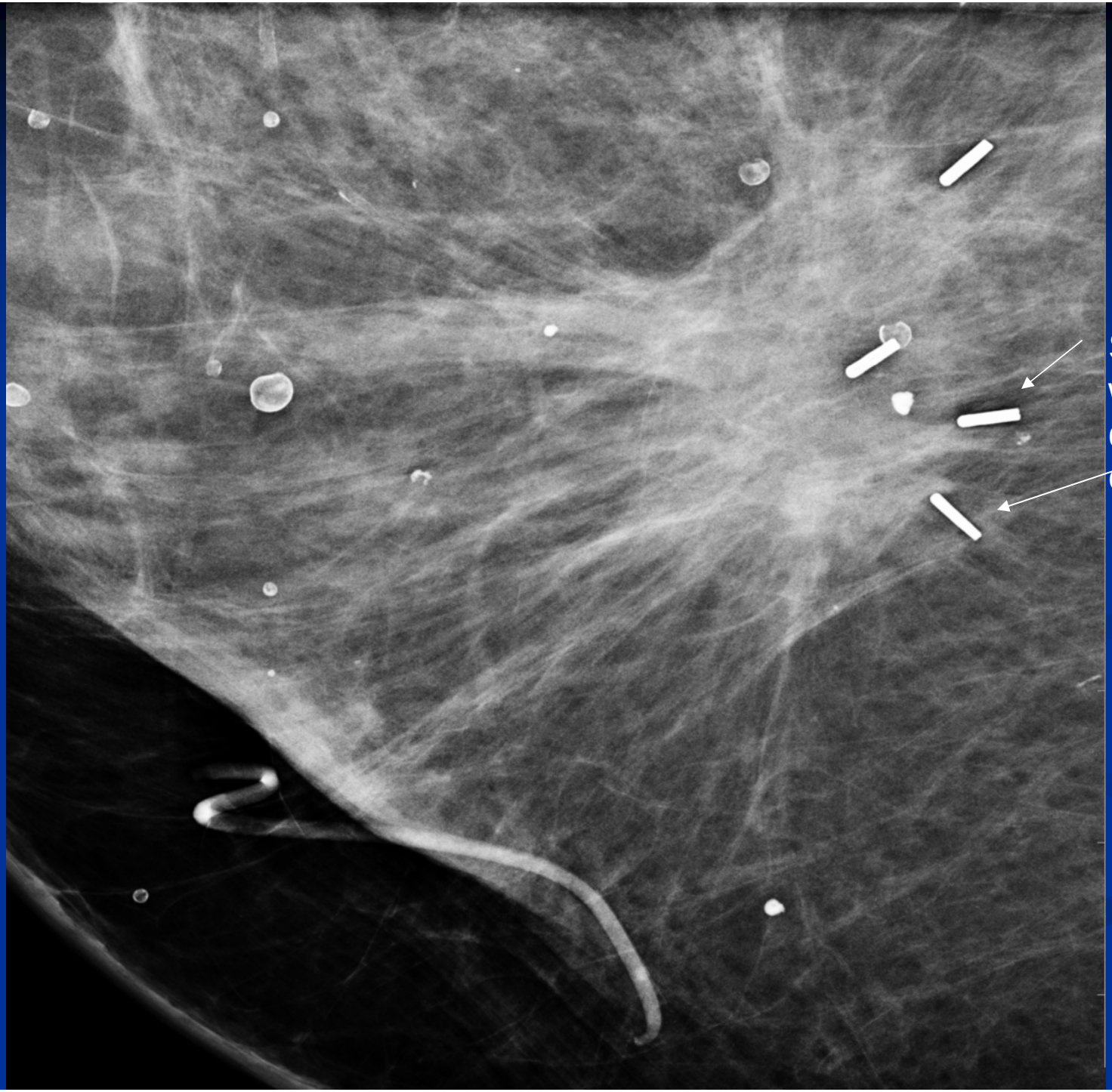
Sharp
well
defined
clip edges

- Tape on the breast. This can cause anatomy to be obscured on the image.

- Pathology other than cancer can be an artifact also. Here a patient has a yeast infection with coarse, flaky skin that mimics calcifications on the initial study.

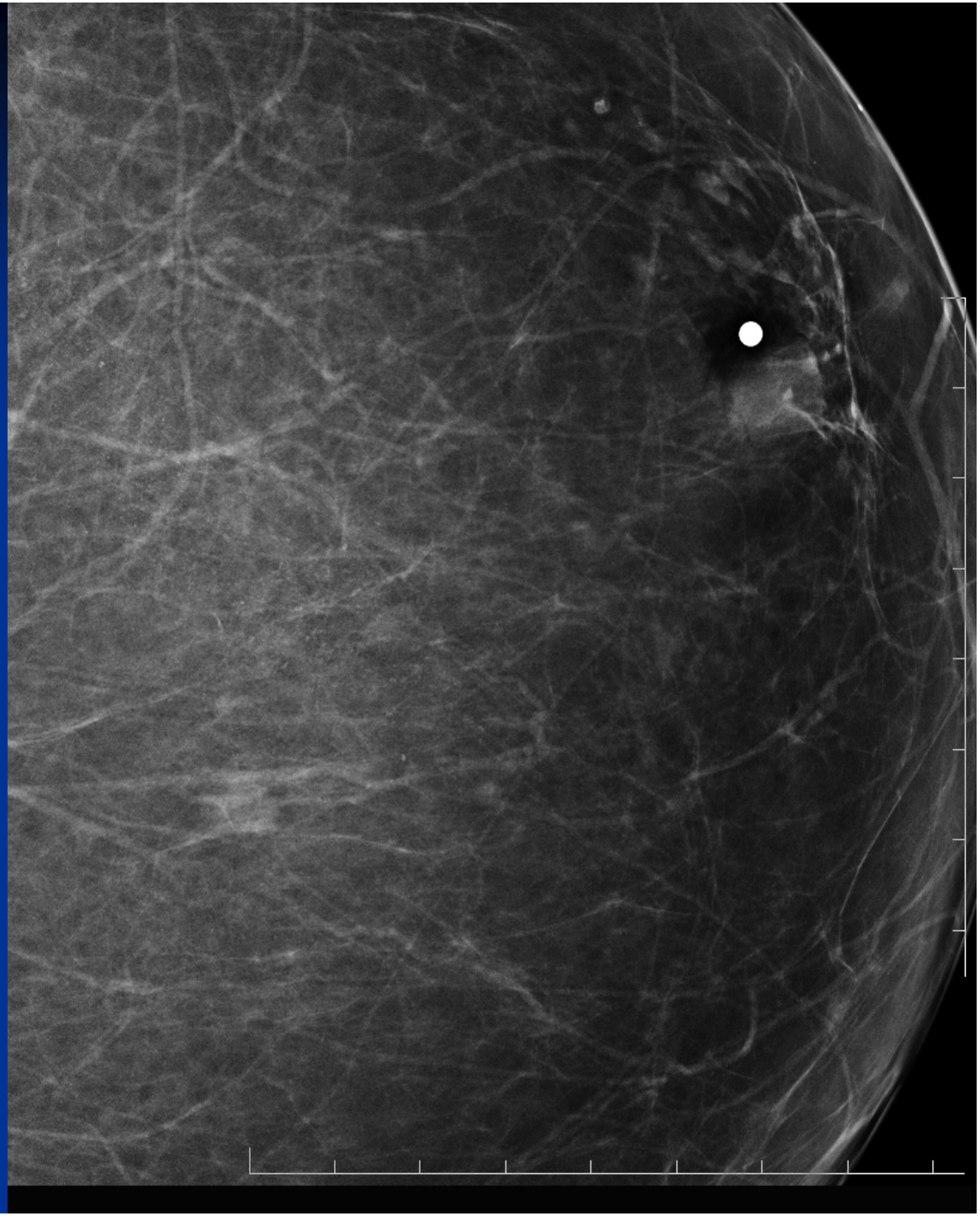

- Imaging of the patient a month later after the condition has cleared. The “calcifications” are no longer visible.

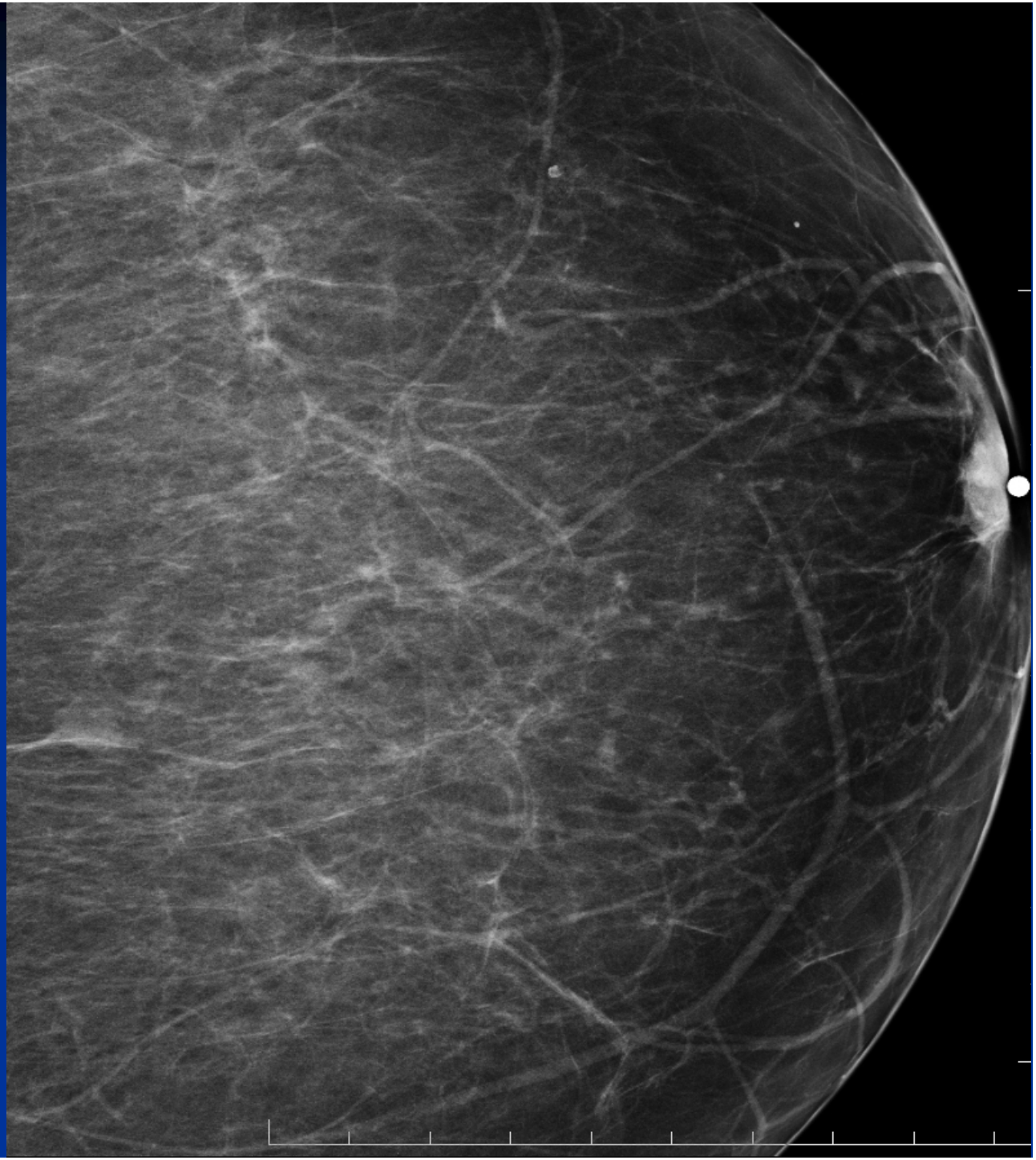

- Patient with a port for a central line.
- Note the dark halo surrounding the port. This is a common processing artifact.

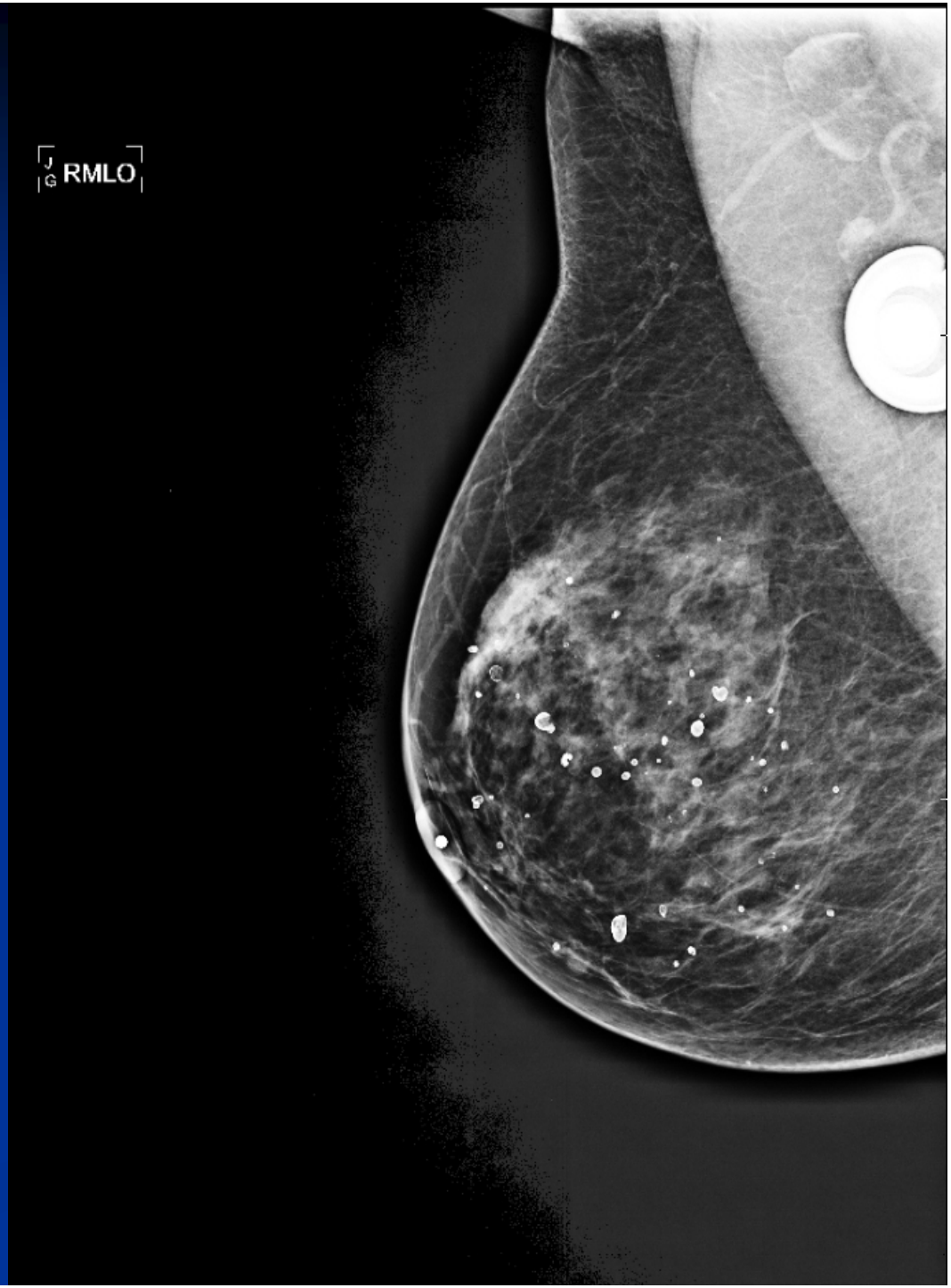

- Eye glasses in image field

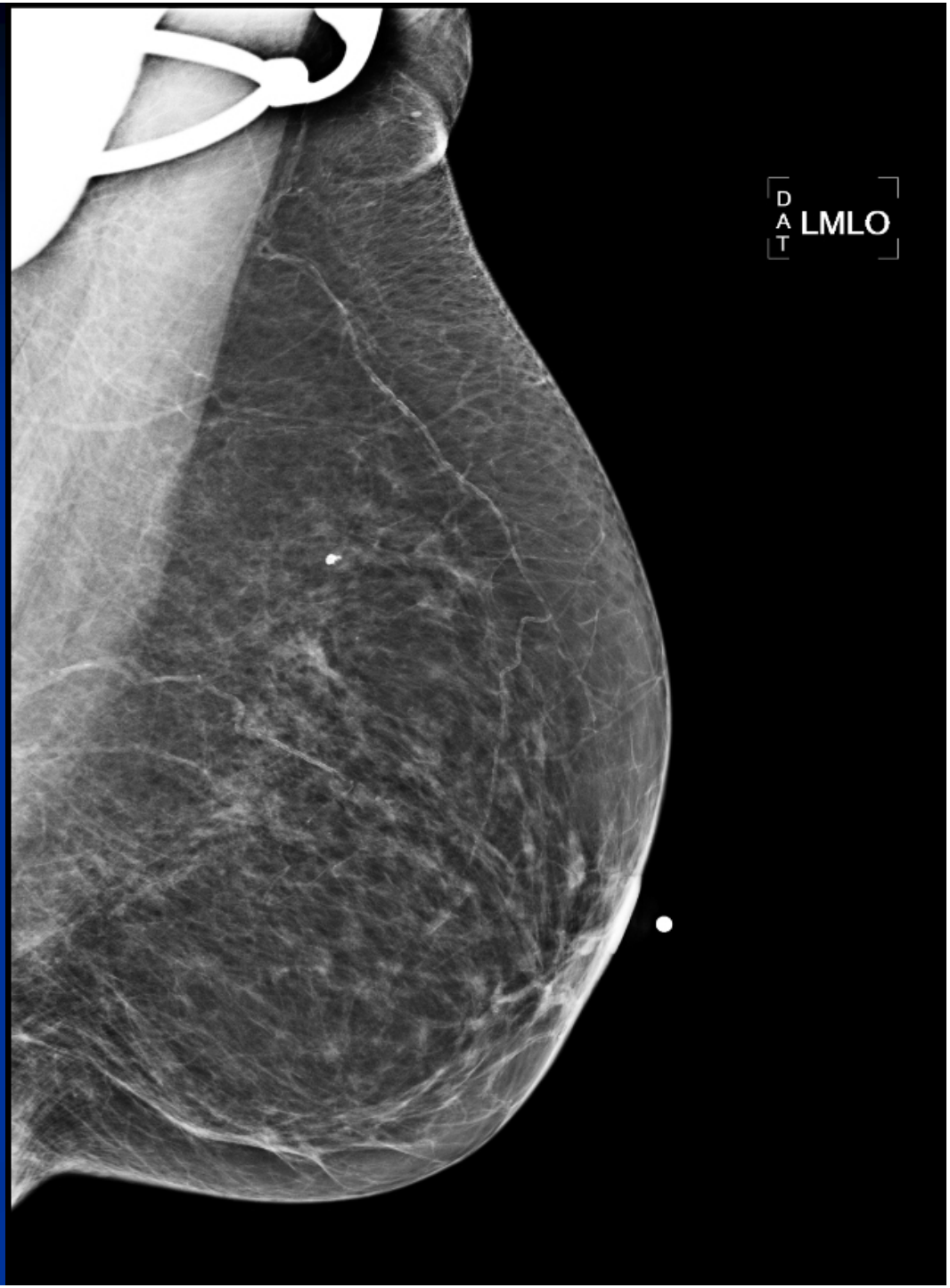

- Ear and earring in image field on LCC

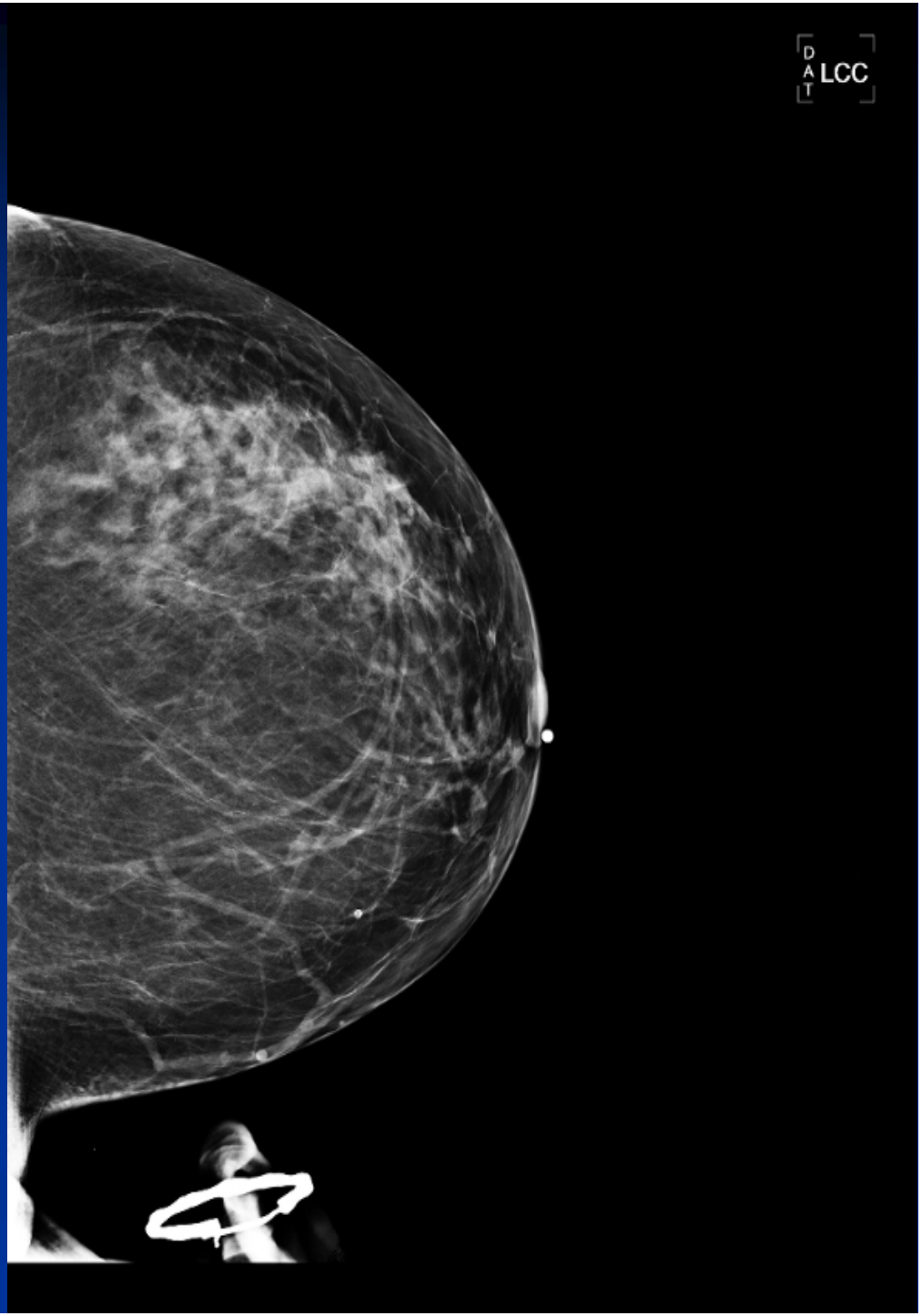

- Free silicone injections obscure pathology

- Scar marker with the tape used to hold it on the patient clearly visible.

Processing and Storage Artifacts

- Processing artifacts are those artifacts caused by the inability of the processing algorithm to be able to compensate for differences in exposure across the detector.
- Storage artifacts are caused when the PACS system does not properly reconstruct the image for display or does not properly interpret the DICOM header information stored with the image, giving improper display parameters.

- Figure 18: Detector interface line on an irradiated breast. This is caused by a slight difference in calibration of the two halves of the detector.

- The following two images show what happens when the skin line processing parameter is set incorrectly. The undersized breast is displayed with a grey halo around it due to failure of the skin line to be processed and displayed correctly.

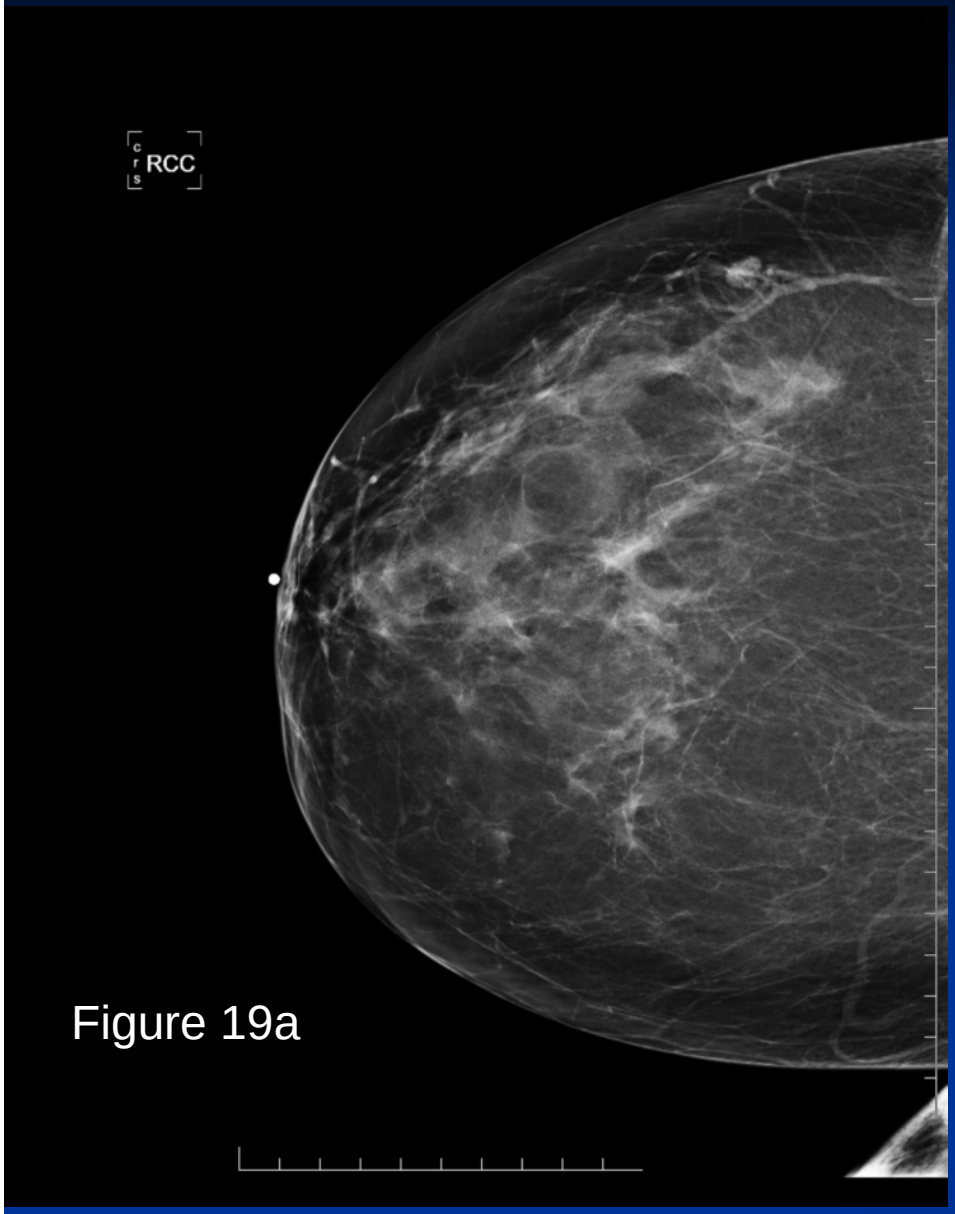

Figure 19a

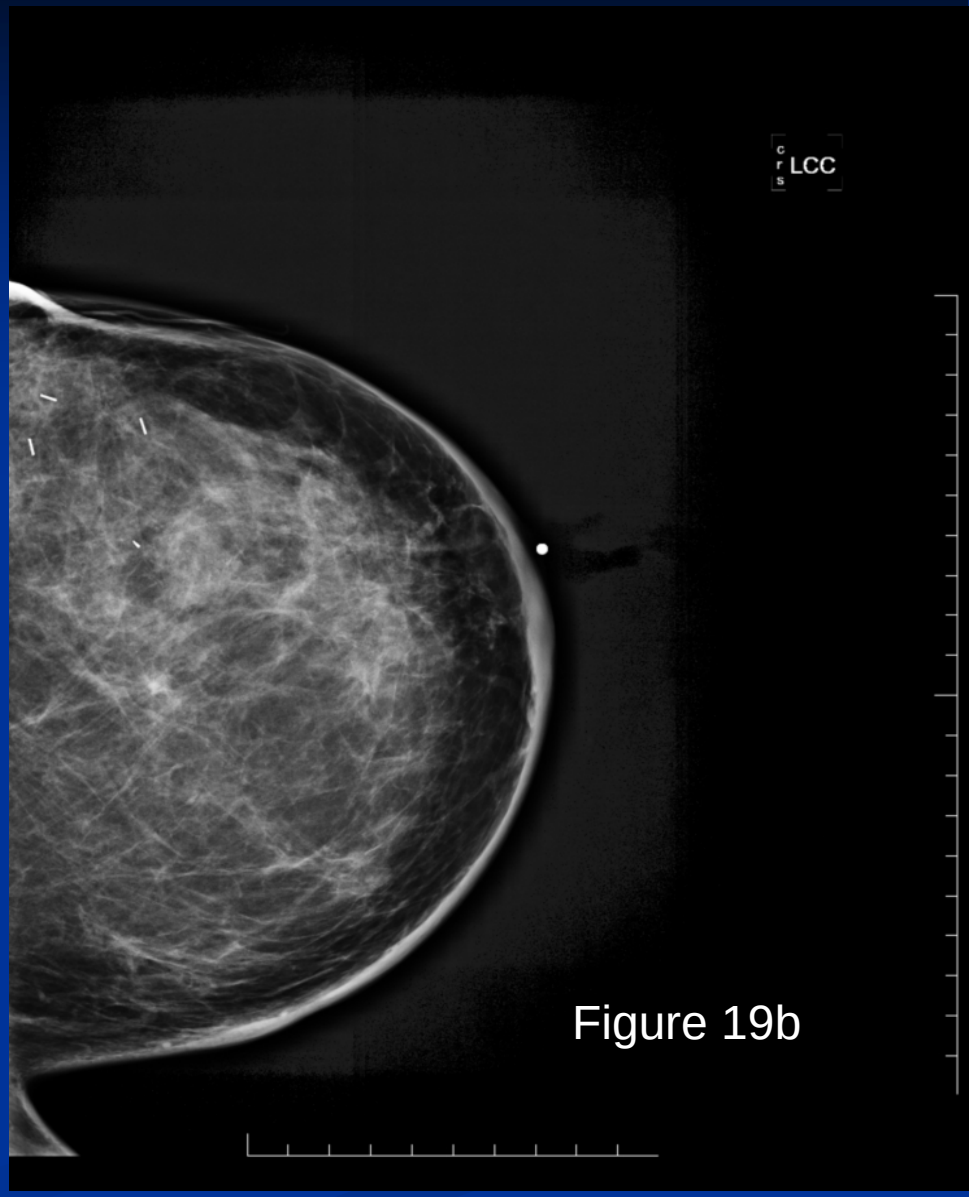

Figure 19b

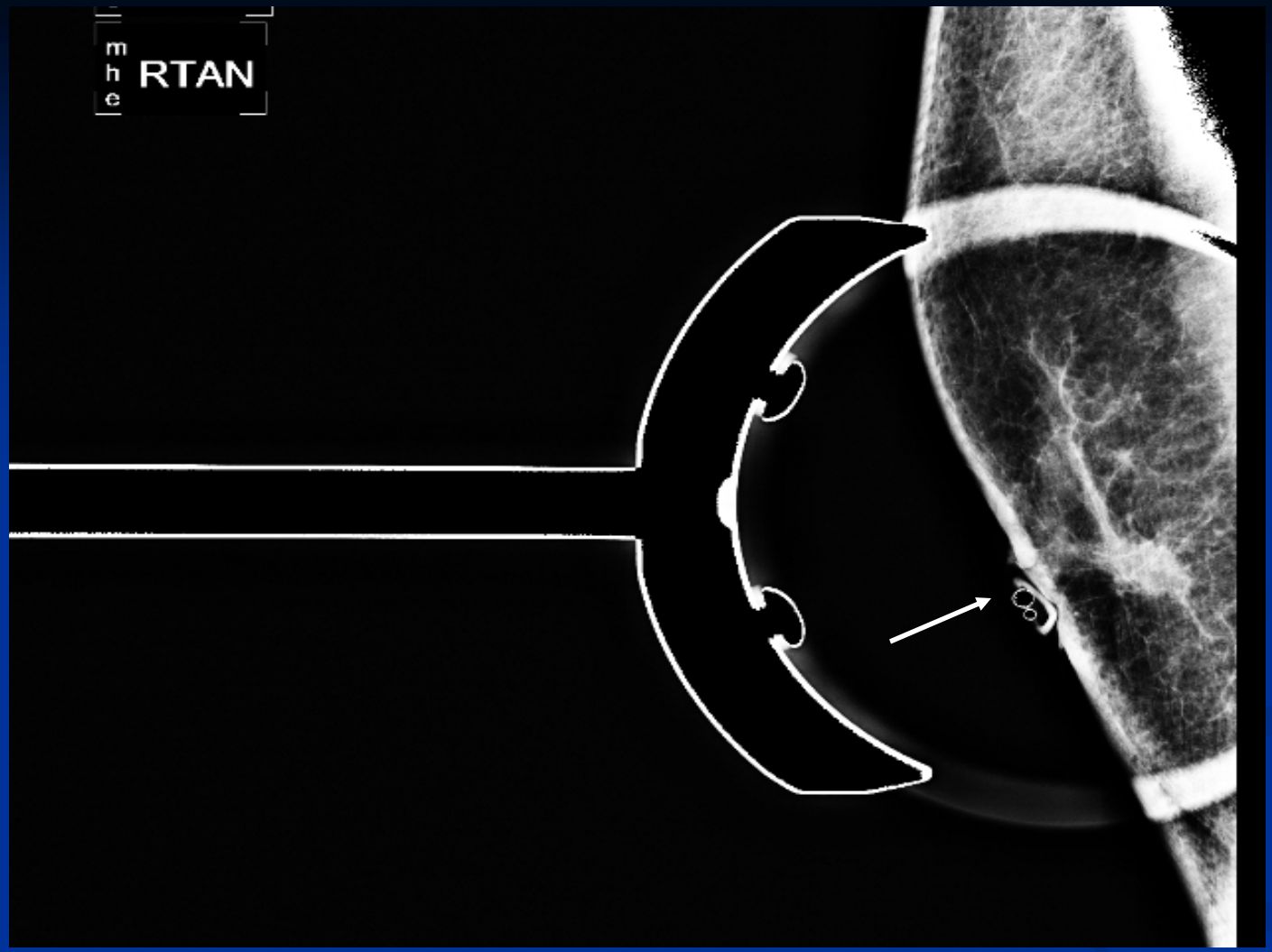

Inversion of pixel data on the nipple marker. Nipple marker should appear bright on the image. Here the marker has been made dark by the skin line processing algorithm

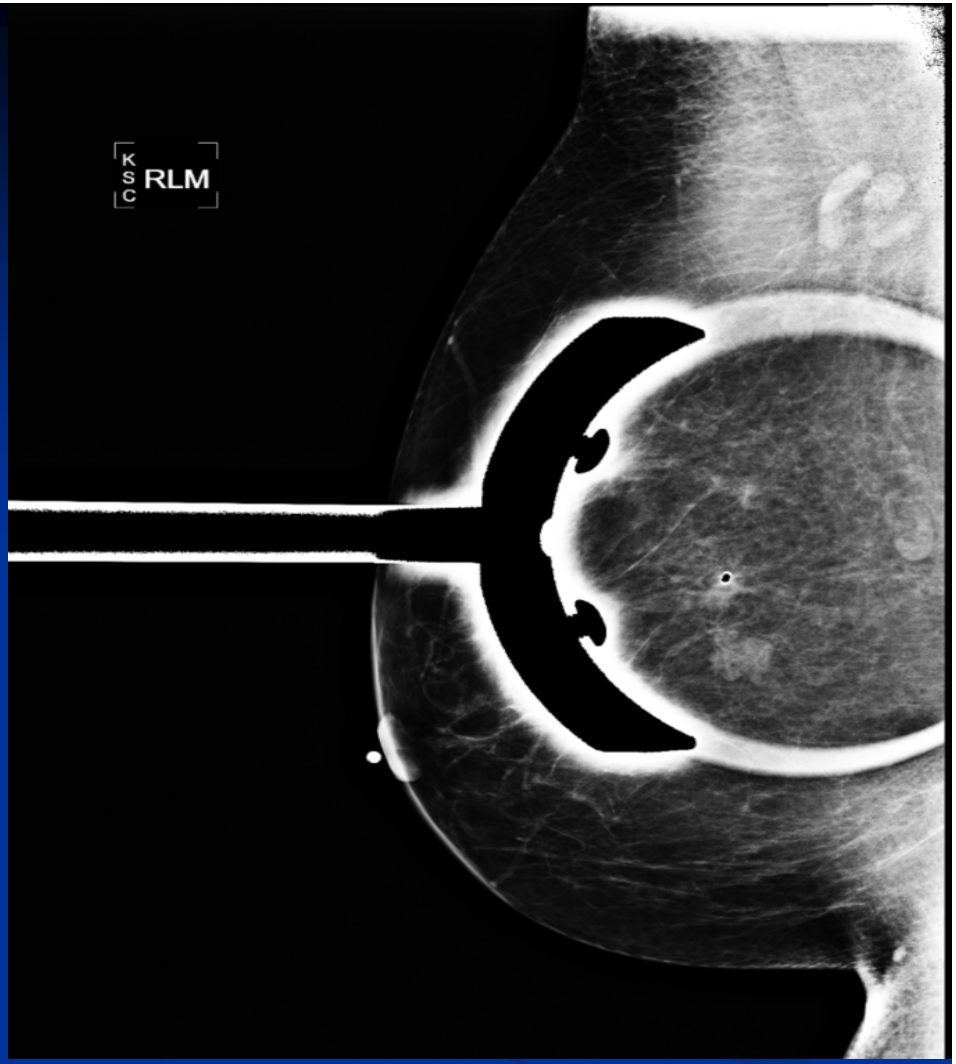

- Pixel drop out on a clip on a spot view. This is caused by the effect of the spot paddle on the image processing algorithm.

- Reconstruction artifact caused by PACS and incorrect storage of the frequency coefficients for this image.
- This image cannot be recovered from the PACS system. It needed to be deleted and resent.
- It is important that the technologist check the images sent to PACS after the completion of the study.

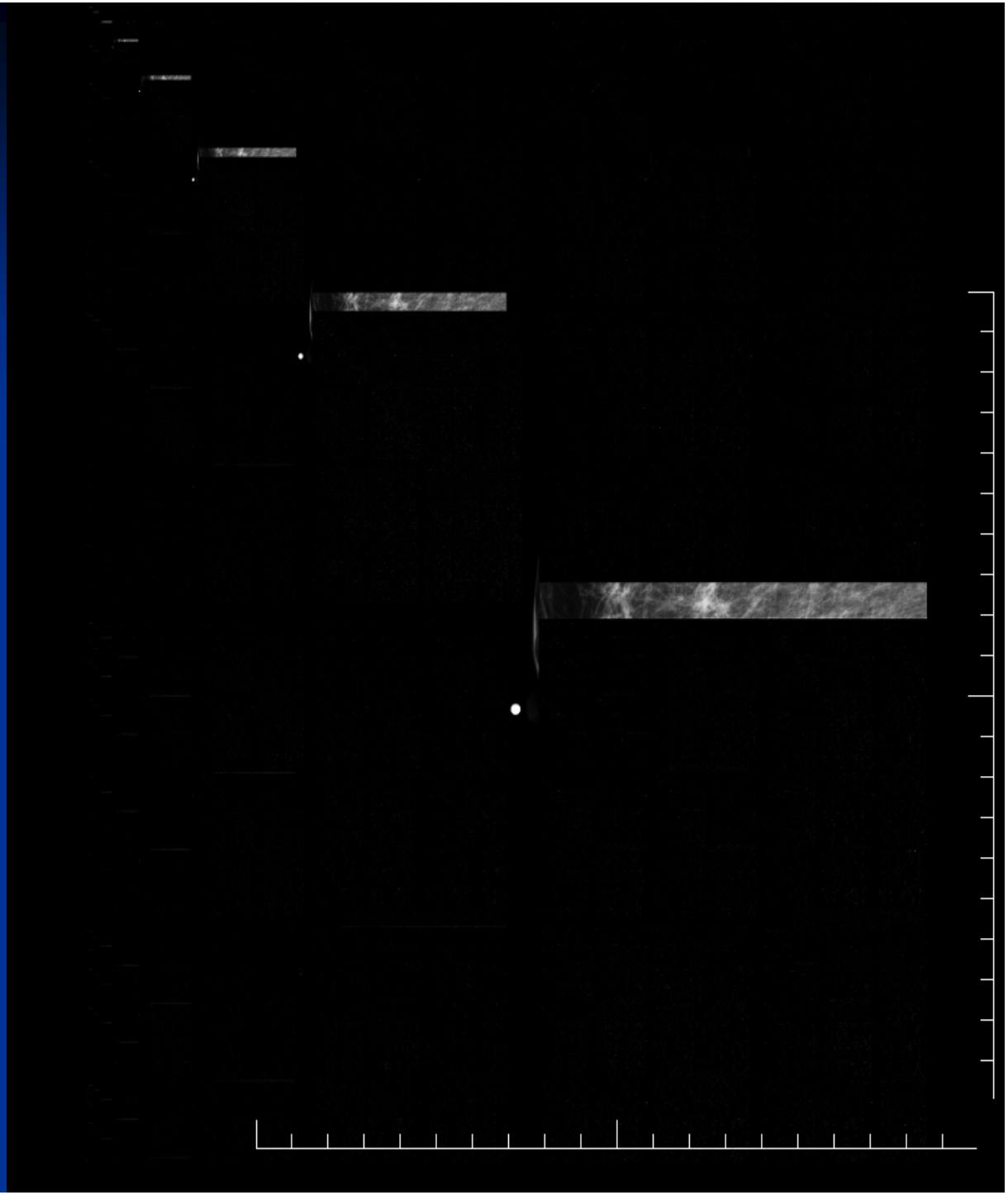

References

- **"Digital Mammographic Artifacts on Full-Field Systems: What Are They and How Do I Fix Them?"** Rama S. Ayyala, MD, MaryAnn Chorlton, RTRM, Richard H. Behrman, PhD, Phyllis J. Kornguth, MD, PhD, and Priscilla J. Slanetz, MD, MPH **RadioGraphics 2008;28:1999-2008**

- **Artifacts in Digital Mammography: What a Radiologist Needs to Know,** W. Geiser, M.S. T. Haygood, PhD, M.D., T. Stephens, M.D., L. Santiago, M.D., D. Thames, RT(R)(M) , G. Whitman, M.D., ARRS 2009