CT Imaging of the Breast

with a Novel New System

Cone Beam CT

John Neugebauer

john.n@koningcorporation.com

Cell 412-779-0392

Breast Cancer

- No cure
- Etiology of the disease is unknown
- Mammography is limited in dense breasts
- To affect mortality rates and reduce the cancer burden, we need to find cancer in the earliest stages.



Standard of Care for Detection and Diagnosis

Mammography

- Additional views- spot, angled, magnification

Ultrasound

Ductography

MRI

Biopsy

Limitations of Mammography

- High spatial resolution but limited contrast resolution especially in dense breasts
- Mammography is a 2D projection acquisition of a 3D structure leading to structure and tissue overlap
- Extent of disease
  - Actual tumor size, multifocality, and multicentricity

Limitations of Ultrasound

- Operator dependent and time consuming
- ACRIN 6666 (2004-2008)
  - Many more false positive biopsies to get to a true cancer
- Low spatial resolution and has severe limitations in visualizing and characterizing calcifications

Limitations of Breast MRI

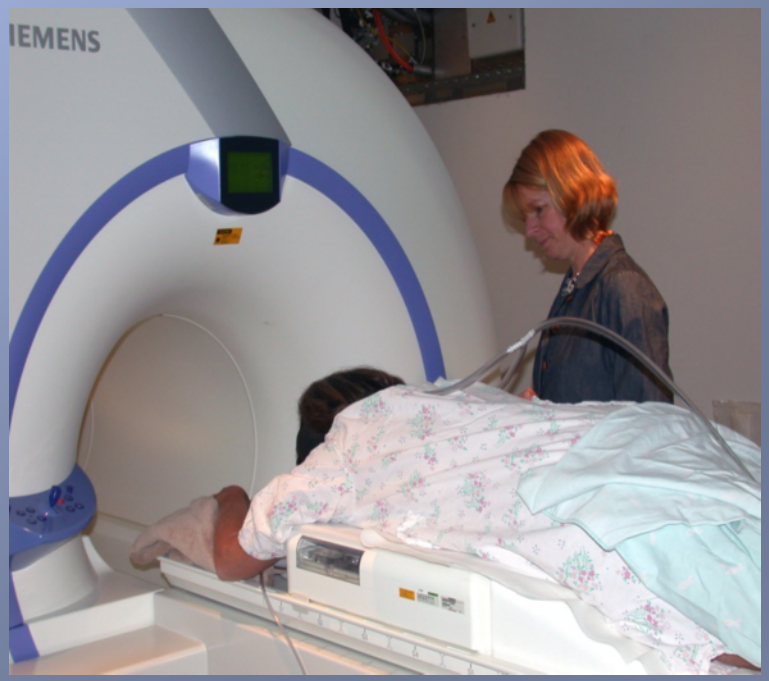

- The dependence of MRI on contrast constrains the modality to balance spatial resolution against temporal resolution
- Breast MRI cannot distinguish calcifications
  - High sensitivity for invasive breast cancer but limited in detecting DCIS
- Breast MRI 3D rendering
  - Maximum contrast uptake intensity projection (MIP) used for geographic location only

Why not CT?

- Patient Positioning and Access
- Tissue Coverage
- Resolution/ Image Quality
- Dose
- IV Contrast

Not with current design and configuration:

Current Use of CT in Breast Imaging

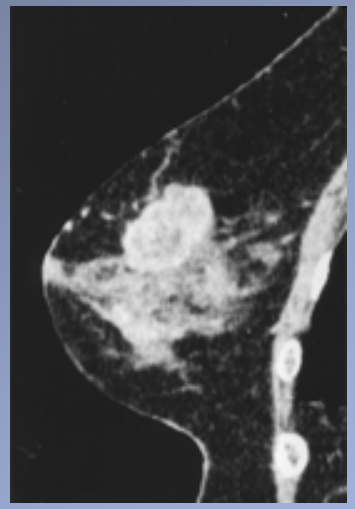

GENERAL ELECTRIC- CT/M

First CT from GE

Unit #1- 1975- Mayo Clinic

Unit #2- 1976- U of Kansas

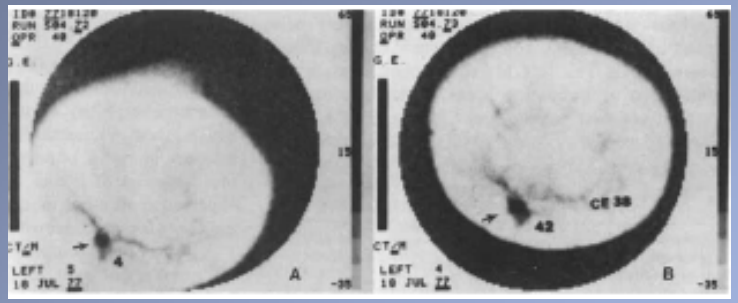

Specifications: GE CT/M

Slice Thickness	5 -10mm
Spatial Resolution	.32 lp/mm
Scan Time	10 seconds per slice
Dose	39-73 mGy
Technique	75 kVp - 200 mA
Reconstruction Time	90 seconds per slice

Results: University of Kansas Medical Center

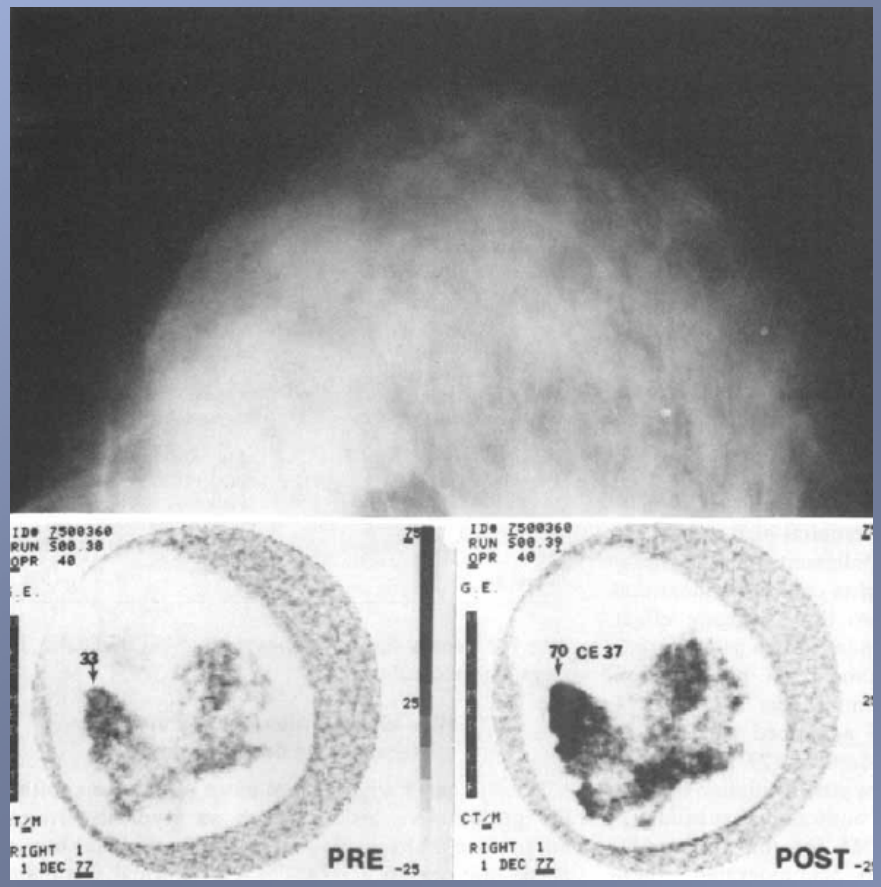

1976-1979

1625 Patients- All with Contrast

78 Cancers

Increase in CT Number

CT- 94% Sensitivity

Mammo - 77% Sensitivity

Conclusion:

"The CT/M appears to be especially superior to the mammography for detecting cancers in dense, premenopausal dysplastic breasts. The CT/M can detect totally unsuspected very small breast cancers that were unable to be identified by conventional mammography or physical exam. The CT/M scan also seems to be a better test for recognizing precancerous high risk lesions. CT/M evaluation affords definitive diagnostic help in instances where the mammographic and/or physical examinations are inconclusive. Although CT/M will not replace conventional mammography in routine breast examinations, it overcomes the limitations of mammography."

Cancer 46: 939-946, 1980

Lesion Differentiation Based on CT Number

Japan

154 Cancers

Cutoff Attenuation 60HU

90% sensitivity

77% specificity

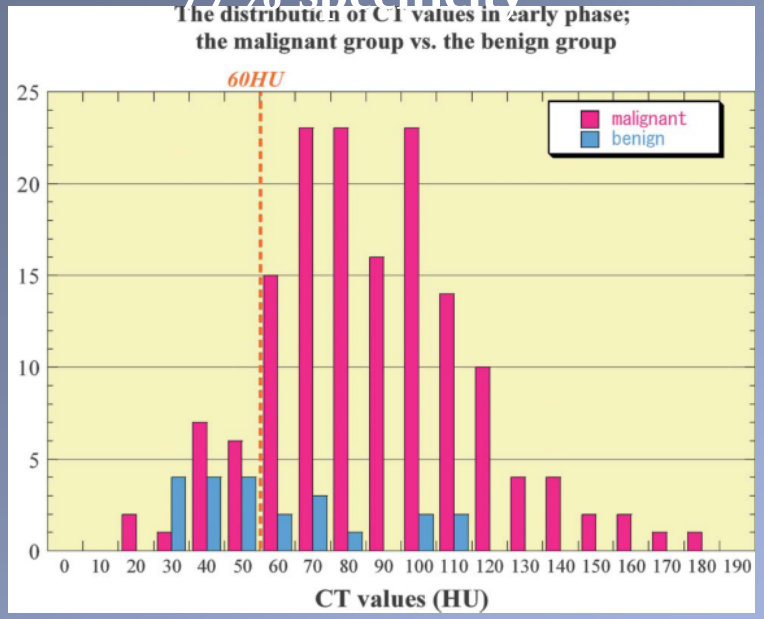

Multi Detector CT

- Italy
- 61 Birads 4/5 Patients
- Unable to undergo MRI
- 47 to Surgery
- Cutoff Attenuation 90 HU
- 25 of 27 Malignant (92% Sensitivity)
- 20 of 20 Benign (100% Specificity)

2004 - UC Davis Clinical Prototype



Cone Beam Scanner

30 x40 cm Flat Panel Detector

Neoprene Hammock for Breast Support

16.6 second scan time

10 to 110kVp Fluoroscopic Operation (6mA)

0.4mm x 0.4mm focal spot

Results: Radiology Jan 08

- Overall equal in visualization
- Better on Masses
- Inferior on calcifications
- More comfortable…but not for everyone
- No visualization difference malignant or benign
- Less coverage of pectoralis and axillary tail
- Dose equal to a two view mammogram

Conclusion: Some technical challenges remain but promising

2006- URMC Clinical Prototype



- Cone Beam/Flat Panel Scanner
- Mammography Tube/ Tungsten Anode (0.3) (49kVp)
- Radiographic Technique
- 10 second exposure
- 140 and 270 micron (isotropic)
- 0.25mm slice thickness
- Slip Ring Technology
- Patient access either side
- Table/ Gantry Elevation to 5 feet

Initial Pilot Study

Comparison with Mammography

-Image Quality

-Coverage

-Dose

23 Patients/44 Breasts

All Birads 1&2

Ages40-65

7 patients-40 to 45

7 patients-45 to 50

Clinical Study Conducted By:

Highland Breast Center-URMC

Elizabeth Wende Breast Care LLC

Results: Breast Tissue Coverage

Pilot Study, Normal Cohort		
Breast site	**Mammogram (n=40)**	**KBCT (n=40)**
Superior	40 (100%) (MLO)	40 (100%)
Inferior	27 (67%)	34 (85%)
Posterior	21 (52.5%) (CC)	36 (90%)
Medial	14 (35%)	36 (90%)
Lateral	5 (12.5%)	37 (92.5%)
Axilla or Axillary Tail	29 (72.5%)	3 (7.5%)

Results: Average Glandular Dose

Pilot Study, Normal Cohort

- N = 44 breasts
- Average glandular radiation dose (mGy) as a function of x-ray tube current (mA)
  - Voltage [kVp] and time [ms] are constant
  - Determined from prior dose phantom studies
  - The mA-to-mGy relationship was verified using an FDA-approved 16-cm PMMA head dose phantom to measure the weighted computer tomography dose index (CTDIw)
- 2 orthogonal low dose scout images of the breast were obtained prior to the scan.
  - The optimal tube current (mA) to obtain sufficient contrast-to-noise ratio in the reconstructed cross-sectional images at a minimum dose was determined from these scout images.
  - Dose was tailored to each breast, depending on breast size and density

- **Mammogram** (dose per complete exam)
  - Range: **2.2 mGy to 15 mGy**; Mean = **6.5 mGy**; Standard deviation = 2.8 mGy
- **CBCT** (dose per scan)
  - Range: **4 mGy to 12.8 mGy**; Mean = **8.2 mGy**; Standard deviation = 1.2 mGy

Results: Image Quality

Types and Sizes of Findings and Impression of Better Detection

Findings and Sizes[1] (n=69)	Seen Better on CBBCT	Equally on CBBCT and Mammogram	Seen Better on Mammogram	p-value[2]
Calcifications[3] (n=55)	22 (40.0%)	22 (40.0)	11 (20.0)	
< 1 mm (n = 35)	19 (54.3)	6 (17.1)	10 (28.6)	< 0.0001
≥ 1 mm (n = 20)	3 (15.0)	16 (80.0)	1 (5.0)	
Masses[4] (n=11)	6 (54.5)	4 (36.4)	1 (9.1)	
< 1 mm (n = 3)	3 (100.0)	0 (0.0)	0 (0.0)	0.1793
≥ 1 mm (n = 8)	3 (37.5)	4 (50.0)	1 (12.5)	
Clips (n=3)	0 (0.0)	3 (100%)	0 (0.0)	
< 1 mm (n = 0)	--	--	--	N/A
≥ 1 mm (n = 3)	0	3 (100)	0	
Combined (n = 69)	28 (40.6)	29 (42.0)	12 (17.4)	
< 1 mm (n = 38)	22 (57.9)	6 (15.8)	10 (26.3)	< 0.0001
≥ 1 mm (n = 31)	6 (19.4)	23 (74.2)	2 (6.5)	

1 Sizes measured in mammogram.
2 p-values of chi-square test in distribution of better detection between size groups.
3 Includes single calcification, 2-4 calcifications in the same quadrants, skin calcifications, and calcification clusters
4 Includes masses, cysts, intramammary lymph nodes, nodules, and skin moles.

Results: Image Quality

Location of the Findings and Impression of Better Detection

Location (n=61)[1]	Seen Better on CBBCT	Equally on CBBCT and Mammogram	Seen Better on Mammogram
Retroareolar	6 (85.7%)	1 (14.3)	0 (0.0)
Mid-depth	2 (33.3)	3 (50.0)	1 (16.7)
Posterior	2 (28.6)	3 (42.9)	2 (28.6)
Skin	2 (25.0)	6 (75.0)	0 (0.0)
Upper Inner	3 (37.5)	5 (62.5)	0 (0.0)
Upper Outer	6 (46.2)	6 (46.2)	1 (7.7)
Lower Inner	3 (60.0)	2 (40.0)	0 (0.0)
Lower Outer	4 (57.1)	3 (42.9)	0 (0.0)

[1] Excluding findings not seen on CBBCT.

Results: Patient Comfort

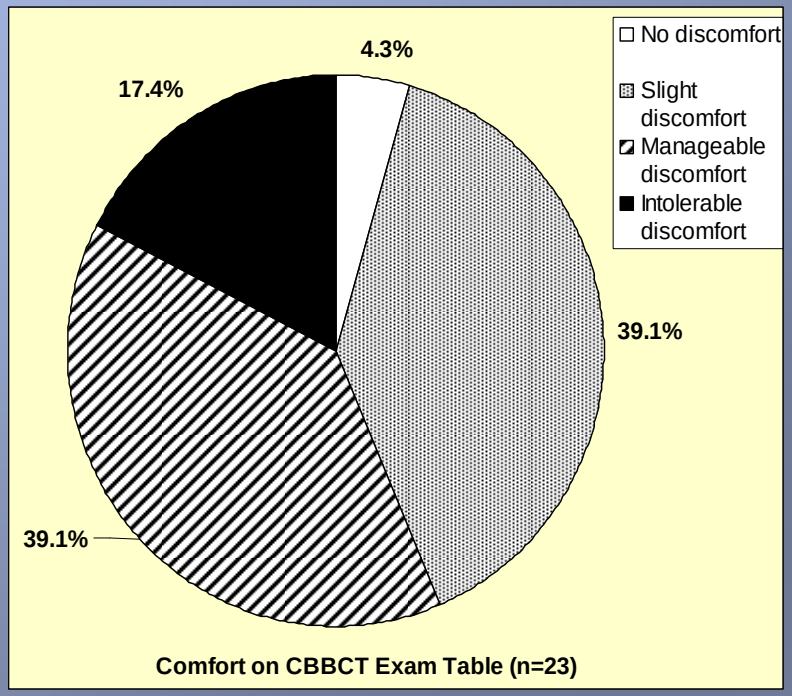

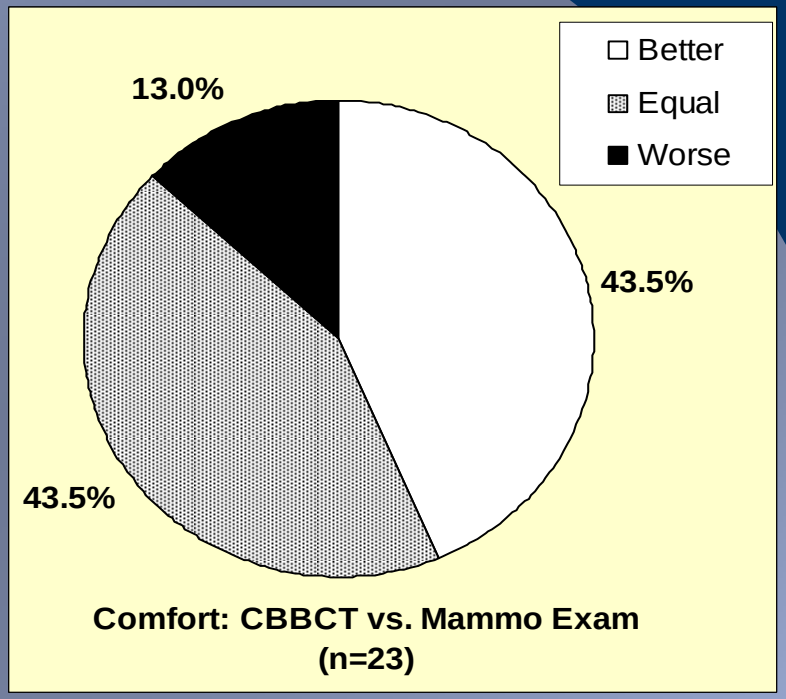

Comfort of CBCT Table

Comfort of CBCT vs. Mammogram

Koning Corporation

- Privately held Delaware C Corp (2004)
- West Henrietta, New York
- Exclusive License from URMC
- Extensive Intellectual Property
- Virtual Manufacturing
- Financing to date:
  $2.65 million SBIR Grant
  $5.0 million Angel and VC Funding

2008- First 2 Production Systems



INTERTEK ETV VERIFIED
A Signal of Quality and Performance



Additional Features



- Self Shielded
- Independent Operators Console
- Add-on Biopsy Device
- 10 Second Scan Time
- 90 Second Reconstruction
- DICOM Compliant
- PACS, HIS, RIS Connectivity
- Internet Accessible from 4 Separate Locations

Add- On Biopsy