Multimodality Imaging – Clinical Perspective

Michael W. Vannier, M.D.
University of Chicago

Outline

- Challenges in diagnostic imaging technology (2009)
  - Multimodality – What, why, how?
  - Applications
- Identify trends
  - New scanners and applications
  - Low end CT scanners:
    - Point of Care CT ; DentoMaxilloFacial/ENT; Portable CT

Case History

46 year old female with melanoma.

PET-CT exam for initial staging.

THE UNIVERSITY OF CHICAGO
Department of Radiology

Radiological Presentations

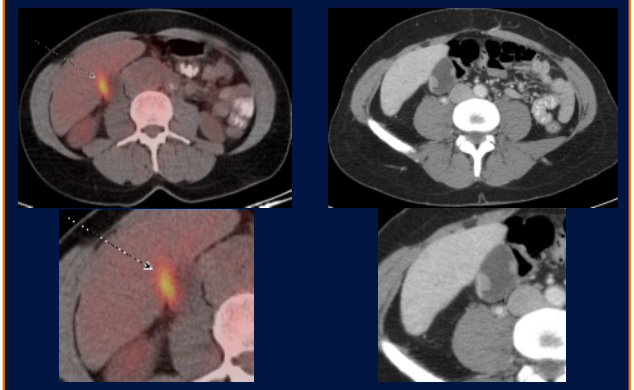

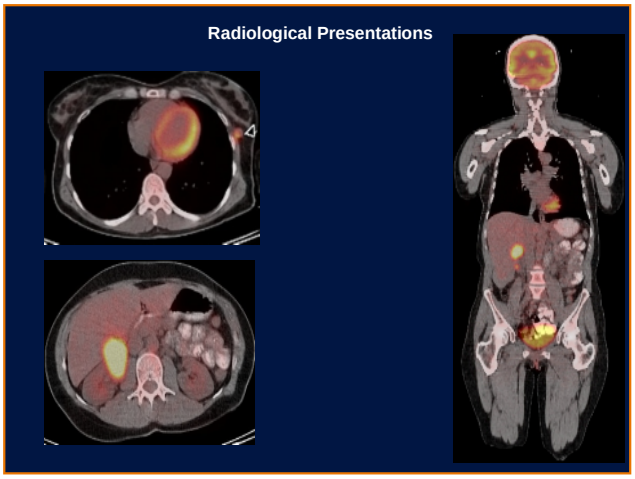

Multimodality, multitemporal imaging

- Payors will reimburse for a single exam from a single modality (pre-cert) at a single time – for diagnosis/staging
- Follow-up scans to evaluate disease status (e.g., restaging; response evaluation)
- Common scenario:
  - Detect lesion on CT, and characterize it with MRI. Biopsy with US.

Case History

65 year old male with elevated liver function tests.

Status post sigmoidectomy for colon cancer 5 years ago.

CT exam to rule out mass or biliary tract disease.

THE UNIVERSITY OF CHICAGO
Department of Radiology

Liver Mass

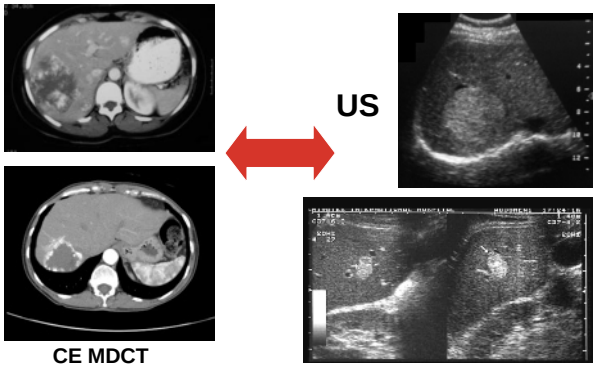

MRI of liver

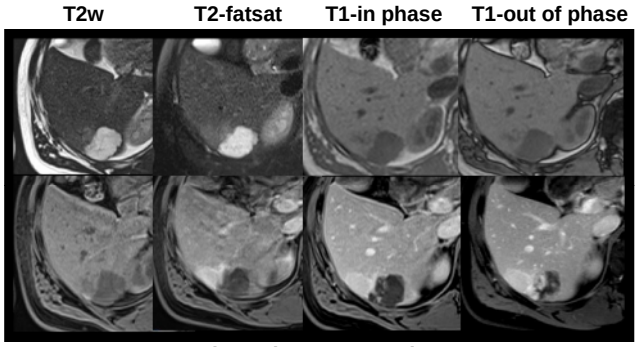

Liver hemangioma

- Hepatic hemangiomas are present in about 7% of healthy people.
- Hemangiomas are four to six times more common in women than in men.
- Hemangiomas, although referred to as tumors, are not malignant and do not become cancerous.
- Hemangiomas are not unique to the liver and can occur almost anywhere in the body.
- Giant hemangiomas do occur and are susceptible to occult bleeding

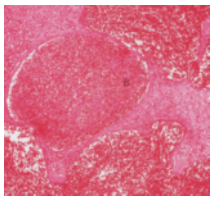

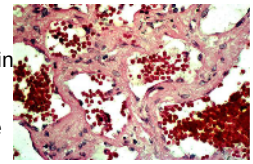

Why so many modalities?

- Each has strengths and weaknesses; Synergy
- One size / type does not fit all
- Reimbursement; instrument/operator availability
- CT is most available and widely used
  - Essential technology for emergency dept.
  - CT is fast; 24/7 access
- MR is expensive, time consuming
  - Some patients are ineligible or unable to tolerate
- US is operator dependent
  - Skilled examiner is required, otherwise many errors
  - Real time; versatile; safe; widely available

Tools ~ Modalities

- Use the right tool for the job
- No single tool will suffice
- One size doesn't fit all
- May be used separately or in combination
- Some require a skilled operator; others are simple enough for anyone to use

When is multimodality imaging used?

- **Breast** imaging: mammography, ultrasound, MRI
- **Cardiac** imaging: echo, SPECT, cardiac cath, CCTA, CMRI
- **Prostate** imaging: US, MRI, CT (for staging)
- **Brain** tumors: MRI, MRS, CT
- **Stroke**: CT (CTA and perfusion), MRI
- Solid **tumors**: CT, MRI, PET
- **Transplant**: US, MRI, CT
- **Interventional**: fluoroscopy, US, CT, MRI
- **Orthopedic**: radiography, MRI, fluoroscopy, CT

- And many others….

When is multimodality imaging NOT used?

- **Emergency:** CT
- **ICU:** radiography (sometimes head CT or portable US)
- **O.R.:** fluoroscopy (sometimes US or radiography)
- **Thyroid:** US (and sometimes SPECT)
- **Follow-up** solid tumor/surveillance: CT

- And many others….

Choice of modality and scanning protocol is difficult and complex.

- Limited knowledge of the clinical status and history
- Similar history may require very different exams:
  - Abdominal pain
    - Depends on renal function and allergy to iodinated contrast
    - Acute vs. chronic; where does it hurt?
    - WBC; fever
    - Jaundice
    - Gender and gynecologic history
  - Altered mental status
    - Prior surgery
    - Known malignancy
    - Intoxicated?
  - Search for primary tumor – occult malignancy
    - Serum biomarkers
    - Known metastases
- Payor may deny reimbursement for repeat or additional exams.

CT ? With or without IV contrast ?

MRI ?

US ? Oral contrast ?

Doppler ?

PET ?

Delayed images?

Exceptions

- Diversity of patients; generalizations are difficult
  - Massive obesity
  - Children (including neonates and infants)
  - ICU patients – on respirator
  - Immunosuppressed; contagious (e.g., Tb)
  - Mental impairment; claustrophobia
  - Pregnancy
  - Renal failure – acute and chronic

Multitemporal imaging

- Contrast-enhanced: (within exam session)
  - Multiphase: arterial, venous, equilibrium
  - Perfusion: DCE
  - 10+ minute: excretion; redistribution
- Sequential (e.g., monthly, quarterly encounters)
  - Restaging in oncology; Baseline + followup
  - Revascularization; vessel patency
  - Measure of response to therapy
    - e.g, Imaging biomarker

Multiphase contrast-enhanced imaging

- Common in CT and MRI
- Essential for liver, pancreas, kidneys
- CT angiography typically consists of both a non-contrast and post-contrast enhanced series (same for MRA)
- Multiphase cardiac CTA:
  - Precontrast coronary calcium scan
  - Post-contrast retrospective gating

Multiphase CT

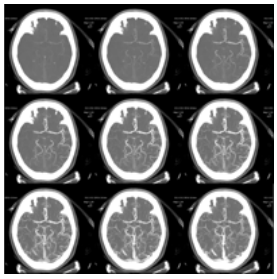

Same slice, multiple time points

Liver lesion after RFA

Pre-

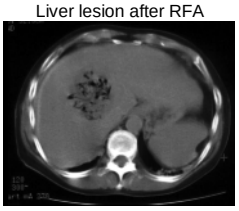

Post-

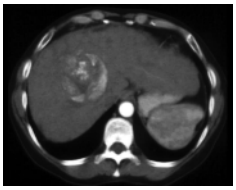

Liver malignancy prior to RFA

Cardiac imaging – an example

- EKG and stress testing → cardiac SPECT
- Abnormal SPECT → cardiac cath & PCI
  or may choose coronary CTA
- Coronary calcium measurement with CT
  - Risk assessment by age and gender norms
- Valvular disease: echocardiography
- Cardiac MRI
  - Congenital anomalies, congenital heart disease
  - Myocardial viability; cardiac function

Future? – PET-CT; MRI-PET; …

Modalities

SPECT
Cath / PCI
CCTA
CorCa CT
Echo
CMRI

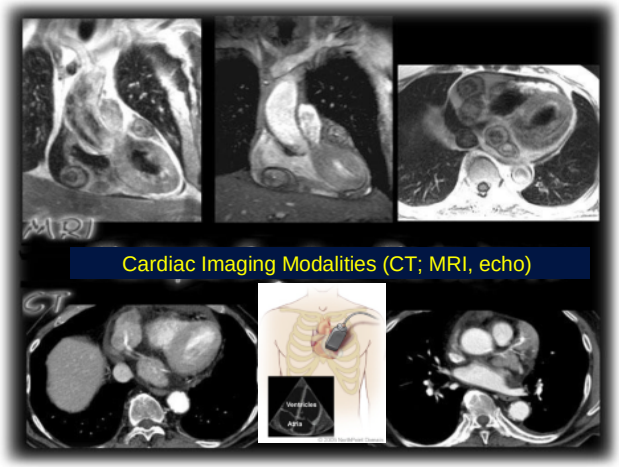

Delayed CT/MRI imaging

- Redistribution phenomena
  - Gd contrast into fibrosis (Myocardial viability)
  - Cholangiocarcinoma (malignant)
  - Adrenal adenoma (benign)
  - Hemangioma (benign, but may be very large)
- Renal excretion
  - Antegrade opacification of urinary tract
  - Basis of CT urogram (akin to IVP / EXU)

Delayed CE-MRI:
Normal myocardial viability

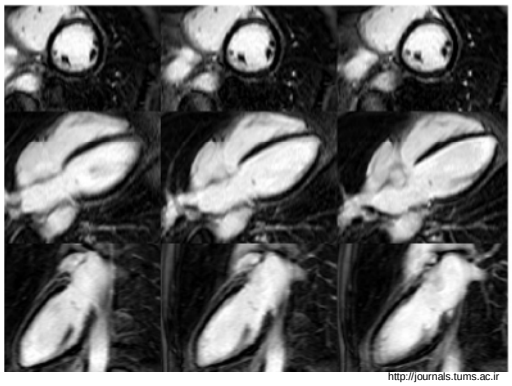

http://journals.tums.ac.ir

Delayed CE-MRI

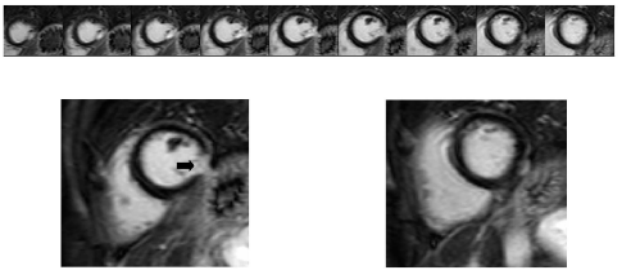

Mid-ventricular slice demonstrating abnormal enhancement (arrow)

Basal slice demonstrating no abnormal LV enhancement

http://journals.tums.ac.ir

Myocardial SPECT

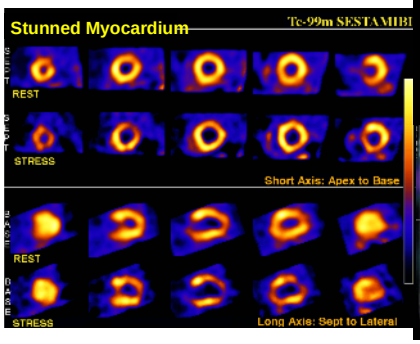

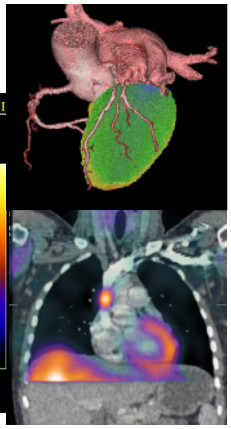

brighamrad.harvard.edu/education/online/Cardiac/

www.gehealthcare.com/euen/advantage-workstation/

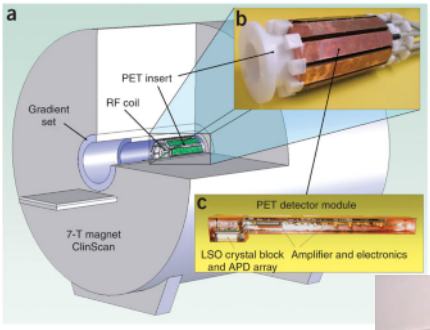

Integration of the multislice PET scanner into a 7-T MRI apparatus.



Simultaneous PET-MRI: a new approach for functional and morphological imaging
Martin S Judenhofer, et al.
Nature Medicine 14, 459 - 465 (2008)

PET/MRI scan of a tumor in a lab mouse. The arrow points to central necrosis within the tumor.

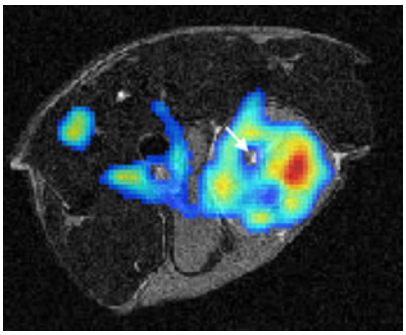

CT Market 2009

CT Market Doldrums

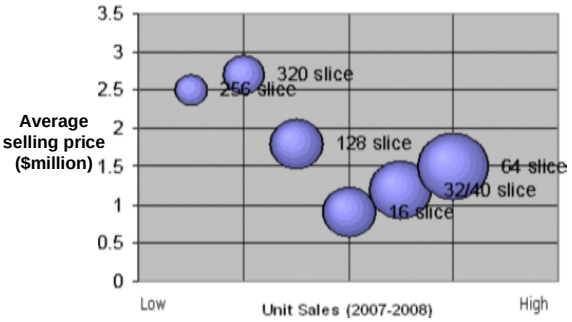

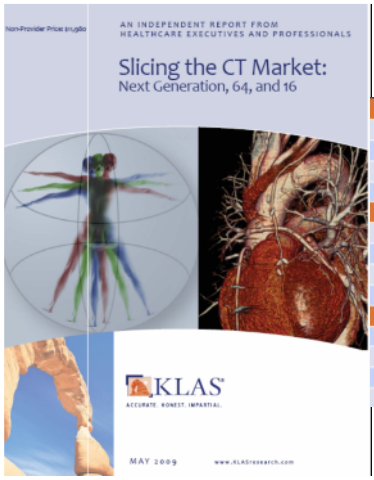

Four major manufacturers
3 major types – 16, 64, high-end

64-slice CT Vendor/Product
Toshiba Aquilion 64
GE LightSpeed VCT 64
Siemens Sensation 64
Philips Brilliance 64
16-slice CT Vendor/Product
Siemens Emotion 16
Toshiba Aquilion 16
GE LightSpeed 16
Philips Brilliance 16
Next Generation Vendor/Product
GE Discovery CT750 HD
Philips Brilliance iCT*
Siemens Definition Dual Source
Toshiba AquilionONE*

www.klasresearch.com

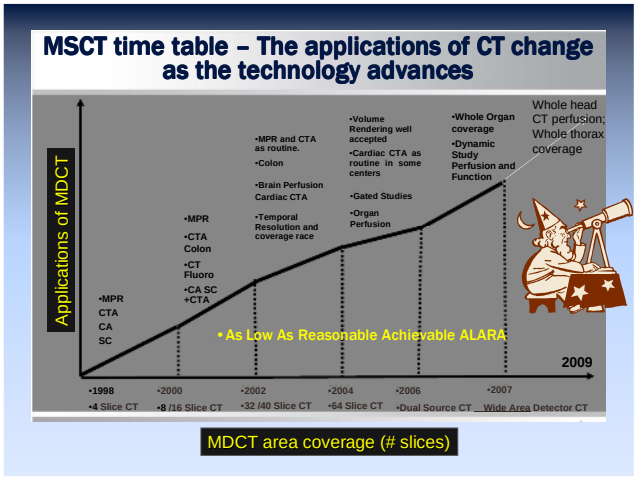

Image Gently℠

http://www.pedrad.org/associations/5364/ig/

13 yr old Female- Scanned w/256-slice CT

- *4.8 sec scan*
- *2D Anti-Scatter detector grid improves contrast resolution*
- *Smart Focal Spot for artifact elimination*

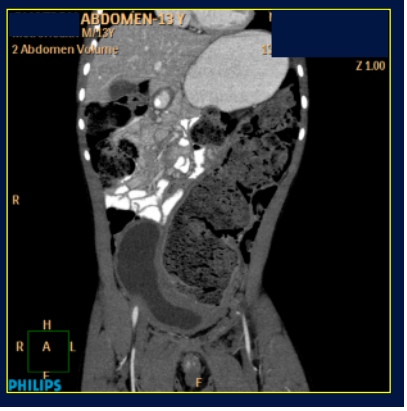

Clarity™ Tissue Adaptation

sapheneia
An Imaging Services Company
Clarity in Imaging

- Automatically adapts to the tissue.
- Decrease noise in the soft tissue and increase the contrast in the lung.

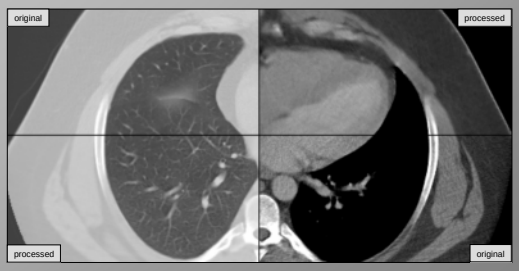

Clarity™ *Solution*

Pediatric - Liver

original | processed

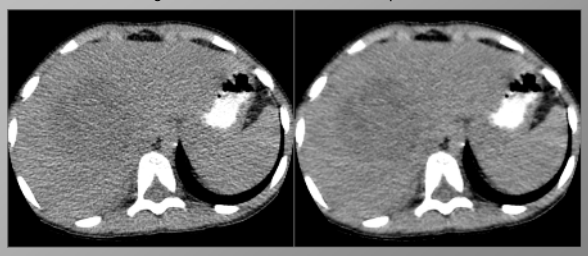

Thin slice 0.6 mm

Clarity™ *Solution*

Obese patient - Liver

original | processed

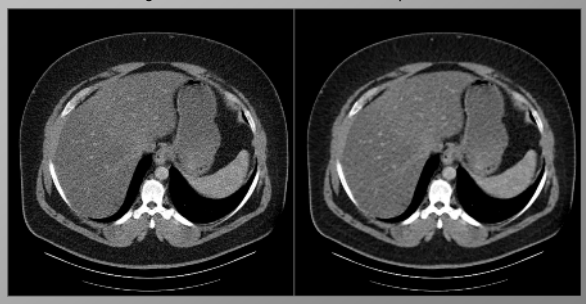

Clarity™ *Solution*

Clarity™ *CT Solution* Server

- **Clarity™ *CT Solution* Server** acts as a DICOM node that receives DICOM3.0 compliant data, then processes the data, and then forwards the optimized study to the selected destination. This destination can be any DICOM node, typically either the PACS system or a specific workstation.

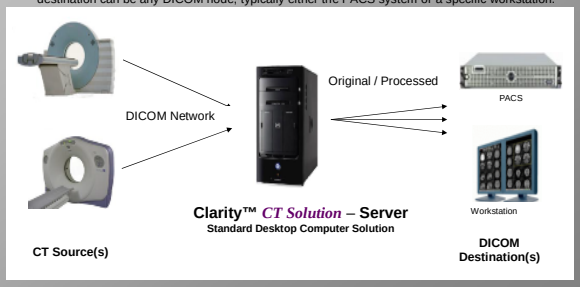

Clarity™ *Solution*

Clarity™ Ultra Low Dose CT Liver

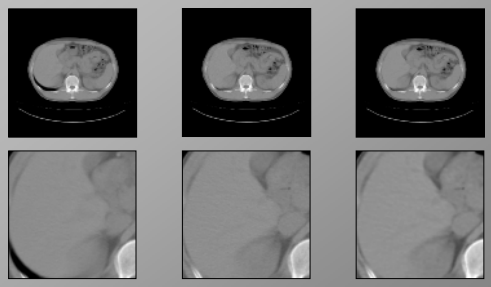

100 % (standard dose) | 50 % (low dose) | 50 % dose (processed)

Clarity™ *Solution*

256-320 Channel MDCT

41

Multirow Detector CT (MDCT) Scanner

128 detector rows; 256 slices (iCT)

Increased Speed, Power, Coverage

- Higher temporal resolution
  - 0.27 sec rotation
- Increased Tube Power
  - 120 kW / 1,000 mA
  - X-Y and Z focal spot modulation
- Greater coverage per rotation
  - 8 cm
  - 256 slices

Nose to Toe Scan:168 cm in 22sec

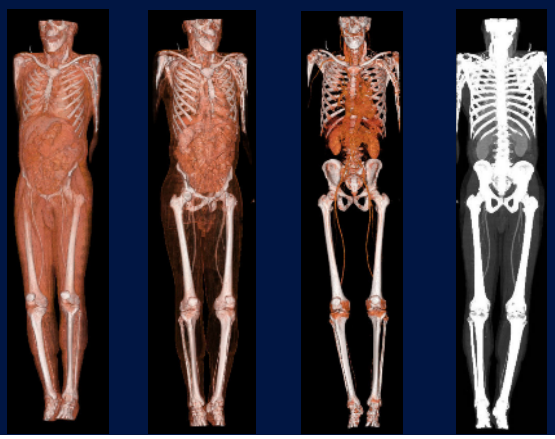

Multi-phase Cardiac Imaging less than 5 sec

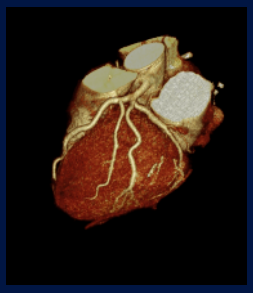

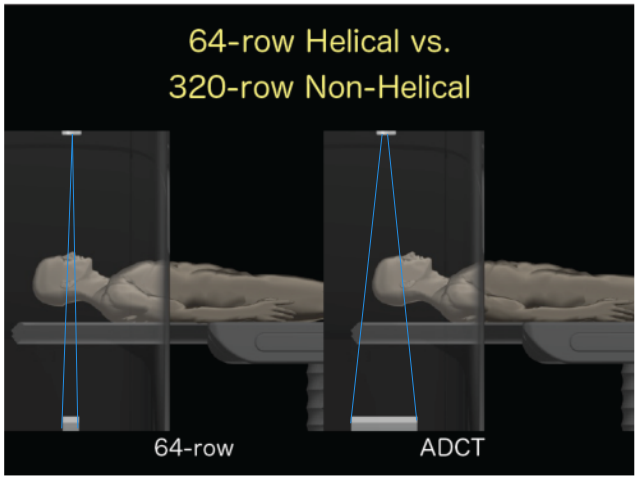
64-row Helical vs.
320-row Non-Helical
64-row
ADCT

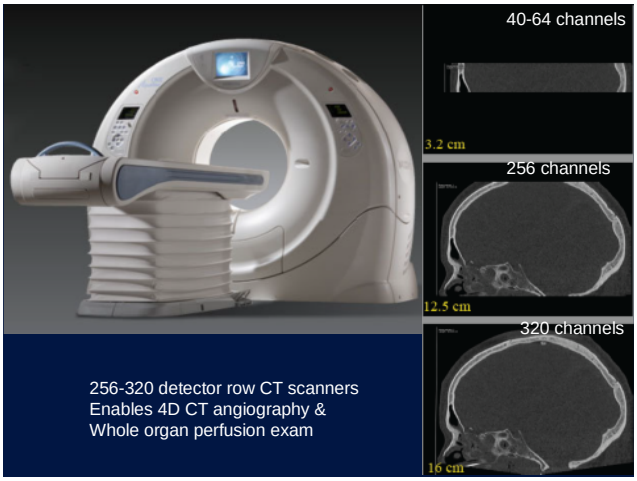
40-64 channels
3.2 cm
256 channels
12.5 cm
320 channels
16 cm
256-320 detector row CT scanners
Enables 4D CT angiography &
Whole organ perfusion exam

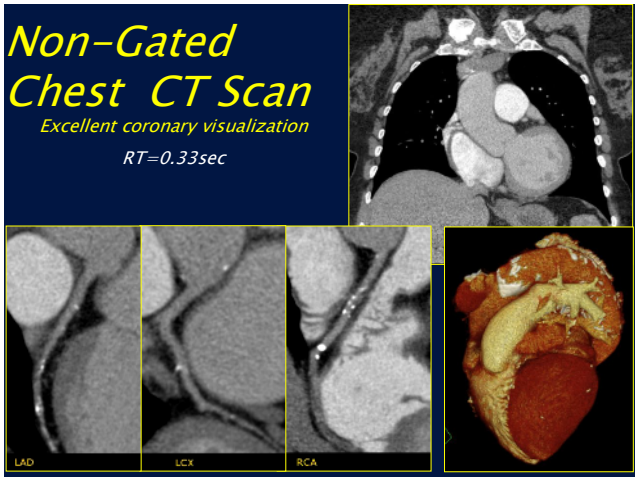
Non-Gated
Chest CT Scan
Excellent coronary visualization
RT=0.33sec
LAD
LCX
RCA

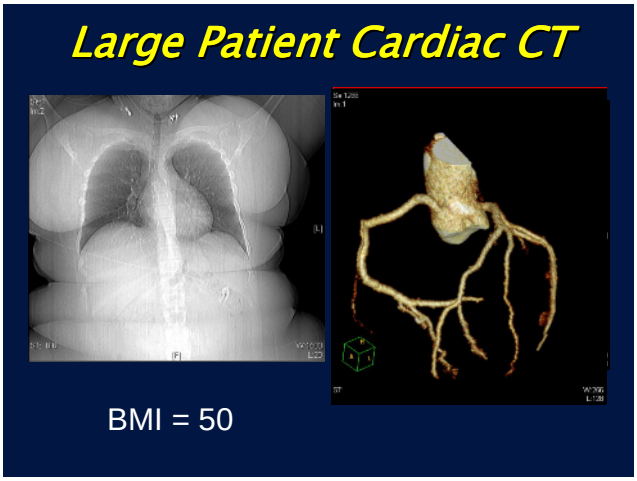
Large Patient Cardiac CT
BMI = 50

Head & Neck

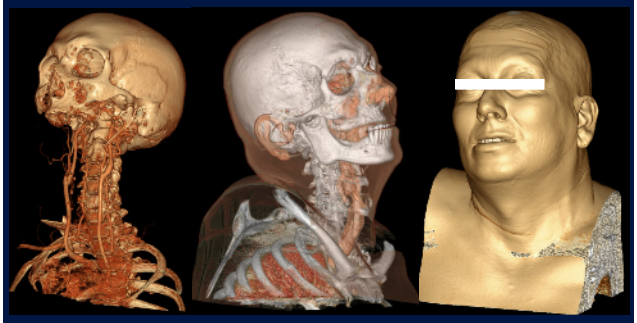

AJNR Am J Neuroradiol 29:E23–E30 | May 2008 | www.ajnr.org E23

RESEARCH PERSPECTIVES

Max Wintermark
Gregory W. Albers
Andrei V. Alexandrov
Jeffry R. Alger
Roland Bammer
Jean-Claude Baron
Stephen Davis
Bart M. Demaerschalk
Colin P. Derdeyn
Geoffrey A. Donnan
James D. Eastwood
Jochen B. Fiebach
Marc Fisher
Karen L. Furie
Gregory V. Goldmakher
Werner Hacke
Chelsea S. Kidwell

Acute Stroke Imaging Research Roadmap

ABSTRACT: The recent "Advanced Neuroimaging for Acute Stroke Treatment" meeting on September 7 and 8, 2007 in Washington DC, brought together stroke neurologists, neuroradiologists, emergency physicians, neuroimaging research scientists, members of the National Institute of Neurological Disorders and Stroke (NINDS), the National Institute of Biomedical Imaging and Bioengineering (NIBIB), industry representatives, and members of the US Food and Drug Administration (FDA) to discuss the role of advanced neuroimaging in acute stroke treatment. The goals of the meeting were to assess state-of-the-art practice in terms of acute stroke imaging research and to propose specific recommendations regarding: (1) the standardization of perfusion and penumbral imaging techniques, (2) the validation of the accuracy and clinical utility of imaging markers of the ischemic penumbra, (3) the validation of imaging biomarkers relevant to clinical outcomes, and (4) the creation of a central repository to achieve these goals. The present article summarizes these recommendations and examines practical steps to achieve them.

Table 1: Recommended Acquisition Protocols for Perfusion-Weighted (PWI) and Diffusion-Weighted (DWI) MR Imaging

	PWI	DWI
Sequence	Single-shot gradient-echo echoplanar imaging	Single-shot diffusion-weighted spin-echo echoplanar imaging
Image acquisition parameters	TR≤1500 ms* TE=35 to 45 ms @ 1.5T TE=25 to 30 ms @ 3T flip angle α=60 to 80° @ 1.5T, 60° @ 3.0T	TR≥4000 ms but can be as high as needed to fit all slices TE minimum (partial Fourier) b=0 and 1000 sec/mm² (at least 3 orthogonal directions) eddy current correction (dual-spin echo or postprocessing)
	Parallel imaging and coil selected at the discretion of the site	
Image acquisition duration	90 to 120 seconds image acquisition started 10 seconds before initiation of injection to achieve at least 10 to 12 baseline images and also record slow uptake in stroke regions	90 to 260 seconds
Coverage and slice thickness	Whole brain coverage using ≥12 slices	Whole brain coverage using ≥12 slices

MRI of Cerebral Ischemia

Early DWI/MTT mismatch, lesion growth

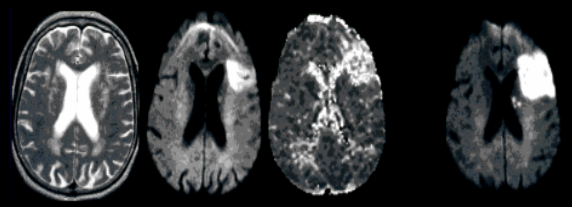

FSE T2W | Initial DWI | Initial MTT | DWI 5 days later

78 yo female 3 hrs after onset of aphasia during cardiac cath.

Greg Sorensen, Massachusetts General Hospital

CT Brain Perfusion

Color-Coded Parameter Maps

Color-coded parameter maps for a selected slice

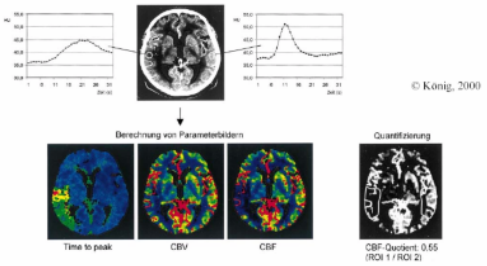

Bernhard Preim, Visualization Research Group, University of Magdeburg, Germany

Perfusion

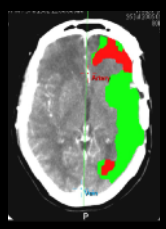

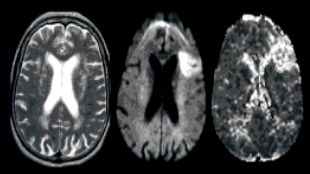

T2 DWI MTT

CT vs. MRI

vs. xenon CT vs. PET vs. SPECT

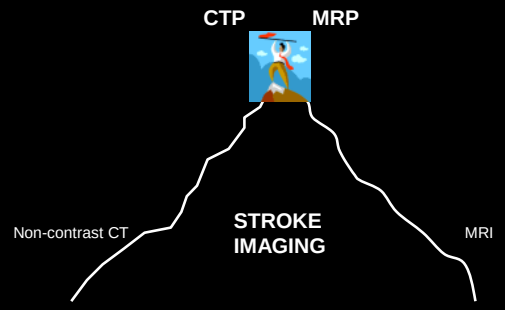

Imaging Ischemia--Vascular

Angiogram
1950-60's (pre-CT era)

Vascular occlusion

Thrombolysis

Recanalization ≠
Clinical improvement

Imaging Ischemia- Parenchyma

Head CT

No ICH

<1/3 MCA territory

<3 hours

IV Thrombolysis

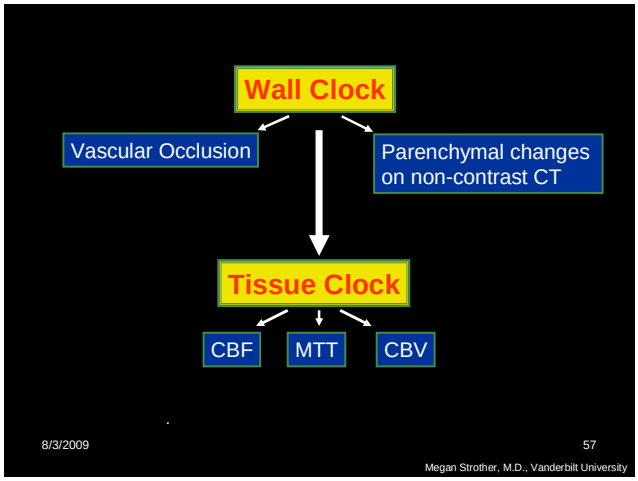
Wall Clock
Vascular Occlusion
Parenchymal changes on non-contrast CT
Tissue Clock
CBF
MTT
CBV
8/3/2009
57
Megan Strother, M.D., Vanderbilt University

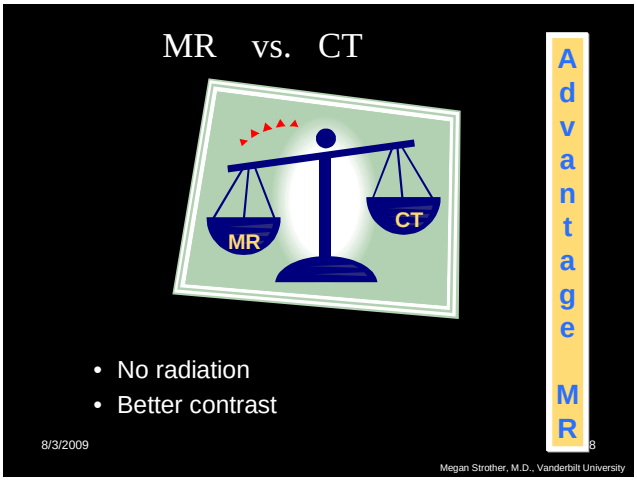
MR vs. CT
MR
CT
• No radiation
• Better contrast
Advantage MR
8/3/2009
8
Megan Strother, M.D., Vanderbilt University

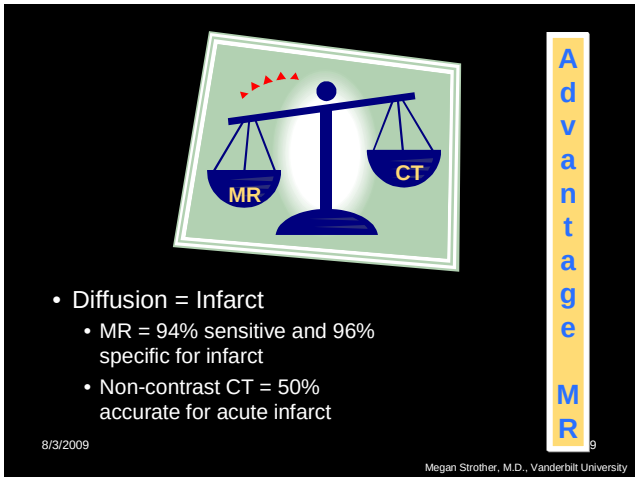
MR
CT
• Diffusion = Infarct
• MR = 94% sensitive and 96% specific for infarct
• Non-contrast CT = 50% accurate for acute infarct
Advantage MR
8/3/2009
9
Megan Strother, M.D., Vanderbilt University

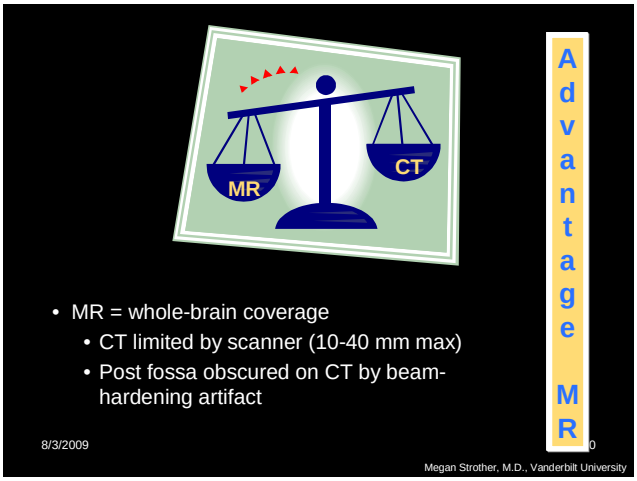
MR
CT
• MR = whole-brain coverage
• CT limited by scanner (10-40 mm max)
• Post fossa obscured on CT by beam-hardening artifact
Advantage MR
8/3/2009
10
Megan Strother, M.D., Vanderbilt University



Advantage CT

- Speed
- Accessibility
- Spatial Resolution on CTA

Advantage CT

– Quantifiable
- MR relies on indirect T2* effects on tissue from gad, therefore not quantifiable

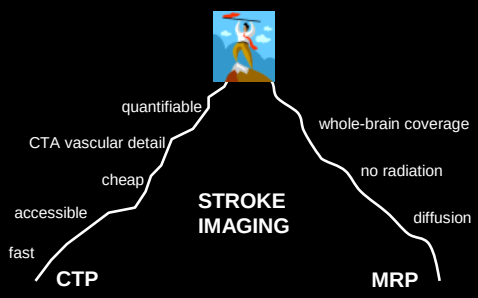

CT Scan Protocol

1st Non-contrast Head CT

↓

2nd CT Perfusion

↓

3rd CT angiogram

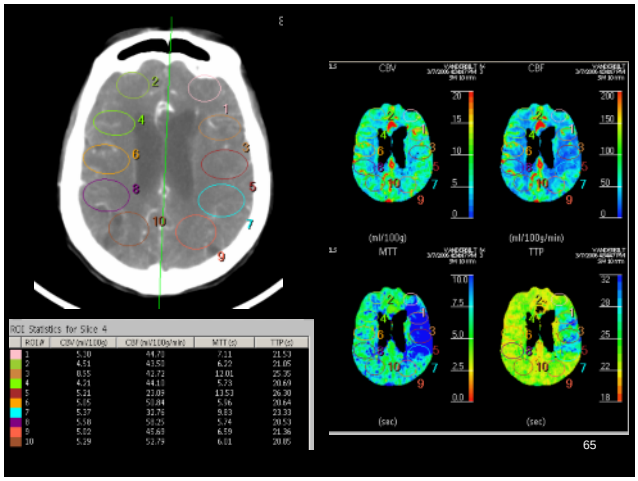
CBV
CBF
MTT
TTP
(ml/100g)
(ml/100g/min)
(sec)
(sec)
ROI Statistics for Slice 4
65

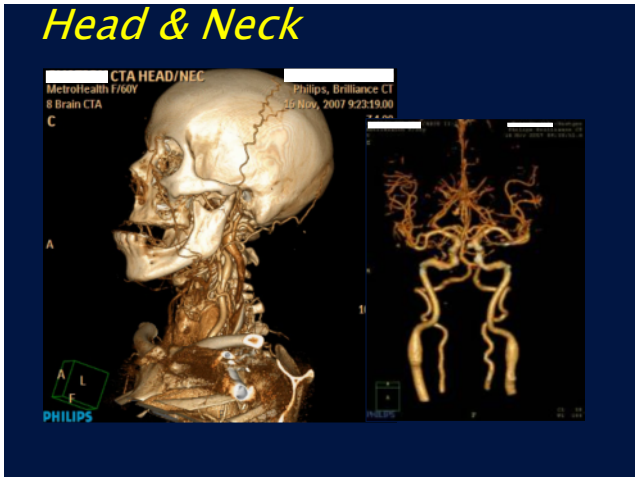
Head & Neck
CTA HEAD/NEC
MetroHealth F/60Y
8 Brain CTA
Philips, Brilliance CT
16 Nov, 2007 9:23:19.00
PHILIPS

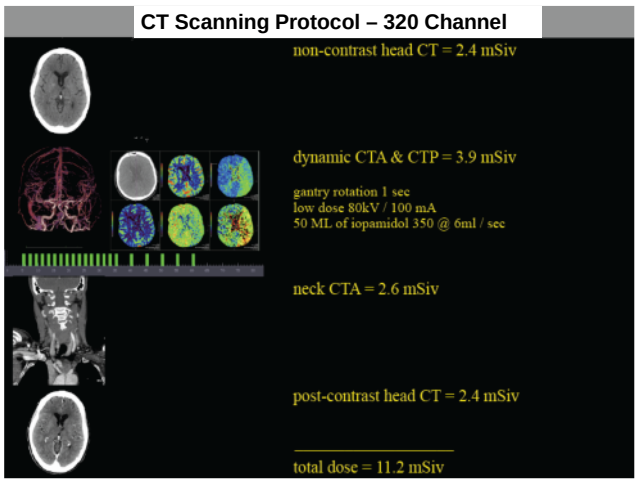
CT Scanning Protocol – 320 Channel
non-contrast head CT = 2.4 mSiv
dynamic CTA & CTP = 3.9 mSiv
gantry rotation 1 sec
low dose 80kV / 100 mA
50 ML of iopamidol 350 @ 6ml / sec
neck CTA = 2.6 mSiv
post-contrast head CT = 2.4 mSiv
total dose = 11.2 mSiv

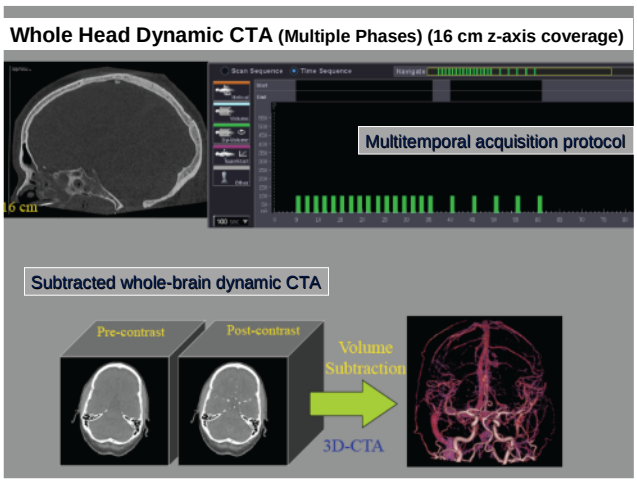
Whole Head Dynamic CTA (Multiple Phases) (16 cm z-axis coverage)
Multitemporal acquisition protocol
16 cm
Subtracted whole-brain dynamic CTA
Pre-contrast
Post-contrast
Volume Subtraction
3D-CTA

Whole Brain Perfusion (16 cm z-coverage)

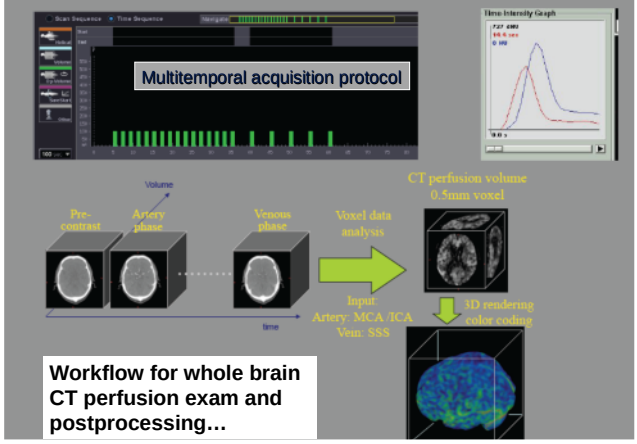

Workflow for whole brain CT perfusion exam and postprocessing…

Whole Brain Perfusion

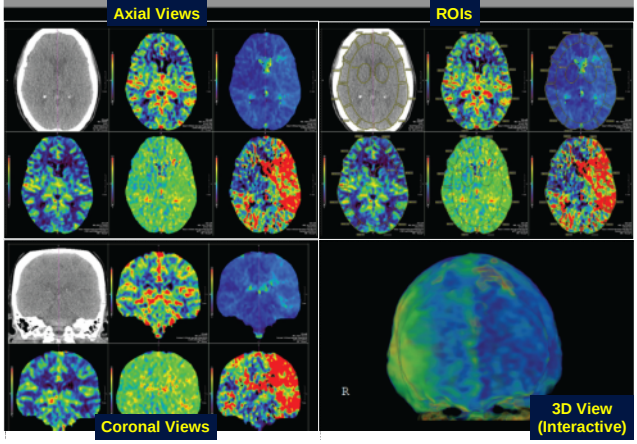

PHILIPS

Spectral and Dual Energy CT

Simple Analogy

Traditional CT	Spectral CT	Limited Spectral CT	Dual Energy CT
Yesterday & Today	Future	Future	Today

PHILIPS

Dual-energy Material Separation

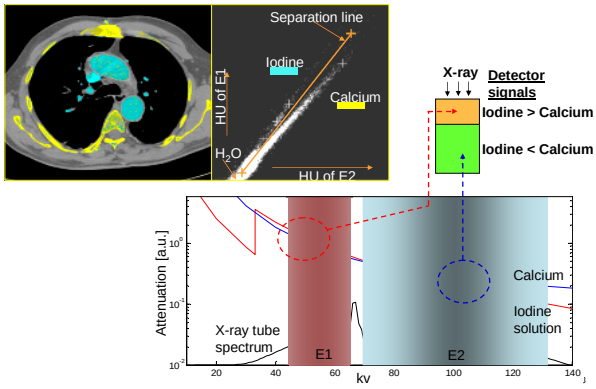

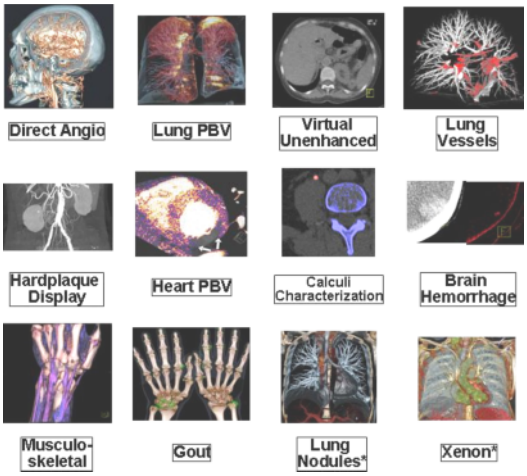

Siemens

PHILIPS

Spectral vs. Dual Energy CT

Techniques That are Possible on Commercial Systems

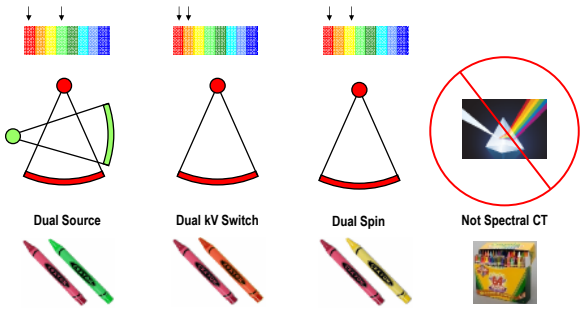

PHILIPS

Spectral vs. Dual Energy CT

Techniques That are Available on Research Systems

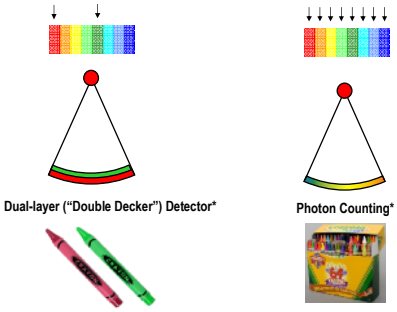

*Works-in-Progress: Pending commercial availability and regulatory clearance

PHILIPS

Dual-Layer CT (Orion-N)

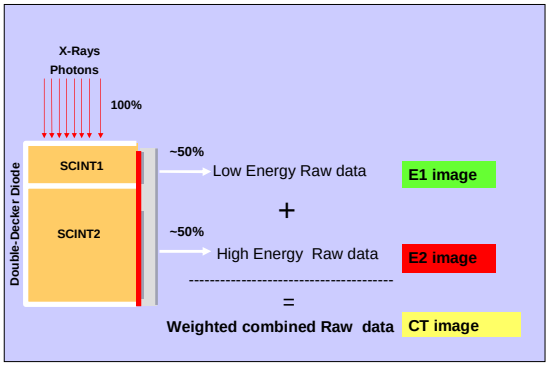

PHILIPS

Spectral CT

How does spectral CT fit into today's standard of care?

"new clinical features, such as spectral imaging, may still be works in progress through 2010 and longer" imaging 5g2 Question of the Month

- No medical guidelines include spectral CT
- No reimbursement for spectral CT
- No large studies have been published for spectral CT
- Alternative approaches exist for proposed spectral CT clinical applications
- Rapidly changing technology

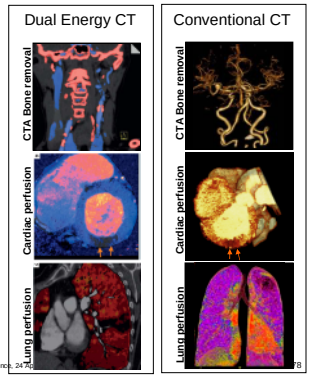

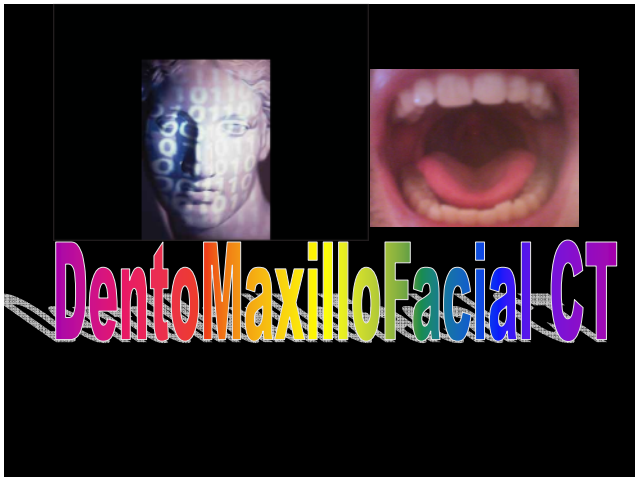

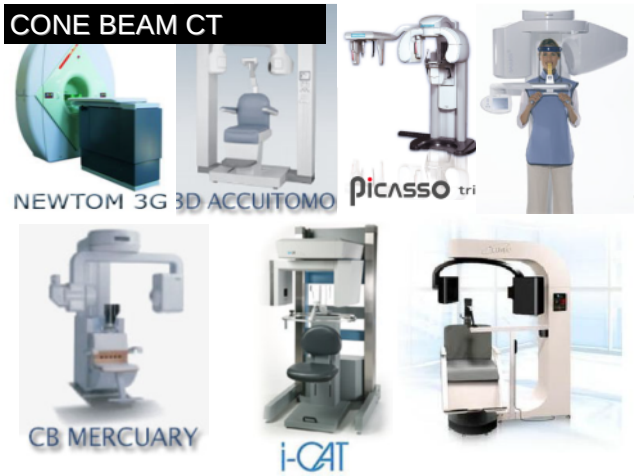

Advantages in Dental Imaging

- Lower dose than helical CT
- Compact design
- Superior images to Panoramic
- Low cost
- Low heat load

Dose:

Panoramic: 6-20 µSv

CBCT: 20-70 µSv

Conventional CT: 314 µSv

CBCT vs. Panoramic

The i-Cat CBCT

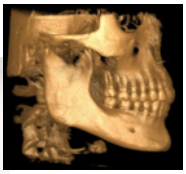

Cephalometric CBCT image

Cephalometric Panoramic image

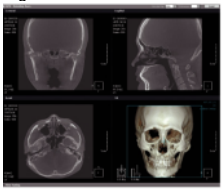

Shortcomings

- Metal artifacts?
- Worse low contrast detectability
- Long scan times = motion artifacts
- Slightly Inferior quality to conventional CT

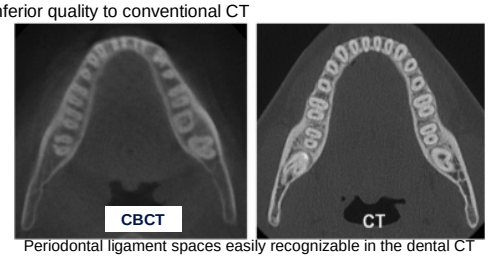

Periodontal ligament spaces easily recognizable in the dental CT but not satisfactory in the CBCT

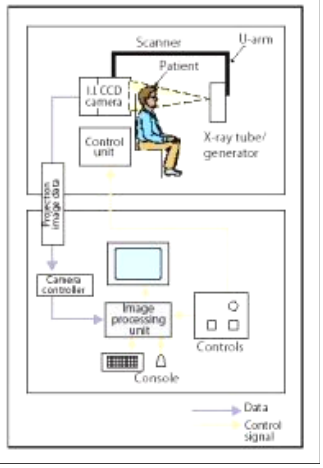

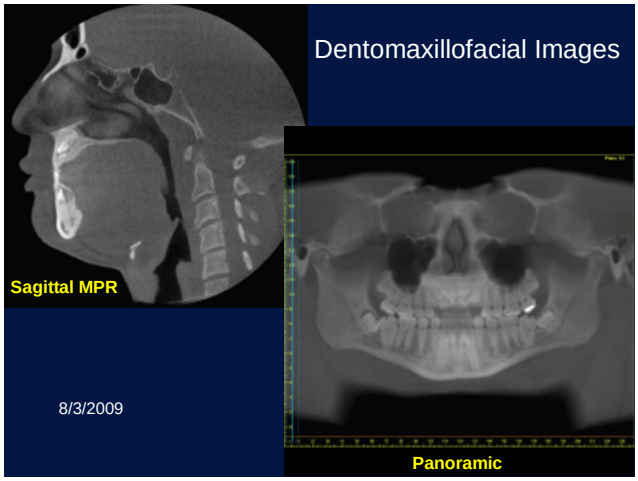

NeuroICU & ENT Office CT

8/3/2009

8-Slice Portable CT Scanner

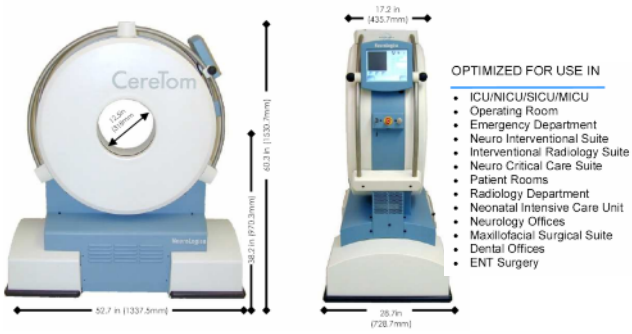

Radiation Data

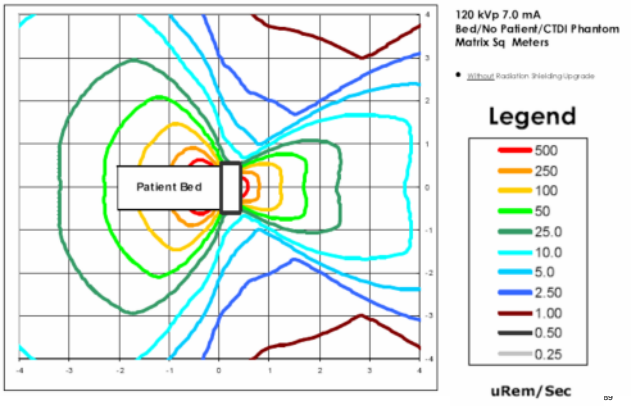

Low X-Ray Radiation Dose

Sinus CT with a full-body scanner

- Adult: 1.0-2.0 mSv
- Child: 1.0-2.0 mSv

Sinus CT with the MiniCAT™ low-dose scanner

- Adult: 0.13 mSv (7-15 x lower radiation dose)
- Child: 0.07 mSv (14-28 x lower radiation dose)

This is the same pt scanned within 24 hours using the Ceretom portable scanner and then a GE stationary scanner…

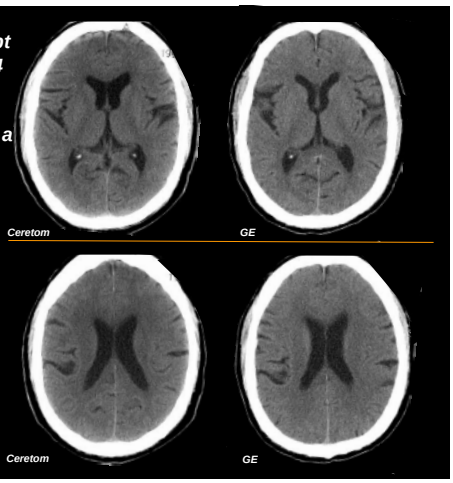

Which do you prefer?

Another Clinical Example….

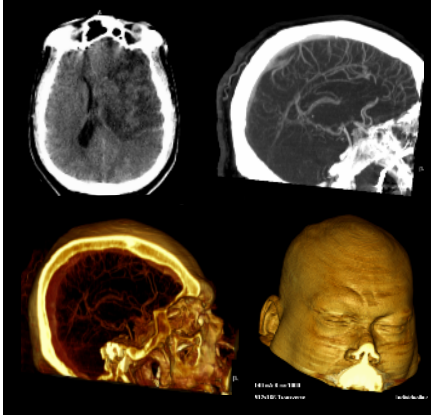

Patient
500lb 38 year old African American male

Symptoms
Aphasia and right sided hemiparesis.

Issues
Unable to scan a patient over 450lbs. Patient went 5 days without a CT scan.

Imaging
Large MCA infarct with mass effect & midline shift.

Cerebrovascular Evaluation

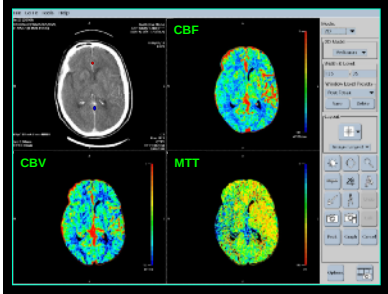

CTA

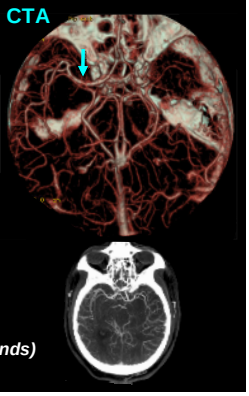

CT Perfusion (CTP)

- *axial, 1 cm slice, 1 slice/second,*
- *acquisition time is user defined (30-40 seconds)*
- *reconstruction on the scanner in real time*

Direct coronal imaging

Direct Coronal Facial CT

4 months apart, same Pt, same dose, same recon settings

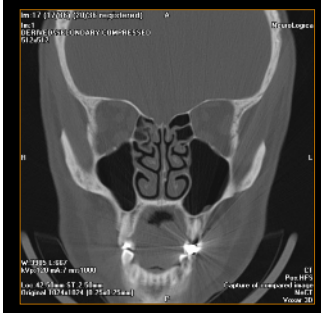

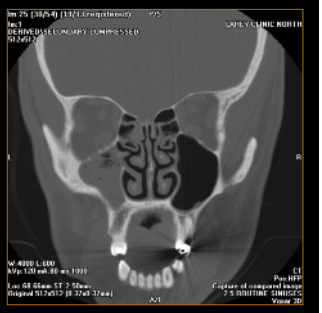

CereTom **GE Lightspeed**

Enterprise Visualization & Analysis

8/3/2009

Use of multimodality and multitemporal data

- Post-processing software tools
  - Visualization: MPR and 3D
  - Fusion: usually limited to image pairs
  - Perfusion: based on assumed compartmental model, not standardized
  - Most interpretations are subjective
- Enterprise integration with PACS
  - Access to images and advanced analysis tools remotely
  - Subspecialized experts apply unique tools for planning, implant specification, response measurement

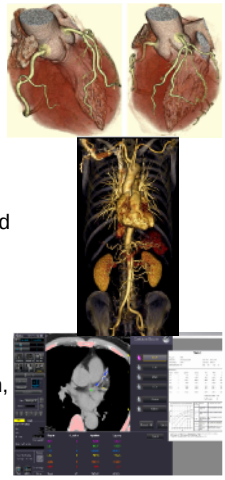

Enterprise Visualization

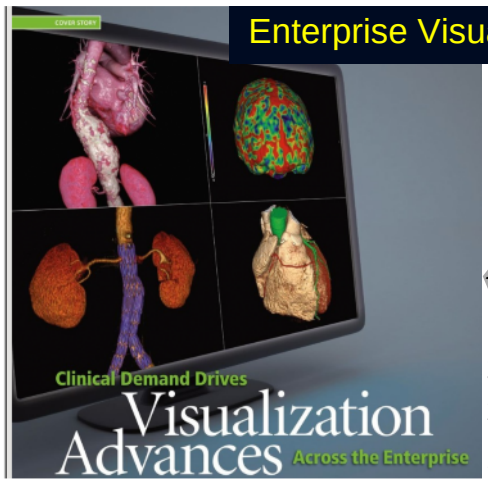

Should we offer advanced visualization services across the enterprise using a client-server system?

Medical Imaging Workstations



Thick Client – expensive, with substantial local processing capability

Thin Client – small, portable Accessible throughout enterprise

Thin Client Solutions

Why
- Time is a physician's most precious asset
- "Every 15-seconds matters"

What
- Images
- 3D Viewing
- All Key Applications

Where
- Scanner
- Workstation
- PACS
- Virtual Private Network
  - Department
  - Hospital
  - Imaging Center
  - Home

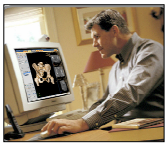

Revolution in thin-client solutions
Adding applications and 3D to viewing

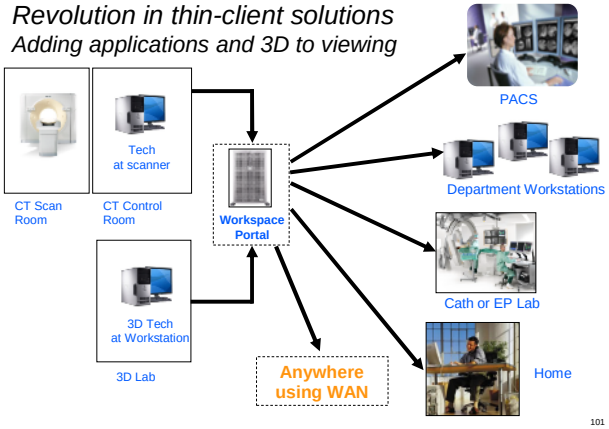

Thin Client Solutions

CT viewing plus

- Comprehensive Cardiac Analysis
- Brain perfusion-summary maps
- CT Angiography Applications
  - AVA Stenosis and Stent Planning
- Lung Nodule Assessment
- Virtual Colonography

All Key Clinical Applications

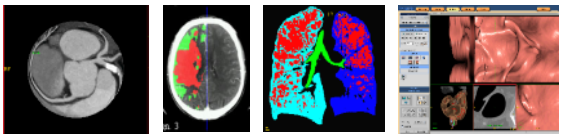

Conclusion

- Multimodality (and multitemporal) imaging is widely used
- Tailoring systems to solve specific diagnostic imaging problems is complex
- Workflow includes post-processing on imaging workstations, distributed across the clinical enterprise
- New scanners and technologies are emerging – wide area CT, dual energy, cone beam OMF scanners, portable CT, PET/MRI

Acknowledgments

- **John Steidley, Ph.D., Philips Medical Systems**
- **GE Healthcare, Inc.**
- **Siemens Medical Solutions, Inc.**
- **Diego Ruiz, Johns Hopkins Hospital**
- **Predrag ("Pedja") Sukovic, Xoran Technologies, Inc.**
- **Bernhard Preim, University of Magdeburg, Germany**
- **John C. Messenger, MD, FACC, University of Colorado**
- **Megan Strother, MD, Vanderbilt University**
- **Patrik Rogalla, MD, Charite' Berlin**
- **Alisa Gean, MD, UCSF Radiology**
- **David Rosenblum, DO, Case Western Reserve Univ.**

Thank You