Multimodality Breast Imaging Systems

Tomo/Ultrasound/Optics, Ultrasound/Other

Paul L. Carson, Ph.D.

Mitchell M. Goodsitt, Ph.D.
Xueding Wang, Ph.D.
Gerald LeCarpentier, Ph.D.
Marilyn A. Roubidoux, M.D.
Mark A. Helvie, M.D.
Frederic Padilla, Ph.D.
Zhixing Xie, Ph.D.
Sacha van der Spek, B.S.
At GE:
Kai Thomenius, Ph.D.
Andrea Schmitz, , Ph.D.

Heang-Ping Chan, Ph.D.
J. Brian Fowlkes, Ph.D.
Oliver Kripfgans, Ph.D.
Ganesh Narayanasamy, Ph.D.
Rene Pinsky, M.D.
Chintana Paramagul, M.D.
Sumedha Sinha, M.S.
Chris Lashbrook, R.T.
At GE:
Carl Chalek, Ph.D.
Anne Hall, Ph.D.

Acknowledgements & Disclaimer

- Most of the illustrations and most of the U of M work described here were supported in part by PHS grants R01 CA91713, CA91713- S1, CA115267 and, previously, PO1 CA87634.
- The first 3 grants are in partnership with General Electric Global Research Center, Niskayuna, NY.
- Opinions are those of the author.

Outline

- Combinable modalities with screening potential
  - Auto 3D Ultras. - 2/3D x-ray - Optical - MRI
- The two geometries, dependent and compressed
  - Breast Tomo/Ultras./Optical or photoacoustic
  - MRI/x-ray CT/Ultras./Diffuse Optical
- Colocated and image based registration
- Contrast agents; in screening?
- Other ultras. modes

#1 Ultrasound

- No longer mainly solid/cyst ~ all Dx studies include US
- Automated ultras. – extensive evaluations of screening for breast cancer
- Ultras. is sensitive to cancers not well detected by mammography, particularly in dense breasts
- US screening sees many apparent abnormalities, increasing callbacks. US misses many cancers detected/diagnosed by their microcalcs.
- Colocated ultrasound and BT, MRI or possibly x-CT should essentially eliminate this barrier.

The future of the world (breast screening) is divided into two (or 3) geometries

- Distant 3rd is supine for US and optical, but not compatible for collocating with dependent or compressed breast
- 1st is the conventional mammographic geom.
  - Breast Tomo/Ultras./Optical or photoacoustic
- 2nd is dependent breast in air or water
  - MRI/x-ray CT/Ultras./Optical/Microwave

Combined BT-AUS system

1. Tomosynthesis Unit
2. GE Logiq 9 US Unit
3. Retractable US Scanner, Dual Modality Paddle, then Digital Detector

With GE Global Research

Breast Tomosynthesis (BT)

- X-ray in mammographic geometry is now dominant for good reasons
  - Calcification, fat, H_2O/protein contrast
  - Mean of max thickness 5.5 cm
  - High res., low dose
- No reason x-ray shouldn't be in 3D, with compression till MR improves in several aspects
  - 1 to 2x the equivalent mammography dose
- FDA approval of breast tomosynthesis (BT) delayed because of poor resolution/noise in 2 dimensions for early application and pubs.

LCC

US = LCC (saggital)

- US-suggested ductal extension ↘
- Density 4
- Mammo - 2.3 cm spiculated mass
- 56 y/o

Invasive CA

(14071)

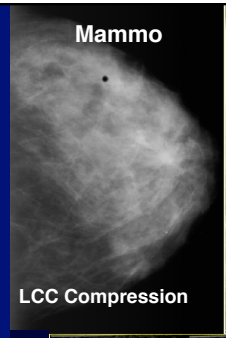

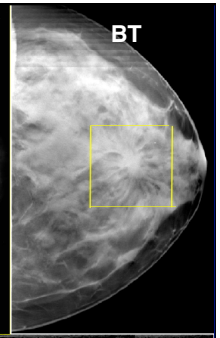

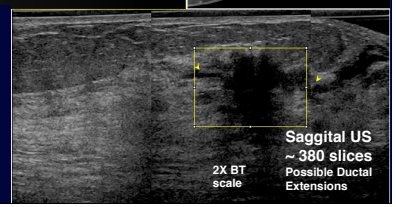

US Screening - ↑↑ Mammo Sensitivity, ↓ Specificity

- Particularly in dense breasts
- ACRIN 666, Kolb papers, international experience

- Not enough skilled practitioners to perform US screening in the US and pretty expensive
- Map of same tissues in x-ray & US a problem
- Goal of supine & prone automated US systems

SonoVu - Standalone by U-Systems, Inc. (Siemens)

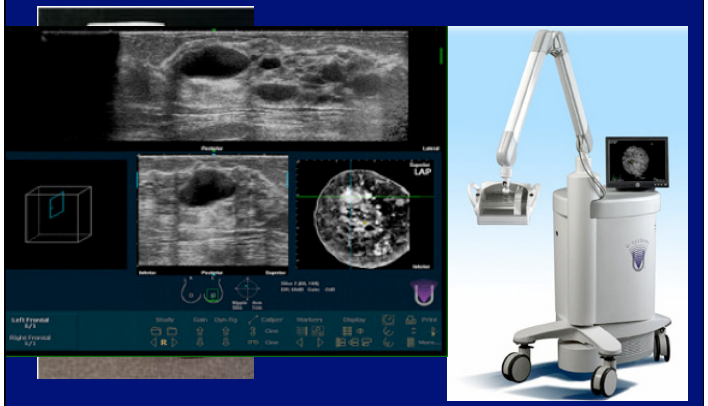

Manually Guided Supine 3D



~Most positive AUS clin trials reports From Sonocine Website

http://www.sonocine.com/medical.html

Colocation Reader Study Display GUI showing Corresponding VOI's in DBT & AUS

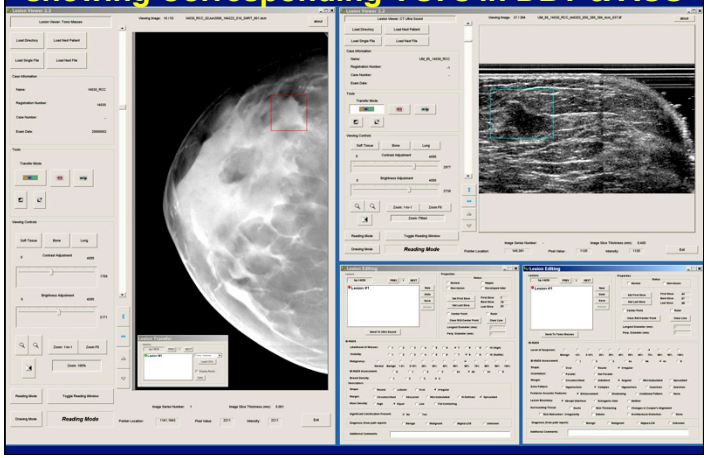

New human study of the combined system BT & BT + AUS, of 52 going to Bx

- Preliminary results of human study of the combined system:
- AUS did not aid substantially in diagnosis of these masses chosen by mammo and US to go to biopsy, while BT did.
- I.e., BT improved over mammo plus hand-performed US, whereas adding AUS to BT increased sensitivity slightly and decreased specificity.
- If simple cyst cases had been included at an ~ typical 22% of diagnostic US exams, and AUS identified them, then the PPV of BT alone or of clincal mammo & US would be 24 or 25%, respectively, *vs.* 30% for BT & AUS.
- Readers opined strongly that adding US to BT would in a screening situation would allow them to make fewer referalls for further imaging studies.
- CAs - 13, benign – 39. 5 readers.

Misdiagnosis by two of four r'drs on BT as Benign, corrected by US

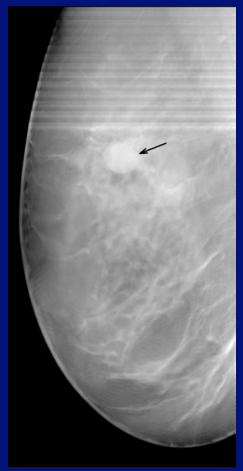

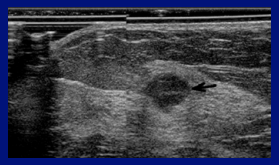

RLM view of a carcinoma (black arrow)

Improvements

- Coverage
  - Cowling
  - Mesh paddle
  - Dual Sided imaging

- Other Image Quality Improvements
  - …

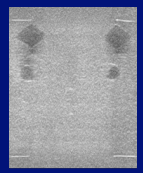

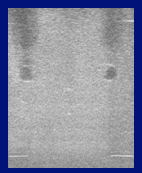

Phantom for Dual Sided Imaging

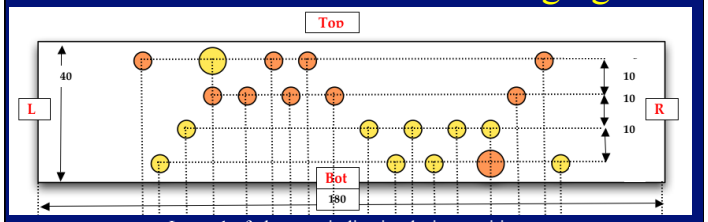

Layer 1 of phantom indicating lesion positions

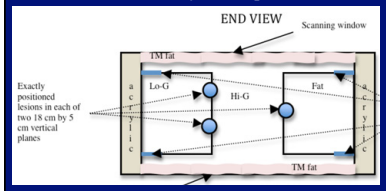

Cyst: A-5 mm, AL-8 mm.	
Hypoechoic high att.: B-5 mm, BcL-8 & 10 mm.	
Hyperechoic high att: CL-8 mm.	

Phantom 2 design

Tissue-Mimicking Material	Speed of Sound (m/s)	Relative Echogenicity (dB)	Att. coeff. at 10 MHz (dB/cm)
low speed glandular	1455	0	5.26
low speed glandular	1423	-7	4.61
hyperechoic lesion	1550	+5	11.76
hypoechoic lesions	1539	-11	15.64
fat	1412	-10	5.25
cyst			

Relevant physical properties of materials in high SOS-contrast phantom.
EL Madsen and G Frank designed with us and constructed.

US Images from Top, Bottom, Fused

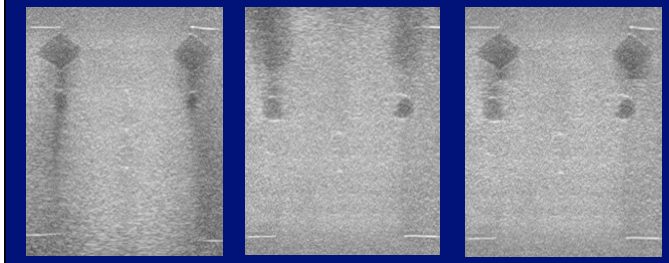

(a) (b) (c)

Figure 5: Cancer-like double cones and cysts imaged from both sides [(a) and (b)] and roughly fused (c). Subcutaneous fat layers cropped.

Diffuse Optical or Photoacoustic

- Diffuse optical imaging and photoacoustic tomography (PAT) are sensitive to vascular anomalies including small vessels with flow too slow for Doppler US.
- PAT offers higher resolution, but optical penetration limitations.
- The penetration looks promising for PAT imaging from both sides of the compressed breast.
- Spectroscopic PAT, S-PAT can distinguish oxy- and deoxyhemoglobin
- Coregistered BT, US and optical imaging might well provide similar screening effectiveness as the combination of current mammography, ultrasound and contrast MRI examinations.

Three-modality Imaging of Breast Cancer

Combine three promising medical imaging modalities for breast cancer detection and diagnosis: 3D x-ray, advanced ultrasound (US), and photoacoustic tomography (PAT)

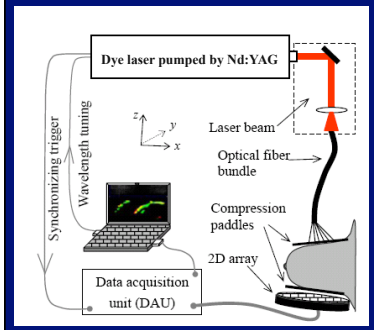

Combined US and NIR systems and a handheld probe with a centrally located US linear array and NIR source-detector fibers distributed at the periphery of the probe.

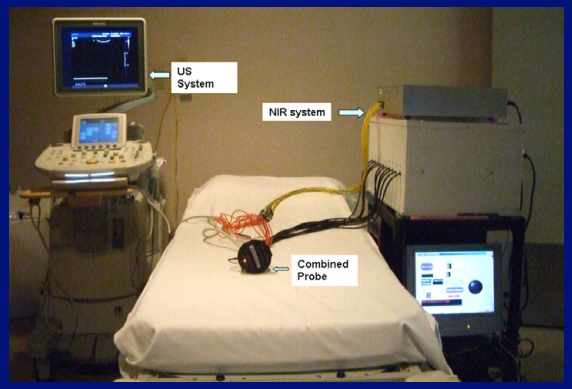

Zhu Q et al. Radiology doi:10.1148/radiol.10091237

(a) US image of a suspicious tubular-like lesion (arrow) located at12-o'clock position in the right breast in 71-year-old woman.

(b) tHb map showed an isolated, well-defined mass with high tHb of maximum of 97.8 μmol/L and average of 65.7 μmol/L at the corresponding location of section 3.

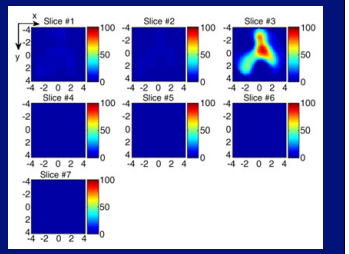

Zhu Q et al. Radiology doi:10.1148/radiol.10091237

MRI/x-ray CT/Ultras./Optical/Microwave

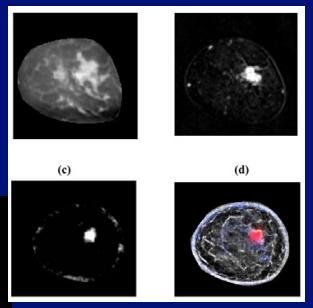

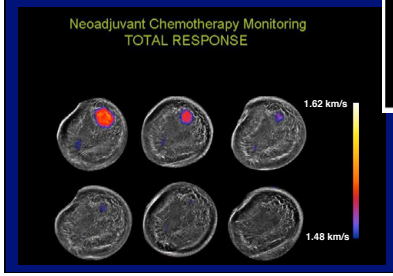

Neb Duric, Ph.D. Karmanos Cancer Institute

Similar work at Techniscan with UCSD and now Mayo

Other Ultrasound Modes

- Additions possible to the considerably orthogonal information provided by BT, pulse echo US and S-PAT
- Scatterer size and density
- Elasticity, strain or shear wave velocity
- Transmission ultrasound imaging - attenuation, speed of sound