Use of molecular and functional imaging for treatment planning
The Good, The Bad and The Ugly

Robert Jeraj, PhD
Associate Professor of Medical Physics, Human Oncology, Radiology and Biomedical Engineering
University of Wisconsin Carbone Cancer Center, Madison, WI
rjeraj@wisc.edu

University of Wisconsin
SCHOOL OF MEDICINE
AND PUBLIC HEALTH

Molecular and functional imaging

- **Molecular Imaging:** "Visualization, characterization and measurement of biological processes at the molecular and cellular levels in humans and other living systems"
  - It can probe molecular abnormalities that are the **basis of disease** rather than image the end effects
- **Functional Imaging:** "Visualization, characterization and measurement of organ function in humans and other living systems"
  - It can probe **functional status** of an organ, which is direct consequence of disease or treatment

See *in vivo* what we can see *in vitro*

Microscopy



Courtesy of A. van der Kogel, Nijmegen, NL

Proliferation
Hypoxia

PET/CT imaging

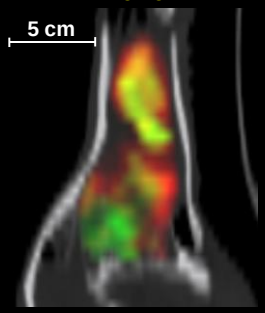

Paradigm shift in imaging

- From **QUALITATIVE DIAGNOSTIC IMAGING** (Diagnosis and Staging)…
- …To **QUANTITATIVE THERAPEUTIC IMAGING** (Target definition, Treatment assessment)
- **Limited experience** with imaging in treatment context, compared to diagnostic (except CT)!
- **Dangerous** to use diagnostic quality imaging in a therapeutic context **(Qualitative ≠ Quantitative)**

PET imaging uncertainties

- **Technical factors**
  - Relative calibration between PET scanner and dose calibrator (**10%**)
  - Residual activity in syringe (**5%**)
  - Incorrect synchronization of clocks (**10%**)
  - Injection vs calibration time (**10%**)
  - Quality of administration (**50%**)
- **Physical factors**
  - Scan acquisition parameters (**15%**)
  - Image reconstruction parameters (**30%**)
  - Use of contrast agents (**15%**)
- **Analytical factors**
  - Region of interest (ROI) definition (**50%**)
  - Image processing (**25%**)
- **Biological factors**
  - Patient positioning (**15%**)
  - Patient breathing (**30%**)
  - Uptake period (**15%**)
  - Blood glucose levels (**15%**)

Jeraj 2010

Boellaard et al 2009, J Nucl Med 50: 11S

Imaging in oncology

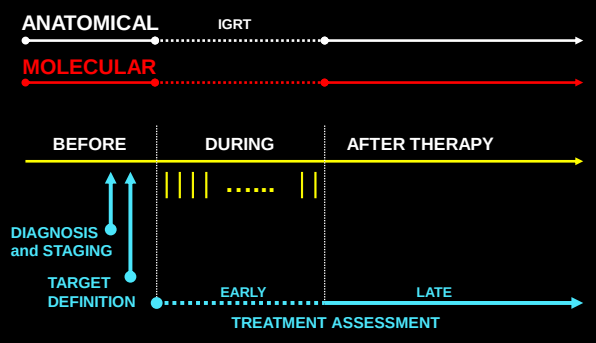

Imaging in oncology

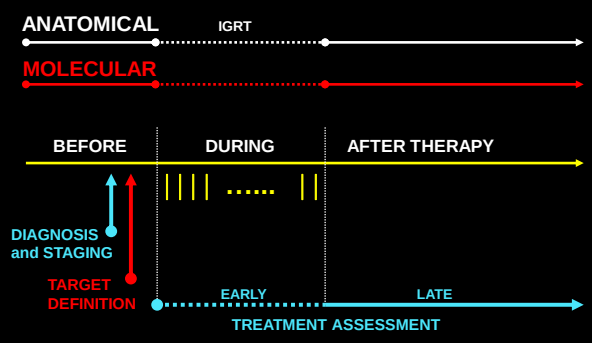

Target definition

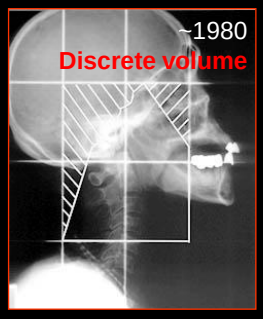

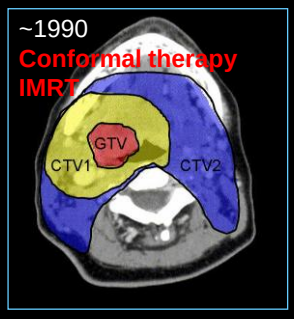

Current state of affairs…

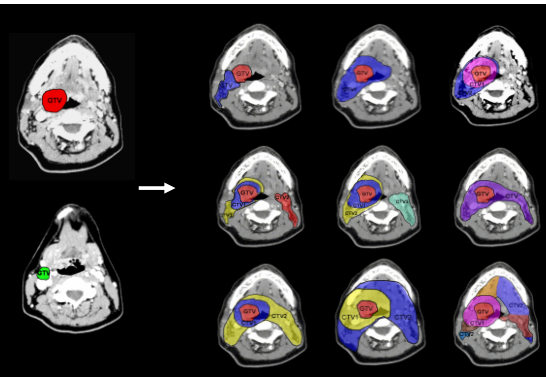

Hong and Harari, 2005

What is the real tumor extent?

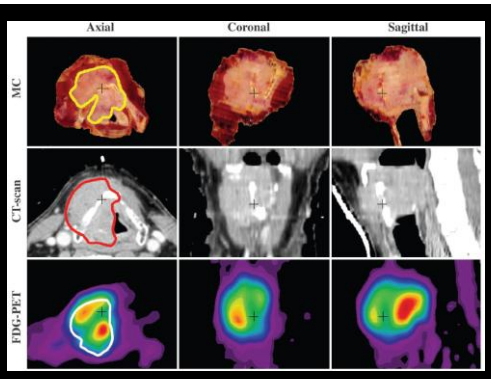

Daisne et al 2004, Radiology 233, 93.

Different modalities – different answer

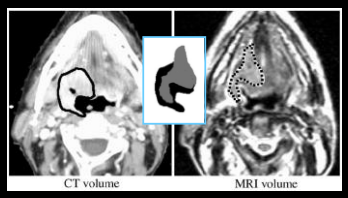

Average Mismatch of Laryngeal GTVs between Imaging Modalities and the Surgical Specimen

Pair	Mismatched Volume (%)
CT	
To MR imaging	26 (6.2/23.8)
To FDG PET	48 (7.8/16.3)
To specimen	81 (10.2/12.6)
MR imaging	
To CT	45 (9.3/20.8)
To FDG PET	67 (11.0/16.3)
To specimen	107 (13.4/12.6)
FDG PET	
To CT	17 (3.5/20.8)
To MR imaging	15 (3.6/23.8)
To specimen	46 (5.8/12.6)
Specimen	
To CT	10 (2.0/20.8)
To MR imaging	9 (2.2/23.8)
To FDG PET	13 (2.1/16.3)

Note.—Data in parentheses are the average mismatched volumes in cubic centimeters.

Daisne et al 2004, Radiology 233, 93.

Same modality – different answers

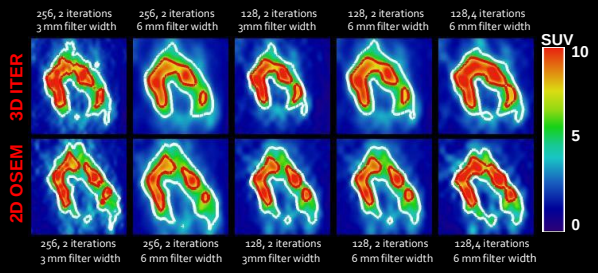

FDG PET/CT

Imaging uncertainties – extra margins

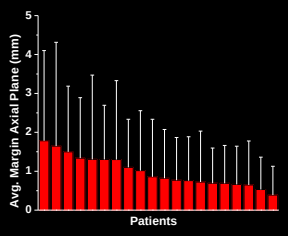

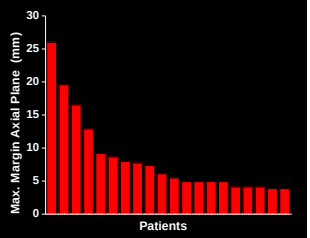

Margin plane	Mean ± SD (mm)	Maximum (mm)	Avg. Max ± SD (mm)	Maximum (mm)
Axial	1.0 ± 0.4	1.8	8.4 ± 6.0	26.0
Coronal	0.5 ± 0.3	1.2	10.6 ± 6.1	26.7
Sagittal	0.5 ± 0.3	1.2	10.2 ± 5.3	22.1

And here comes DOSE PAINTING…

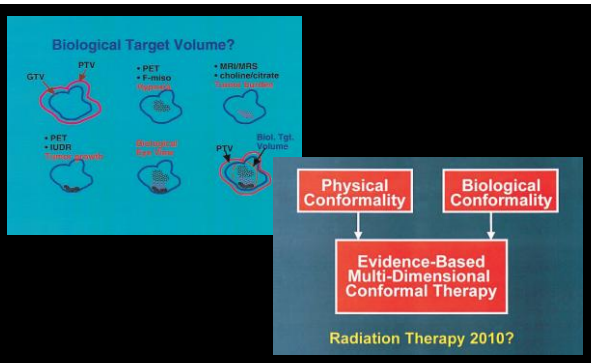

Ling et al 2000, Int J Rad Oncol Biol Phys 47: 551

Spatial distribution of tumor phenotypes

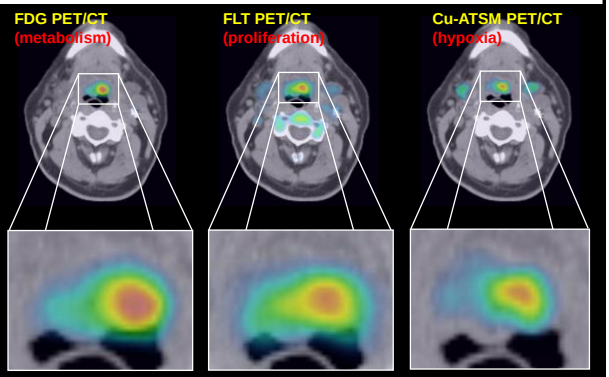

Spatial distribution of tumor phenotypes

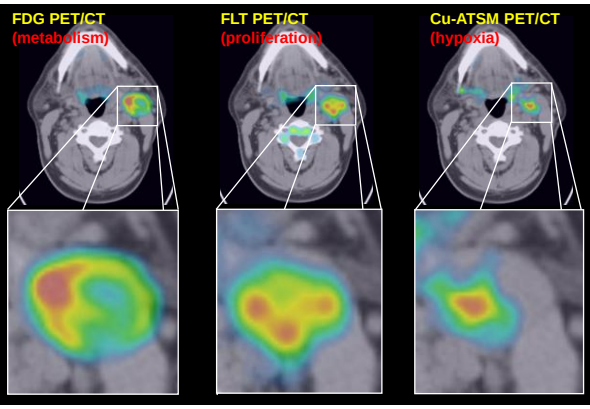

How to combine this information?

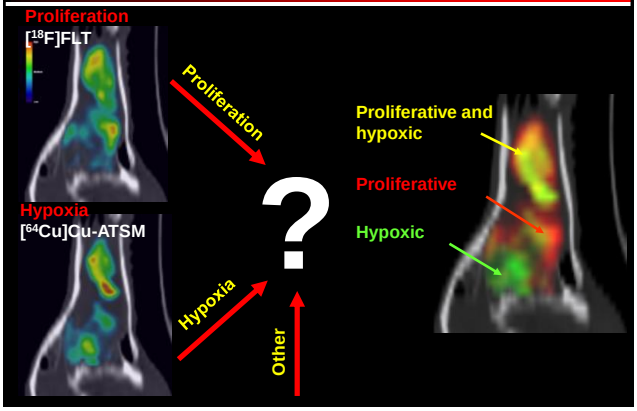

Uniform dose → Non-uniform dose

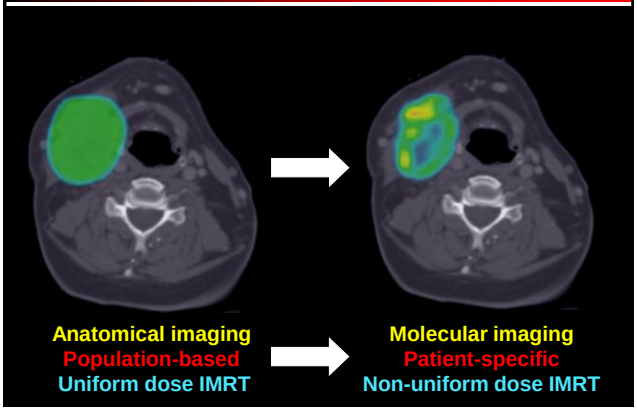

Symposium

- **Yue Cao:** MRI for Radiation Treatment Planning
- **Dimitris Visvikis:** The Good, the Bad and the Ugly About Using PET for Treatment Planning
- **Vincent Gregoire:** This House Believes That the Use of Functional Imaging for Treatment Planning of Head and Neck Tumors Need to be Carefully Considered