This house believes that the use of Functional Imaging for treatment planning of head and neck tumors needs to be carefully considered.

Vincent GREGOIRE, M.D., Ph.D., Hon. FRCR

Head and Neck Oncology Program, Radiation Oncology Dept. & Center for Molecular Imaging and Experimental Radiotherapy, Université Catholique de Louvain, St-Luc University Hospital, Brussels, Belgium

IMRT for Head and Neck Tumors

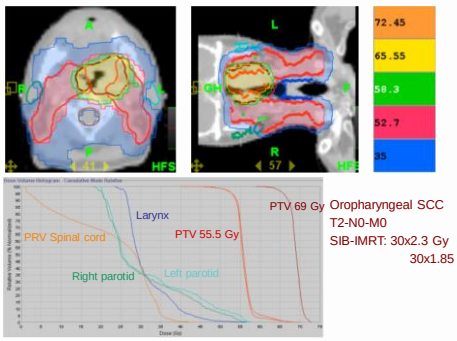

Oropharyngeal SCC
T2-N0-M0
SIB-IMRT: 30x2.3 Gy
30x1.85 Gy

This house believes that …

- RO will be (even more) multidisciplinary…
- RO is conformal (e.g. IMRT, proton, hadrons)…
- RO will be tailored (individualized) (based on imaging and molecular profiling) and adaptive …
- RO will be associated with targeted agents …

Heterogeneity in H&N TV delineation

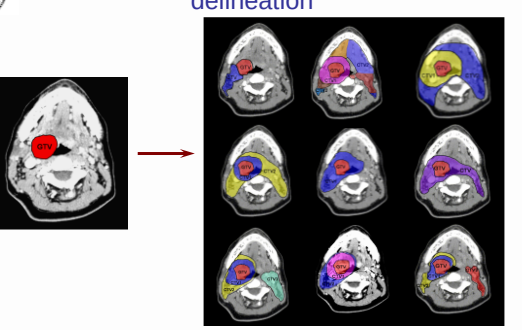

Harari et al., 200

Target selection and delineation

Betrayal of images

This is not an apple…

R. Magritte

Segmentation methods: one by lab…!

Manual delineation
- Visual interpretation
- Subjective approach!

Histogram-based
- Fixed threshold (SUV, %)
- Adaptive threshold (SBR)
- Soft thresholding (probabilistic)

Feature-based
- (Fuzzy) clustering
- Clustering of TAC

Image-based
- Probabilistic modeling
- Gradient based

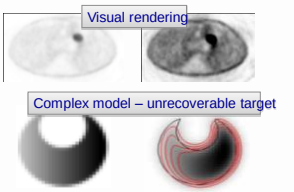

Δ Experimental conditions
Δ Data sets
Δ Validation studies

➡ NO CONSENSUS

Variability in PET image segmentation for H&N tumors …

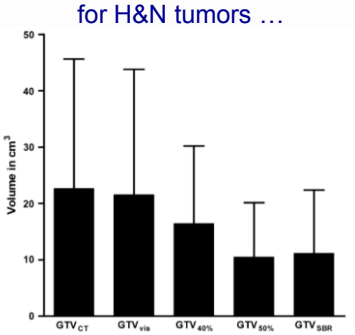

Schinagl et al., 2007

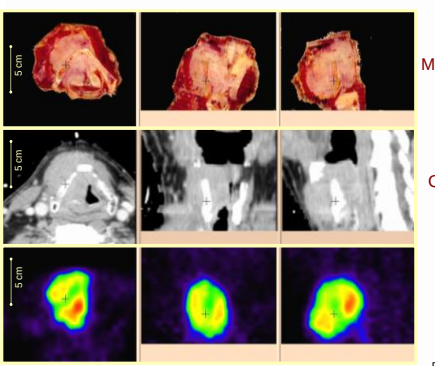

Macroscopy

CAT Scan

^{18}F-FDG PET

Daisne *et al*, 2003

threshold?

Patient	GTV (ml) Surgical Specimen	40%	50%	
1	8.3	23.3	11.8	55.1
2	5.2	10.9	6.7	55.7
3	30.9	29.7	21.7	38.6
4	4.1	8	5.3	57
5	5.6	37.9	19.2	70.9
6	8.6	9.7	6.6	43.2
7	17.3	35.9	25.5	59
8	15.4	41.8	28.3	67.5
9	24.3	39.9	30	56.5
mean	13.3	26.5*	17.2	55.9

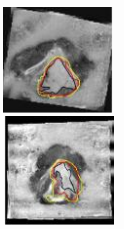

AAPM
Aug. 2011

Geets *et al*, 200

Image-Guided Radiation Therapy in HNSCC
The 4th dimension …

FDG-PET

0 Gy

50 Gy

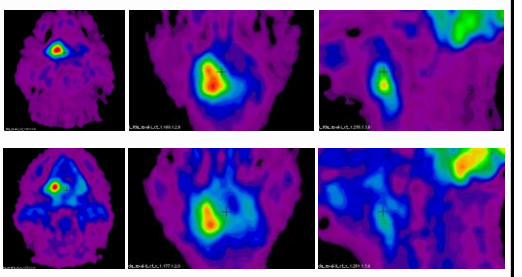

AAPM
Aug. 2011

Geets *et al*, 2003

PET image segmentation during RxTh

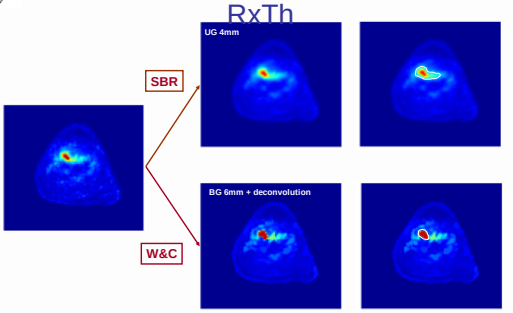

AAPM
Aug. 2011

J. Lee & X. Geets, 2005

PET in radiotherapy planning for NSCLC

Pathological correlation?

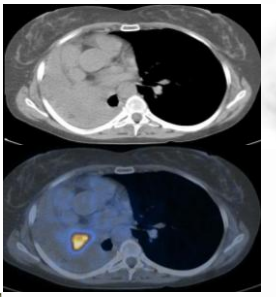

Clinical validation?

NSCLC with atelectasis

AAPM
Aug. 2011

Deruysscher, 2007

NSCLC digital MC PET phantom
Different segmentation methods …

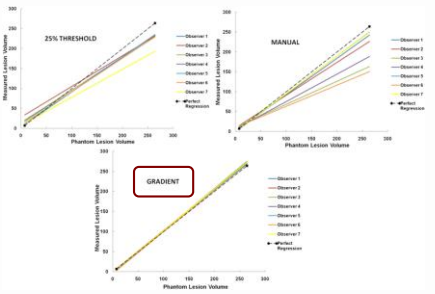

Werner-Wasik et al., 201

PET in radiotherapy planning for NSCLC

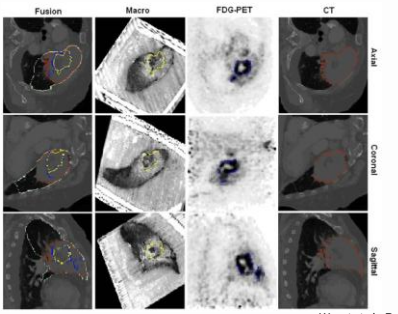

Wanet et al., Radioth. Oncol. 20

PET in radiotherapy planning for NSCLC

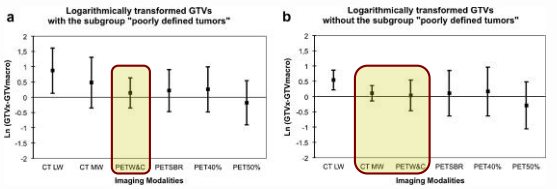

Wanet et al., Radioth. Oncol. 20

Objective evaluation of the available segmentation methods

Methods

Statistical methods

Gradient detection

Images

Simulated PET images (MC)

Pathology validated patient images

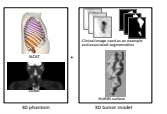

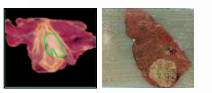

Figures of merit

Precision
Shape/volume

Accuracy
Reproducibility/robustness

AAPM TG211, 201

PET imaging: a wide range of molecular probes

- **Glucose metabolism**
  18F-FDG
- **Protein synthesis**
  11C-MET
  18F-FET
- **Proliferation**
  18F-FLT
- **Hypoxia**
  18F-FMISO
  18F-FAZA
- **Receptors**
  18F-FES
  68GA-Traztuzumab (HER2)
  64Cu-DOTA-panitumumab (EGF

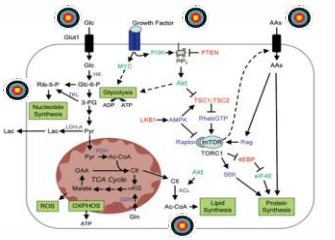

Courtesy of Geets, 20

A word of caution …

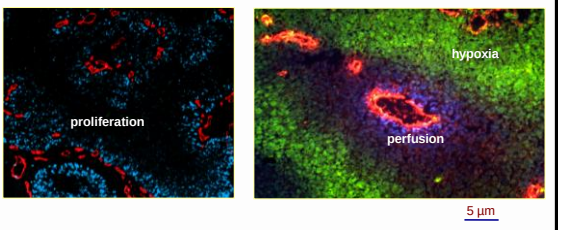

From Kaanders., 2001

Biological heterogeneity

[^{18}F]-FDG TEP

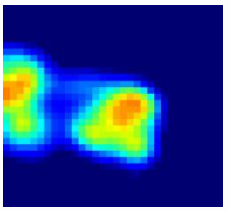

Résolution 2.3 mm

Registered autoradiography

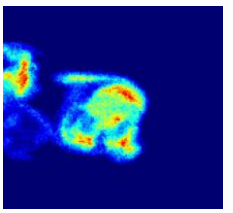

Résolution 0.1 mm

N. Christian, 2010

Effect of resolution

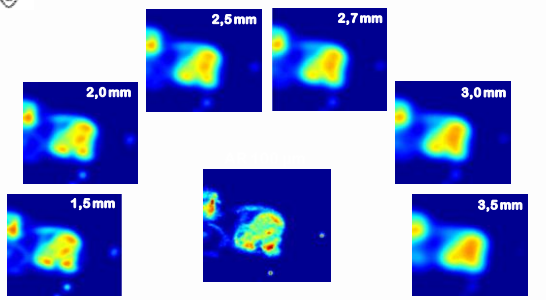

N. Christian, 2010

In Vivo experimental set-up

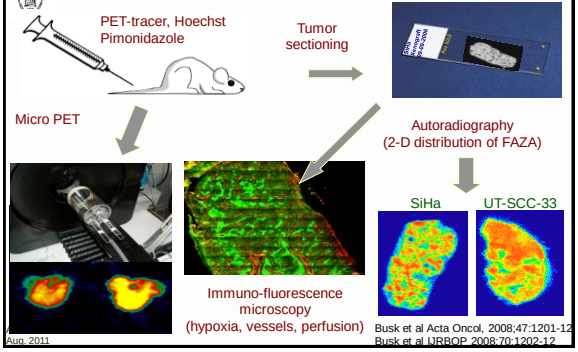

Busk et al Acta Oncol, 2008;47:1201-12
Busk et al IJRBOP 2008;70:1202-12

FAZA autoradiogram & pimonidazol

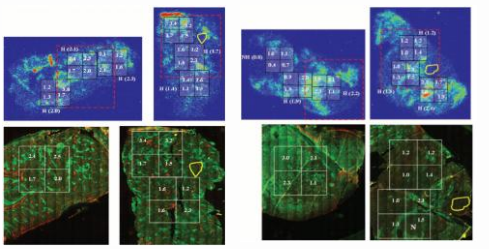

Busk et al Acta Oncol, 2008;47:1201-12
Busk et al IJRBOP 2008;70:1202-12

Scaling issue…

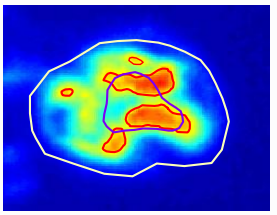

Tumor: FSA II
Mouse n° 2_1
Tum Volume: 2.30 ml
^{18}F-FDG – 300 µCi

Volume corresponding to the highest 10 percent of activity

Mismatch (∿∪)

N. Christian, 2010

Scaling issue…

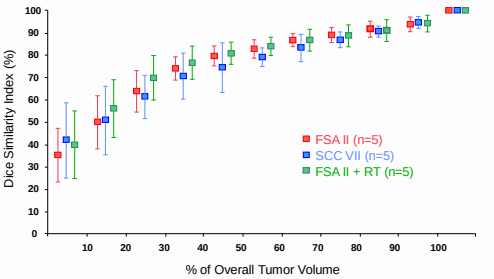

N. Christian, 2007

Effect of resolution

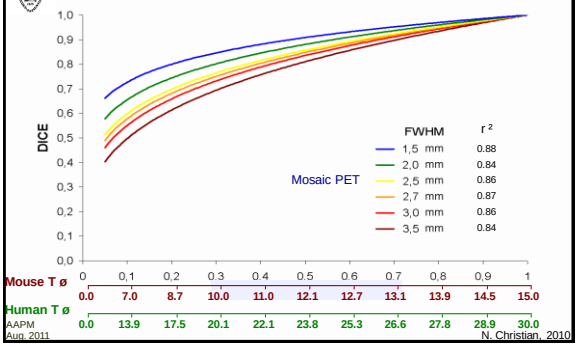

N. Christian, 2010

PET imaging: a wide range of molecular probes

- **Glucose metabolism**
  18F-FDG
- **Protein synthesis**
  11C-MET
  18F-FET
- **Proliferation**
  18F-FLT
- **Hypoxia**
  18F-FMISO
  18F-FAZA
- **Receptors**
  18F-FES
  68GA-Traztuzumab (HER2)
  64Cu-DOTA-panitumumab (EGF

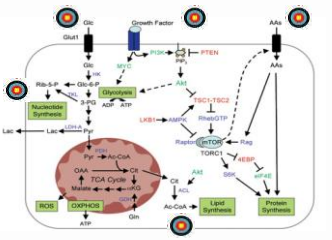

Courtesy of Geets, 20

Comparison ^{18}F-FDG / ^{14}C-EF3

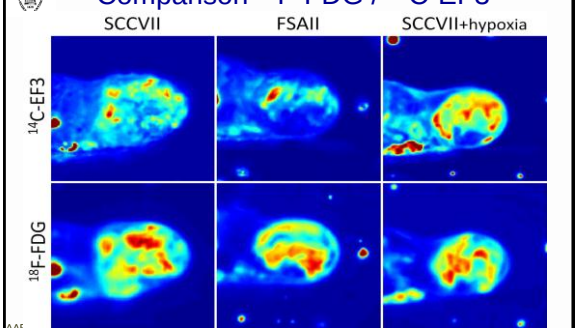

N. Christian, 2010

Comparison ^{18}F-FDG / ^{14}C-EF3

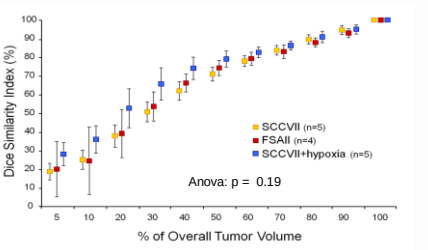

N. Christian, 2010

“Dose painting” by number…

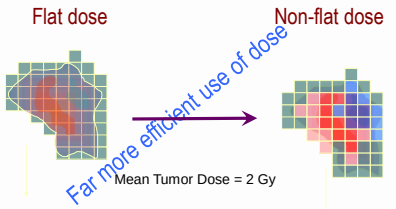

Courtesy of D. De Ruysscher

“Dose painting” : the physics issue

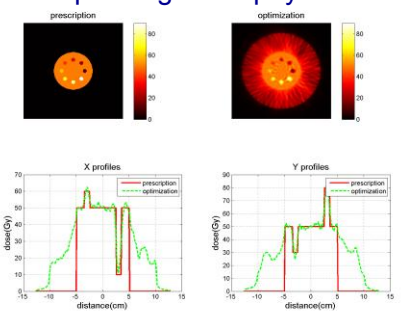

Molecular imaging dose painting by number

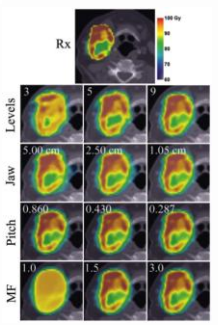

- Tomotherapy Hi-Art
- H&N SCC: T4N2bM0
- 60 Gy + SIB of 30 Gy

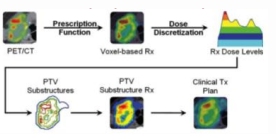

Deveau et al., 2010

Molecular imaging dose painting by number

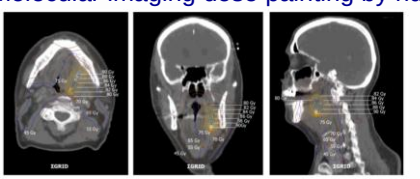

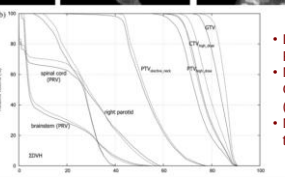

- DPBN based on FDG-PET
- Median dose of 80.9 Gy (n=7) et 85.9 Gy (n=14)
- No grade 4 acute toxicity

Duprez et al., 2010

Functional imaging for H&N treatment planning

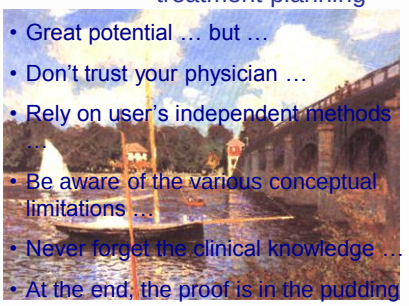

- Great potential … but …
- Don't trust your physician …
- Rely on user's independent methods …
- Be aware of the various conceptual limitations …
- Never forget the clinical knowledge …
- At the end, the proof is in the pudding …

The Bridge at Argenteuil

C. Monet, 1874