PET imaging of tumor microenvironment for radiation treatment planning

A. Pugachev

2011 AAPM
Vancouver, BC, Canada

PET in radiation oncology

PET imaging has many applications in radiation oncology:

- Staging, restaging
- Response assessment
- Target delineation
- Biological boost volume definition
- Dose painting
- etc.

VCU MASSEY CANCER CENTER
Virginia Commonwealth University

Validation of PET in radiation oncology

"Validation of any imaging biomarker assay requires demonstration that the performance of the assay is suitable and reliable for the intended analytical application"

2009 Accelerating the Development of Biomarkers for Drug Safety: Workshop Summary, Washington (DC)

VCU MASSEY CANCER CENTER

Validation of PET in radiation oncology

"Validation of any imaging biomarker assay requires demonstration that the performance of the assay is suitable and reliable for the intended analytical application"

2009 Accelerating the Development of Biomarkers for Drug Safety: Workshop Summary, Washington (DC)

VCU MASSEY CANCER CENTER

PET-guided radiation treatment

CT
(anatomical data)

PET-CT
(functional data)

PTV +
PET Boost Volume

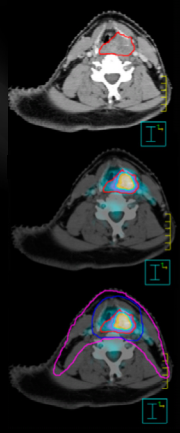

Troost *et al.* 2010 *J.Nucl.Med.* 51(1)

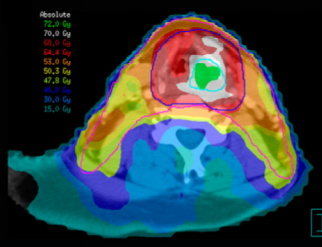

Modified dose distribution

Spatial distribution of the tracer

Spatial characteristics of dose distribution

VCU MASSEY CANCER CENTER

Interpatient vs Intratumoral (spatial) tracer uptake variations

Interpatient variation

- Example: Acquiring biopsies from multiple patients and studying correlation between Ki-67 positivity and FLT PET $SUV_{average}$ or SUV_{peak}
- Useful for evaluating predictive power of $SUV_{average}$ or SUV_{peak} of FLT PET image with respect to average Ki-67 positivity of a lesion
- Application: Treatment response assessment

VCU MASSEY CANCER CENTER

Interpatient vs Intratumoral (spatial) tracer uptake variations

Intratumoral variation

- Example: Acquiring multiple biopsies and studying correlation between Ki-67 positivity and local FLT uptake in a biopsy specimen
- Comparing spatial pattern of FLT uptake to the spatial pattern of Ki-67 staining in the same/adjacent tumor tissue section
- Allows for evaluation of FLT PET with respect to its ability to depict the intratumoral variations of Ki-67 expression
- Application: Boost volume definition

VCU MASSEY CANCER CENTER

Small animal validation studies

- Wide range of experimental conditions
- Wealth of histopathological data
- Provide us with a highly heterogeneous microenvironment similar to that observed in human cancers

VCU MASSEY CANCER CENTER

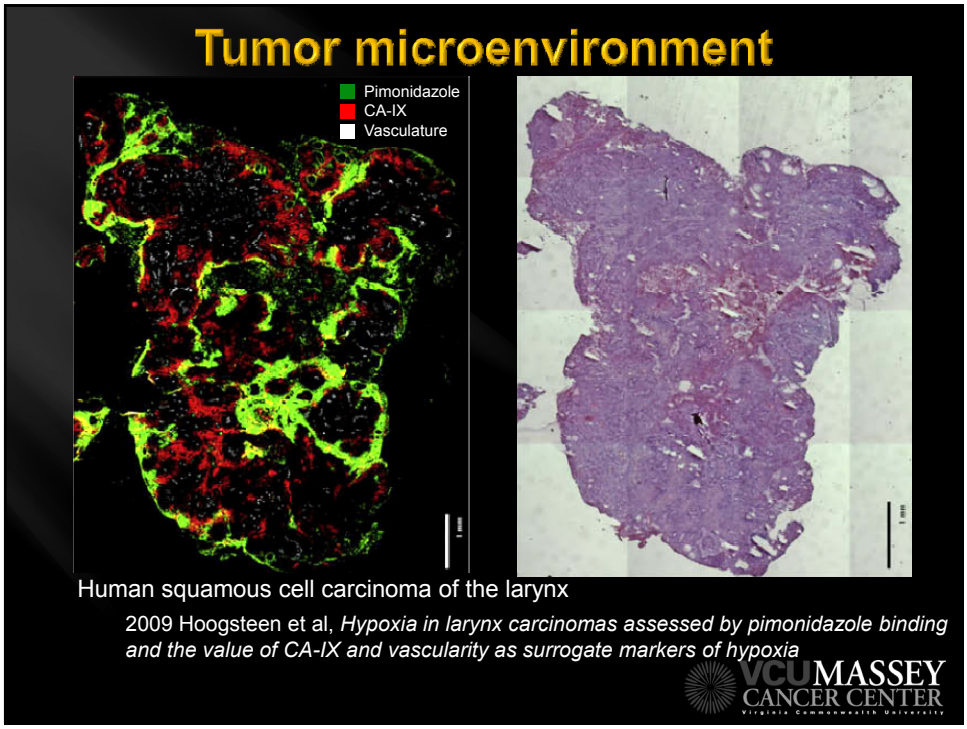
Tumor microenvironment
Pimonidazole
CA-IX
Vasculature
Human squamous cell carcinoma of the larynx
2009 Hoogsteen et al, Hypoxia in larynx carcinomas assessed by pimonidazole binding and the value of CA-IX and vascularity as surrogate markers of hypoxia
VCU MASSEY CANCER CENTER

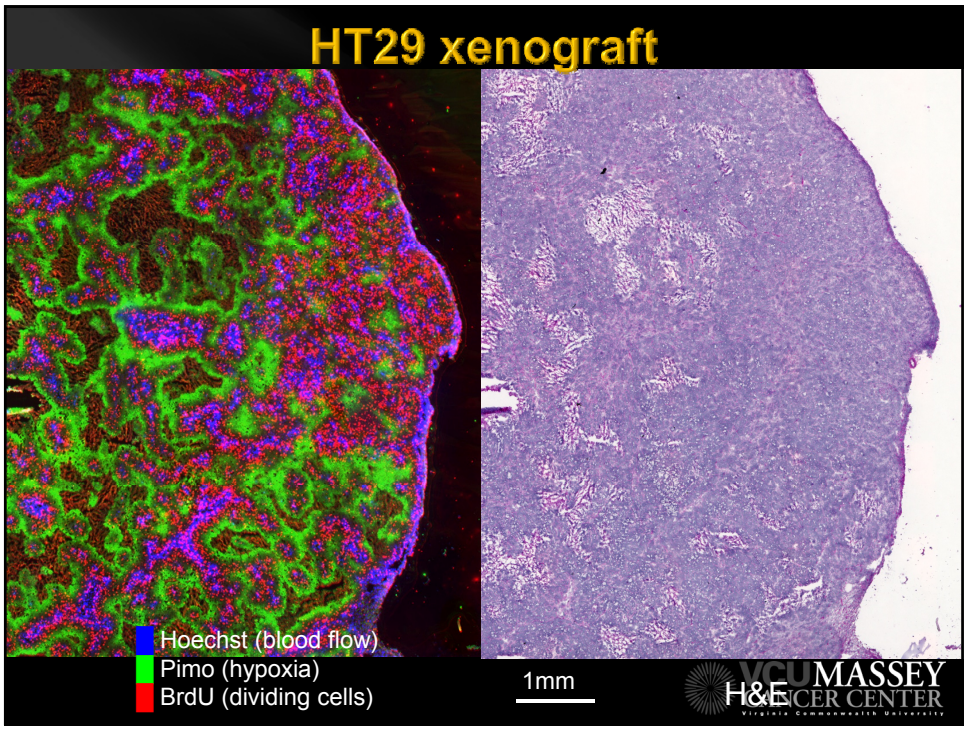
HT29 xenograft
Hoechst (blood flow)
Pimo (hypoxia)
BrdU (dividing cells)
1mm
H&E
VCU MASSEY CANCER CENTER

Small animal validation studies

- Wide range of experimental conditions
- Wealth of histopathological data
- Provide us with a highly heterogeneous microenvironment similar to that observed in human cancers
- Enable evaluation of a PET tracer from the point of view of its affinity to the target

VCU MASSEY CANCER CENTER

HT29 xenograft

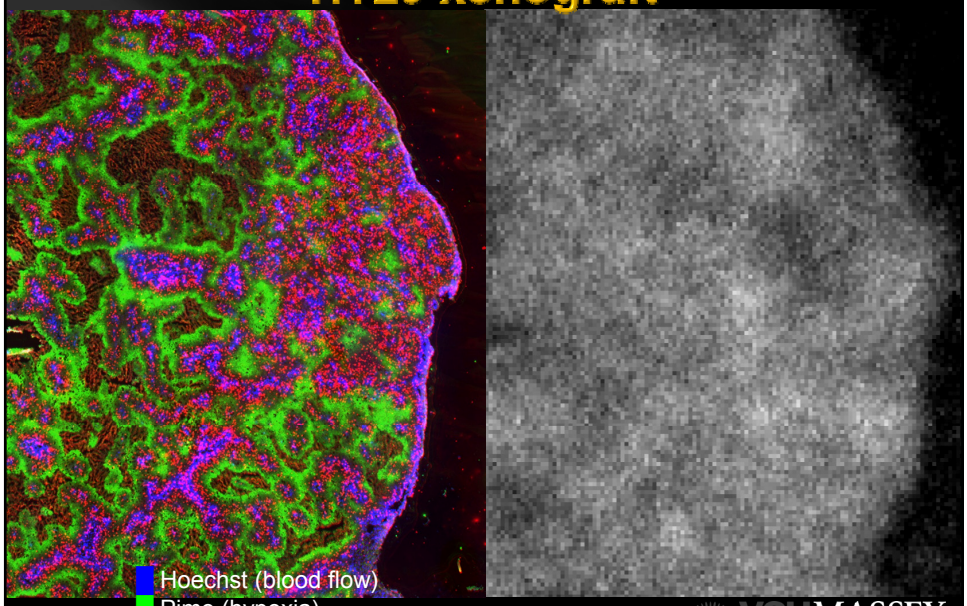

VCU MASSEY CANCER CENTER

Multimodality Hoechst-based Image Registration

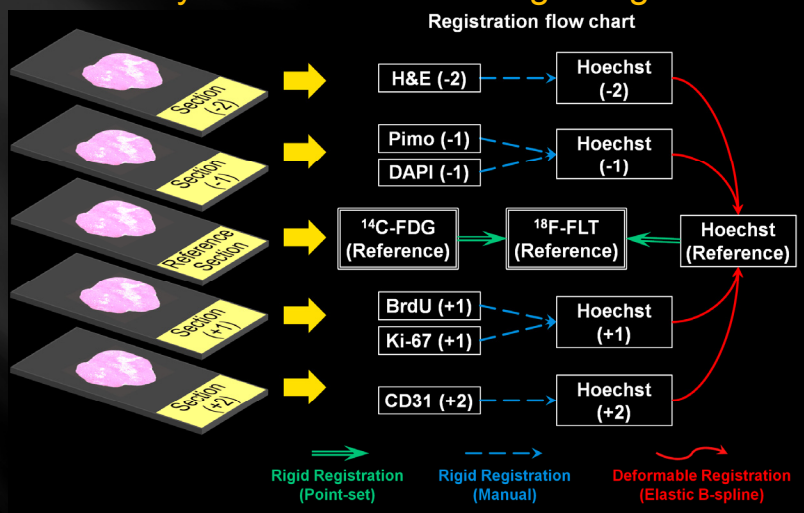

Axente M *et al.* "Comprehensive approach to co-registration of autoradiography and microscopy images acquired from a set of sequential tissue sections", *Journal of Nuclear Medicine* (in press)

13

Small animal PET validation studies

- PET images / tracer distributions in small animal tumors are different from those in human cancers
- Specifics of tracer uptake can be affected by the host
- Animal tumor models can be used as a "testing ground" that provide heterogeneous microenvironment characterized by a wide range of physiological states

VCU MASSEY CANCER CENTER
Virginia Commonwealth University

Targeting Cell Proliferation

^{18}F FLT autoradiography image
average threshold contour

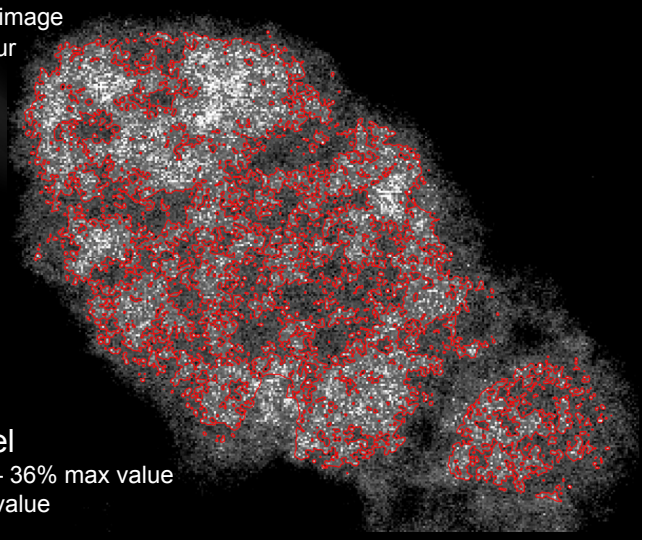

SQ20B tumor model
Average threshold value – 36% max value
Current tumor – 0% max value

Marian Axente, YIS 2011

15

Targeting Cell Proliferation

Bromodeoxyuridine - proliferation
threshold contour



SQ20B tumor model
Cell proliferation pattern does not allow "targetable" segmentation

Tracer affinity to the target is not sufficient

Marian Axente, YIS 2011

16

Tumor Morphology

SQ20B

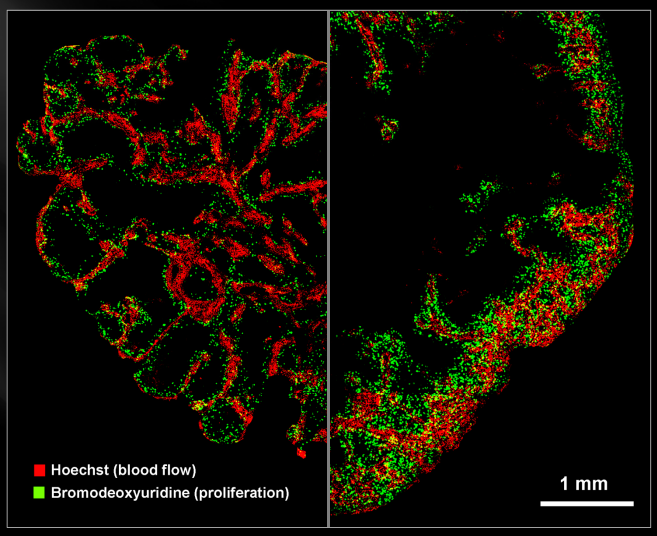

FaDu

Marian Axente, YIS 2011

17

^{18}F-FLT intratumoral distribution

SQ20B

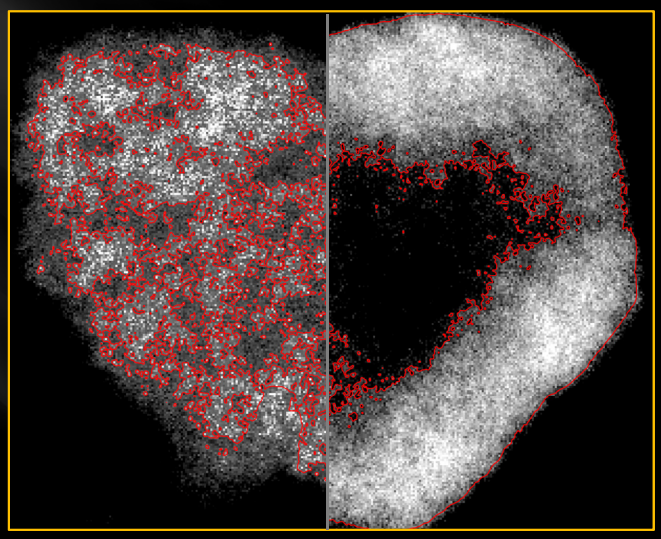

FaDu

"Targetable" segmentation might not be possible

18

Conclusions

- Different applications of PET imaging require different validation
- Animal tumor models can be used as a "testing ground" for validation studies
- Tumor histology plays a major role in defining PET tracer uptake distribution and PET image formation

VCU MASSEY CANCER CENTER
Virginia Commonwealth University

Acknowledgements

Marian Axente
Chris Bass
Jun "Jessie" He

Department of Radiation Oncology

Center for Molecular Imaging

Jeffrey Williamson
Ross Mikkelsen
Jerry Hirsch
Mitchell Anscher
John Humm
Sean Carlin
Joe O'Donoghue
Jamal Zweit
Sundaresan Gobalakrishnan
Geoffrey Hugo



VCU MASSEY CANCER CENTER
Virginia Commonwealth University