SBRT: Simulation, Localization, and Delivery

Moyed Miften, PhD
University of Colorado

SBRT Process in a Nut Shell

- Immobilization and Simulation
  - Motion Management
- Treatment Planning (TP)
  - Image Fusion
  - Planning Techniques (3DCRT, IMRT, Arcs)
  - Dose Calculation Algorithms
- Localization
- Treatment Delivery
- Quality Assurance

SBRT ≠ IMRT

- Ultra-high doses per fx, 10 to 20 Gy, in a hypofractionated regimen of 5 or fewer fxs
  - Errors will not be diluted
- Technically refined patient repositioning and treatment delivery procedures

SBRT ≠ IMRT

TG 101

TABLE I. Comparison of typical characteristics of 3D/IMRT radiotherapy and SBRT.

Characteristic	3D/IMRT	SBRT
Dose/fraction	1.8–3 Gy	6–30 Gy
No. of fractions	10–30	1–5
Target definition	CTV/PTV (gross disease+clinical extension): Tumor may not have a sharp boundary.	GTV/CTV/ITV/PTV (well-defined tumors: GTV=CTV)
Margin	Centimeters	Millimeters
Physics/dosimetry monitoring	Indirect	Direct
Required setup accuracy	TG40, TG142	TG40, TG142
Primary imaging modalities used for treatment planning	CT	Multimodality: CT/MR/PET-CT
Redundancy in geometric verification	No	Yes
Maintenance of high spatial targeting accuracy for the entire treatment	Moderately enforced (moderate patient position control and monitoring)	Strictly enforced (sufficient immobilization and high frequency position monitoring through integrated image guidance)
Need for respiratory motion management	Moderate—Must be at least considered	Highest
Staff training	Highest	Highest+special SBRT training
Technology implementation	Highest	Highest
Radiobiological understanding	Moderately well understood	Poorly understood
Interaction with systemic therapies	Yes	Yes

Immobilization/Simulation

- Scanning in TX Position
  - CT, MR, PET-CT
- Vac-Loc
- Motion Management
  - Abdominal Compression Plate
  - Pressure Belt
  - Body Immoblization
- CT scan with ≤ 3 mm slice thickness

Motion Management and CT Simulation

- Suppressed respiratory motion techniques (Compression Paddle, Pressure Belt)
- Free Breathing (FB) & Slow CT-Scanners
- Free Breathing & Fast CT-Scanners
  → Tumor at atypical position
- Breath-Hold (BH) CT-Scans
  → Motion encompassing volume
- Respiratory Correlated CT (4D-CT)

Commercial Devices

ROC Abdominal Compression Belt

- Plastic board with two long slits on the sides
- Blood pressure cuff, Velcro® mounted under the board
- Adjustable, Velcro® covered belt
- Sewn-on ruler for consistent setup

Courtesy Joerg Lehmann, Ph.D.

Pneumatic Compression Belt

- Air inflation bulb
- Pressure gauge
- Non-Rigid
- Marking of the patient skin & immobilization device
- Recording of the pressure
- Easy to use!

→ more compression compared to the paddle

Slow CT Scans for SBRT

- Patient breathes normally
- Rotation time >> breathing period
- CT images are an average over all breathing phases
- Borders of tumor volumes can become diffuse

Observe target movement under fluoroscopy

4DCT – What Do We Get

- Snapshots of selected breathing phases, including EOE, EOI, and everything in-between
- Average of all breathing phases (like slow CT)
- Combination of M out of N breathing phases (needed for gated RT delivery)
- Max/Min Intensity Projections (MIP/minIP)
- Visualization of the tumor motion over the whole respiration cycle
- Display of anatomy in space (3D) and time (4D)

Statistics from a 4DCT Scan

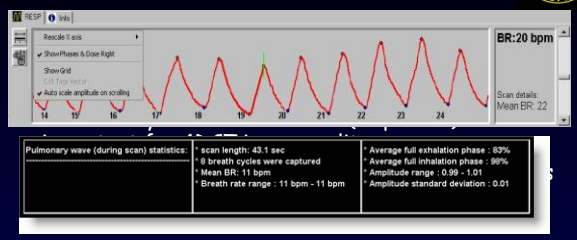

A relative amplitude range of 0.95 – 1.05 for the pulmonary breathing wave during the 4DCT scan of a lung SBRT patient indicates

10% 1. In-consistent breath size (amplitude)

6% 2. Decreased 4DCT image quality

78% 3. The patient is a suitable candidate for respiratory-correlated SBRT treatment

3% 4. Improved processing speed of the 4DCT image reconstruction algorithm

4% 5. The patient has a poor lung function

A relative amplitude range of 0.95 – 1.05 for the pulmonary breathing wave during the 4DCT scan of a lung SBRT patient indicates

1. In-consistent breath size (amplitude)
2. Decreased 4DCT image quality
3. The patient is a suitable candidate for respiratory-correlated SBRT treatment
4. Improved processing speed of the 4DCT image reconstruction algorithm
5. The patient has a poor lung function

Refs:
R. Underberg, F. Lagerwaard, B. Slotman et al., Benefit of respiration-gated stereotactic radiotherapy for stage I lung cancer: An analysis of 4DCT datasets, IJROBP 62, 554-560 (2005).
V.R. Kini, S.S. Vedam and P.J. Keall et al., Patient training in respiratory-gated radiotherapy, Med Dosim 28, 7-11, (2003)

Lung: Contouring ITV on MIP

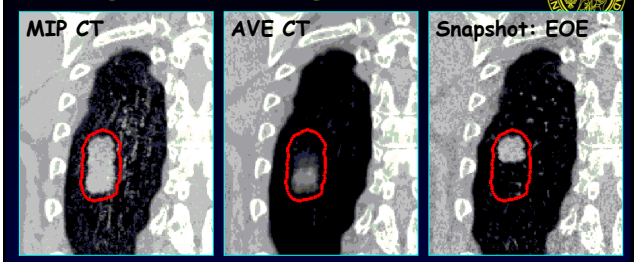

→ Contouring on Frozen Images is superior
- Better contrast (brightest voxels along the viewing ray)
- Avoids geometrical misses due to irregular motion

→ Inspecting the FB (or Ave) images may be necessary
→ Use of FB (or Ave) for dose calculations

Liver: Contouring ITV on minIP

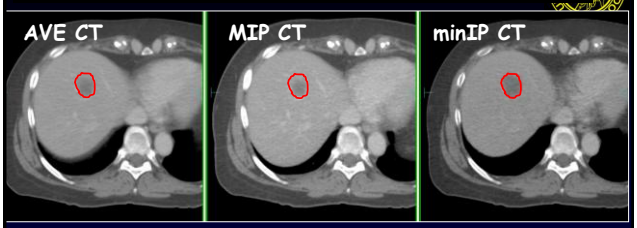

→ Contouring on minIP is superior
- Better contrast (darkest voxels along the viewing ray)
- Display structures w/ low signal compared to surrounding structures

→ Inspecting the FB (or Ave) images may be necessary
→ Use of FB (or Ave) for dose calcs

The minimum and maximum intensity projection (MinIP and MIP) images for liver & lung tumors, respectively, can be used to

9% 1. Improve treatment localization accuracy

9% 2. Reduce the ITV to PTV margin

2% 3. Reduce intra-fraction motion

80% 4. Obtain the tumor motion-encompassing volume

1% 5. Improve dose calculation accuracy

The minimum and maximum intensity projection (MinIP and MIP) images for liver & lung tumors, respectively, can be used to

1. Improve treatment localization accuracy
2. Reduce the ITV to PTV margin
3. Reduce intra-fraction motion
4. Obtain the tumor motion-encompassing volume
5. Improve dose calculation accuracy

Ref: P. J. Keall et al., "The management of respiratory motion in radiation oncology report of AAPM Task Group 76," Med. Phys. 33, 3874-3901 (2006).

Liver: CT Contrast Enhancement

- Hepatocellular Carcinomas (HCCs)
  - best visualized on an arterial phase due to hyper-vascularity
  - arterial phase of image acquisition ~ 25-30 secs after the initiation of the contrast injection
- Hypo-attenuating lesions (liver mets)
  - best visualized on a venous phase
  - venous phase of image acquisition ~ 60-75 seconds
- Equilibrium phase of image acquisition ~ 3-5 min
  - Useful for hyperdense lesions with prolonged enhancement

Is a Single 4DCT Sufficient for TP?


CLINICAL INVESTIGATION Lung

IS A SINGLE RESPIRATORY CORRELATED 4D-CT STUDY SUFFICIENT FOR EVALUATION OF BREATHING MOTION?

Matthias Guckenberger, M.D., Jürgen Wilbert, Ph.D., Jürgen Meyer, Ph.D., Kurt Baier, Anne Richter, and Michael Flentje, M.D.

Department of Radiation Oncology, Julius-Maximilian University of Würzburg, Würzburg, Germany

- 10 patients with 14 lung mets
  - SBF for 30 min-- 4 repeated 4DCT every 10 min
  - Abdominal compression in 7 pts
- Peak-to-peak tumor motion
  - 9.9 ± 6.8 mm at T0
  - 9.0 ± 7.4 mm at T30
- 1 pt with poor PF → motion increase from 17.4 mm to 28.3
- 5 pts → mean tumor position shift by 3 mm
- TP based on a single 4DCT is reliable for majority of pts
- Increased intrafractional uncertainties for pts with poor PF and with tumors located in the lower lobe

Multimodality Imaging for TP

- Lung and Liver
  - Likely: fusion with PET/CT diagnostic scans
    - Challenges
      - arms up vs. arms down
      - flat-table top vs. curved table top
      - uniform sampling
  - Preferred: fusion of planning CT with PET/CT scan in the treatment position
  - Ideal: PET/CT sim in the treatment position
- Spine
  - Fusion of planning CT with MR

PTV Margins

SBRT Reports on Lung & Liver

TG101

- 0.5 cm axial and 1.0 cm Sup/Inf for txts with suppressed respiratory motion
- Some centers are moving toward an isotropic expansion with 1.0
  → 0.5 cm

Reports on Spine
→ GTV=PTV

Recommendation: At the current time, it remains difficult to base target margins directly on clinical results. However the adequacy of the definitions of target margins (i.e., GTV, CTV, ITV, etc.) in SBRT should be based on an understanding of how the steep dose gradients and high fractional doses of SBRT affect the accuracy of traditional margin recipies,[119] as well as the natural history of the tumor, the limitations of in-house localization capabilities to reduce random and systematic treatment uncertainty, and from information in the current literature. Simultaneously, centers should make systematic efforts to gather and analyze clinical results to improve margin design in the future.

TP Techniques & Beam Arrangements

- 3DCRT → 7 to 13 Beams
- IMRT → 7 to 13 Beams
- VMAT → 1 full Arc and 1/2 Arcs
- Dynamic Conformal Arcs → 1 to 7 Arcs
  - Avg: 3 Arcs
- Coplanar and non-coplanar directions
- 6, 10, and 15 MV beams

Plan Reporting & Evaluation

RTOG 0915

PTV Volume (cc)	Ratio of Prescription Isodose Volume to the PTV Volume		Ratio of 50% Prescription Isodose Volume to the PTV Volume, $R_{50\%}$		Maximum Dose (in % of dose prescribed) @ 2 cm from PTV in Any Direction, D_{2cm} (Gy)		Percent of Lung Receiving 20 Gy Total or More, V_{20} (%)	
	Deviation		Deviation		Deviation		Deviation	
	None	Minor	None	Minor	None	Minor	None	Minor
1.8	<1.2	<1.5	<5.9	<7.5	<50.0	<57.0	<10	<15
3.8	<1.2	<1.5	<5.5	<6.5	<50.0	<57.0	<10	<15
7.4	<1.2	<1.5	<5.1	<6.0	<50.0	<58.0	<10	<15
13.2	<1.2	<1.5	<4.7	<5.8	<50.0	<58.0	<10	<15
22.0	<1.2	<1.5	<4.5	<5.5	<54.0	<63.0	<10	<15
34.0	<1.2	<1.5	<4.3	<5.3	<58.0	<68.0	<10	<15
50.0	<1.2	<1.5	<4.0	<5.0	<62.0	<77.0	<10	<15
70.0	<1.2	<1.5	<3.5	<4.8	<66.0	<86.0	<10	<15
95.0	<1.2	<1.5	<3.3	<4.4	<70.0	<89.0	<10	<15
126.0	<1.2	<1.5	<3.1	<4.0	<73.0	>91.0	<10	<15
163.0	<1.2	<1.5	<2.9	<3.7	<77.0	>94.0	<10	<15

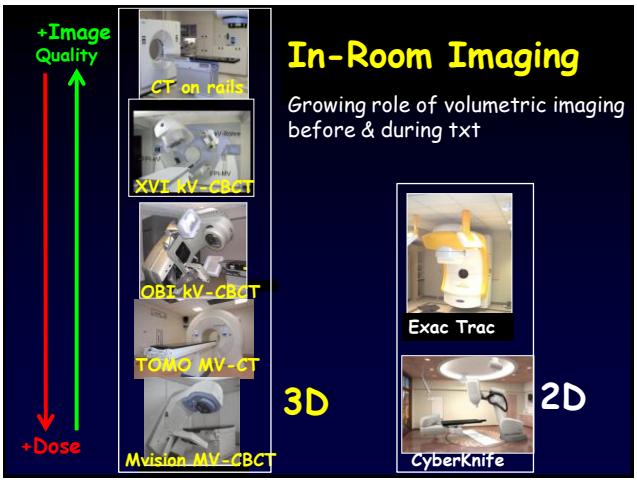

In-Room Imaging

Growing role of volumetric imaging before & during txt

Localization

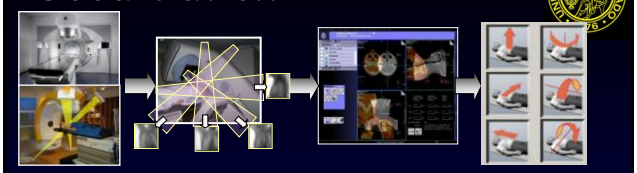

Acquisition Reconstruction Registration Table offsets

- Fusion shifts = table corrections needed to correct patient positioning
  - Translational shifts (Varian, Elekta, Siemens)
  - Translational shifts, pitch & roll (Novalis)
  - Translational shifts & roll (Tomotherapy)
  - Translational & rotational (Elekta w/ Hexapod table)

2D vs. 3D Localization

- kV 2D Imaging
  - Limited information
  - Limited FOV of EPI does not always provide sufficient information for fusion process
    - → may result in erroneous results
  - Good fusions with bone and fiducials
  - Verification CT prior to treatment and external aides can help eliminate gross errors
- CBCT Imaging
  - Large amount of information → good fusion in tissue and bone
  - Subject to operator errors

In-room CBCT-based volumetric imaging technologies for SBRT treatment localization are

1. Less accurate than 2D kV/MV imaging
2. Used for continuous monitoring of tumor position during treatment (7%)
3. Not capable of detecting rotation setup errors (4%)
4. Able to correct for systematic errors only (6%)
5. Subject to operator errors (82%)

In-room CBCT-based volumetric imaging technologies for SBRT treatment localization are

1. Less accurate than 2D kV/MV imaging
2. Used for continuous monitoring of tumor position during treatment
3. Not capable of detecting rotation setup errors
4. Able to correct for systematic errors only
5. Subject to operator errors

Ref: Benedict et al., "Stereotactic body radiation therapy: The report of AAPM Task Group 101," Med. Phys. 37, 4078–4101 (2010).

Repeated Localization Imaging?

- Treatment time → ~30 mins
  - kV 2D (e.g. Exac Trac) and CBCT
    - Image & localize → Treat → Image → Treat

The mean intrafraction tumor position deviation → measured as function of the interval between localization & repeated CBCT for 8 Pts

→ 5.3 mm if the time > 34 mins
→ 2.2 mm if the time < 34 mins
} $p < 0.01$


PHYSICS CONTRIBUTION

CONE-BEAM COMPUTED TOMOGRAPHY FOR ON-LINE IMAGE GUIDANCE OF LUNG STEREOTACTIC RADIOTHERAPY: LOCALIZATION, VERIFICATION, AND INTRAFRACTION TUMOR POSITION

Correction for Rotations?

Spine SBRT

- Evaluated impact of rotational setup errors on dose using 39 CBCT scans from 16 txts
- Cord PRV expansion of 2 mm assures safe txt delivery in the face of typically encountered rotations

Lung SBRT

- Evaluated translational and rotation errors for 8 Pts.
- Mean rotational variation was 0.1 ± 0.2°


PHYSICS CONTRIBUTION

INFLUENCE OF ROTATIONS ON DOSE DISTRIBUTIONS IN SPINAL STEREOTACTIC BODY RADIOTHERAPY (SBRT)


Image-Guided Stereotactic Body Radiotherapy for Lung Tumors Using BodyLoc With Tomotherapy: Clinical Implementation and Set-Up Accuracy

Caution: Pts. might involuntary counteract the couch motion

SBRT Txt May Last 45 mins

- Possible compromise in treatment efficacy for individual fxs that require long txt time
  - Tumor intra-fraction motion and patient involuntary movement during delivery
  - Theoretical risk of intra-fractional radiation damage repair within tumor cells in the context of prolonged fractional delivery
- Patient comfort

Rotation Delivery is Efficient

12 Gy in 3 fxs

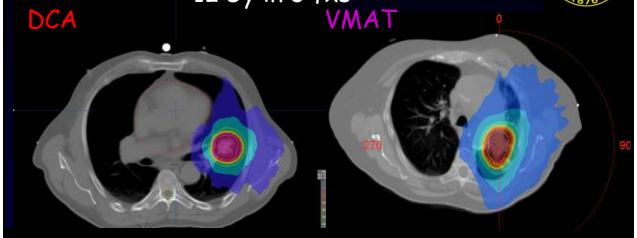

- # of MUs 2033
- Two partial DC arcs → 20-160 & 340-20 @ 90° Table
- Txt time ~6 mins

- # of MUs 2569
- # of segments 113
- One partial arc → 0-180
- Txt time ~6 mins

VMAT Delivery

- Rotational IMRT
- Continuous gantry motion
- Continuous leaf motion
- Variable gantry speed and variable dose rate
  → Variable MU per degree

VMAT By Numbers

Number as of 7/25/11: 120 VMAT Cases

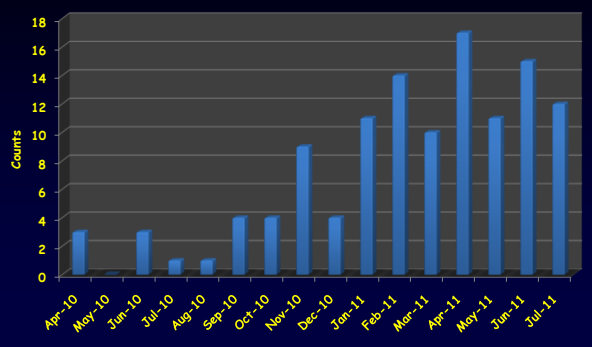

VMAT SBRT vs. IMRT

- ❑ SBRT → 58 Patients (≤ 5 fxs)
  - 9 Prostate (incl. 6 on protocol)
  - 21 Lung (incl. 2 protocols 1x34Gy)
  - 19 Liver
  - 5 Periariortic Lymph Nodes (PAN)
  - 1 H&N
  - 3 Pancreas

- ❑ IMRT→ 62 Patients (> 5 fxs)
  - 51 Prostate (incl. prostate bed & boost)
  - 2 Brain (incl. boost)
  - 3 Ventricles (Peds)
  - 1 Spleen
  - 3 Lung
  - 2 Liver

Case 1: Lung SBRT

34 Gy in 1 fx

RTOG 0915: A randomized Phase II Comparing 2 SBRT Schedules for Medically Inoperable Patients w/ Stage I Peripheral NSCLC

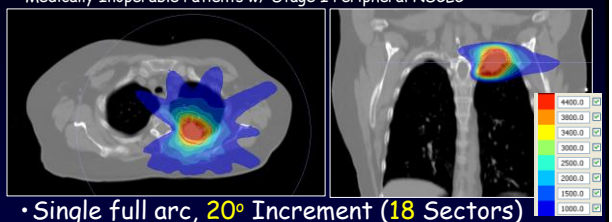

- Single full arc, 20° Increment (18 Sectors)
- # of Segments 462
- # of MUs 9851
- Txt time 23 mins & 20 secs

→ Image → Treat (17 Gy) → Image → Treat (17Gy)

Case 2: Prostate SBRT

50 Gy in 5 fxs

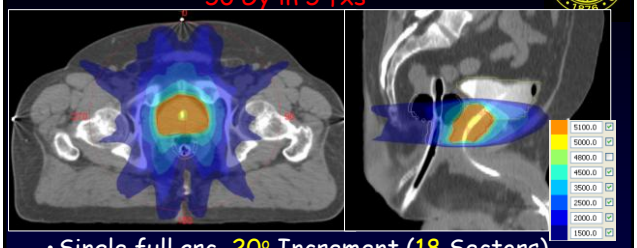

- Single full arc, 20° Increment (18 Sectors)
- # of Segments 529
- # of MUs 4620
- Txt time 12 mins & 35 secs

Case 3: Liver SBRT

18 Gy in 3 fxs

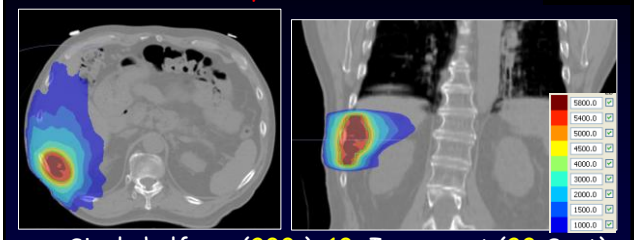

- ~Single half arc (200°), 10° Increment (20 Sect)
- # of Segments 85
- # of MUs 3324
- Txt time 7 mins & 5 secs

SBRT: 3%-3mm QA Passing Rate

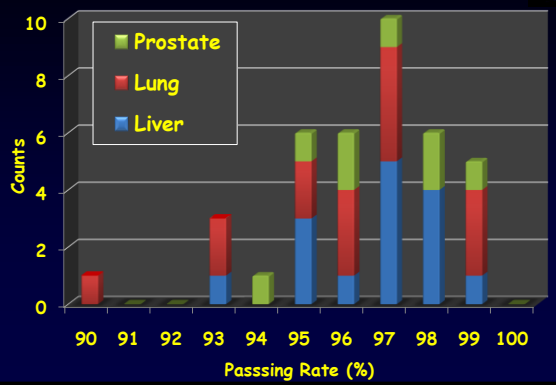

Conclusions

- SBRT is a complex treatment procedure
  - Team approach
- Accurate and comfortable patient setup and motion management procedures are essential
- Simple and effective solutions can be implemented to minimize setup errors and respiratory motion
- Key: Care must be exercised during the whole SBRT txt process

Thank You

Team
Kelly Stuhr
Quentin Diot
Tracey Schefter
Laurie Gaspar
Brian Kavanagh



University of Colorado Anschutz Medical Campus