Quantitative Ultrasound Imaging of Tendon Deformation during Dynamic Loading

Darryl G. Thelen, Ph.D., Laura Chernak, David Bunger

Departments of Mechanical Engineering, Biomedical Engineering, and Orthopedics and Rehabilitation

THE UNIVERSITY of WISCONSIN MADISON

Musculoskeletal Biomechanics

Motion Analysis | ***Musculoskeletal Simulations*** | ***Finite Element Models*** | ***Imaging Biomechanics***

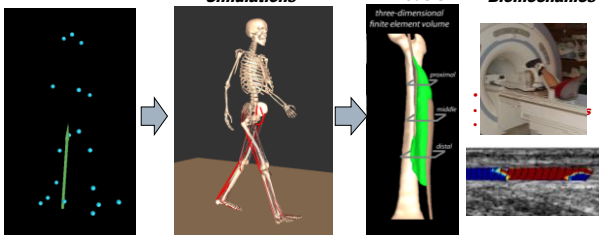

Thelen and Anderson
J Biomech 2006

Blemker et al.
Annals Biomed Eng 2007

Tendon Injuries

Common in work and sports settings
- Acute tears
- Overuse (repetitive loading) injuries

Quantitative imaging of tendon tissue mechanics relevant for:
- Understanding injury mechanisms
- Diagnosis of subtle abnormalities
- Evaluation of treatment outcomes

Acute Musculotendon Strain Injuries

Injuries occur during eccentric contractions
(Garrett 1990)

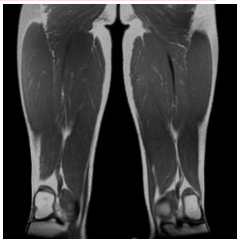

Post-injury remodeling can significantly alter the morphology at the muscle-tendon junction (Silder et al, 2008)

Dynamic MR Imaging of Muscle Tissue Deformations

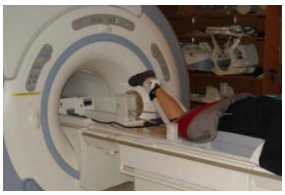

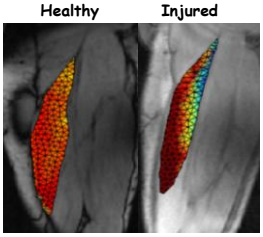

Silder et al. *J Biomechanics*, 2010

- Cine PC measurement of 3D muscle tissue velocities
- Integration to track tissue motion

Long-Term Changes in Injured Tendon Morphology

Uninjured Limb

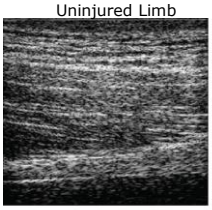

Previously Injured Limb

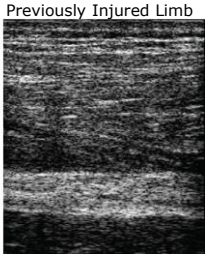

How to extract quantitative information regarding mechanics and function?

Chernak et al. ASB 2010

Quantitative Ultrasound Imaging of Tendon Mechanics

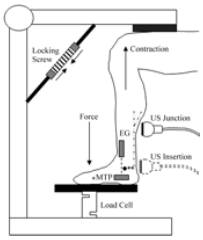

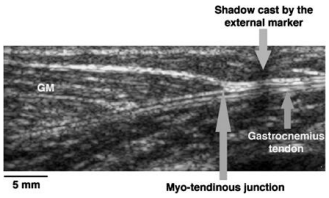

- Visually track muscle-tendon junction
- Using multiple probes, compute average stretch

1. Magnaris, *J Biomechanics*, 2002
2. Magnaris and Paul, *J Exp Biology* 2000
3. Bryant et al., J Appl Phys 2008

Tendon Imaging using Ultrasound Elastography

Elastography *(Ophir et al. 1991)*

- Image tissue in undeformed and deformed states
- Speckle tracking of tissue motion
- High resolution strain information along beam direction

B-Mode Image



Strain Image

Elastographic imaging of muscle and tendon tissue deformations

- Witte et al. 2006
- Farron et al. 2008
- Deffieux et al. 2008
- Lopatta et al. 2010

Challenges for Imaging Muscle-Tendon Dynamics

- Primary motion is transverse to beam direction
- Large deformations and relative motion
- Fibrous architecture

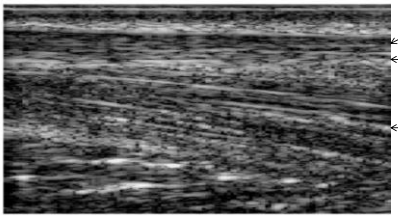

Ex Vivo Tendon Testing

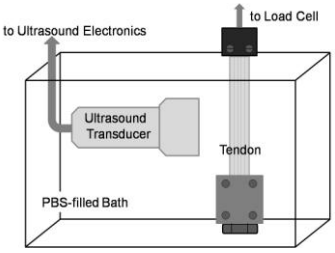

- Porcine flexor tendon
- Sinusoidal stretch
  - 0.5 cycles/sec
  - 4% peak stretch
- Measurements
  - RF data (63 frames/sec)
  - Tendon force

Tissue Motion Tracking

- Place nodes along the fascicles
- 2D frame-to-frame speckle tracking
- Integrate to get cumulative motion

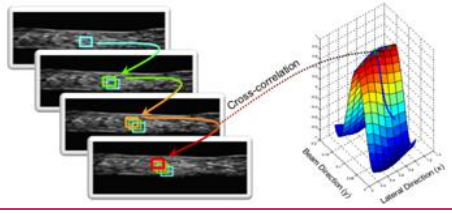

Ex Vivo Tendon Strains

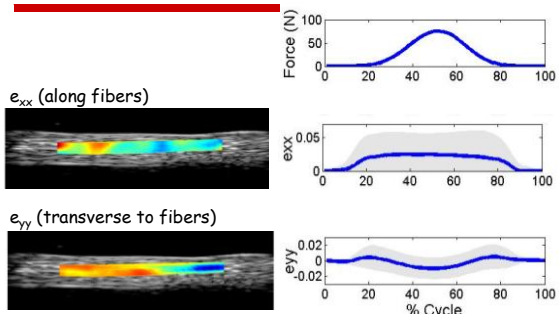

Achilles Tendon

- Gastrocnemius and soleus muscles insert on to the tendon
- Injuries tend to occur 2-7 cm proximal to insertion

(Ahmed et al. J Orthop Res 1998, Jozsa et al. Am J Sports Med)

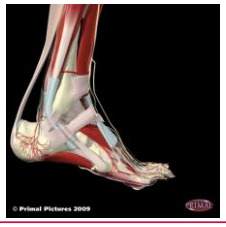

Achilles Tendon Imaging during Eccentric Contractions

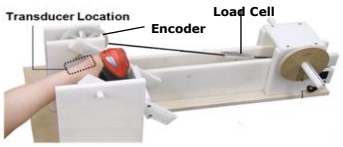

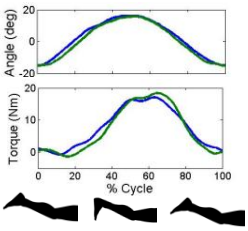

- Cyclic motion at 0.5 Hz
- Measurements
  - ankle angle
  - ankle torque
  - RF data (70 fps)

Along Fiber Strain

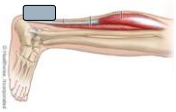

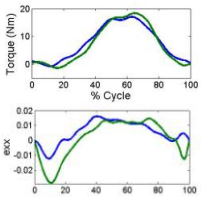

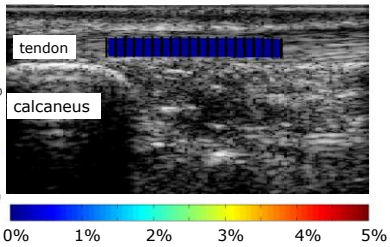

Soleus Muscle and Tendon Strain

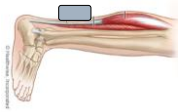

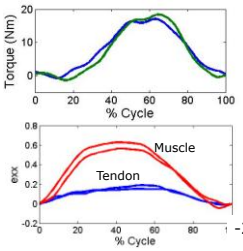

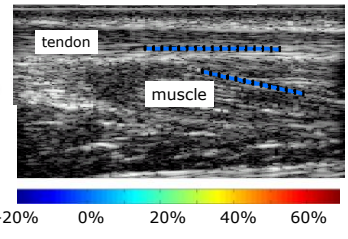

Conclusions

- Ultrasound elastography can be adapted to image muscle and tendon dynamics
- Nonuniform tendon strain patterns emerge during eccentric contractions
- Motion and strain information is relevant for investigating musculotendon function in normal, injured and diseased states

UDSMR.org
UW Neuromuscular Biomechanics Lab

Acknowledgements

- David Bunger
- Laura Chernak
- Ryan DeWall
- Sarah Duenwald, PhD
- Ken Lee, MD
- Tomy Varghese, PhD
- Daniel Volk

- NIH AR56201

UW Neuromuscular Biomechanics Lab